

# The application of discriminant analysis in differentiation of fibroadenoma and ductal carcinoma of breast tissue using ultrasound velocity measurement

M. Mokhtari-Dizadji<sup>1\*</sup>, M. Vahed<sup>1</sup>, M. Gity<sup>2</sup>

<sup>1</sup> Department of Medical Physics, Tarbiat Modarres University, Tehran, Iran

<sup>2</sup> Department of Radiology, Tehran University of Medical Sciences, Tehran, Iran

---

## ABSTRACT

**Background:** Ultrasound propagation velocity was measured experimentally in normal, fibroadenoma and ductal carcinoma breast tissues, in order to distinguish normal breast tissue from tumors.

**Materials and methods:** In quantitative measurements of ultrasound velocity, 403 breast tissue images were selected, comprising 130 normal breast tissue, 130 fibroadenoma, and 143 ductal carcinoma tumors. The cases were implanted in breast tissue mimicking materials and ultrasonic images (A-mode) at 35°C were processed and evaluated.

**Results:** It was observed that ultrasound propagation velocity is an important factor for distinguishing *in vitro* specimens of fibroadenoma and ductal carcinoma from normal tissue (P-value<0.005). Evaluation of ultrasound velocities showed that from normal breast tissue, fibroadenoma and ductal carcinoma, ultrasound velocity increases respectively. The discriminant functions of types of lesions, based on ultrasound velocity, have been formulated by discriminant analysis. The results indicate that probability of discrimination, sensitivity and specificity for tumors and normal breast tissues are 72, 60 and 100 percents at 35°C. With measuring ultrasound velocities, we can distinguish normal breast tissue of from ductal carcinoma and fibroadenoma masses (with the probability of 100%).

**Conclusion:** It is proposed that probably by measuring attenuation coefficient and ultrasound velocity on time, fibroadenoma and ductal carcinoma tumors can be differentiated well.  
*Iran. J. Radiat. Res., 2003; 1(3): 163 – 169*

---

**Key Words:** Ultrasonic tissue characterization, ultrasonic imaging, velocity, breast cancer diagnosis.

## INTRODUCTION

When ultrasound fields interact with tissue, the characteristics of the field will be affected in a manner, which is dependent upon the acoustic properties of the tissue (Price *et al.* 1980, Taylor *et al.* 1989). The most important acoustic parameters of the tissue are velocity, attenuation, impedance, backscatter,

angular dependence of scattering, frequency dependence of attenuation, and non-linearly parameter (Duck 1990). Currently there is considerable interest in ultrasonic tissue characterization. The general aim is to isolate and measure those ultrasonic parameters which discriminate the different tissues and their pathological states (Rosenfield *et al.* 1980). Ultrasound waves are used in breast imaging for the detection of pathological conditions, particularly cystic and cancerous conditions (Edmonds *et al.* 1991, Wiewad *et al.* 2000). Most carcinomas are detected by ultrasound because they are hypoechoic compared to the

---

\* Corresponding author:

Dr. M. Mokhtari-Dizadji, Department of Medical Physics,  
Tarbiat Modarres University, P.O. Box:14115-111,  
Tehran, Iran. Fax: +98- 21- 8006544  
E.mail: [mokhtarim@modares.ac.ir](mailto:mokhtarim@modares.ac.ir)

surrounding dense tissues. Fat and some other benign lesions may be hypoechoic as well. Thus, carcinomas without shadowing may not be detected by conventional ultrasound. Furthermore, hypoechoic fat lobules, fibroadenomas or inflammation can be mistaken for malignancy, because detection and differentiation of small malignancies, especially in large breasts, is limited and the interpretation of the ultrasound images is only dependent on the experience of radiologist and palpate examinations. Therefore, it would be helpful to obtain additional information from the ultrasound examination to simplify and improve the interpretation.

A number of techniques for measuring ultrasound velocity with pulse-echo ultrasound have been proposed in this paper and have been recently reviewed. These techniques can be classified to three groups: those based on the analysis of aberrations in images obtained from different directions, transit-time methods using intersecting beams, and methods using axial measurements of travel time (Robinson *et al.* 1991, Wiewad *et al.* 2000). In addition, a number of techniques for correcting phase aberration errors, of which gross ultrasound velocity errors are a subset, have been proposed and evaluated (Krishnan *et al.* 1997). The impact of ultrasound velocity errors on blood flow velocity measurements has also been investigated and reviewed (Christopher *et al.* 1995).

Recently a simplified procedure was published: Clinical Amplitude Velocity Reconstruction Imaging (CARI). Sonography allows the assessment of ultrasound velocity information, which is usually obtained by B-scan ultrasound (Richter 1995). CARI sonography is an automated ultrasound examination of the breast in which the breast is fixed between two compression plates, as in mammography. Ultrasound waves transverse the upper compression plate and the compressed breast. The lower plate can be a metallic plate, therefore it is imaged as an intensely echogenic line underneath the compressed breast as a reference structure. Changes in the ultrasound velocity are visualized on sonograms as areas of elevation and decreased or increased echogenicity in the

hyperechoic line that represents the metallic plate (Richter and Heywang-Kobrunner 1995).

In general, acoustic parameters of tissue are not constant. The ultrasound velocity is dependent upon frequency, temperature, anisotropy, tissue composition, tissue fixation and changes following death (Duck 1990). The ultrasound velocity in non-fatty tissues increases with temperature and reaches maximum at around 50°C, while for fatty tissue a negative dependence is reported (Bamber and Hill 1979).

In this paper, we have described a technique for the measurement of ultrasound velocity with pulse-echo ultrasound. The relative ultrasound velocities at 35°C were measured to determine their value in distinguishing fibroadenoma and ductal carcinoma breast lesions from normal breast tissue in 403 breast tissue images that specimens were implanted in breast tissue mimicking materials.

## MATERIALS AND METHODS

The study included 403 ultrasonography images of breast tissue which had pathologic reports, comprising 130 normal breast tissues, 130 fibroadenoma, and 143 ductal carcinoma. Normal breast tissues and lesions were implanted in breast tissue mimicking materials (Mokhtari-Dizaji 2002) and put in a cubic chamber. To measure the ultrasound velocity, we used an experimental set consisting of a clamp, an ultrasound A-mode device (Echoscans US-2500 NIDEK, 10 MHz), a video blaster (SE Creative Technology), a personal computer (Pentium 133), a heater (Rena Co.) and a digital thermometer (SIGMA,  $\pm 0.01^\circ\text{C}$ ). The chamber containing the tissues was heated and temperature ( $\pm 0.01^\circ\text{C}$ ) during the experiment was monitored and controlled by a thermocouple inserted in the chamber wall. Tissue specimens were collected from pathologic centers (especially Imam Khomani Hospital, Tehran, Iran). The specimens were cut by microtome (NVSLM1-Vibroslice) and implanted in breast parenchymal tissue of mimicking materials. These materials have acoustic properties similar

to real breast tissue. The specimens were heated and at 35°C, ultrasound images were taken by A-mode sonography. The images were digitized by the videoblaster board and saved by the computer. The ultrasound velocities in the specimens ( $C_s$ ) were calculated by the following formula:

$$\frac{1}{C_s} = \frac{1}{C_{ph}} - \frac{l' - l''}{l_s \cdot C_A}$$

where  $C_{ph}$  is the ultrasound velocity in tissue mimicking materials,  $C_A$  is ultrasound velocity in eye that the A-mode ultrasound system was regulated at 1550 m.s<sup>-1</sup>,  $l_s$  is the real length of the specimens,  $l'$  is the length of the tissue mimicking materials and  $l''$  is the length measured by the A-mode ultrasound system. Therefore, ultrasonic images were processed and the ultrasound velocities in normal breast tissue, fibroadenoma and ductal carcinoma tumors were measured. The relative accuracy of the measurements is assumed to be approximately 3%. Thus, the measurement error can be neglected comparing to the fluctuations of ultrasound velocity, which are caused by the inhomogeneity of the tissues. For each specimen, three measurements were performed. Neglecting the fixator effect and death time, conditions for all of the specimens were equal.

The mean of ultrasound velocities  $\pm$  standard deviation were calculated. The means of ultrasound velocities in different tissue groups were compared by using one way analysis of variance (ANOVA). Probability values less than 0.005 was regarded as statistically significant.

Linear discriminate analysis is a conventional statistical procedure for testing the extent to which groups such as various classes of lesions can be discriminated on the basis of their quantitative specifications (Scherzinger *et al.* 1989, Hedderson 1991). Therefore, the discriminant functions of types of lesions based on ultrasound velocity are formulated.

**Table 1.** The discriminant functions of types of groups based on ultrasound velocities at 35°C.

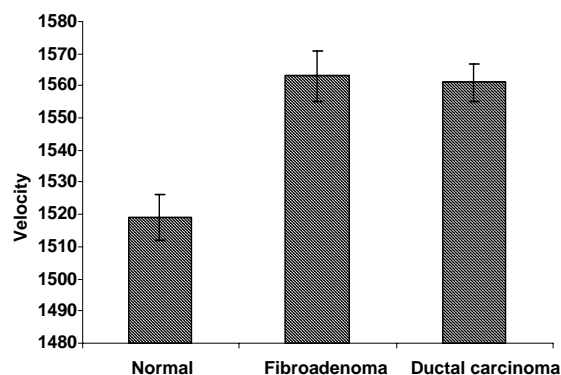
| Discriminant functions | Wilk's Lambda | Group centroids |              |                  | Canonical correlation |
|------------------------|---------------|-----------------|--------------|------------------|-----------------------|
|                        |               | Normal          | Fibroadenoma | Ductal carcinoma |                       |
| 0.123V* - 190.852      | 0.146         | -3.812          | 1.916        | 1.743            | 0.936                 |

\* Ultrasound velocity (m. s<sup>-1</sup>)

## RESULTS

Results of measuring ultrasound velocities in the evaluated groups were reported. First we considered 403 tissue images, comprising 130 normal breast tissues, 130 fibroadenoma and 143 ductal carcinoma tumors in biopsy specimens.

The means and standard deviations of ultrasound velocities in the evaluated groups are shown in figure 1. The statistical analysis of variance (ANOVA) indicates that differences between normal and fibroadenoma and ductal carcinoma groups were significant (P-value < 0.005). Although the assessment of the relative ultrasound velocity in breast tissue was successful, the ultrasound velocities differed only insignificantly among fibroadenoma and ductal carcinoma lesions (P-value > 0.005).



**Figure 1.** The Means and standard deviations of ultrasound velocities (m. s<sup>-1</sup>) at 35°C in the specimens of normal breast tissue, fibroadenoma and ductal carcinoma lesions.


The discriminant functions of types of lesions based on ultrasound velocities in the three groups are formulated by discriminant analysis. In table 1, the discriminant functions, group centroids and canonical correlations were calculated in the three groups at 35°C.

The statistical power of discriminant analysis can be tested by canonical correlation that must be close to 1.

Scatter plots using canonical variable to optimize the separation of the groups at 35°C are shown in figure 2. In figure 2, the numbers 1, 2

and 3 denote the group centroids in the space of canonical variable for the normal, benign and malignant groups, respectively.

It is clear that even under this presumably optimal separation, classes of fibroadenoma and ductal carcinoma occupy the same region.



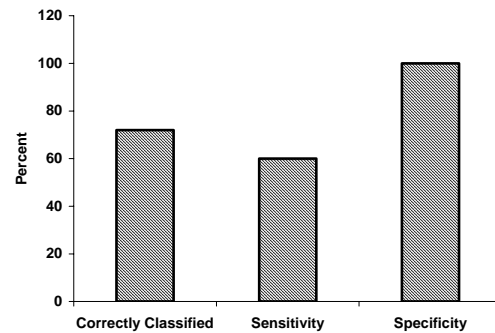
**Figure 2.** The scatter plot using canonical variable to optimize separation of the groups at 35°C.

The classification results of the groups were shown in table 2.

**Table 2.** The percent of classified results.

| Actual group                | Predictive group membership |              |                  |
|-----------------------------|-----------------------------|--------------|------------------|
|                             | Normal                      | Fibroadenoma | Ductal carcinoma |
| Normal<br>N = 130           | 100                         | 0            | 0                |
| Fibroadenoma<br>N = 130     | 6.2                         | 86.2         | 7.6              |
| Ductal carcinoma<br>N = 143 | 0                           | 58.4         | 41.6             |

It is observed that the correctly classified means for the discrimination of fibroadenoma are 86 % and for ductal carcinoma is only 42% and for normal are 100%. The percent of correctly classified groups, and the sensitivity and specificity of the three groups at 35°C are shown in figure 3.



**Figure 3.** The percent of correctly classified groups, and the sensitivity and specificity of the three groups at 35°C.

## DISCUSSION

Breast cancer is a major health care problem that affects an increasing number of young women. X-ray mammography provides an excellent tool for diagnosis, but has a high false positive rate and is possibly even less sensitive in women who have dense breasts (Leopold

1995). Clinical sonography, used in screening to detect breast cancer, is increasingly being used to reach a high degree of diagnostic accuracy and to eliminate physical hazards such as in X-ray mammography. The study of an ultrasonic tissue characteristic is an important factor in determining diagnostic criteria for breast cancer and for developing new ultrasonic equipment in clinical breast echography.

The existence of differences among the ultrasound velocities in malignant and benign tumors and normal breast tissue was reported (Carson *et al.* 1981, Robinson 1982, Carson *et al.* 1988, Richter and Heywang-Kobrunner 1995, Richter 1995, Richter *et al.* 1996, Mortensen *et al.* 1996, Pedersen 1997, El-Fallah *et al.* 1997, Wiewad *et al.* 1999, Wiewad *et al.* 2000). Two fundamental assumptions underlying the beam forming process as it is currently practiced are that the medium through which the ultrasound waves propagates, sends homogeneous beams and that ultrasound velocity through this medium is known. These assumptions don't reflect the true nature of the tissues of the human body (Anderson and Taylor 1998), because ultrasound velocities in actual tissues can range from 1400 to 1650 m.s<sup>-1</sup> (Duck 1990).

In this article, we have described a simple method, which allows visualization of changes in velocity, obtained by pulse-echo of ultrasound, on a real time sonography (A-mode). The ultrasound velocities in normal breast tissue, fibroadenoma and ductal carcinoma lesions have been measured at 35°C *in vitro*. Figure 1, is included as a general summary of ultrasound velocities in normal breast tissue and lesions measured. Like other imaging techniques, measurement of ultrasound velocity cannot show all ductal carcinoma lesions and does not discriminate malignant and fibroadenoma in all cases, but our measurements show large and significant differences between normal breast tissue and lesions.

Compared to previous studies, the measurements obtained in this study were performed exclusively *in vitro*. Based on previous works that compared ultrasound velocities measured *in vivo* and *in vitro*, it was

reported that with increasing temperature, the ultrasound velocity increases linearly in tissues rich in water (e.g. carcinoma, fibroadenoma, and glandular tissues) (Bamber and Hill 1979, Duck 1990). Only in fatty tissue, the measurement of ultrasound velocity confronted with difficulty (Duck 1990).

The ultrasound velocities in our evaluated three groups at 20, 25, 30 and 35°C show that with increasing temperature, ultrasound velocity increases linearly, with little slope as a consequence of having less fatty tissues (Mokhtari-Dizaji *et al.* 2002). Thus it is predictable, since young breast tissues have 70% glandular tissue and 30% fatty tissue which increases in old ages (Curny and Tempkin 1995). In this study, we have measured velocities of specimens in 35°C that was similar with body temperature.

Generally, our results indicate that ultrasound velocity is a good parameter for discriminating normal breast tissue from lesions. These results confirm those reported previously, obtained from direct and indirect measurements of ultrasound velocities in certain fibroadenoma lesions and ductal carcinoma. Although the assessment of the relative ultrasound velocities in breast tumors was successful, the relative ultrasound velocities differed only insignificantly among fibroadenoma and ductal carcinoma lesions (figure 2).

The discriminant analysis of the groups indicated that ultrasound velocity is an important variable for discriminating malignant lesions when compared to normal breast tissues, but it is not a suitable parameter for discriminating fibroadenoma and ductal carcinoma lesions. The discriminant analysis shows 72% for correctly classified. It is observed that the means of correctly classified groups for discriminating fibroadenoma, ductal carcinoma lesions and normal breast tissue are 87%, 43% and 100%, respectively. Probably, the reasons of overlapping of fibroadenoma and ductal carcinoma lesions are that elastic modulus in fibroadenoma lesions are more than that in ductal carcinoma lesions and the mass density of

fibroadenoma lesions is less than that of ductal carcinoma lesions (Mokhtari-Dizaji et al. 2000). The difficulty of discriminating ductal carcinoma from fibroadenoma lesions by using these data emphasizes the complexity of the problem and the need for inclusion of additional parameters for example attenuation coefficient, elastic modulus and so on.

Threshold values for color coding breast lesion images could be provided (Golub et al. 1993, Robinson et al. 1991). We can allocate a color code to each calculated velocity, thus ultrasonic images will be observed clearly.

## REFERENCES

- Anderson M. E. and Taylor G. E. (1998). The direct estimation of sound speed using pulse-echo ultrasound. *J. Acoust. Soc. Am.*, **104**: 3099-3106.
- Bamber J. C. and Hill C. R. (1979). Ultrasonic attenuation and propagation speed in mammalian tissues as a function of temperature. *Ultrasound Med. Biol.*, **5**: 149-157.
- Carson P. L., Meyer C. R., Scherzinger A. L., Oughton T. V. (1981). Breast imaging in coronal planes with simultaneous pulse-echo and transmission ultrasound. *Science*, **4**: 1141-1143.
- Carson P. L., Scherzinger A. L., Meyer C. R., Jobe W., Samuels. B, Adler D. D. (1988). Lesion detectability in ultrasonic computed tomography of symptomatic breast patients. *Invest. Radiol.*, **23**: 421-427.
- Christopher D. A., Burns P. N., Hunt J. W., Foster F. S. (1995). The effect of refraction and assumed speeds of sound in tissue and blood on Doppler ultrasound velocity measurements. *Ultrasound Med. Biol.*, **21**: 187-201.
- Curny R.A. and Tempkin B.B. (1995). Ultrasonography, an introduction to normal structure and functional anatomy. *W. B. Sanders Company. Chap. 40*.
- Duck F. A. (1980). Physical properties of tissue. *Academic Press*: 73-167.
- Edmonds P.D., Mortensen C. L., Hill J. R. (1991). Ultrasound tissue characterization of breast biopsy specimens. *Ultrasound imaging*, **13**: 162-185.
- El – Fallah A. I., Plantec M. B., Ferrara K. W. (1997). Ultrasonic measurement of breast tissue motion and the implications for velocity estimation. *Ultrasound Med. Biol.*, **23**: 1047-1057.
- Golub R. M., Parsons R. E., Sigel B, Feleppa E. J., Justin J., Zaren H. A., Rorke M., Sokil – Melgar J., Kimitsuki H. (1993). Differentiation of breast tumors by ultrasonic tissue characterization. *J. Ultrasound Med.*, **12**: 601-608.
- Hedderston J. (1991). SPSS/Pc+MADE simple. *Wadsworth Publishing Company*: 140-153.
- Krishnan S., Rigby K. W., O' Donnell M. (1997). Adaptive aberration correction of abdominal images using PARCA. *Ultrasound. Imaging*, **19**: 169-179.
- Leopold G. R. (1995). Breast imaging with an ultrasound CT scanner. *Breast Cancer Research Program Compendium of Awards*.
- Linzer M. (1979). Ultrasonic tissue characterization II. *National Bureau of Standards, Washington DC*: 227-233.
- Mokhtari-Dizaji M. (2002). Tissue mimicking materials for teaching sonographers and evaluation of their specifications after three years. *Ultrasound Med. Biol.*, **27**: 1713-1716.
- Mokhtari-Dizaji M., Zahedi E., Sharafi A. A., Gity M. (2000). Evaluation of Young modulus and presentation of new discriminant functions in diagnosis of normal and abnormal breast tissues by ultrasound. *Proceeding of the ICBME*: 277-278.
- Mokhtari-Dizaji M., Vahed M., Gity M. (2000). Measurement and comparison ultrasound velocity as a function of temperature in normal breast tissue and tumors. *Daneshvar*, **41**: 51-56.
- Mortensen C. L., Edmonds P. D., Gofu Y., Hill J. R., Jensen J. F., Schattner P., Shifrin L. A., Valdes A. D., Jeffrey S. S., Esserman L. J. (1996). Ultrasound tissue characterization of breast biopsy specimens: expanded study. *Ultrasound imaging*, **18**: 215-230.

- Pederson J. F. (1997). A simple method for relative assessment of the sound propagation velocity in breast tumors: technique and diagnostic efficacy. *A. J. R. Am. Roentgenol.*, **168**: 1591-1594.
- Price R. R., Jones T. B., Goddard J., James A. E. (1980). Basic concepts of ultrasonic tissue characterization. *Radiologic Clinics of North America*, **18**: 21-30.
- Richter K. (1995). Clinical amplitude velocity reconstructive imaging (CARI) – a new sonographic method for detecting breast lesions. *Br. J. Radiol.*, **68**: 375-384.
- Richther K., Heywang – Kobrunner S. H. (1995). Quantitative parameters measured by a new sonographic method for differentiation of benign and malignant breast disease. *Invest. Radiol.*, **30**: 401-411.
- Richter K., Heymang – Kobrunner S. H. (1995). Sonographic differentiation of benign from malignant breast lesions: value of indirect measurement of ultrasound velocity. *A. J. R.*, **165**: 825-831.
- Richter K., Willrodt R. G., Opri F., Heywang – Kobrunner S. H. (1996). Differentiation of breast lesions by measurements under craniocaudal and lateromedial compression using a new sonographic method. *Invest. Radiol.*, **31**: 401-414.
- Rosenfield A. T., Taylor K. J. W., Jaffe C. C. (1980). Clinical applications of ultrasound tissue characterization. *Radiologic Clinics of North America*, **18**: 31-58.
- Robinson D. E., Chen F., Wilson L. S. (1982). Measurement of velocity of propagation from ultrasonic pulse–echo data. *Ultrasound Med. Biol.*, **8**: 413-420.
- Robinson D. E., Ophir J., Wilson L. S., Chen C. F. (1991). Pulse – echo ultrasound speed measurements: progress and prospects. *Ultrasound Med. Biol.*, **17**: 633-646.
- Scherzinger A. L., Belgam R. A., Carson P. L., Meyer C. R., Sutherland J. V., Bookstein F. L., Silver T. M. (1989). Assessment of ultrasonic computed tomography in symptomatic breast patients by discriminant analysis. *Ultrasound Med. Biol.*, **15**: 21-28.
- Song C. W. (1984). Effect of hyperthermia on blood flow and microenvironment: a review. *Cancer Res.*, **44**: 4721s-4730s.
- Taylor K. J. W., Wells P. N. T (1989). Tissue characterization. *Ultrasound Med. Biol.*, **15**: 421-428.
- Weiwed W., Heinig A., Gotz L., Lampe D., Buchmann J., Millner R., Spielmann R. P., Heywang – Kobrunner S. H. (1999). Direct *in vitro* measurement of ultrasound velocity in carcinomas, mastopathic tissue, fatty tissue and fibroadenomas of the female breast. *Rofo. Fortschr. Geb. Ronthenstr. Neuen. Bildgeb. Verfahr.*, **171**: 480-484.
- Wiewad W., Heinig A., Goetz L., Hartman H., Lampe D., Bochmann J., Millner R., Spielmann R. P., Heywang – Koebrunner S. H. (2000). Direct measurement of sound velocity in various specimens of breast tissue. *Invest. Radiol.*, **35**: 721-726.