Volume 20, No 1 | International Journal of Radiation Research, January 2022

The evaluation of neurovascular relationships in trigeminal neuralgia: a pilot study on the optimal combination of high-resolution three-dimensional MR sequences

W. Jiang[1,2,3#], B. Liu[1,4#], Y. Liu[5#], J. Wang[3], Q. Ding[6], H. Ji[4], Y. Cui[2], Y. Wang[1], Q. Pang[7], Q. Zeng[2,8*]

[1]*First School of Clinical Medicine, Shandong University of Traditional Chinese Medicine, Jinan 250011, China*
[2]*Department of Radiology, Qianfoshan Hospital, Cheeloo College of Medicine, Shandong University, Jinan 250012, China*
[3]*Department of Medical Imaging, Affiliated Hospital of Shandong University of Traditional Chinese Medicine, Jinan 250011, China*
[4]*Department of Critical Care Medicine Ward 3, Shandong Provincial Hospital Affiliated to Shandong First Medical University, Jinan 250021, China*
[5]*Department of Radiology, Changle People's Hospital, Changle 262400, China.*
[6]*Department of Gastroenterology, Shandong Provincial Hospital Affiliated to Shandong First Medical University, Jinan 250021, China*
[7]*Department of Neurosurgery, Shandong Provincial Hospital Affiliated to Shandong First Medical University, Jinan 250021, China*
[8]*Department of Radiology, The First Affiliated Hospital of Shandong First Medical University & Shandong Provicial Qianfoshan Hospital, Jinan 250014, China*

► ***Original article***

***Corresponding author:**
Qingshi Zeng, M.D., Ph.D.,
E-mail:
qingshizeng@outlook.com

Received: June 2020
Final revised: June 2021
Accepted: June 2021

Int. J. Radiat. Res., January 2022; 20(1): 67-73

DOI: 10.52547/ijrr.20.1.11

#W. Jiang, B. Liu and Y. Liu contributed equally to this study.

Keywords: *Trigeminal neuralgia, Magnetic resonance, Neurovascular compression, Facial pain, Microvascular decompression.*

ABSTRACT

Background: To explore the efficacy and optimal modality of three-dimensional (3D) MRI sequences in the preoperative detection of neurovascular compressions (NVCs) in patients with trigeminal neuralgia (TN). ***Materials and Methods***: Forty-nine cases of typical unilateral TN had undergone 3D time-of-flight magnetic resonance angiography (3D-TOF MRA), 3D fast imaging employing steady-state acquisition (3D-FIESTA), and contrast-enhanced 3D spoiled gradient-recalled sequence (3D-SPGR) on a 3 Tesla MR scanner. Neurovascular relationships (including neurovascular contact and position and the nature of the offending vessels) on MR images were reviewed by a neuroradiologist who was unaware of the clinical findings. Subsequently, microvascular decompression (MVD) surgery was performed on all patients. Comparison was made between the imaging results and surgical findings. ***Results***: MVD verified NVC in 48 (98%) symptomatic nerves, while 3D-TOF MRA, 3D-FIESTA, and 3D-SPGR revealed NVC in 38 (78%), 48 (98%), and 47 (96%) cases, respectively. Agreement between the position of NVC, as defined by 3D-FIESTA (κ = 0.86) or 3D-SPGR (κ = 0.83) and surgical findings, was excellent. Moreover, excellent agreement was confirmed between the nature of compressing vessels as defined by 3D-FIESTA in combination with 3D-TOF MRA (κ = 0.95) or contrast-enhanced 3D-SPGR in combination with 3D-TOF MRA (κ = 0.92) and surgical findings. ***Conclusions***: NVCs were visualized with good sensitivity and specificity with 3D MRI sequences in TN. We propose that 3D-FIESTA combined with 3D-TOF MRA is a safe, convenient, and efficacious MRI sequence for revealing NVCs and is crucial for the preoperative diagnosis and surgical planning of MVD.

INTRODUCTION

Trigeminal neuralgia (TN) is characterized by recurrent unilateral lancinating pain comprising one or more innervation territories of the trigeminal nerve branches, and the estimated annual incidence is approximately 4.5 cases per 100,000 [(1)]. Neurovascular compression (NVC) at the trigeminal nerve root is a major cause of TN, accounting for 80%-90% of total cases [(2)]. Based on this theory, microvascular decompression (MVD) has been identified as the standard surgical procedure for drug-resistant TN [(3)]. Thus, preoperative identification of neurovascular relations in the posterior fossa is critical for the diagnosis and preoperative planning of MVD [(4)].

It is rather difficult to visualize the small neurovascular structures in the posterior fossa with

[Downloaded from ijrr.com on 2025-08-23]
[DOI: 10.52547/ijrr.20.1.11]

conventional computed tomography (CT) and two-dimensional MRI [5]. High-resolution three-dimensional (3D) MRI techniques could provide improved resolution and differentiation to better delineate the complex posterior fossa anatomy. Nowadays, a variety of 3D MRI sequences have been widely used in patients with TN, including 3D time-of-flight angiography (3D-TOF MRA), 3D fast imaging employing steady-state acquisition (3D-FIESTA), and contrast-enhanced 3D spoiled gradient-recalled sequence (3D-SPGR) [6-10]. In our hospital, these MRI sequences have been used as routine methods to reveal NVC, and we have also reported some effective outcomes for the assessment of patients with TN [11-14]. In addition, contrast-enhanced FIESTA has been reported to delineate the interface between brain tumours and surrounding structures, and contrast-enhanced FIESTA is also effective for the preoperative evaluation of skull-base tumours and pituitary adenomas [15-17].

This investigation was designed to explore the diagnostic value of 3D-TOF MRA, 3D-FIESTA, and enhanced 3D-SPGR in the evaluation of NVC in the same cohort of patients with TN and to identify the best combination of these MRI sequences, emphasizing the importance of convenience and reliability for clinical use. This is the first study comparing these 3 sequences simultaneously within the same cohort of patients with TN.

MATERIALS AND METHODS

Patients

This study consisted of 49 patients (21 male and 28 female, age range 30–77 years, mean age 53.1 years) with unilateral (left side involved, n = 17; right side involved, n = 32) TN who met the diagnostic criteria for typical TN [18]. All patients had no history of MVD and were medically intractable. After MRI examinations, all patients subsequently underwent MVD. The present study was performed with the general consent of all patients and was approved by the Ethics Committee of Qilu Hospital of Shandong University (Registration number: KYLL-013-028, Date of registration: February 21, 2013).

The MR imaging protocol

All patients were assessed using conventional MR scanning with a 3T scanner (Signa; GE Medical Systems, Milwaukee, WI) by using an 8-channel quadrature head coil to rule out tumoral or other diseases.

The parameters for 3D-TOF MRA sequence were: relaxation time (TR), 22 ms; echo time (TE), 3.2 ms; flip angle, 15°; field of view (FOV), 240 mm ×240 mm; matrix, 256×512; one acquisition; and thickness, 1.2 mm. The parameters for 3D-FIESTA sequence were: TR, 6.1 ms; TE, 1.5 ms; flip angle, 60°; FOV, 240 mm ×240 mm; matrix, 512×512; two acquisitions; and thickness, 1.2 mm. The parameters for 3D-SPGR sequence were: TR, 8.6 ms; TE, 3.4 ms; flip angle, 12°; FOV, 240 mm ×240 mm; matrix, 512×512; one acquisition; and thickness, 1.2 mm.

MR imaging analysis

The neurovascular relation was independently assessed by an experienced neuroradiologist who was unaware of the clinical findings.

The nature (artery or vein) and the site of the offending vessels (interior, lateral, superior or inferior) relative to the nerve were assessed. The nature of the offending vessel (artery or vein) was distinguished as described previously [14].

Surgical results

All patients underwent MVD via a suboccipital retromastoid approach as described previously [3, 14]. The nature and relative site of the offending vessels were recorded by the neurosurgeon based on surgical findings.

Statistical analysis

Statistical analyses were performed by SPSS version 21.0 (SPSS, Chicago, IL). Ssensitivity, specificity, false-positive rate and false-negative rate of 3 MR imaging were calculated by using MVD results as the reference standard. The κ statistic was preformed to test the agreement between MR imaging and surgical results.

RESULTS

Identification of NVC using 3D-TOF MRA, 3D-FIESTA or enhanced 3D-SPGR sequences

MVD verified NVC in 48 of 49 (98%) patients with TN. The 3D-TOF MRA, 3D-FIESTA, and 3D-SPGR revealed NVC in 38 (38/49, 78%), 48 (48/49, 98%), and 47 (47/49, 96%) patients, respectively. Representative images are shown in figures 1, 2 and Figure 3.

The 3D-TOF MRA combined with 3D-FIESTA images detected NVC in 48 of 49 cases (sensitivity, 100%; specificity, 100%, false-positive rate, 0; false-negative rate, 0), while 3D-TOF MRA combined with contrast-enhanced 3D-SPGR techniques detected NVC in 47 of 49 patients (sensitivity, 97.9%; specificity, 100%; false-positive rate, 0; false-negative rate, 2.1%). No significant difference was found between the combinations of 3D-TOF MRA with 3D-FIESTA and enhanced 3D-SPGR (Fisher's exact test, P = 1.00), and the consistency of detection rates among the three was good (κ = 0.66).

[Downloaded from ijrr.com on 2025-08-23]

[DOI: 10.52547/ijrr.20.1.11]

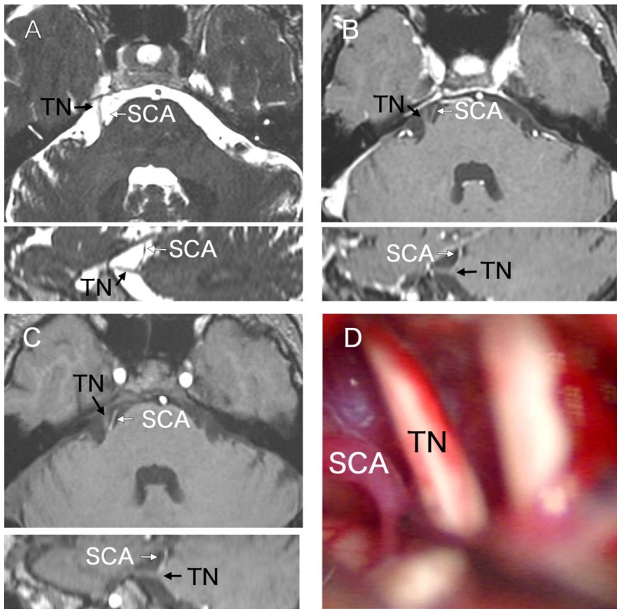

Figure 1. Transverse planar (upper images in A, B and C) and sagittal reformatted MRI images (lower images in A, B, and C) and intraoperative images **(D)** in a patient with left trigeminal neuralgia with trigeminal nerve (TN) compression purely by the superior cerebellar artery (SCA). **A:** FIESTA sequences; **(B)** enhanced 3D-SPGR sequences; and **(C)** TOF MRA sequences.

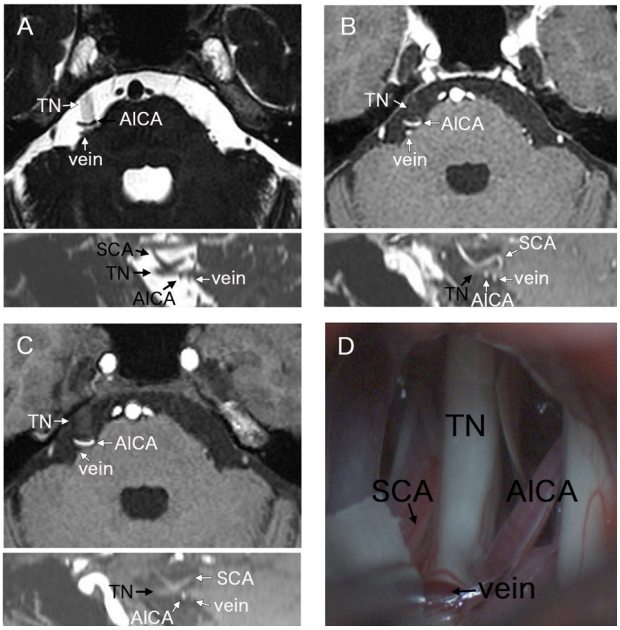

Figure 3. Transverse planar (upper images in A, B and C) and sagittal reformatted MRI images (lower images in A, B, and C) and intraoperative images **(D)** in a patient with right trigeminal neuralgia with trigeminal nerve (TN) compression by the anterior inferior cerebellar artery (AICA) and a vein. The superior cerebellar artery (SCA) could also be visualized. **(A)** FIESTA sequences; **(B)** enhanced 3D-SPGR sequences; **(C)** TOF MRA sequences.

Identification of the site of offending vessels relative to the symptomatic nerve

As table 1 shows, in 48 cases with NVC, MVD and 3D MRI confirmed that most offending vessels were situated at the superior, medial and lateral aspect of

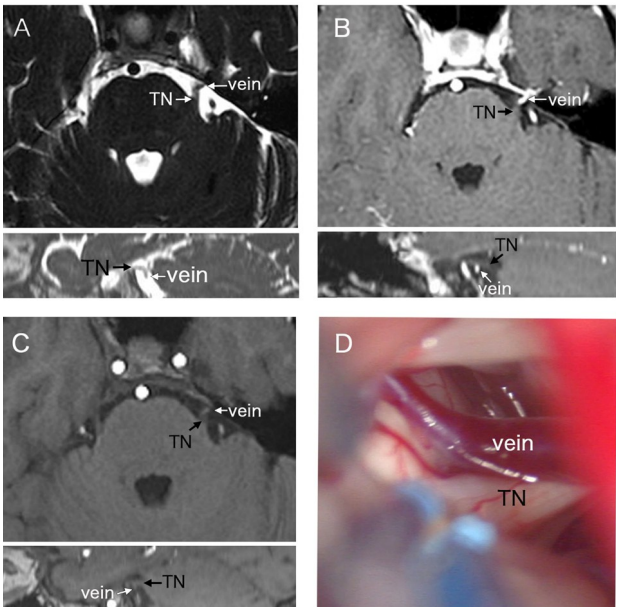

Figure 2. Transverse planar (upper images in A, B and C) and sagittal reformatted MRI images (lower images in A, B, and C) and intraoperative images **(D)** in a patient with left trigeminal neuralgia with trigeminal nerve (TN) compression purely by a vein. **(A)** FIESTA sequences; **(B)** enhanced 3D-SPGR sequences; and **(C)** TOF MRA sequences.

the nerve. In addition, the findings of 3D-TOF MRA in combination with 3D-FIESTA agreed excellently with the findings at surgery (κ = 0.86). Similarly, the findings of 3D-TOF MRA in combination with contrast -enhanced 3D-SPGR also agreed excellently with the surgical findings (κ = 0.83). No difference was identified between the combinations of 3D-TOF MRA with 3D-FIESTA and enhanced 3D-SPGR techniques ($P > 0.05$).

Table 1. Demographics of patients with unilateral trigeminal neuralgia.

Sex	Age	Patients number	Neuralgia	Position of the compressing vessel	Nature of the compressing vessel
Female	51.9 ±12.9	28	Right (60.7%)	Lateral (50%)	Artery (71.4%)
			Left (39.3%)	Medial(46.4%)	Vein (21.4%)
				Superior (3.6%)	Artery and vein (7.1%)
Male	54.9 ±12.0	21	Right (71.4%)	Lateral (33.3%)	Artery (76.2%)
			Left (28.6%)	Medial (42.9%)	Vein (14.3%)
				Superior (4.8%)	Artery and vein (4.8%)
				Inferior (14.3%)	Normal (4.8%)
				Normal (4.8%)	

Definition of the nature of offending vessels (arteries or veins)

MVD identified the nature of compressing vessels as follows: 2 (4%) cases were identified as an artery and a vein; 37 (77%) cases were identified as an

[Downloaded from ijrr.com on 2025-08-23]
[DOI: 10.52547/ijrr.20.1.11]

artery; and 9 (19%) cases were identified as a vein. In the same cases, offending vessels verified by 3D-FIESTA in combination with 3D-TOF MRA were the vein and artery, 3 (6%); artery, 36 (75%); and vein, 9 (19%). The 3D-FIESTA images in combination with 3D-TOF MRA images agreed excellently with the surgical findings (κ = 0.95). By contrast-enhanced 3D -SPGR in combination with 3D-TOF MRA, 47 patients in whom contact with a symptomatic nerve was visualized. Among these, 2 (4%) vessels were identified as a vein and an artery; 37 (79%) vessels were defined as an artery; and 8 (17%) vessels were defined as a vein. The findings of contrast-enhanced 3D-SPGR combined with 3D-TOF MRA images agreed well with the surgical findings (κ = 0.94). No difference was found between the combinations of 3D-TOF MRA with 3D-FIESTA and 3D-SPGR.

DISCUSSION

TN is a chronic pain disorder affecting the trigeminal nerve. It has been proposed that TN is a consequence of the compression of the trigeminal nerve by a contacting artery or vein, leading to nerve fibre demyelization [2]. Accordingly, MVD is the preferred treatment for refractory classic TN [19]. However, MVD is effective only if offending vessels exist [20]. In addition, increasing evidence has shown that outcome after MVD is better when the compressing vessel is an artery rather than a vein [21]. In addition to MVD, alternative treatment options, including percutaneous radiofrequency thermocoagulation and stereotactic radiosurgery, are available for the treatment of medically intractable TN. Therefore, accurate determination of the compression of the symptomatic trigeminal nerve by offending vessels, as well as the nature of offending vessels preoperatively, provides valuable information for preoperative planning for MVD and avoids unnecessary surgery.

The travelling of the trigeminal nerve is quite complicated, including nerves, blood vessels, and cerebrospinal fluid (CSF) of the cerebellopontine angle; thus, conventional imaging methods, such as angiography and CT, have difficulty clearly evaluating the cerebellopontine angle anatomy. At present, several MRI sequences, including TOF MRA, FIESTA, and enhanced SPGR, have been widely used to explore the relationship between the trigeminal nerve and offending vessels in patients with TN [4, 12, 22]. Moreover, compared with conventional two-dimensional MR sequences, high-resolution 3D sequences display the cranial nerve, vasculature and other surrounding structures in greater detail [7, 8], and it is also helpful to construct 3D images before surgery [20].

These MRI sequences are also useful for preoperative simulations of brain tumours, especially for posterior fossa tumours. Mikami *et al.* reported that FIESTA depicted the surrounding cranial nerves clearly in posterior fossa tumours such as meningiomas, schwannomas and epidermoid tumours [23]. Xie *et al.* also reported that 3D-FIESTA is a useful tool for surgical planning in the detection of small structures, including cranial nerves and vessels, in the sellar area in an endoscopic expanded endonasal approach [24]. In addition, contrast-enhanced FIESTA can identify the difference in the peritumoural brain parenchyma, which helps in the differential diagnosis of metastatic brain tumours and glioblastomas [25]. Moreover, contrast-enhanced 3D-TOF can depict peritumoural lenticulostriate arteries (LSAs) in insular gliomas but is poor in outlining the vessel-tumour interface. However, the combination with analogous constructive interference in steady-state (CISS) sequences can be helpful to overcome this limitation to depict the LSA-tumour interface without regard to tumour intensity [26].

However, there is a lack of studies exploring the optimistic sequence combination for the detection of NVC of the trigeminal nerve. Thus, we conducted a comparative study of the diagnostic value of 3 major MRI sequences, 3D-TOF MRA, 3D-FIESTA, and contrast-enhanced 3D-SPGR, in NVC in the same cohort of patients with TN.

Three-dimensional TOF MRA applies fast spoiled GRE T1WI sequence acquisition for clearly visualizing the vasculature and surrounding structures. Sens *et al*. described that 7D-TOF MRA performed on a 1T system delineated compressing vessels in 5 patients with TN [27]. The results of the present study showed that 3D-TOF MRA revealed 79% (38/48) of NVCs, which was in line with previous reports. Meany et al. reported that NVC was found on 3D-TOF MRA in 70% of 40 patients [28]. Additionally, Voros *et al.* found that even 3D-TOF MRA examined by a 0.5T system appears to be similarly effective as examinations by higher field strength systems in the identification of NVC [6]. Similar to previous reports, some causative arteries and veins were unable to be visualized by 3D-TOF MRA [6, 22, 28, 29]. This result could be explained by the fact that 3D-TOF MRA yields a relatively low signal-to-noise ratio, and the contrast between CSF and nerves or vessels is sometimes not satisfactory [13, 22]. In addition, for some blood vessels with small diameters and tortuous shapes, the signal is not of high intensity but instead medium intensity, which makes it difficult to isolate from nerves. More importantly, it is impossible to visualize veins in 3D-TOF MRA images [13, 22]. Thus, 3D-TOF MRA alone in the visualization of compressing vessels is not reliable enough for clinical use.

The 3D-FIESTA sequence is a version of fully focused steady-state sequences with a shorter TR [30, 31]. It can provide excellent contrast between CSF and other structures, such as nerves and vessels; thus, the trigeminal nerve is clearly displayed with

[Downloaded from ijrr.com on 2025-08-23]
[DOI: 10.52547/ijrr.20.1.11]

high-contrast CSF. The 3D-FIESTA sequence has been frequently applied to detect the neurovascular relationship in NVC syndromes such as facial spasms, glossopharyngeal neuralgia and TN [6, 9, 10]. In the present study, 3D-FIESTA precisely depicted 100% of responsible vessels that were subsequently confirmed in surgery, showing a better accuracy rate than 3D-TOF MRA (χ^2 = 9.50, P = 0.002). In a previous study, 3D-FIESTA was found to predict NVC in 71.4% of 7 patients [9]. In another study, 3D-CISS, a counterpart sequence of 3D-FIESTA, accurately predicted all responsible vessels (12 arteries and 3 veins) in 15 patients, while 3D-TOF MRA missed 3 veins [22].

Enhanced 3D-SPGR also provides fine spatial resolution and outstanding contrast between neurovascular structures and CSF [4, 12]. The current study found that enhanced 3D-SPGR, similar to 3D-FIESTA, also detected more offending vessels than 3D-TOF MRA (χ^2 = 7.18, P = 0.007). In our previous study with different cohorts of patients, SPGR had a sensitivity of 97.2% and a PPV of 100%, which are similar to other previous studies [13, 29]. Additionally, 3D-SPGR could provide an additional advantage in identifying the nature of vascular structure. In a recent report, 90% of responsible veins could be detected by SPGR [32]. However, this technique requires the contrast agent administration prior to the examination, which increases medical costs and has potential medical risks, such as anaphylaxis.

Additionally, we evaluated the nature of offending vessels. For patients with TN, accurate identification of the nature of offending vessels is important since various studies have shown that compression purely by a vein indicates an increased risk of pain recurrence postoperatively [2, 29]. In the current study, the majority of the compressing vessels were arterial in 39 (81%) patients. All of the responsible arteries were SCA and AICA. These results were consistent with previous reports that arteries, especially the SCA and AICA, are the most common vascular offenders [33, 34]. The results of the nature of the offending vessels, as revealed by the combination of 3D-TOF MRA with either 3D-FIESTA (κ =0.95) or enhanced 3D-SPGR (κ =0.94), showed excellent agreement with the finding in surgery. The 3D-TOF MRA sequence provides high signal intensity of arteries; however, it is impossible to visualize veins [35]. In contrast, 3D-FIESTA and enhanced 3D-SPGR have good spatial resolution and present excellent contrast between neurovascular structures and CSF within the cistern. Moreover, the veins could be detected in 3D-FIESTA and enhanced 3D-SPGR with high signal intensity, however, it is still challenging to distinguish veins from arteries. With the combination of 3D-TOF MRA with 3D-FIESTA or enhanced 3D-SPGR techniques, each complements the limitations of the other, and veins could be clearly identified.

However, the interpretation of MRI images demands subtle judgement and detailed anatomical knowledge. The existence of image artifacts could also lead to different results. Inoue et al. reported that only 65% of small veins were visualized by FIESTA, whereas SPGR imaging detected more than 90% of veins [32]. In contrast, our study identified all responsible veins with 3D-FIESTA, but one vein was undetected by 3D-SPGR. In hemifacial spasms, another clinical syndrome caused by NVC in the cerebellopontine angle, differing interpretations between a neurosurgeon and 2 neuroradiologists were reported [36]. The neurosurgeon's interpretation had a sensitivity of 79% and a PPV of 100%. The two neuroradiologists' interpretations had sensitivities of 21% and 59% and PPVs of 100% and 100%, respectively. These conflicting results indicate that more reports from multicentre studies with larger case numbers are needed.

In the present study, 3D-TOF MRA in combination with either 3D-FIESTA or contrast-enhanced 3D-SPGR can accurately identify the nature of offending vessels, and both combinations have excellent agreement with the findings of MVD. However, the 3D-FIESTA method does not require the administration of MR contrast agents. This use of this method will not only eliminate the potential adverse effects of contrast agents but also shorten the scan time and reduce medical expenses. Nevertheless, this method requires subtle judgement and detailed anatomical knowledge from experienced experts. In addition, 3D-FIESTA has ultrashort TR and TE, allowing for a quick acquisition, and outstanding images can be conveniently reformatted in any plane [37, 38]. Taking all these aspects into consideration, the 3D-FIESTA sequence in combination with the 3D-TOF MRA sequence is an effective and practical MRI examination for TN patients with NVC.

CONCLUSION

The 3D-TOF MRA in combination with either 3D-FIESTA or enhanced 3D-SPGR can provide excellent information on neurovascular relationships in patients with TN. As a non-invasive method, 3D-FIESTA combined with 3D-TOF MRA is safe, convenient and efficacious in the prediction of NVC in patients with TN.

ACKNOWLEDGEMENT

We would like to thank the patients who contributed to this research. The authors declare that there are no conflicts of interest.

Ethical considerations: The present study was performed with the general consent of all patients and was approved by the Ethic Committee of Qilu

[Downloaded from ijrr.com on 2025-08-23]

[DOI: 10.52547/ijrr.20.1.11]

Hospital of Shandong University (Registration number: KYLL-013-028.

Funding: This work was supported by the "National Natural Science Foundation of China" (grant number 81902531) and "Key Research and Development of Shandong Province" (grant number 2015GGH318009).

Conflicts of interest: *None declared.*

Authors' Contributions: (W.J): Methodology, Investigation, Writing - Original Draft; (B.L): Formal analysis, Investigation, Data creation, Writing - Original Draft, Writing, Review & Editing, Visualization, Funding acquisition; (Y.L): Methodology, Investigation, Validation, Writing -Original Draft; (J.W): Investigation, Validation, Resources, Data creation; (Q.D): Formal analysis, Data creation, Writing - Review & Editing; (H.J): Writing - Review & Editing, Funding acquisition; (Y.C): Resources, Investigation; (Y.W): Resources, Investigation; (Q.P): Resources, Investigation; (Q.Z): Conceptualization, Supervision, Project administration, Writing - Original Draft, Writing - Review & finalizing manuscript.

REFERENCES

1. Hall GC, Carroll D, Parry D, McQuay HJ (2006) Epidemiology and treatment of neuropathic pain: the UK primary care perspective. *Pain*, ***122****(1-2): 156-162*.
2. Jannetta PJ (1980) Neurovascular compression in cranial nerve and systemic disease. *Ann Surg*, 192(4):518-525.
3. Barker FG, Jannetta PJ, Bissonette DJ, Larkins MV, Jho HD (1996) The long-term outcome of microvascular decompression for trigeminal neuralgia. *N Engl J Med*, ***334****(17): 1077-1083*.
4. Hastreiter P, Naraghi R, Tomandl B, Bonk A, Fahlbusch R (2003) Analysis and 3-dimensional visualization of neurovascular compression syndromes. *Acad Radiol*, ***10****(12): 1369-1379*.
5. Feinstein MG, Fiekers J, Fraser C (1976) An analysis of the mechanism of local anesthetic inhibition of platelet aggregation and secretion. *J Pharmacol Exp Ther*, ***197****(1): 215-228*.
6. Voros E, Palko A, Horvath K, Barzo P, Kardos L, Kuncz A (2001) Three-dimensional time-of-flight MR angiography in trigeminal neuralgia on a 0.5-T system. *Eur Radiol*, ***11****(4): 642-647*.
7. Akimoto H, Nagaoka T, Nariai T, Takada Y, Ohno K, Yoshino N (2002) Preoperative evaluation of neurovascular compression in patients with trigeminal neuralgia by use of three-dimensional reconstruction from two types of high-resolution magnetic resonance imaging. *Neurosurgery*, ***51****(4): 956-961; discussion 961-952*.
8. Kakizawa Y, Hongo K, Takasawa H, Miyairi Y, Sato A, Tanaka Y, *et al.* (2003) "Real" three-dimensional constructive interference in steady-state imaging to discern microneurosurgical anatomy. Technical note. *J Neurosurg*, ***98****(3): 625-630*.
9. Benes L, Shiratori K, Gurschi M, Sure U, Tirakotai W, Krischek B, *et al.* (2005) Is preoperative high-resolution magnetic resonance imaging accurate in predicting neurovascular compression in patients with trigeminal neuralgia? A single-blind study. *Neurosurg Rev*, ***28****(2): 131-136*.
10. Satoh T, Onoda K, Date I (2007) Preoperative simulation for microvascular decompression in patients with idiopathic trigeminal neuralgia: visualization with three-dimensional magnetic resonance cisternogram and angiogram fusion imaging. *Neurosurgery*, ***60****(1): 104-113*.
11. Chun-Cheng Q, Qing-Shi Z, Ji-Qing Z, Zhi-Gang W (2009) A single-blinded pilot study assessing neurovascular contact by using high-resolution MR imaging in patients with trigeminal neuralgia. *Eur J Radiol*, ***69****(3): 459-463*.
12. Ni S, Su W, Li X, Zeng Q, Liu Y, Zhu S, *et al.* (2009) Enhanced three-dimensional fast spoiled gradient recalled MRI combined with magnetic resonance angiography for preoperative assessment of patients with trigeminal neuralgia. *J Clin Neurosci*, ***16****(12): 1555-1559*.
13. Zhou Q, Liu Z, Li C, Qu C, Ni S, Zeng Q (2011) Preoperative evaluation of neurovascular relationship by using contrast-enhanced and unenhanced 3D time-of-flight MR angiography in patients with trigeminal neuralgia. *Acta Radiol*, ***52****(8): 894-898*.
14. Zeng Q, Zhou Q, Liu Z, Li C, Ni S, Xue F (2013) Preoperative detection of the neurovascular relationship in trigeminal neuralgia using three-dimensional fast imaging employing steady-state acquisition (FIESTA) and magnetic resonance angiography (MRA). *J Clin Neurosci*, ***20****(1): 107-111*.
15. Yamamoto J, Kakeda S, Takahashi M, Aoyama Y, Soejima Y, Saito T, *et al.* (2011) Dural attachment of intracranial meningiomas: evaluation with contrast-enhanced three-dimensional fast imaging with steady-state acquisition (FIESTA) at 3 T. *Neuroradiology*, ***53****(6): 413-423*.
16. Watanabe K, Kakeda S, Yamamoto J, Watanabe R, Nishimura J, Ohnari N, *et al.* (2012) Delineation of optic nerves and chiasm in close proximity to large suprasellar tumors with contrast-enhanced FIESTA MR imaging. *Radiology*, ***264****(3): 852-858*.
17. Yamamoto J, Kakeda S, Shimajiri S, Takahashi M, Watanabe K, Kai Y, et al. (2014) Tumor consistency of pituitary macroadenomas: predictive analysis on the basis of imaging features with contrast-enhanced 3D FIESTA at 3T. *AJNR Am J Neuroradiol*, ***35****(2): 297-303*.
18. Scrivani SJ, Mathews ES, Maciewicz RJ (2005) Trigeminal neuralgia. *Oral Surg Oral Med Oral Pathol Oral Radiol Endod*, ***100****(5): 527-538*.
19. Burchiel KJ (2003) A new classification for facial pain. *Neurosurgery*, ***53****(5): 1164-1166; discussion 1166-1167*.
20. Hitotsumatsu T, Matsushima T, Inoue T (2003) Microvascular decompression for treatment of trigeminal neuralgia, hemifacial spasm, and glossopharyngeal neuralgia: three surgical approach variations: technical note. *Neurosurgery*, ***53****(6):1436-1441; discussion 1442-1433*.
21. Boecher-Schwarz HG, Bruehl K, Kessel G, Guenthner M, Perneczky A, Stoeter P (1998) Sensitivity and specificity of MRA in the diagnosis of neurovascular compression in patients with trigeminal neuralgia. A correlation of MRA and surgical findings. *Neuroradiology*, ***40****(2): 88-95*.
22. Yoshino N, Akimoto H, Yamada I, Nagaoka T, Tetsumura A, Kurabayashi T, *et al.* (2003) Trigeminal neuralgia: evaluation of neuralgic manifestation and site of neurovascular compression with 3D CISS MR imaging and MR angiography. *Radiology*, ***228****(2): 539-545*.
23. Mikami T, Minamida Y, Yamaki T, Koyanagi I, Nonaka T, Houkin K (2005) Cranial nerve assessment in posterior fossa tumors with fast imaging employing steady-state acquisition (FIESTA). *Neurosurg Rev*, ***28****(4): 261-266*.
24. Xie T, Zhang XB, Yun H, Hu F, Yu Y, Gu Y (2011) 3D-FIESTA MR images are useful in the evaluation of the endoscopic expanded endonasal approach for midline skull-base lesions. *Acta Neurochir (Wien)*, ***153****(1): 12-18*.
25. Yamamoto J, Kakeda S, Shimajiri S, Nakano Y, Saito T, Ide S, *et al.* (2018) Evaluation of Peritumoral Brain Parenchyma Using Contrast-Enhanced 3D Fast Imaging Employing Steady-State Acquisition at 3T for Differentiating Metastatic Brain Tumors and Glioblastomas. *World Neurosurg*, ***120****: e719-e729*.
26. Rao AS, Thakar S, Sai Kiran NA, Aryan S, Mohan D, Hegde AS (2018) Analogous Three-Dimensional constructive interference in steady state sequences enhance the utility of three-dimensional time of flight magnetic resonance angiography in delineating lenticulostriate arteries in insular gliomas: Evidence from a prospective clinico-radiologic analysis of 48 patients. *World Neurosurg*, ***109****: e426-e433*.
27. Sens MA and Higer HP (1991) MRI of trigeminal neuralgia: initial clinical results in patients with vascular compression of the trigeminal nerve. *Neurosurg Rev*, ***14****(1): 69-73*.
28. Meaney JF, Eldridge PR, Dunn LT, Nixon TE, Whitehouse GH, Miles JB (1995) Demonstration of neurovascular compression in trigeminal neuralgia with magnetic resonance imaging. Comparison with surgical findings in 52 consecutive operative cases. *J Neurosurg*, ***83****(5): 799-805*.
29. Anderson VC, Berryhill PC, Sandquist MA, Ciaverella DP, Nesbit GM, Burchiel KJ (2006) High-resolution three-dimensional magnetic resonance angiography and three-dimensional spoiled gradient-recalled imaging in the evaluation of neurovascular compression in patients with trigeminal neuralgia: a double-blind pilot study. *Neurosurgery*, ***58****(4): 666-673*.

[Downloaded from ijrr.com on 2025-08-23]

[DOI: 10.52547/ijrr.20.1.11]

30. Lane JI, Ward H, Witte RJ, Bernstein MA, Driscoll CL (2004) 3-T imaging of the cochlear nerve and labyrinth in cochlear-implant candidates: 3D fast recovery fast spin-echo versus 3D constructive interference in the steady state techniques. *AJNR Am J Neuroradiol*, ***25****(4): 618-622*.
31. Chavhan GB, Babyn PS, Jankharia BG, Cheng HL, Shroff MM (2008) Steady-state MR imaging sequences: physics, classification, and clinical applications. *Radiographics*, ***28****(4): 1147-1160*.
32. Inoue T, Hirai H, Shima A, Suzuki F, Fukushima T, Matsuda M (2017) Diagnosis and management for trigeminal neuralgia caused solely by venous compression. *Acta Neurochir (Wien)*, ***159****(4): 681-688*.
33. Lorenzoni J, David P, Levivier M (2012) Patterns of neurovascular compression in patients with classic trigeminal neuralgia: A high-resolution MRI-based study. *Eur J Radiol*, ***81****(8): 1851-1857*.
34. Gamaleldin OA, Donia MM, Elsebaie NA, Abdelkhalek Abdelrazek A, Rayan T, Khalifa MH (2020) Role of fused three-dimensional time-of-flight magnetic resonance angiography and 3-dimensional T2-weighted imaging sequences in neurovascular compression. *World Neurosurg*, ***133****: e180-e186*.
35. Chang JW, Chang JH, Park YG, Chung SS (2000) Microvascular decompression in trigeminal neuralgia: a correlation of three-dimensional time-of-flight magnetic resonance angiography and surgical findings. *Stereotact Funct Neurosurg*, ***74****(3-4): 167-174*.
36. Raslan AM, DeJesus R, Berk C, Zacest A, Anderson JC, Burchiel KJ (2009) Sensitivity of high-resolution three-dimensional magnetic resonance angiography and three-dimensional spoiled-gradient recalled imaging in the prediction of neurovascular compression in patients with hemifacial spasm. *J Neurosurg*, ***111****(4): 733-736*.
37. Amemiya S, Aoki S, Ohtomo K (2009) Cranial nerve assessment in cavernous sinus tumors with contrast-enhanced 3D fast-imaging employing steady-state acquisition MR imaging. *Neuroradiology*, ***51****(7): 467-470*.
38. Prieto R, Pascual JM, Yus M, Jorquera M (2012) Trigeminal neuralgia: Assessment of neurovascular decompression by 3D fast imaging employing steady-state acquisition and 3D time of flight multiple overlapping thin slab acquisition magnetic resonance imaging. *Surg Neurol Int*, **3**: 50.

[Downloaded from ijrr.com on 2025-08-23]

[DOI: 10.52547/ijrr.20.1.11]

[Downloaded from ijrr.com on 2025-08-23]

[DOI: 10.52547/ijrr.20.1.11]