

Radioprotective effect of hesperidin against ovarian toxicity induced by Ionizing radiation through inhibiting oxidative stress in mice

S. Hosseinpour¹, A.E. Nejad Moghaddam^{1*}, F. Talebpour Amiri^{1*}
S.J. Hosseinimehr², M. Zargari³, A. Karimpour Malekshah¹, A. Ghasemi⁴

¹Department of Anatomy, Faculty of Medicine, Molecular and Cell Biology Research Center, Mazandaran University of Medical Sciences, Sari, Iran

²Department of Radiopharmacy, Faculty of Pharmacy, Mazandaran University of Medical Sciences, Sari, Iran

³Department of Clinical Biochemistry, Molecular and Cell Biology Research Center, Faculty of Medicine, Mazandaran University of Medical Sciences, Sari, Iran

⁴Department of Radiology, Faculty of Medicine, Mazandaran University of Medical Sciences, Sari, Iran

► Original article

ABSTRACT

*Corresponding authors:

A.E. Nejad Moghaddam, Ph.D.,

E-mail: mog1339@gmail.com

Fereshteh T. Amiri, Ph.D.,

E-mail: Ftaleb2001@yahoo.co.uk

Received: December 2020

Final revised: May 2021

Accepted: June 2021

Int. J. Radiat. Res., April 2022;
20(2): 417-423

DOI: 10.52547/ijrr.20.2.24

Background: Radiotherapy enhances the risk of ovarian injury induced by oxidative stress in the female patients. Hesperidin, as a natural compound has various biological properties included anti-tumoral, antioxidant, and anti-inflammatory activities. This research evaluated the effects of hesperidin on ovarian damage induced by IR.

Materials and Methods: Twenty-eight female mice distributed to four groups randomly: Control, Hesperidin (100mg/kg), ionizing radiated (IR) (3.2 Gy), and ionizing radiated + hesperidin groups (3.2Gy + 100mg/kg). Hesperidin was administrated orally for 7 successive days. Animals were exposed to total body irradiation on the 8th day of study. Biochemical, hormonal (estrogen and progesterone), and histopathological assessments did on day 12. **Results:** IR group demonstrated necrosis, apoptosis, and atresia in ovaries, decreased estrogen and progesterone and increased oxidative stress. While Hesperidin pre-treatment improved histological features, recovered the number of follicles in ovaries of the irradiated mice. In addition, the Hesperidin increased estrogen and progesterone and decreased oxidative stress (malondialdehyde, Ferric Reducing Antioxidant Power, and catalase). **Conclusion:** Data of this research indicate that hesperidin is may be useful in female patients with pelvic cancer during radiotherapy for their ovarian conservation.

Keywords: Hesperidin, irradiation, ovary, toxicity, oxidative stress.

INTRODUCTION

Ionizing radiation (IR) and chemotherapy are the most ordinary treatments for malignancy that and more than half of these persons need radiation therapy during their treatment ^(1, 2). Although radiotherapy is a favored treatment for cancer patients, it has many side effects on healthy tissues around the cancer area, including the lung, liver, bone, and heart and reproductive organs (testis and ovary) ⁽³⁾. The ovaries are very vulnerable and very sensitive to irradiation, which can affect a patient's life. Precocious menopause and sterility are their symptoms. Radiotherapy by inducing oxidative stress, inhibits the growth of cancerous masses ⁽⁴⁾. Therefore, non-target tissues are also exposed to this damage. Furthermore, it seems that germ cells are far more vulnerable than the somatic cells. The increase of oxidative stress in granulosa cells of the ovary have a harmful effect on oocyte fertility, fetus quality, and implantation amount ^(5, 6). Radiotherapy results in

ovarian atrophy, oocyte destruction accompanied by a decrease in follicle stock, which subsequently leads to menstrual disarray, ovarian failure, and sterility ⁽⁷⁾. It was reported that even 2 Gy IR evacuates half of the oocytes in the ovary, and IR doses of 10 to 20 Gy in children and 4 to 6 Gy in adolescents can cause constant suspension of ovarian function ⁽⁸⁾. In order to further inhibit tumor growth by increasing the IR dose, normal tissues nearby tumor should be preserved against IR-induced damage. Today, the study on more effective radioprotectors was increased due to frequent usage of IR for the treatment of patients with pelvic tumors. IR causes ovarian damage by producing reactive oxygen species ⁽⁹⁾. Naturally existing antioxidants, for instance, polyphenols and various extracts of curative herbs and plans, have a protective role against the harmful effects of IR because of their potential in free radical scavenging and antioxidant activity ⁽¹⁰⁾. Studies have also shown that fruits and vegetables, as a huge source of polyphenols, can reduce the risk of cancers

of the breast, lung, pancreas, colon, larynx, mouth and prostate ⁽¹¹⁾. Flavonoids are a beneficial class of polyphenols that play an active role in inhibiting oxidative stress, inflammation, and tumor growth as well as free radical scavenging activity ⁽¹²⁾.

Hesperidin (HES) as a natural compound belongs to the flavonoid family ⁽¹³⁾. It is a significant flavonoid source that is found in the skin and inner membranes of citrus fruits, vegetables, plant-based foods, tea and olive oil ⁽¹⁴⁾. The antioxidant, anti-inflammatory, and radical scavenging properties of HES is extensively documented ^(13, 15, 16). Regarding biological activity of HES, the potential of anti-tumorigenesis is highly emphasized in various cancers ⁽¹⁷⁻¹⁹⁾. In addition, it was considered as inexpensive and safe for women during pregnancy ⁽²⁰⁾. Some studies have reported protective effects of HES on cerebral ⁽²¹⁾ cardiac ⁽²²⁾ and intestinal injury ⁽²³⁾. The protective effect of hesperidin on ovarian toxicity has been observed in one study ⁽²⁴⁾, but we have not seen the radioprotective effect of hesperidin on ovarian injury as far as we have examined.

Based on the above, it is hypothesized that HES can reduce the damage to ovarian tissue caused by radiotherapy. The current study was designed to examine the protective effect of HES on ovarian damage induced by IR with biochemical, hormonal and histopathological assessments in mice.

MATERIALS AND METHODS

Animals

Female BALB/c mice (pubertal, 6 to 8 weeks old, 30±5 gr) were obtained from Mazandaran University Animal Care. The mice were kept under standard situation of room temperature, humidity and light/dark cycle (26 ± 1 °C, 50 ± 10%, and 12/12-h) in usual cages and had free access to food and water. The research was authorized by the Institutional Animal Ethical Committee of Mazandaran University of Medical Sciences. (ID: 2152).

Experimental design

Twenty-eight adult female mice were distributed randomly into four groups (7/group) as follows:

The control: normal saline was applied for 7 days.

HES: Mice was recieved HESorally for 7 days with dose of 100 mg/kg/day.

IR: Mice was exposed a single dose of irradiation with 3.2 Gy total body on day 8th.

IR + HES: HES (100 mg/kg/day) was administrated for 7 days by gavage and IR was exposed whole-body on day 8th (3.2 Gy).

The doses of HES ⁽²⁵⁾ and IR ⁽²⁶⁾ were selected according to previous studies.

HES administration and total body X- ray irradiation

HES (Sigma, USA) was freshly prepared in phosphate buffer saline (PBS; Sigma, USA) and orally was administrated for seven consecutive days. On the 8th day of study, for whole-body irradiation, animals were fixed in a supine situation in particular Plexiglas cages, which were designed and constructed according to mice's physical measurements, and exposed to whole-body IR. The IR procedure was performed at Imam Hospital, Sari, Iran with a 6 MV X-ray beam generated by a Linear accelerator (Siemens, Primus, Germany) at a dose rate of 1.9 Gy/min.

Specimen collection

Four days after the IR exposure (on day 12), the mice were anesthetized with xylazine and ketamine (5 and 50 mg/kg). Blood sample was taken from the heart. Part of the blood was transferred to the heparin syringe to separate the plasma and part of the blood, after clot formation and centrifugation (3000 rpm, 15 min). Serum was separated and stored at -70 °C for biochemical and hormonal evaluations. Immediately, the ovaries were removed and separated from the adipose tissue, and processed for histopathological assessment.

Biochemical analysis

Malondialdehyde (MDA) was evaluated as an indicator of lipid peroxidation by measuring the amount of thiobarbituric acid (TBA) reactants, according to Ohkawa *et al.* ⁽²⁷⁾. The content of MDA in plasma samples was reacted with TBA at 95°C and incubated for 25 minutes. After centrifugation (4°C, 15 min), the concentration of the supernatant was determined by a spectrophotometer at 532 nm wavelength.

In order to determine antioxidant activity, the FRAP (ferric reducing antioxidant power) assay was performed according to Benzie and Strain ⁽²⁸⁾. The measurement criterion was the amount of ferric (Fe³⁺) conversion to Fe²⁺ form, which was absorbed in 593 nm. In this reaction, Fe³⁺ was complexed to a TPTZ reagent and then converted to the Fe²⁺-TPTZ complex. The FRAP level was calculated in (μM / l) by plotting the absorption standard curve on the concentration of iron (II) standard solution.

Catalase activity available in erythrocyte hemolysate was measured based on the Aebi method ⁽²⁹⁾. Catalase enzyme activity in decomposition of H₂O₂ and O₂ was shown at 240 nm. The reaction mixture to measure the activity of the catalase enzyme included 50 mM potassium phosphate buffer, 10 mM H₂O₂, and an appropriate amount of hemolysate.

Hemoglobin (Hb) was estimated by the

auto-analyzer through a commercial kit.

Progesterone and estrogen analysis

Following the manufacturer's protocol, the ELISA kits (EAST BIOPHARM, Hangzhou, China/ Torrance, USA) were used to appraise of serum Progesterone and Estrogen. The intra- and inter- assay coefficient of variations were less than 10% and 12%, respectively and the absorbance was measured at 450 nm for both. The results were expressed in ng/ml according to the established standard curve.

Histopathology assay

The ovaries for light microscope (Nikon 200, Japan) analysis were fixed in 10% (W/V) formalin solution for two nights. Afterwards, samples were processed in the alcohol series, clarified in xylene and embedded in paraffin. Consecutive sections of blocks with 5 μ m thickness were stained with Hematoxylin and Eosin (H&E staining). Series sections were prepared with Interval 5 from the entire surface of the ovary, were investigated, and follicles containing oocyte nuclei were counted in a blinded method. The follicles were counted according to the Devine *et al* method ⁽³⁰⁾.

Statistical evaluation

Statistical evaluation were executed by SPSS software (ver. 18.0 USA). Variables are expressed as the mean \pm SD and statistical differences were demonstrated using one-way analysis of variance (ANOVA) and with Tukey's post-test, P values < 0.05.

RESULTS

Effect of HES on oxidative stress markers in irradiated mice

Throughout the experiment before euthanasia, no animal was lost owing to HES administration and IR exposure, and there was no significant difference in terms of body weight between the groups.

IR exposure elevated the MDA level of the serum in the mice, while FRAP and catalase reduced, specifically in the status of enzymic oxidant (catalase) as shown in figure 1.

Pre-treatment of HES caused significant protection against oxidative stress induced by IR and preserved the level of FRAP close to the control group and even rise slightly in the HES alone group.

The antioxidant effect of HES was more pronounced when administered without IR, and showed higher cultivars in all evaluations except MDA. It is worthy to mention that the IR group figures demonstrated significant difference with other ones in all biochemical parameters. ($p < 0.05$).

Effect of HES on female sexual hormone amounts in irradiated mice

The serum estrogen level in the irradiated mice showed a significant reduction (46%) compared with the control group (28.04 ± 2.8 versus 51.38 ± 9.5). As showed in figure 2, the serum estrogen level was 26% lower in IR exposed mice compared with HES supplemented animals (28.04 ± 2.8 versus 37.68 ± 3.17). Besides, in HES only group a marked rise of 18% was found in estrogen concentration versus the control group (62.6 ± 1.18 vs 51.38 ± 9.5).

The same status was seen with the progesterone in irradiation alone group versus the control one; an intensive reduction of which was about 48% (39.79 ± 5.25 vs 20.98 ± 7.1) (figure 2).

Although pre-administration of HES brought progesterone level close to the basal, marked differences were not observed between control and HES groups. Concurrently, HES administration elevated the progesterone status by 43% in the pretreated mice compared to the irradiated female mice (20.98 ± 7.1 vs 36.49 ± 3.06).

Effect of HES on ovarian histopathological changes in irradiated mice

Figure 4 shows the histopathological features of ovarian tissue in all groups. The control and HES groups demonstrated normal ovarian histomorphological features, which were characterized by normal appearance of cortex including different types of growing follicles in all stages, normal granulosa cell layers, oocytes, and corpus luteum, that associated with detectable medulla in ovaries (figure 3. A & B). Not only histological alterations were not seen in ovarian gland of HES treated mice, but also these sections also represented more developed follicles compared to the control group. Furthermore, the highest crowd among non-radiation treated follicles belonged to the primordial follicles (table 1).

On the contrary, in IR exposure mice were specified follicles with shrunken and vacuolated oocytes (figure 3. C Blue arrow), extrusion of the ooplasmic contents, degenerated nucleus, malformed zona pellucida, round cells, apoptotic bodies and hemorrhage. The granulosa layer was loosened (figure 3. C white arrow), containing blood and vacuolated cells, as well as, degenerated cumulus oophorus cells (figure 3. C Thick black arrow), which have lost their integrity with pycnotic and fragmented nucleus found in granulosa cells as well. There were hypertrophy and dissociation between layers and immersion of clear cells in theca. Most of the follicles in IR exposure mice were atretic at the primary stage concluding abnormal expansions in the middle part, increased height of granulosa compared to HES + IR group and was rarely seen in primordial

follicles in IR group (table 1). In the microscopic examination germinal epithelium integrity was intact in the control group, whereas ovaries receiving X-rays, showed loss of germinal epithelium cohesion (detachments). In contrast to the IR group, a few cases of preantral follicles observed that were in the early phases of atresia and primordial follicles with a normal appearance were detected in the HES + IR group, and primary follicles had an almost normal size and shape compared to IR.

Pre-treatment with HES revealed normal cortex and medulla structure at most developmental stages from primordial to antral follicles, while in irradiated mice follicles appeared as dominant stock compared to the HES pretreated mice. The number of follicles in all groups is given in table 1. There was a statistically considerable difference in follicle counts between the groups in all stages including primordial and primary, between the IR and HES + IR groups ($p < 0.05$).

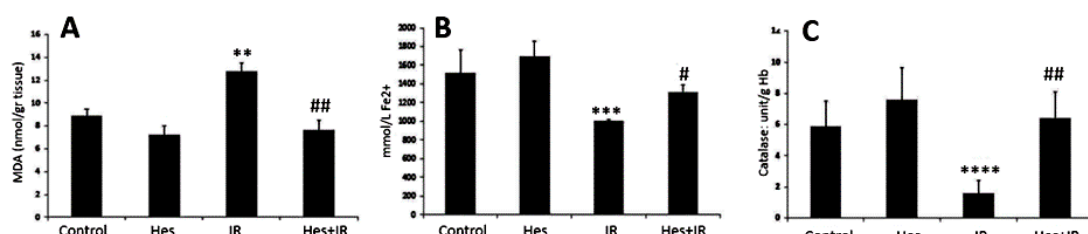


Figure 1. Levels of Malondialdehyde (MDA) (A), ferric reducing antioxidant power (FRAP) (B) and catalase (C) in the experimental groups of animals. The values are expressed as mean \pm SD and statistically difference at $P < 0.05$. MDA: nM MDA/g tissue; FRAP: mM/L Fe2+; Catalase: unit/g Hb; Group I: control, Group II: HES (hesperidin), Group III: IR (ionizing radiation), Group IV: HES+IR (ionizing radiation+ hesperidin). * significant vs control and # significant vs IR. **, ($p < 0.01$); ***, ($p < 0.001$); ****, ($p < 0.0001$); #, ($p < 0.05$); ##, ($p < 0.01$).

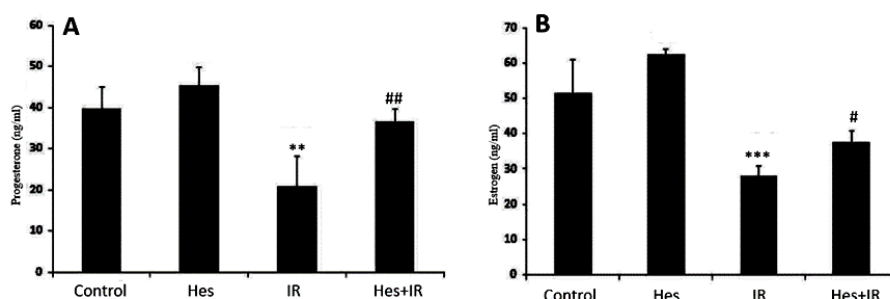


Figure 2. The level of progesterone (A) and estrogen (B) in blood serum of experimental groups of animal. The values are expressed as mean \pm SD and statistically difference at $P < 0.05$. Group I: control, Group II: HES (hesperidin), Group III: IR (ionizing radiation), Group IV: Hes+IR (ionizing radiation+ hesperidin). * Significant vs control and # significant vs IR. **, ($p < 0.01$); ***, ($p < 0.001$); #, ($p < 0.05$); ##, ($p < 0.01$).

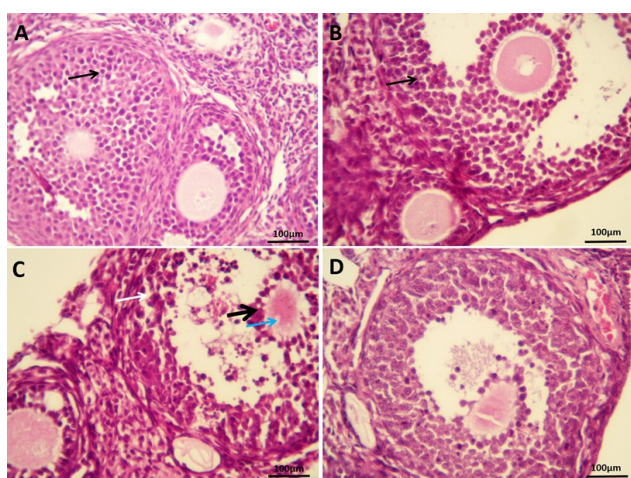


Figure 3. Photomicrographs of ovary sections show effect of HES and IR on ovarian histoarchitecture. A) Control group with normal follicles, normal granulosa cell layers (thin black arrow), and oocytes. B) As the same as control group, normal follicular structure can be observed in HES (hesperidin) group. C) IR group showed loosened granulosa (white arrow), vacuolization in oocytes (blue arrow) and degenerated cumulus oophorus cells (thick black arrow). D) Improved morphology show in the HES + IR (hesperidin + ionizing radiation) group. H&E staining. ($\times 400$ magnification), scale bar = 100 μ m.

Table 1. Follicle counts in mice treated with hesperidin and ionizing radiation.

Groups	Control	HES	IR	HES + IR
Primordial	3.57 \pm 0.97	16.57 \pm 2.37	0.43 \pm 0.53**	2.71 \pm 0.75#
Primary	7.71 \pm 1.11	7.57 \pm 2.14	2 \pm 1.41* **	7.29 \pm 2.28
Pre antral	8.71 \pm 2.4	5.57 \pm 1.13	3.43 \pm 1.27**	9.43 \pm 4.31
Antral	14.86 \pm 2.11	12.71 \pm 2.36	6.29 \pm 1.6** *	14 \pm 3.51
Atretic	4.43 \pm 1.13	1.57 \pm 0.53	9.57 \pm 2.14**	4.43 \pm 1.51

Data expressed as Mean \pm SD (n = 7). * Significant vs control and # significant vs IR. HES (hesperidin), IR (ionizing radiation) and HES+ IR (hesperidin + ionizing radiation).

, ($p < 0.01$); *, ($p < 0.001$); #, ($p < 0.05$)

DISCUSSION

The ovary is a tissue that is very sensitive to radiation after IR exposure, and this ovarian damage can continue for a long time after radiotherapy. In this study, IR induced ovarian injury, reduced estrogen and progesterone, increased oxidative stress. It was observed that HES pre-treatment can recover sexual hormone levels and declined MDA level, ameliorated the total antioxidant capacity (FRAP) in the plasma and antioxidant enzyme (catalase) in the serum and improved morphological features in ovary.

X-rays and accelerated electron beams currently used for radiotherapy⁽³¹⁾, either directly through reactive oxygen species release the apoptotic pathway or indirectly by creating oxidative stress⁽³²⁾. Studies have shown that IR with induction of follicular apoptosis accelerates atresia⁽³³⁾. In the present study, histomorphologic features of irradiated ovaries included condensed pycnotic and fragmented nucleus cells, and the appearance of apoptotic bodies, which are the prevalent features of apoptosis manifestation. These findings were consistent with the study of others⁽³⁴⁾. Our results showed that primordial follicles preserved in the IR+HES group, while they were almost evacuated in the IR group that manifested the consistency of sensitivity in primordial follicles with other groups. The granulosa cells are the essences of follicular development, as they frequently release local factors, which regulate the growth of ovarian follicles and sacrifice themselves prior to follicles during the apoptosis process⁽³⁵⁾. Hence, apoptosis of granulosa cell triggers follicular atresia⁽³⁶⁾, which was negatively affected by IR in present study that is in agreement with prior studies⁽²⁶⁾. The apoptosis and disruption of granulosa cells observed in irradiated follicles, which illustrates progressed atretic phase; however, the HES pretreated expressed the symptoms of early stages of atresia in a few cases. In detail, necrosis as a mode of cell death causes changes in the ovarian histoarchitecture containing round cells, ruptured cell membrane, and plasma leakage⁽³⁷⁾. Comparatively, the preserved follicular morphology and less apoptotic feature in follicles of HES + IR group suggest that HES protected necrosis and apoptosis in the ovarian follicles, theca and granulosa cells. The cortex thickness and total volume of cortex eliminated in the irradiated group, which could be due to apoptosis and atresia in follicles.

Natural antioxidants like flavonoids protect against radiation-related damages because of their scavenging free radicals potential. HES, a flavanone glycoside as a medication is recently focused because of its antioxidant⁽¹⁵⁾, anti-inflammatory⁽¹⁶⁾, and anti-tumoral effects⁽³⁸⁾. Lately, it is announced that HES has ovarian beneficial effect and improved the

ovulation in I/R and CP models⁽³⁹⁾. ROS is the main product of IR, which causes lipid peroxidation and leads to cell membrane damage. Evaluation of malondialdehyde (MDA) as a by-product in serum and tissues can be determined as an indicator of membrane lipid damage⁽⁴⁰⁾. In the previous study reported pre-treatment with HES orally attenuate on genotoxicity of lymphocytes and bone marrow cells induced by IR^(41, 42). Hesperidin has already been shown that protect testicular toxicity induced by IR⁽⁴³⁾. They showed HES pre-treatment with a dose of 200 mg/kg for 7 successive days protects against testicular damage caused by radiation. Hepatoprotective effect of hesperidin has been shown by researchers by reducing oxidative stress⁽²⁵⁾. Khedr *et al.* showed the protective effect of HES in pregnant models and infertility induced by oxidative stress⁽²⁴⁾. In this study, was shown that HES by reducing oxidative stress also positively affected ovarian damage induced by IR.

Antioxidant enzymes, such as catalase, play an important role in the defense of cells exposed to IR. Catalase converts hydrogen peroxide to water. In catalase deficiency, the accumulation of hydrogen peroxide causes necrosis⁽³⁷⁾ and cell membrane damage. Consequently, increase of MDA and H2O2 content leads to reduction in catalase level and necrosis induction, which confirms the data of the current research. Besides, hydrogen peroxide-induced necrosis requires iron reactions⁽³⁷⁾, which is related to devaluation in FRAP scale. The total antioxidant capacity of plasma was measured using the analysis called FRAP⁽⁴⁴⁾, which has progressed in HES+IR group compared to the IR alone group.

Furthermore, theca cells generate androgens, which is a substrate for estrogenic hormones synthesized by granulosa⁽⁴⁵⁾. Estrogen, the essential anti-atherogenic female sex hormone that develops and regulates the reproductive system, granulosa cells, and folliculogenesis, comprised three major endogenous estrogens such as estradiol. Estradiol prohibits granulosa and other reproductive cells from antioxidant stress-induced apoptosis⁽⁴⁶⁾. Previous studies stated that IR down-regulates estradiol in the blood serum and stimulates follicle apoptosis⁽⁴⁷⁾; whereas the flavonoids modulated estrogen rate in human⁽⁴⁸⁾. The preantral and antral follicles are significantly dependent on steroidogenesis⁽⁴⁹⁾. Meanwhile, the normal function of the uterus, luteal cell, and follicular development depend on the ovarian progesterone⁽⁹⁾ that would be suppressed by X-radiation⁽⁵⁰⁾ through enhancing ROS level, impairing antioxidant enzymes activity⁽⁵¹⁾ and stimulating the luteal regression. Moreover, a more dramatic increase in progesterone level than other hormone might be due to the similarity of its chemical structure to the polycyclic chemical structure of hesperidin. The results revealed that HES pretreatment was able to stabilize the progesterone

and estrogen level close to the control group probably owing to its antioxidant feature, which made a concession with other studies ⁽⁵²⁾. The present study is the first to evaluate the protective effect of HES on radiotherapy-induced ovarian lesions. Although in this study the protective effect of HES on ovarian damage caused by IR was presented, but evaluation of molecular mechanisms of HES in different doses is necessary.

CONCLUSION

Generally, it is concluded that HES gives remarkable defense to mice ovary in confronting with the destruction of X-irradiation. Data suggests that HES with anti-oxidant property controlled oxidative stress parameters, female sex hormones, and histological structure the ovarian toxicity-induced IR.

ACKNOWLEDGMENT

Not applicable.

Conflict of interest: Declared none.

Ethical approval: The research was authorized by the Institutional Animal Ethical Committee of Mazandaran University of Medical Sciences. (ID: 2152).

Funding: This study was funded by a research grant (ID: MA-ZUMS.REC.1396.2152) from Mazandaran University of Medical Sciences, Sari, Iran.

Authors' contributions: All authors contributed in all parts of research conceptualization, experimentation, data analysis and manuscript preparation.

REFERENCES

1. Miller RW, L Young Jr J, Novakovic B (1995) Childhood cancer. *Cancer*, **75**(S1): 395-405.
2. Delaney G, Jacob S, Featherstone C, Barton M (2005) The role of radiotherapy in cancer treatment: estimating optimal utilization from a review of evidence-based clinical guidelines. *Cancer: Interdisciplinary. Int J of the American Cancer Society*, **104**(6): 1129-37.
3. Oeffinger KC, Mertens AC, Sklar CA, Kawashima T, Hudson MM, Meadows AT (2006) Chronic health conditions in adult survivors of childhood cancer. *New England Journal of Medicine*, **355**(15): 1572-82.
4. Abdel-Messeih PL, Nosseir NM, Bakhe OH (2017) Evaluation of inflammatory cytokines and oxidative stress markers in prostate cancer patients undergoing curative radiotherapy. *Central-European Journal of Immunology*, **42**(1): 68.
5. Jančar N, Kopitar AN, Ihan A, Klun IV, Bokalič EV (2007) Effect of apoptosis and reactive oxygen species production in human granulosa cells on oocyte fertilization and blastocyst development. *Journal of Assisted Reproduction and Genetics*, **24**(2-3): 91-7.
6. Bedaiwy MA, Falcone T, Mohamed MS, Aleem AA, Sharma RK, Worley SE (2004) Differential growth of human embryos in vitro: role of reactive oxygen species. *Fertility and Sterility*, **82**(3): 593-600.
7. Sönmez M and Oktay K (2008) Assisted reproduction and fertility preservation techniques in cancer patients. *Current Opinion in Endocrinology. Diabetes and Obesity*, **15**(6): 514-22.
8. Chemaitilly W, Mertens AC, Mitby P, Whitton J, Stovall M, Yasui Y (2006) Acute ovarian failure in the childhood cancer survivor study. *The Journal of Clinical Endocrinology & Metabolism*, **91**(5): 1723-8.
9. Gao W, Liang J-X, Ma C, Dong J-y, Yan Q (2017) The protective effect of N-acetylcysteine on ionizing radiation induced ovarian failure and loss of ovarian reserve in female mouse. *BioMed Research International*, **2017**(8):1-11.
10. Gandhi NM and Nair CKK (2005) Radiation protection by Terminalia chebula: some mechanistic aspects. *Molecular and Cellular Biochemistry*, **277**(1-2):43-8.
11. Ross JA and Kasum CM (2002) Dietary flavonoids: bioavailability, metabolic effects, and safety. *Annual Review of Nutrition*. **22**(1): 19-34.
12. Birt DF, Hendrich S, Wang W (2001) Dietary agents in cancer prevention: flavonoids and isoflavonoids. *Pharmacology & Therapeutics*, **90**(2-3): 157-77.
13. Wilmsen PK, Spada DS, Salvador M (2005) Antioxidant activity of the flavonoid hesperidin in chemical and biological systems. *Journal of Agricultural and Food Chemistry*, **53**(12): 4757-61.
14. Garg A, Garg S, Zaneveld L, Singla A (2001) Chemistry and pharmacology of the citrus bioflavonoid hesperidin. *Phytotherapy Research*, **15**(8): 655-69.
15. Sun Y, Qiao L, Shen Y, Jiang P, Chen J, Ye X (2013) Phytochemical profile and antioxidant activity of physiological drop of citrus fruits. *Journal of Food Science*, **78**(1): C37-C42.
16. Coelho RCLA, Hermsdorff HHM, Bressan J (2013) Anti-inflammatory properties of orange juice: possible favorable molecular and metabolic effects. *Plant Foods for Human Nutrition*, **68**(1): 1-10.
17. Saiprasad G, Chitra P, Manikandan R, Sudhandiran G (2013) Hesperidin alleviates oxidative stress and downregulates the expressions of proliferative and inflammatory markers in azoxymethane-induced experimental colon carcinogenesis in mice. *Inflammation Research*, **62**(4): 425-40.
18. Kamaraj S, Ramakrishnan G, Anandakumar P, Jagan S, Devaki T (2009) Antioxidant and anticancer efficacy of hesperidin in benzo (a) pyrene induced lung carcinogenesis in mice. *Investigational New Drugs*, **27**(3): 214-22.
19. Lee K-H, Yeh M-H, Kao S-T, Hung C-M, Liu C-J, Huang Y-Y (2010) The inhibitory effect of hesperidin on tumor cell invasiveness occurs via suppression of activator protein 1 and nuclear factor-kappaB in human hepatocellular carcinoma cells. *Toxicology letters*, **194**(1-2): 42-9.
20. Buckshee K, Takkar D, Aggarwal N (1997) Micronized flavonoid therapy in internal hemorrhoids of pregnancy. *International Journal of Gynecology & Obstetrics*, **57**(2): 145-51.
21. Gaur V and Kumar A (2010) Hesperidin pre-treatment attenuates NO-mediated cerebral ischemic reperfusion injury and memory dysfunction. *Pharmacological Reports*, **62**(4): 635-48.
22. Selvaraj P and Pugalandi KV (2010) Hesperidin, a flavanone glycoside, on lipid peroxidation and antioxidant status in experimental myocardial ischemic rats. *Redox Report*, **15**(5): 217-23.
23. Pehlivan M, Hazinedaroglu S, Kayaoglu H, Erkek A, Keklik T, Canbolat O (2004) The effect of diosmin hesperidin on intestinal ischaemia—reperfusion injury. *Acta Chirurgica Belgica*, **104**(6): 715-8.
24. Khedr NF (2015) Protective effect of mirtazapine and hesperidin on cyclophosphamide-induced oxidative damage and infertility in rat ovaries. *Experimental Biology and Medicine*, **240**(12): 1682-9.
25. Pradeep K, Park SH, Ko KC (2008) Hesperidin a flavanoglycone protects against γ-irradiation induced hepatocellular damage and oxidative stress in Sprague–Dawley rats. *European Journal of Pharmacology*, **587**(1-3):273-80.
26. Said RS, Nada AS, El-Demerdash E (2012) Sodium selenite improves folliculogenesis in radiation-induced ovarian failure: a mechanistic approach. *PLoS one*, **7**(12): e50928.
27. Ohkawa H, Ohishi N, Yagi K (1979) Assay for lipid peroxides in animal tissues by thiobarbituric acid reaction. *Analytical Biochemistry*, **95**(2): 351-8.
28. Benzie IF and Strain JJ (1996) The ferric reducing ability of plasma (FRAP) as a measure of "antioxidant power": the FRAP assay. *Analytical Biochemistry*, **239**(1): 70-6.
29. Aebi H (1984) Catalase in-vitro. *Methods in Enzymology*, **105**:121-6.
30. Devine P, Payne C, McCuskey M, Hoyer P (2000) Ultrastructural evaluation of oocytes during atresia in rat ovarian follicles. *Biology of Reproduction*, **63**(5): 1245-52.

31. Lacombe S and Le Sech C (2009) Advances in radiation biology: Radiosensitization in DNA and living cells. *Surface Science*, **603**(10-12): 1953-60.
32. Ward JF (1988) DNA damage produced by ionizing radiation in mammalian cells: identities, mechanisms of formation, and reparability. Progress in nucleic acid research and molecular biology. *Elsevier*, **35**: 95-125.
33. Hendry JH and West CM (1997) Apoptosis and mitotic cell death: their relative contributions to normal-tissue and tumour radiation response. *International Journal of Radiation Biology*, **71**(6): 709-19.
34. Inoue N, Matsuda F, Goto Y, Manabe N (2011) Role of cell-death ligand-receptor system of granulosa cells in selective follicular atresia in porcine ovary. *Journal of Reproduction and Development*, **57**(2): 169-75.
35. Adashi EY (1992) The potential relevance of cytokines to ovarian physiology. *The Journal of Steroid Biochemistry and Molecular Biology*, **43**(5): 439-44.
36. Devine P, Payne C, McCuskey M, Hoyer PB (2000) Ultrastructural evaluation of oocytes during atresia in rat ovarian follicles. *Biology of Reproduction*, **63**(5): 1245-52.
37. Berghe TV, Vanlangenakker N, Parthoens E, Deckers W, Devos M, Festjens N (2010) Necroptosis, necrosis and secondary necrosis converge on similar cellular disintegration features. *Cell Death and Differentiation*, **17**(6):922.
38. Kohno H, Tanaka T, Kawabata K, Hirose Y, Sugie S, Tsuda H (2002) Silymarin, a naturally occurring polyphenolic antioxidant flavonoid, inhibits azoxymethane-induced colon carcinogenesis in male F344 rats. *International Journal of Cancer*, **101**(5): 461-8.
39. Gungor ANC, Gencer M, Karaca T, Hacivelioglu S, Uysal A, Korkmaz F (2014) The effect of hesperetin on ischemia–reperfusion injury in rat ovary. *Archives of Gynecology and Obstetrics*, **290**(4): 763-9.
40. Valko M, Izakovic M, Mazur M, Rhodes CJ, Telser J (2004) Role of oxygen radicals in DNA damage and cancer incidence. *Molecular and Cellular Biochemistry*, **266**(1-2): 37-56.
41. Hosseinimehr S and Nemati A (2006) Radioprotective effects of hesperidin against gamma irradiation in mouse bone marrow cells. *The British Journal of Radiology*, **79**(941): 415-8.
42. Hosseinimehr SJ, Mahmoudzadeh A, Ahmadi A, Mohamadifar S, Akhlaghpour S (2009) Radioprotective effects of hesperidin against genotoxicity induced by γ -irradiation in human lymphocytes. *Mutagenesis*, **24**(3):233-5.
43. Shaban NZ, Zahran AMA, El-Rashidy FH, Kodous ASA (2017) Protective role of hesperidin against γ -radiation-induced oxidative stress and apoptosis in rat testis. *Journal of Biological Research-Thessaloniki*, **24**(1): 5.
44. Zargari M, Allameh A, Sanati MH, Tiraihi T, Lavasani S, Emadyan O (2007) Relationship between the clinical scoring and demyelination in central nervous system with total antioxidant capacity of plasma during experimental autoimmune encephalomyelitis development in mice. *Neuroscience Letters*, **412**(1): 24-8.
45. Matsuda F, Inoue N, Manabe N, Ohkura S (2012) Follicular growth and atresia in mammalian ovaries: regulation by survival and death of granulosa cells. *Journal of Reproduction and Development*, **58**(1): 44-50.
46. Lund SA, Murdoch J, Van Kirk EA, Murdoch WJ (1999) Mitogenic and antioxidant mechanisms of estradiol action in preovulatory ovine follicles: relevance to luteal function. *Biology of Reproduction*, **61**(2): 388-92.
47. Mahran YF, El-Demerdash E, Nada AS, Ali AA, Abdel-Naim AB (2013) Insights into the protective mechanisms of tamoxifen in radiotherapy-induced ovarian follicular loss: impact on insulin-like growth factor 1. *Endocrinology*, **154**(10): 3888-99.
48. Jacobs MN and Lewis DF (2002) Steroid hormone receptors and dietary ligands: a selected review. *Proceedings of the Nutrition Society*, **61**(1): 105-22.
49. Mandl AM (1959) A quantitative study of the sensitivity of oocytes to X-irradiation. *Proceedings of the Royal Society of London Series B-Biological Sciences*, **150**(938): 53-71.
50. Hixon JE, Gengenbach DR, Hansel W (1975) Failure of prostaglandin F $_{2\alpha}$ to cause luteal regression in ewes after destruction of ovarian follicles by X-irradiation. *Biology of Reproduction*, **13**(2): 126-35.
51. Noda Y, Ota K, Shirasawa T, Shimizu T (2012) Copper/zinc superoxide dismutase insufficiency impairs progesterone secretion and fertility in female mice. *Biology of Reproduction*, **86**(1): 16, 1-8.
52. Yamashita K (1965) Effect of flavonoid compounds on progesterone in pregestational development. *Journal of Endocrinology*, **32**(2): 259-60.

