

Proximal-type epithelioid sarcoma of the groin: Clinical experience and literature review

X. Hu, C. Zhang, K. Qian, R. Yu, T. Mei, J. Cai*

Department of Nuclear Medicine, Affiliated Hospital of Zunyi Medical University, Zunyi, Guizhou, 563003, PR China

ABSTRACT

► Case report

***Corresponding author:**

Jiong Cai, Ph.D.,

E-mail: jiong_cai@163.com

Received: August 2021

Final revised: April 2022

Accepted: May 2022

Int. J. Radiat. Res., October 2022;
20(4): 887-892

DOI: 10.52547/ijrr.20.4.24

Keywords: Epithelioid sarcoma, groin, mesenchymal tumor, case report.

Background: Epithelioid sarcoma (ES) is a rare soft tissue tumor that mainly occurs under the skin of the extremities. ES in the groin area may be easily misdiagnosed with undifferentiated pleomorphic sarcoma, leiomyosarcoma, rhabdomyosarcoma, and other mesenchymal tumors. Herein, we reported a single case of a patient with proximal-type epithelioid sarcoma of the groin, including its clinical and imaging findings. We also discussed some previously reported similar cases. **Case Presentation:** Our ES patient was a 24-year-old male who developed a subcutaneous nodule in the groin area 1 year before admission. After careful clinical and pathological examination, the patient was diagnosed with ES. He received chemotherapy (doxorubicin, ifosfamide plus cisplatin) and, later on, surgery. His symptoms improved, and he is still being followed up. In addition, we conducted a review of the literature and compared our data with 12 previously reported similar cases (including 17 patients with ES involving the groin). **Conclusion:** ES is a highly invasive tumor prone to metastasis and postoperative recurrence. Surgery seems to be the most effective treatment for ES. The effectiveness of auxiliary and radiotherapy needs to be confirmed by a large amount of data. A systematic understanding of the clinical and imaging features of ES in the groin area may help clinical and imaging doctors to correctly diagnose the disease.

INTRODUCTION

Epithelioid sarcoma (ES) is a rare mesenchymal tumor of uncertain origin and slow growth, whose incidence accounts for about 1% of soft tissue tumors. ES shares similar morphology and immunohistochemistry with some epithelioid tumors and thus may be easily misdiagnosed. This may further lead to insufficient treatment and early death ⁽¹⁾.

The etiology and pathogenesis of ES are still unclear, and there is no definite genetic basis. However, some studies suggested that the occurrence of ES might be related to the loss of SMARCB1/INI1 protein expression ^(2,3). ES can occur in any part of the body at any age but is more prominent in young adult men ⁽¹⁾. The morphological characteristics of ES usually manifest as single, hard bean-like nodules under the skin ⁽⁴⁾.

Clinically, ES is classified into classic or distal and proximal types ⁽⁵⁾. The distal type is more common and mainly occurs under the skin of the distal hand. It is also foot-related to tendons or aponeurosis. The proximal type occurs in the head and neck, trunk, pelvis, groin, perineum, external genitalia, and other parts and often manifests as nodules or masses involving the subcutaneous or deep soft tissues; when the lesion is large, hemorrhage and necrotic cystic

change may also occur ⁽⁶⁾. The proximal-type ES can maintain a slow growth for a long time and can be easily mistaken for a benign lesion. Nonetheless, it is a highly malignant and aggressive tumor with poor therapeutic effect and susceptibility to recurrence and metastasis ⁽⁷⁾. Herein, we reported a single case of a patient with proximal-type epithelioid sarcoma of the groin, including its clinical and imaging findings. We also discussed some previous similar cases reports, which may be helpful in differentiating this type of malignancy from other tumors.

Case presentation

A 24-year-old male was admitted to our hospital with a left inguinal mass that appeared one year ago. The mass showed signs of significant enlargement and was accompanied by pain that lasted for the last two months. Physical examination revealed a hard mass closely attached to the skin in the corresponding area. The skin was still intact, and no ulceration was observed. Serum tumor markers showed a slight increase in neuron-specific enolase (NSE) value (28.280 ng/ml, reference value <16.3 ng/ml); the values of other tumor markers, such as alpha-fetoprotein and carcinoembryonic antigen, were within the normal reference range. Based on the above clinical manifestations, physical examination, and laboratory examination results, the presence of a

malignant tumor was suspected. Consequently, a part of the tumor tissue was collected for immunopathological examination. Under the microscope, tumor cells appeared pleomorphic and with nodular arrangements, most of which are epithelioma-like cells. Immunohistochemical results showed that cytokeratin (CK), epithelial membrane antigen (EMA), Vimentin, CgA, inhibitor bina, Melan-A, and S100 were positive; Ki-67 was about 40% positive, and Syn was weakly positive (representative pathological and immunohistochemical images are shown in figure 1); all reagents were purchased from Fuzhou MXB Biotechnology Co., Ltd., China. The histopathological diagnosis was ES. To further assess the extent of tumor invasion and stage and to determine the treatment plan, the patient underwent a whole-body fluorine 18 labeled deoxyglucose positron emission tomography/computed tomography (^{18}F -FDG PET/CT) examination (Biograph mCT; Siemens; Germany); ^{18}F -FDG PET/CT data are shown in figure 2. The results showed mass hypermetabolic regions in the coccyx and the left inguinal region. Moreover, bone destruction was seen in the coccyx. Considering that the patient developed distant metastases, he was treated with a chemotherapy regimen of doxorubicin, ifosfamide plus cisplatin. During chemotherapy, blood routine monitoring was conducted every two weeks. After receiving chemotherapy for eight months, the groin mass on the patient's left side was significantly reduced; thus, the doctor decided to surgically remove the mass.

Under general anesthesia, the patient underwent enlarged resection of the left inguinal mass, left inguinal lymph node dissection (postoperative pathology confirmed with lymph node invasion), and left anterolateral thigh pedicled flap transfer repair. After surgery (1 day later), symptoms were relieved, and the patient was able to walk slowly. After surgical removal of the lump in the left groin, the patient was followed up for 17 months. Currently, the patient is still regularly receiving chemotherapy. Recently, he complained about the bulging feeling in the anus, so another CT scan (16 slices Spiral CT, GE Corporation, USA) was performed. CT data showed no tumor recurrence in the surgical area of the left groin, while the soft tissue mass in the tailbone area was larger than before the operation, as shown in figure 3.

Literature search for similar cases

PubMed, Embase, and Cochrane Library databases were searched for reports on Inguinal ES cases and case series published before March 31, 2021; only English articles were searched. The following keywords were used: "groin OR inguinal OR inguinal" AND "epithelioides sarcoma". Through the gradual elimination of duplicate literature, reviews, irrelevant publications, and articles that did not describe patients' clinical data, 12 full texts (including 17

patients) were obtained; a detailed screening flowchart of the literature is shown in figure 4. The detailed information of the patient's age and gender, the largest diameter of the mass, the lateral position (left or right), imaging findings, distant metastasis location and recurrence time, treatment decision, and follow-up time are presented in table 1.

According to the results of our literature search, only 21 cases of ES involving the inguinal area have been reported so far (8-19). Tateishi *et al.* included 4 cases of inguinal ES; however, since they reported no detailed clinical data of the patients, their study was excluded (20). We finally included and analyzed the clinical features of 18 cases of inguinal ES (including our case). The age range of the patients at the time of diagnosis was 10 to 64 years, the median age was 37.5 years, and the average age was about 36.7 years. There was no significant difference in the occurrence of ES in the groin area in terms of location and gender (both accounted for 50% of each, and most of the patients (14/18) were Asians) (figure 5). ES in the inguinal area was prone to metastasis (10/16) and postoperative recurrence (9/16), where the most common was lymph node metastasis (8/10), followed by bone metastasis (3/10) and other metastatic locations including lung, and abdominal wall. Out of 18 patients, 15 were timely followed-up. Kaplan-Meier survival curves were used to assess patient survival, and the average survival time of ES patients in the groin area was 120 months. Gender, type of treatment (whether combined with radiotherapy and chemotherapy after surgery), and whether metastasis occurred at the time of diagnosis resulted as factors that did not affect the average survival rate (p values <0.05 , as shown in figure 6).

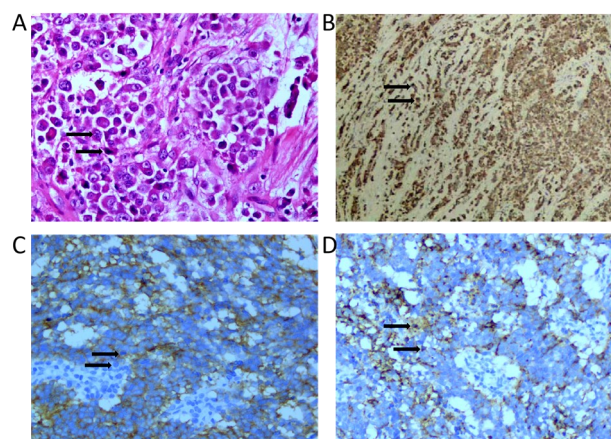


Figure 1. Histopathological and immunohistochemical tumor staining. (A) Hematoxylin and eosin-stained sections of the tumor, the tumor cells are arranged in nodular shape, mainly epithelioid cells, Magnification, $\times 200$; Immunohistochemical staining shows that the tumor cells were positive for CK (B, magnification, $\times 40$), EMA (C, magnification, $\times 200$) and vimentin (D, magnification, $\times 100$).

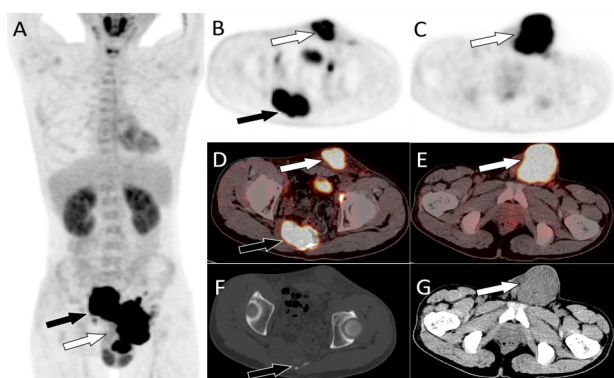


Figure 2. PET/CT examination of epithelioid sarcoma in the inguinal area. (A). The MIP (maximum intensity projection) figure showed a large mass of increased FDG uptake in the pelvic area, and SUVmax was 17.1 (arrows). On axial PET (B, C) and fusion images (D, E), activity enhancement was located in the coccygeal vertebra (black arrow) and left inguinal region (white arrow). Axial CT showed bone destruction in the coccygeal vertebra (F, black arrow) and soft tissue mass shadows in the left inguinal region (G, white arrow).

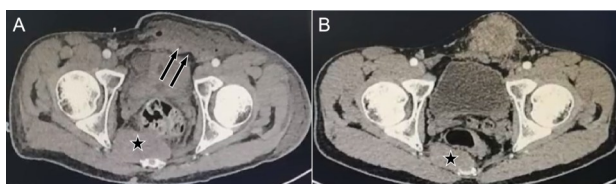


Figure 3. Postoperative CT examination (A) showed that there was no obvious tumor recurrence at the operation site of the left groin area (arrows), but the soft tissue mass in the coccyx area was larger than before operation (pentagram arrow, B is preoperative).

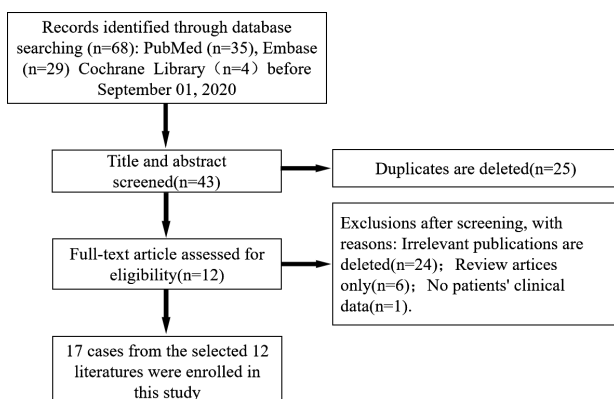


Figure 4. Flow chart of literature screening for epithelioid sarcoma in the inguinal area.

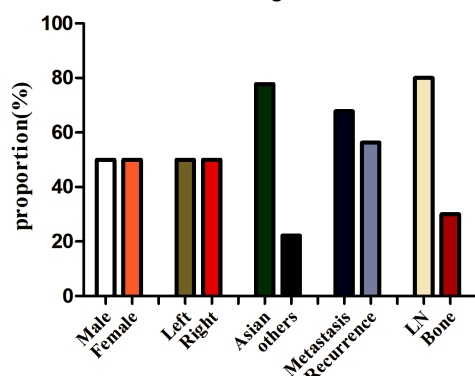


Figure 5. Clinical distribution and characteristics of epithelioid sarcoma in the inguinal area. The occurrence of epithelioid sarcoma in the inguinal area is not significantly different between men and women, and on the left and right sides, and the proportion of Asians is higher than that of other places. It is prone to metastasis and recurrence, and the metastatic sites are mainly lymph nodes, followed by bones.

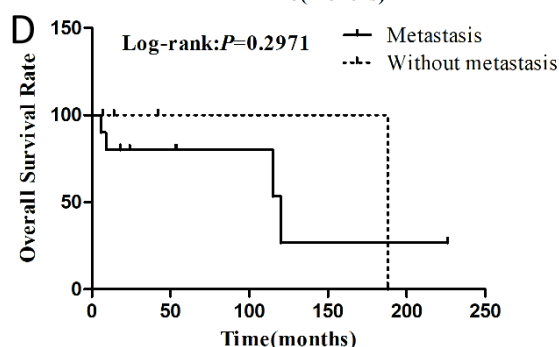
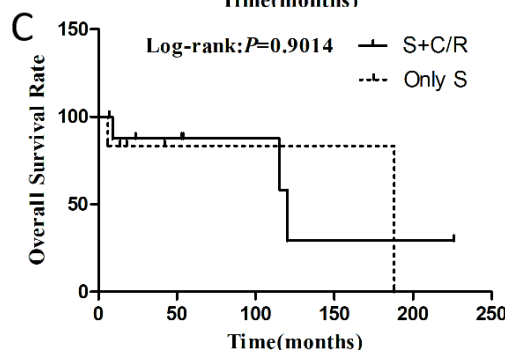
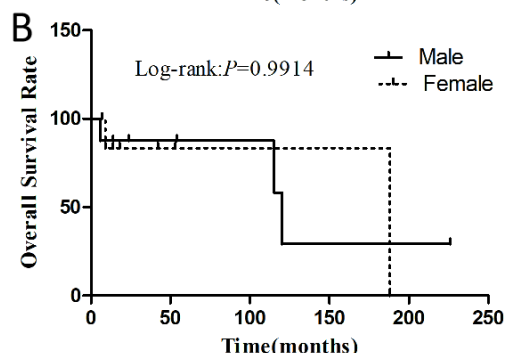
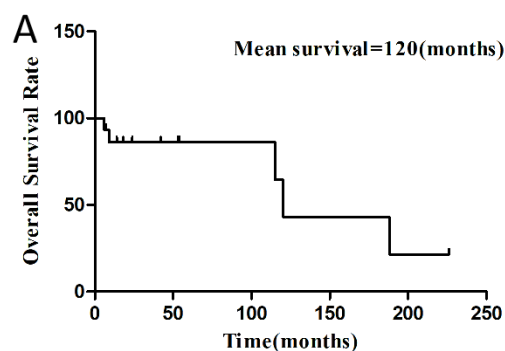


Figure 6. Kaplan-Meier overall survival (OS) rate of epithelioid sarcoma in the inguinal area. (A). OS in all cases (N=15, 3 patients with no recorded follow-up time were excluded from the analysis), the mean survival time of patients is 120 months; (B). OS by gender; (C). OS by treatment; and (D). OS by stage.

Table 1. The clinical features of epithelioid sarcoma in the inguinal area reported in the literature.

Study/ References	Year/Nation	Sex/ Age	MD (cm)/ Side	History	Imaging examination		Metastasis/ Recurrence	Treatment	Follow-up (months)
					Methods	Imaging findings			
Mahajan <i>et al.</i> ⁽⁸⁾	2016/India	M/20	-/L	Painless soft tissue mass	CT	Low-density soft tissue mass surrounding the iliac vessels	Iliac fossa LN	S+C	24(0)
Irimura <i>et al.</i> ⁽⁹⁾	2015/Japan	M/38	11/L	Left groin discomfort for 1 year	MR	T1WI is iso-signal, T2WI is uneven and high-signal, obviously enhanced	Lung	S+C	54(0)
Kim <i>et al.</i> ⁽¹⁰⁾	2012/Korea	F/40	2.4/L	Groin mass	PET/CT	Soft tissue mass with radioactive uptake	2 years recurrence	S	42(0)
Rekhi <i>et al.</i> ⁽¹¹⁾	2016/India	M/46	-	-	-	-	-	-	-
Fujiki <i>et al.</i> ⁽¹²⁾	2015/Japan	F/64	-/R	Painless soft tissue mass	-	-	None	S	14(0)
Dainichi <i>et al.</i> ⁽¹³⁾	2008/Japan	F/37	-/L	-	PET/CT	Soft tissue mass with radioactive uptake	-	-	-
Flucke <i>et al.</i> ⁽¹⁴⁾	2010/ Germany	F/25	4.0/-	-	-	-	1year recurrence	S	-
Rekhi <i>et al.</i> ⁽¹⁵⁾	2016/India	F/58	5.0/R	Groin mass	MRI and PET/CT	T1WI is iso-signal, T2WI is uneven and high-signal, obviously enhanced; high radioactivity uptake, SUVmax =25.13	Abdominal Wall;3 years recurrence	S+R	53(0)
		F/33	3.2/R	Groin mass 1month	-	-	None	S+R	7(0)
Khazeni <i>et al.</i> ⁽¹⁶⁾	2018/USA	F/33	3.6/R	Groin mass	CT	Soft tissue masses with uneven density	Inguinal LN	S+C+R	9(1)
Mannan <i>et al.</i> ⁽¹⁷⁾	2010/ Kuwait	M/47	14/R	Painless soft tissue swelling lasts for 1 year	CT/MRI	Low-density soft tissue mass; T1WI is iso-signal, T2WI is uneven and high-signal, obviously enhanced.	None	S	14(0)
Hasegawa <i>et al.</i> ⁽¹⁸⁾	2001/Japan	M/43	4/-	Groin mass	-	-	44months recurrence; LN ;Bone	S+C+R	120(1)
		M/47	3/-	Groin mass	-	-	2 months recurrence; LN	S	6(1)
		F/26	2.5/-	Groin mass	-	-	15months recurrence; LN	S	18(0)
		M/46	5.0/-	Groin mass	-	-	93 months recurrence; LN; Bone	S+C+R	226(0)
		F/23	4.0/-	Groin mass	-	-	144 months recurrence; LN	S	188(1)
Kodet <i>et al.</i> ⁽¹⁹⁾	1994/USA	M/10	-	-	-	-	23 months recurrence	S+C+R	115(1)
	Present case	M/24	12/L	Groin mass 1year	PET/CT:	Soft tissue masses with uneven density; high radioactivity uptake, SUVmax=17.1	Bone; Inguinal LN	S+C	25(0)

DISCUSSION

Primary tumors that occur in the groin area are relatively rare. We discovered that only 21 ES cases involving the groin area had been published so far (taking into consideration only English articles). Although ES in the groin area is uncommon, it is more aggressive than the classic ES that occurs in the distal extremities ⁽⁸⁾. Consistent with our data, the clinical history of most ES patients in the literature showed slow-growing painless nodules or masses in the groin. The masses can infiltrate the skin and form ulcers locally as the disease progresses. At present, the main causes leading to ES remain unclear. A

previous study suggested that skin damage, history of trauma, or scar tissue formation after skin damage are important factors related to ES ⁽²¹⁾. Our patient showed a left inguinal nodule on admission, which was also why he did not timely receive radical surgery.

Like proximal-type ES in other areas, the imaging features of ES in the inguinal area are usually not specific. ES in the inguinal area often appears as a slightly low-density soft tissue mass on CT; yet, the boundary is often unclear. Low-density cystic necrosis areas often appear when the mass is large, and calcifications are rarely seen. On magnetic resonance imaging (MRI), the masses often appear as

signals equal to the surrounding muscles on the T1 weighted imaging (T1WI) sequence and unevenly high signals on the T2 weighted imaging (T2WI) sequence. MRI is more accurate than CT in showing the extent of tumor invasion. The lesions appear as an uneven enhancement on both contrast-enhanced CT and MRI scans. Tateishi *et al.* believed that such imaging findings accompanied by lymph node invasion are helpful for the recognition of this disease (20).

PET/CT is also a reliable imaging method for positioning and qualitative diagnosis, which is of great value for detecting primary and metastatic lesions. It has an important role in tumor staging, determining a treatment plan, and evaluating the curative effect. The ES in the inguinal area reported in the literature showed high radioactivity uptake on ¹⁸F-FDG PET/CT, and the maximum standard uptake value (SUVmax) was as high as 25.13 (15), thus suggesting that the glucose metabolism of ES is relatively vigorous. In this case, PET/CT examination showed that in addition to the high metabolic radioactivity uptake in the left groin, the tailbone area also showed a soft tissue mass with high radioactivity distribution, and low-density bone destruction was seen on the CT bone window. However, our patient never complained about any discomfort in the relevant area on admission.

The most common malignant tumors in the groin area are metastatic tumors. Germ cell tumors (GCT) and mesenchymal tumors such as undifferentiated pleomorphic sarcoma, leiomyosarcoma, rhabdomyosarcoma, epithelioid tumors, and other mesenchymal tumors are usually rare (22). In our case, in addition to the groin area, a large soft tissue mass was found in the tail bone, so metastases were considered. Laboratory examination of GCT showed elevated alpha-fetoprotein levels or human chorionic gonadotropin (β -HCG) in some patients. However, the imaging findings of the undifferentiated pleomorphic sarcoma, leiomyosarcoma, rhabdomyosarcoma, and other mesenchymal tumors are not specific, and all of them may present as irregular soft tissue mass shadows of equal or slightly lower density, prone to cystic degeneration and necrosis resulting in uneven mass density; calcification may also occur in some tumors (23). Therefore, it is relatively difficult to distinguish these tumors from ES. Chordoma that usually occurs in the sacrococcyx should be considered for the tumors occurring in the coccyx. Chordomas often occur at age 40-60 years, predominantly in males (its occurrence is 2-3 times higher than in females) (24). CT findings show sacrococcygeal osteolytic or expansive bone destruction accompanied by a large soft tissue mass with uneven density, necrosis, cystic degeneration, and hemorrhage within the mass, often accompanied by calcification (25). Moreover, sacral giant cell tumor, neurogenic tumor, and chondrosarcoma should also be considered when

performing diagnosis. Giant cell tumor of bone usually presents as eccentric, expansive, soap-like bone destruction, with mild osteosclerosis and calcification; the osseous envelope is generally intact, without soft tissue mass (24). Neurogenic neoplasms often present as well-defined soft tissue masses with mild sclerosis of surrounding bone, often without bone destruction. Chondrosarcoma is typically an obvious soft tissue mass with dot, arc, and arch annular calcification signs. Chondrosarcoma diagnosis is achieved by comparing the characteristic imaging manifestations of progressive enhancement like garlands in the internal spacings and peripheral regions after an enhanced scan (26). Our patient had two soft tissue masses in the left groin area and caudal vertebra, so the origin of the primary lesion was essential for differential diagnosis.

The diagnosis of proximal ES mainly relies on histopathological examination. ES cells, mainly epithelioid cells, are pleomorphic and have obvious atypia and large nucleoli. Moreover, the growth pattern of ES is mainly nodular and diffuse, and the diagnosis is confirmed by characteristic rhabdoid cells (27). The CK and EMA proteins and vimentin in immunohistochemical staining are crucial for ES diagnosis and for distinguishing ES from other tumors, including synovial sarcoma, rhabdomyoid tumor, and granulomatous lesions (1).

Extensive surgical resection is the main treatment for ES (28). However, due to the recurrence of ES, adjuvant chemotherapy and local radiotherapy is often given after surgery (29, 30). For advanced or relapsed INI1-negative ES patients, a recent study showed that oral targeted drug tazemetostat could prolong the median survival rate of patients (31, 32).

CONCLUSIONS

Proximal-type ES is relatively rare, especially in the groin area. A clinical history of painless growth of a nodule or mass combined with radiographic findings of unevenly enhanced soft tissue density/signal and high radioactivity uptake with lymph node infiltration may suspect ES. However, its final diagnosis depends on histopathological examination. Our case shows that ES should be considered a differential diagnosis of inguinal metastases and other mesenchymal tumors.

ACKNOWLEDGMENTS

We would like to thank our colleagues in the Department of Pathology of the Affiliated Hospital of Zunyi Medical University for providing us with the pathological pictures of the patient. We would also like to thank the patient and his families for their contributions to our study, without whom we could not have completed our study.

Competing interests: No author has a conflict of

interest.

Declarations: Ethics approval and consent to participate: The research related to human use follows the principles of the Helsinki Declaration and has been approved by the Ethics Committee of the Affiliated Hospital of Zunyi Medical University, with the approval number ZYFY202102 and the release date on January 01, 2020. Written informed consent was obtained from the patient and his parents.

Funding: This study was funded by the National Natural Science Foundation of the People's Republic of China, NSFC (grant numbers: 81571712), Zunyi Medical College Research Start Fund 2018ZYFY03. Jiong Cai was the funder who designed the study and edited the paper for publication.

Authors' contributions: Hu X, Zhang C, Qian K, Yu R and Meng T designed the study; Hu X edited and wrote the paper; Cai J edited the paper; Zhang C and Qian K retrieved and counted the data; all authors read and approved the final manuscript.

REFERENCES

- Thway K, Jones RL, Noujaim J, Fisher C (2016) Epithelioid Sarcoma: Diagnostic Features and Genetics. *Adv Anat Pathol*, **23**(1): 41-49.
- Lualdi E, Modena P, Debiec-Rychter M, Pedetour F, Teixeira MR, Facchinetti F, et al. (2004) Molecular cytogenetic characterization of proximal-type epithelioid sarcoma. *Genes Chromosomes Cancer*, **41**(3): 283-290.
- Modena P, Lualdi E, Facchinetti F, Galli L, Teixeira MR, Pilotti S, et al. (2005) SMARCB1/INI1 tumor suppressor gene is frequently inactivated in epithelioid sarcomas. *Cancer Res*, **65**(10): 4012-4019.
- Armah HB and Parwani AV (2009) Epithelioid sarcoma. *Arch Pathol Lab Med*, **133**(5): 814-819.
- Noujaim J, Thway K, Bajwa Z, Bajwa A, Maki RG, Jones RL, et al. (2015) Epithelioid Sarcoma: Opportunities for Biology-Driven Targeted Therapy. *Front Oncol*, **5**: 186.
- Fukunaga M and Ushigome S (1999) Proximal-type epithelioid sarcoma in the pelvic soft tissues. *APMIS*, **107**(3): 283-288.
- Elsamna ST, Amer K, Elkattawy O, Beebe KS (2020) Epithelioid sarcoma: half a century later. *Acta Oncol*, **59**(1): 48-54.
- Mahajan A, Sen I, Hazra D, Agarwal S (2016) Management of Epithelioid Sarcoma of the Inguinal Region with Vascular Invasion. *Indian J Surg*, **78**(4): 315-317.
- Irimura S, Nishimoto K, Kikuta K, Nakayama R, Susa M, Horiuchi K, et al. (2015) Successful Treatment with Pazopanib for Multiple Lung Metastases of Inguinal Epithelioid Sarcoma: A Case Report. *Case Rep Oncol*, **8**(3): 378-384.
- Kim JY, Chung S, Lee HB, Chung YK (2012) Proximal-type Epithelioid Sarcoma Arising in the Inguinal Area. *Arch Plast Surg*, **39**(2): 177-179.
- Rekhi B and Singh N (2016) Spectrum of cytopathologic features of epithelioid sarcoma in a series of 7 uncommon cases with immunohistochemical results, including loss of INI1/SMARCB1 in two test cases. *Diagn Cytopathol*, **44**(7): 636-642.
- Fujiki M, Miyamoto S, Arikawa M, Sakuraba M (2015) Combined Use of Anterolateral Thigh and Gluteal Fold Flaps for Complex Groin Reconstruction. *Plast Reconstr Surg Glob Open*, **3**(10): e541.
- Dainichi T, Honma Y, Hashimoto T, Furue M (2008) Clavus detected incidentally by positron emission tomography with computed tomography. *J Dermatol*, **35**(4): 242-243.
- Flucke U, Hulsebos TJ, van Krieken JH, Mentzel T (2010) Myxoid epithelioid sarcoma: a diagnostic challenge. A report on six cases. *Histopathology*, **57**(5): 753-759.
- Rekhi B, Verma A, Jambhekar NA, Menon S, Laskar S, Merchant N, et al. (2016) Osteoclast-rich, proximal-type epithelioid sarcoma: clinicopathologic features of 3 unusual cases expanding the histomorphological spectrum. *Ann Diagn Pathol*, **21**: 39-43.
- Khazeni K, LaBove H, Wilky B, Rosenberg AE, Paulus E, Chim H, et al. (2018) Myoepithelial carcinoma or epithelioid sarcoma - A rare diagnosis with poor prognosis. A case report and review of literature. *Int J Surg Case Rep*, **49**: 239-243.
- Mannan AA, Rifaat AA, Kahvci M, Kapila K, Mallik M, Grover VK, et al. (2010) Proximal-type epithelioid sarcoma in the groin presenting as a diagnostic dilemma. *Pathol Oncol Res*, **16**(2): 181-188.
- Hasegawa T, Matsuno Y, Shimoda T, Umeda T, Yokoyama R, Hirohashi S (2001) Proximal-type epithelioid sarcoma: a clinicopathologic study of 20 cases. *Mod Pathol*, **14**(7): 655-663.
- Kodet R, Smelhaus V, Newton WA Jr, Hamoudi AB, Qualman SJ, Singley C, et al. (1994) Epithelioid sarcoma in childhood: An immunohistochemical, electron microscopic, and clinicopathologic study of 11 cases under 15 years of age and review of the literature. *Pediatr Pathol*, **14**(3): 433-451.
- Tateishi U, Hasegawa T, Kusumoto M, Yokoyama R, Moriyama N (2002) Radiologic manifestations of proximal-type epithelioid sarcoma of the soft tissues. *AJR Am J Roentgenol*, **179**(4): 973-977.
- Chase DR and Enzinger FM (1985) Epithelioid sarcoma: Diagnosis, prognostic indicators, and treatment. *Am J Surg Pathol*, **9**(4): 241-263.
- Skubitz KM, Dadamo DR (2007) Sarcoma. *Mayo Clin Proc*, **82**(11): 1409-1432.
- Deng LW (2016) Clinical characteristic and CT features in trunk rhabdomyosarcoma. *Southern Med Univ*, **28**: 21-56.
- Girish G, Finlay K, Fessell D, Pai D, Dong Q, Jamadar D (2012) Imaging review of skeletal tumors of the pelvis malignant tumors and tumor mimics. *ScientificWorldJournal*, **2012**: 240281.
- Hain KS, Pickhardt PJ, Lubner MG, Menias CO, Bhalla S (2013) Presacral masses: multimodality imaging of a multidisciplinary space. *Radiographics*, **33**(4): 1145-1167.
- Zhou J, Ding J, Zeng M (2013) Relationship between imaging findings and pathology of primary chondrosarcoma. *Radiology practice*, **33**(2): 1145-1167.
- Colombo F, Franceschelli A, Schiavina R, Gentile G, Passaretti G, Martorana G (2013) Epithelioid sarcoma of the penis: a case report. *J Sex Med*, **10**(11): 2871-2874.
- Wolf PS, Flum DR, Tanas MR, Rubin BP, Mann GN (2008) Epithelioid sarcoma: the University of Washington experience. *Am J Surg*, **196**(3): 407-412.
- Levy A, Le Pêcheux C, Terrier P, Bouaita R, Domont J, Mir O, et al. (2014) Epithelioid sarcoma: need for a multimodal approach to maximize the chances of curative conservative treatment. *Ann Surg Oncol*, **21**(1): 269-276.
- Baratti D, Pennacchioli E, Casali PG, Bertulli R, Lozza L, Olmi P, et al. (2007) Epithelioid sarcoma: prognostic factors and survival in a series of patients treated at a single institution. *Ann Surg Oncol*, **14**(12): 3542-3551.
- Gounder M, Schöffski P, Jones RL, Agulnik M, Cote GM, Villalobos VM, et al. (2020) Tazemetostat in advanced epithelioid sarcoma with loss of INI1/SMARCB1: an international, open-label, phase 2 basket study. *Lancet Oncol*, **21**(11): 1423-1432.
- Tansir G, Rastogi S, Shamim SA, Barwad A (2021) Early clinical and metabolic response to tazemetostat in advanced relapsed INI1 negative epithelioid sarcoma. *Future Sci OA*, **7**(4): FSO675.