

Effects of repeated ultraviolet-C radiation on tissues: A Guinea pig model study

O. Ozmen*, V. Ipek, S.A. Tasan, L.E.O. Ayozyger, M. Altintas

Burdur Mehmet Akif Ersoy University, Faculty of Veterinary Medicine, Department of Pathology, Burdur, Turkey

► Original article

ABSTRACT

*Corresponding author:

Ozlem Ozmen, Ph.D.,

E-mail:

ozlemozmen@mehmetakif.edu.tr

Received: September 2021

Final revised: August 2022

Accepted: September 2022

Int. J. Radiat. Res., January 2023;
21(1): 45-51

DOI: 10.52547/ijrr.21.1.6

Keywords: UV-C, treatment, Guinea pig, pathology.

Background: Due to the disinfection and antibiotic resistance of microorganisms, there is a growing interest in ultraviolet-C (UV-C). UV-C has numerous advantages, and the applications of this method for fluids, surfaces, and air are rapidly expanding. However, nothing is known about how UV-C affects living bodies. This study's objective is to assess the results of 10 sessions of 10- to 20-minute UV-C exposure on healthy guinea pigs. **Materials and Methods:** After five days of UV-C treatment, blood and visceral organ samples were collected and analyzed. **Results:** Moreover, the hematological and biochemical analyses of the blood samples revealed no significant changes. According to histopathological examination, UV-C treatment did not cause any damage to internal organs. Except for the intestine, caspase-3 immunohistochemistry revealed no increase in apoptotic activity. In the UV-C-treated groups, only minor apoptotic activity was observed in intestinal goblet cells. **Conclusion:** This study found that repeated UV-C exposure for ten sessions lasting 10-20 minutes did not result in any pathological findings in the guinea pig model. This result suggested that UV-C could be used for barn and pen disinfection when animals are present as well as udder disinfection prior to milking.

INTRODUCTION

The most plentiful and natural source of ultraviolet radiation (UVR) is the sun. Based on their wavelength, UVR is divided into three categories: UV-A, UV-B, and UV-C. Because of the ozone layer absorbs UV-C radiation, the sun's rays cannot reach the Earth. As a result, unintended exposure to disinfectant lights is linked to the effects of UV-C on living things ⁽¹⁾. The nucleic acids of microbes strongly absorb UV-C wavelength, which has an antibiotic effect ⁽²⁾. It has been reported that UV exposure causes mutations in DNA ⁽³⁾. The severity of the UV light effects is determined by the wavelength, intensity, exposure time, and distance of the source. Furthermore, the sensitivity of the individual and presence of sensitizing agents are related to the severity of the damage ⁽²⁾.

Due to its effective disinfectant effect, UV-C has long been used for this purpose. In living bodies, UV-C irradiation is only used in a few cases for local infections. Animal trials and clinical studies at the in vitro and ex vivo levels are very rare. According to the results of the studies, UV-C is as effective as strong antibiotics in disinfecting antibiotic-resistant bacteria ⁽⁴⁾. Our recent study also indicated that UV-C is very effective on infected skin lesions in mouse model ⁽⁵⁾.

Environments where people and animals are crowded are constantly at risk of contamination.

Environmental contamination during procedures in hospitals is a great risk for infectious agents to enter and cause infection. Especially in barns, disinfection contributes both to the increase of milk quality and animal health. When there are living bodies both animal and human in the environment, disinfection provides great convenience. However, contact or inhalation of disinfectants can cause significant harmful effects. Because UV-C irradiation to living tissue is a localized process, its use for infectious diseases may be limited to local infections. For that reason, UV-C might be the ideal approach for this purpose, however it is unknown what impact UV-C has on living things. Utilizing UV-C in hospitals may be crucial to preventing environmental or human contamination. Similar to this, its usage to disinfect stables or barns when animals are present may help to avoid a variety of diseases in adult or young animals. However, it is equally important to look into how UV-C affects healthy, living bodies. Examining the effects of 10, 15, and 20 minutes of UV-C exposure on blood parameters and internal organs in healthy guinea pigs is the goal of this study.

MATERIALS AND METHODS

Animals

The experimental phase of the investigation was conducted in accordance with the recommendations

in ARRIVE (Animal Research: Reporting in Live Experiments) 2.0, and the experimental protocols received approval from Burdur Mehmet Akif Ersoy University's Local Animal Research Ethical Committee (MAKU-HADYEK-728 -17.02.2021). All guinea pigs were provided unlimited access to food and water throughout the trial. These animals were kept in a room with a controlled atmosphere. The humidity level and room temperature (22 ± 2 °C) were automatically controlled. They experienced 12-hour cycles of light and darkness.

Experimental procedure

A total of 12, five-month old guinea pigs of both sexes (8 males and 4 females) were used to conduct the experiment and they were divided into four groups of three animals each. No UV-C was applied to the first group, which was designated as the control group. The second group of guinea pigs had two sessions of UV-C treatment for 10 minutes, 15 minutes, and 20 minutes, per day respectively. Following receiving a total of 10 UV-C treatments over the course of five days in the morning and evening, each guinea pig in the control and treatment groups was euthanized four hours after the final UV-C application. A programmable UV radiation generator with sensor (Qzuradiation [nonionizer] generator, Qzu QSS Technology Burdur) was used to subject guinea pigs to UV-C radiation at a distance of 1 meter with an energy density of 120 mw/cm² (figure 1).



Figure 1. UV-C ultraviolet generator used in the study.

At the end of the experimental phase, all guinea pigs were euthanatized and sacrificed while under anesthesia with 10 mg/kg xylazine (Alfazin, Alfasan IBV) and 90 mg/kg ketamine (Alfamin, Alfasan IBV). Moreover, blood samples were collected for biochemical and hematological studies. In addition, for light microscopic examination and immunohistochemical staining visceral organ samples were harvested.

Hematological evaluations

Prior to euthanasia, blood samples were collected for hematological and biochemical analyses. A fully automated cell counter device (Abacus Junior Vet,

Budapest, Hungary) was used for complete blood count of the cardiac blood samples taken into ethylene diamine tetra acetic acid (EDTA) tubes. An automated biochemistry analyzer (Gesam Chem 200 autoanalyzer, Italy) was used to conduct biochemical analyses.

Histopathological method

Visceral organs (liver, lung, spleen, brain, cerebellum, intestine, kidney, uterus, testes, and heart samples) were examined macroscopically during necropsy. After that, organ tissue samples were taken and immediately fixed in a 10% buffered formalin solution. The samples were then taken to a standard tissue processing procedure, where they were processed using a fully automated tissue-processor (Leica ASP300S; Leica Microsystem, Nussloch, Germany). The samples were then embedded in paraffin wax and serial sections were obtained using a fully automatic Leica 2155 rotary microtome with a thickness of 5 µm, additionally, light microscopy was used to examine slides that had been stained with hematoxylin and eosin (HE). Semi-quantitative scores between 0 and 3 were assigned to immunohistochemical expressions. A score of 0 indicates negative, 1; mild, 2; moderate, and 3; severe positive. For microphotography and morphometric analyses Database Manual Cell Sens Life Science Imaging Software System (Olympus Co., Tokyo, Japan) was used.

Immunohistochemical method

In addition, immunohistochemical labeling using the streptavidin-biotin technique was carried out to assess the level of apoptotic activity in sections collected from all guinea pigs. All visceral organ sections were taken on poly L-lysine slides and stained in accordance with the manufacturer's instructions to assess the expression of caspase-3 using the anti-caspase-3 antibody (ab4051), Abcam (Cambridge, UK). Before being incubated with a biotinylated secondary antibody and a streptavidin-alkaline phosphatase conjugate, the sections were first incubated with the caspase-3 primary antibody for 60 minutes. The diaminobenzidine (DAB) was employed as the chromogen, and the EXPOSE Mouse and Rabbit Specific HRP/DAB Detection IHC kit (ab80436) from Abcam, Cambridge, UK, was utilized as the secondary antibody. Instead of using primary antibodies for negative controls, antigen dilution solution was applied. Blind specimens were used for all examinations.

Statistical analysis

The SPSS-22.00 package program was used to do the one-way analysis of variance (ANOVA) Duncan test in order to compare the outcomes of the control, 10-, 15-, and 20-minute UV-C-treated groups among the groups.

RESULTS

Biochemical findings

All of the 12 animals' blood samples were evaluated. The biochemical parameters of control and UV-C-treated healthy guinea pigs were compared. Although there were minor changes in some parameters, there were no significant changes associated with UV-C treatment. Table 1 displays the results of the statistical analysis.

Table 1. Results of statistical analysis of biochemical and hematological values of guinea pigs given control and UV-C for various time periods.

	Control	10-minute	15-minute	20-minute	P value
Urea	44.66±6.50	59.66±6.11	78.66±45.32	62.33±7.02	>0.05
Potassium	3.55±0.31	3.64±0.13	3.60±0.43	3.90±0.13	>0.05
Bileacids	2.91±0.13	3.57±1.86	4.25±1.20	2.93±1.67	>0.05
Total protein	4.65±0.32	4.25±0.30	4.24±0.41	4.64±0.41	>0.05
Inorganic Phos	5.13±0.75	13.00±5.37	9.13±3.85	11.23±1.75	>0.05
GGT	13.66±3.21 ^a	12.33±3.21 ^a	15.00±3.60 ^a	28.00±7.00 ^b	<0.05*
Total bilirubin	0.11±0.17	0.06±0.00	0.05±0.00	0.05±0.00	>0.05
Creatine	0.61±0.17	0.76±0.19	0.78±0.21	0.83±0.13	>0.05
Calcium	10.95±0.22	11.40±0.95	10.59±0.86	11.36±0.22	>0.05
ALT	114.63±21.34 ^a	31.83±10.90 ^b	44.16±25.69 ^b	41.83±20.58 ^b	<0.05*
AST	103.13±12.35	45.33±8.74	67.46±29.86	33.30±13.59	>0.05
ALPAMP	133.00±38.03	150.00±96.34	131.66±66.22	75.66±19.85	>0.05
Albumin (ALB)	2.57±0.14	2.41±0.22	2.28±0.27	2.69±0.11	>0.05
WBC	6.18±1.70 ^a	8.53±1.91 ^b	4.42±0.27 ^a	5.02±0.78 ^a	<0.05*
LYM	1.50±0.16 ^a	3.76±1.14 ^b	1.72±0.35 ^a	2.41±0.60 ^a	<0.05*
MID	0.39±0.28	0.40±0.31	0.19±0.15	0.30±0.27	>0.05
GRA	4.29±1.72	4.36±1.95	2.49±0.22	2.31±0.47	>0.05
LY %	25.13±5.07	45.33±15.88	38.83±5.80	48.33±11.26	>0.05
MI %	7.20±5.70	5.23±3.86	4.70±3.85	5.76±3.16	>0.05
GR %	67.66±10.45	49.30±15.87	56.46±3.06	45.90±5.82	>0.05
RBC	4.94±0.41	4.74±0.13	3.98±2.01	4.45±0.57	>0.05
HGB	12.40±0.91	11.83±0.64	11.00±2.52	11.10±1.30	>0.05
HCT	43.29±4.05	41.69±1.46	35.26±14.98	39.84±4.97	>0.05
MCV	87.33±1.15	87.66±1.15	92.66±13.27	89.33±0.57	>0.05
MCH	25.20±0.91	25.00±0.69	32.46±14.31	24.90±0.26	>0.05
MCHC	28.76±1.30	28.43±0.65	34.00±9.78	27.86±0.30	>0.05
RDWc	15.16±0.28	15.80±1.05	18.43±4.82	14.80±0.20	>0.05
PLT	408.33±54.07	456.66±64.22	974.66±378.55	677.00±65.19	>0.05
PCT	0.36±0.03	0.37±0.02	0.86±0.67	0.53±0.02	>0.05
MPV	9.00±0.36	8.26±0.80	8.50±0.88	7.86±0.35	>0.05
PDWC	34.03±0.56	32.80±1.22	33.03±1.00	32.66±0.05	>0.05

Hematological findings

The UV-C treatment was responsible for the lack of a statistically significant difference in hematological parameters between the control and UV-C-treated groups. Table 1 displays the outcomes and shows the results.

Macroscopic findings

During the experiment, no one died in any of the groups. In all guinea pigs, no macroscopic or behavioral changes were observed. During necropsy, no pathological changes were seen in any of the groups or organs of 12 animals.

Microscopical findings

The liver, lung, spleen, brain, cerebellum, intestine, kidney, uterus, testes, and heart samples of all guinea pigs were examined. The animals in both the control and UV-C-treated groups had completely normal histological structure (figures. 2–5).

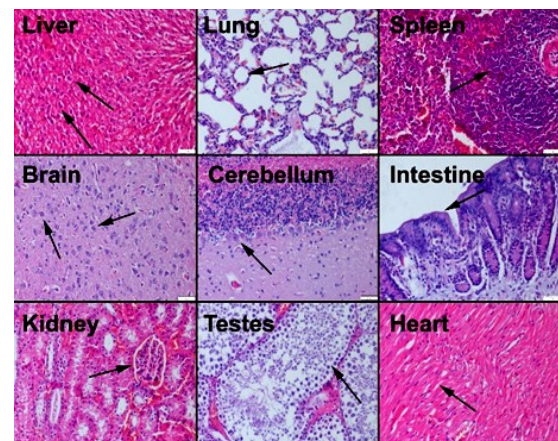


Figure 2. Normal appearance of visceral organs of guinea pigs in the control group, liver and hepatocytes (arrows), lung and alveolus (arrow), spleen and lymphoid follicles (arrow), brain and neurons (arrows), cerebellum and Purkinje cell (arrow), intestine and epithelial layer (arrow); kidney and glomerulus (arrow), testes and seminiferous tubule (arrow), heart and myocardial cells (arrow), HE, 200X.

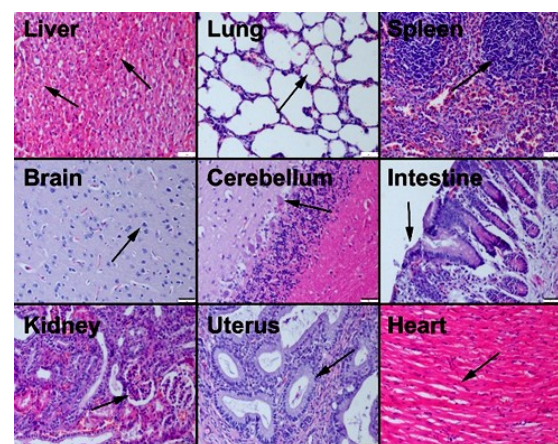


Figure 3. Microscopic view of normal tissue histology in guinea pig visceral organs treated with UV-C for 10 minutes, liver and hepatocytes (arrows), lung and alveolus (arrow), spleen and lymphoid follicles (arrow), brain and neurons (arrow), cerebellum and Purkinje cell (arrow), intestine and epithelial layer (arrow); kidney and glomerulus (arrow), uterus and endometrial glands (arrow), heart and myocardial cells (arrow), HE, 200X.

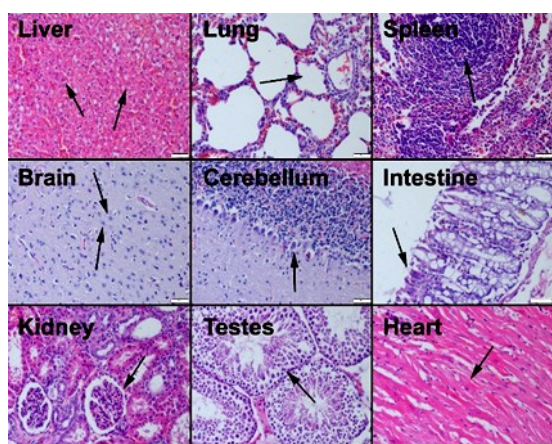


Figure 4. Microscopical appearance of normal tissue microarchitecture in visceral organs of guinea pigs treated with UV-C for 15 minutes, liver and hepatocytes (arrows), lung and alveolus (arrow), spleen and lymphoid follicles (arrow), brain and neurons (arrows), cerebellum and Purkinje cell (arrow), intestine and epithelial layer (arrow); kidney and glomerulus (arrow), testes and seminiferous tubule (arrow), heart and myocardial cells (arrow), HE, 200X.

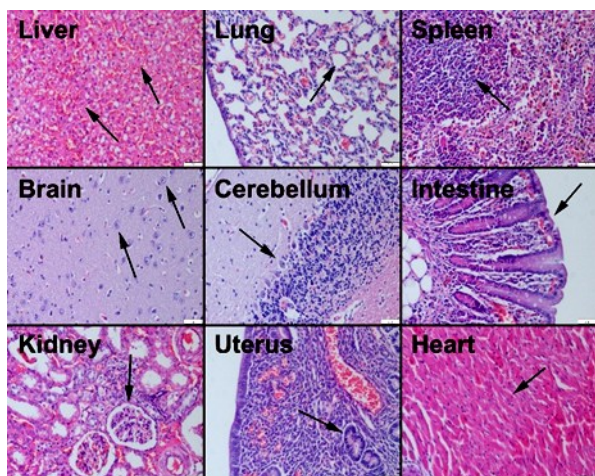


Figure 5. Normal tissue histology of visceral organs of guinea pigs treated with UV-C for 20 minutes, liver and hepatocytes (arrows), lung and alveolus (arrow), spleen and lymphoid follicles (arrow), brain and neurons (arrows), cerebellum and Purkinje cell (arrow), intestine and epithelial layer (arrow); kidney and glomerulus (arrow), testes and seminiferous tubule (arrow), heart and myocardial cells (arrow), HE, 200X.

Caspase-3 immunohistochemical findings

The immunohistochemical examination of apoptotic activity in visceral organs in 12 Guinea pigs revealed that all organs, except the intestines, had negative expressions. One Guinea pig each in 10- and 15-minute groups, 2 Guinea pigs in 20-minute UV-C-treated groups, there was a slight expression in intestinal goblet cells (figures 6–9).

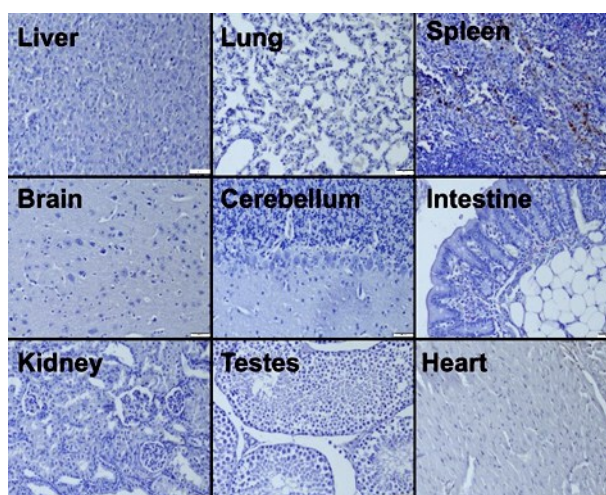


Figure 6. No caspase-3 immunoreaction in the visceral organs in the control group, streptavidin-biotin peroxidase method, 200X.

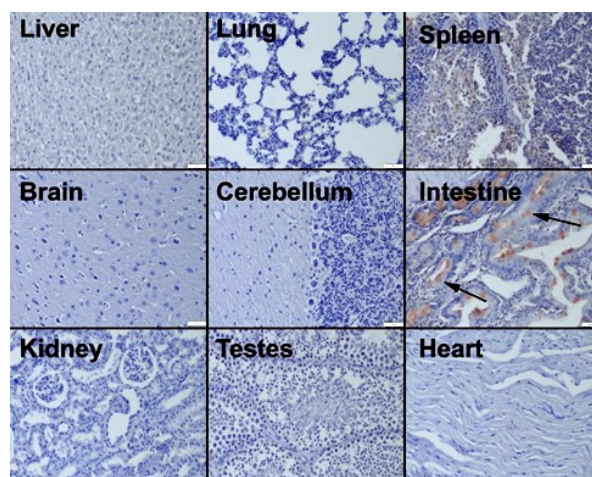


Figure 7. Negative immunoexpressions in the visceral organs of guinea pigs administered with a 10-minute UV-C, mild caspase-3 immunoreaction in some goblet cells in the intestines (arrows), streptavidin-biotin peroxidase method, 200X.

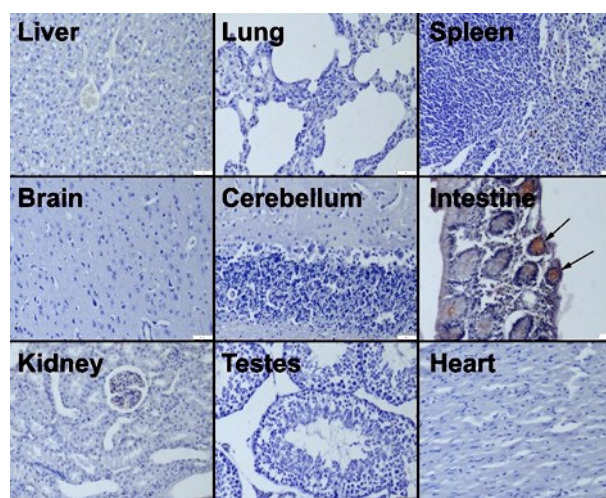


Figure 8. No immunoexpression of the visceral organs of guinea pigs treated with UV-C for 15 minutes, slight caspase-3 immunoreaction in some epithelial cells in the intestines (arrows), streptavidin-biotin peroxidase method, 200X.

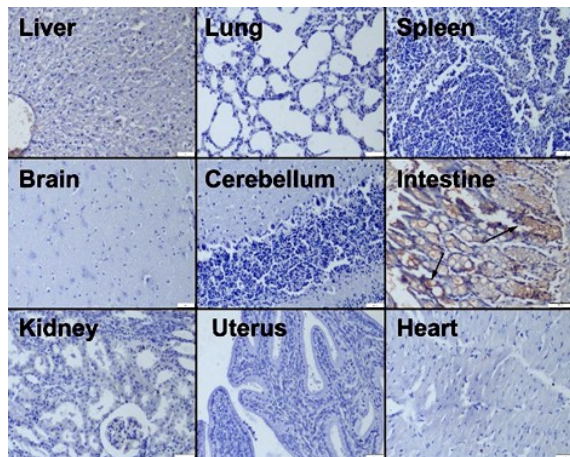


Figure 9. Negative expression in the visceral organs of guinea pigs treated with UV-C for 20 minutes, slight caspase-3 immunoreaction in some cells in the intestines (arrows), streptavidin–biotin peroxidase method, 200X.

DISCUSSION

The consequences of direct UV-C radiation on the bodies of people and animals are not well understood. There are limited reports on the effects of accidental UV-C exposure, which makes them debatable. DNA damages have been linked to acute UV-C irradiation exposure (3). However, a study on students indicated that an unintentionally high exposure to UV-C radiation that was 20 times over the recommended level only caused one case of a severe lesion that was discovered in the short-term follow-up as a result of the exposure's 90 minutes. They only documented reversible lesions that were limited to the skin and eyes (6). According to the study's findings, guinea pigs were exposed to UV-C for 10, 15, and 20 minutes over the course of 10 sessions without any negative effects.

The usage of UV-C for disinfection has recently expanded significantly due to its advantages. In antimicrobial agents with antibiotic resistance, it has a strong antiseptic action (7). In hospitals and operating rooms, it is used to combat resistant organisms like methicillin-resistant *Staphylococcus aureus* (8). The results of repeated UV-C exposure in healthy animals are unknown, though. According to the study's findings, UV-C can be applied to living things without causing any harm. This result indicated that it could be used to prevent or treat diseases caused by microorganisms or for barn disinfection when the animals are present. Short-term UV-C disinfection can also be used in hospitals with a high risk of contamination. While UV-C irradiation causes trace amounts of dimer formation between two strands of double-stranded DNA in aqueous media, the frequency of interstrand dimers increases dramatically in different environments, such as 80% ethanol or dry environments (9). Pyrimidine dimers are slightly photoactive, but exposure to UV-C light can enhance activation (10, 11).

Furthermore, DNA repair processes may occur in vivo in cells exposed to UV-C (12-14). Despite the fact that no tests for DNA damage were performed in this study, no increase in apoptotic activity was observed in any organ except the intestine. In this study, the intestine was found to be the most vulnerable organ to UV-C radiation exposure. Because of the intestinal cells' high mitotic activity and ameliorative capacity, the intestinal changes may be reversible and not cause any problem. On the other hand, this effect may be useful in infectious diseases caused by viral or intracellular bacterial agents by desquamation of the infected cells.

Tolerance and repair systems to UV-C can evolve over a long evolutionary period in different organisms. As a result, UV-C light can be used to destroy and treat bacteria, yeast, viruses, and fungi (15). According to this study, it is safe to utilize UV-C to either prevent or treat infectious diseases in living organisms. Moreover, another application could be udder disinfection in dairy cattle before and after milking. In addition, UV-C may be effective in foot lesions in farm animals or neonatal diseases in newborn animals that caused marked economical losses in farm animal industry.

UV-C disinfects bacteria and fungi much more quickly than antimicrobial drugs. Furthermore, antibiotics typically take several days to reach wound areas, due to impaired blood perfusion in some chronic and burns wounds. As a result, lengthy treatment periods are generally required. UV-C, on the other hand, can kill microorganisms in less than an hour (16). This study found that even after a total of more than three hours of treatment, there were no significant pathological findings in guinea pigs. The reason for this safe situation could be the animals' thick coats of skin, but in general, less treatment is used in human studies. Previous human studies have also demonstrated successful outcomes with no side effects (13, 17-22). The current study's results backed up the previous study reports about the safety of UV-C in living bodies.

Yel et al. found UV-C radiation to be harmful to the stratum corneum of mole rats' epidermis after 52-, 112-, and 168-hour continuous exposure. They performed an ultrastructural examination of the stratum corneum and discovered changes in the cytoplasm, mitochondria, and nucleus (23). In this study, there were no pathological findings in the skin of the guinea pigs. Moreover, the duration of the exposure could be a possible cause of these results.

Recent studies have shown that keratin in the stratum corneum absorbs a significant amount of 222-nm UV-C. Only a minor percentage of the 222-nm UV-C would therefore pass through the epidermal layer. Typically, germicidal lights emit 254-nm UVC, which kills germs efficiently. However, this wavelength can penetrate deeper into the epidermis and cause damage to the skin and eyes (24, 25). Additionally, there have been cases of UV-C-induced erythema in human

skin in a previous report ⁽²⁶⁾. Although UV radiation cannot pass through skin, seasonally increasing UV light exposure is linked to a decreased mortality rate in patients with *Clostridium difficile* infection ⁽²⁷⁾. Furthermore, a recent article reported that ultraviolet irradiation of mouse skin caused alteration in its fecal microbiome ⁽²⁸⁾. Recently, reports have been published that UV-C can also be used in the control of coronaviruses ⁽²⁹⁻³³⁾. According to these reports, not all UV radiation was absorbed by the skin. It is possible that some of the radiation made its way to the gut. Further, higher-energy UV rays are a type of ionizing radiation. This study also found that long-term UV-C radiation had an effect on some enterocytes, which could be used to treat intestinal infectious diseases. However, no one knows what effects 254-nm UV radiation has on visceral organs and blood parameters.

For the first time, no marked pathological findings in guinea pigs after 10 session UV-C treatment were reported in this study. As a result, UV-C can be used for disinfection in guinea pig production centers, experimental animal rearing units, animal hospitals, milking areas and domestic animal shelters that disinfectants commonly used. The primary benefit of this disinfection method may be lower side effects and toxicity than disinfectants, as well as usability when the animals in the barns are present. Furthermore, because of its numerous advantages, such as no precipitation, no damage for surfaces or fluids, and no chemical reaction, it may be a good choice for the treatment of skin or visceral organ diseases prophylaxis or treatment. The duration and dosage of UV-C administration on people and animals for varied purposes require further studies.

ACKNOWLEDGMENT

For their assistance throughout the experimental study, the authors are grateful to the personnel of the Burdur Mehmet Akif Ersoy University Experimental Animals Production and Experimental Research Center.

Funding: No funding was received for conducting this study.

Conflicts of interests: There is no conflict of interest.

Ethical considerations: Experimental procedure was approved by Local Ethical Committee on Animal Research of Burdur Mehmet Akif Ersoy University, Burdur, Turkey (MAKU-HADYEK-728-17.02.2021).

Author contribution: OZ: Designing the experiment, investigation, evaluation, and writing. VI: Investigation, editing. SAT: Experimental procedure and care of experimental animals. LEOA: Histopathology and Immunohistochemistry laboratory procedure. MA: Data collection and blood analyses.

REFERENCES

1. Matsumura Y and Ananthaswamy HN (2004) Toxic effects of ultraviolet radiation on the skin. *Toxicol Appl Pharmacol*, **195**(3): 298-308.
2. Gurzadyan GG, Gorner H, Schulte-Frohlinde D (1995) Ultraviolet (193, 216 and 254 nm) photoinactivation of Escherichia coli strains with different repair deficiencies. *Radiat Res*, **141**(3): 244-51.
3. Tornaletti S and Pfeifer GP (1996) UV damage and repair mechanisms in mammalian cells. *BioEssays*, **18**(3): 221-8.
4. Conner-Kerr TA, Sullivan PK, Gaillard J, Franklin ME, Jones RM (1998) The effects of ultraviolet radiation on antibiotic-resistant bacteria in vitro. *Ostomy Wound Manage*, **44**(10): 50-6.
5. Ozmen O, Sababoglu E, Ozyildiz Z, Milletsever A, Okuyucu G (2021) Ameliorative and disinfection effects of Ultraviolet-C Radiation on experimentally induced and infected skin wounds: A mice model study. *Int J Low Extrem Wounds*, DOI: 10.1177/15347346211041869 (in press).
6. Trevisan A, Piovesan S, Leonardi A, Bertocco M, Nicolosi P, Peliz MG, Angelini A (2006) Unusual High Exposure to Ultraviolet-C Radiation *Photochem Photobiol*, **82**(4): 1077-9.
7. Maclean M, MacGregor SJ, Anderson JG, Woolsey G (2009) Inactivation of bacterial pathogens following exposure to light from a 405-nanometer light emitting diode array. *Appl Environ Microbiol*, **75**(7): 1932-7.
8. Jinadatha C, Quezada R, Huber TW, Williams JB, Zeber JE, Copeland LA (2014) Evaluation of a pulsed-xenon ultraviolet room disinfection device for impact on contamination levels of methicillin-resistant Staphylococcus aureus. *BMC Infect Dis*, **14**(1): 1-14.
9. Douki T, Laporte G, Cadet J (2003) Inter-strand photoproducts are produced in high yield within A-DNA exposed to UVC radiation. *Nucleic Acids Res*, **31**(12): 3134-42.
10. Cadet J and Vigny P (1990) The photochemistry of nucleic acids. In: H Morrison (ed.): Bioorganic photochemistry, Vol. 1. Wiley and Sons, New York, 1-272.
11. Cadet J, Voituriez L, Hruska FE, Kan L-S, de Leeuw FAA, Altona C (1985) Characterization of thymidine ultraviolet photoproducts. Cyclobutane dimers and 5,6-dihydrothymines. *Can J Chem*, **63**(11): 2861-8.
12. Sinha RP and Hader DP (2002) UV-induced DNA damage and repair: A review. *Photochem Photobiol Sci*, **1**(4): 225-236.
13. Taylor GJ, Leeming JP, Bannister GC (1993) Effect of antiseptics, ultraviolet light and lavage on airborne bacteria in a model wound. *J Bone Joint Surg Br*, **75**(5): 724-30.
14. Taylor JS (1994) Unraveling the molecular pathway from sunlight to skin-cancer. *Acc Chem Res*, **27**(3): 76-82.
15. Cleaver JE (2006) Cells have long experience of dealing with UVC light. *Nature*, **442**(7100): 244.
16. Dai T, Vrahas MS, Murray CK, Hamblin MR (2012) Ultraviolet C irradiation: an alternative antimicrobial approach to localized infections? *Expert Rev Anti Infect Ther*, **10**(2): 185-195.
17. Shimomura A, Tahara D, Tominaga M, Uchigiri S, Yamaguchi Y, Ishioka H, Nakahata A (1995) The effect of ultraviolet rays on the prevention of exit-site infections. *Adv Perit Dial*, **11**: 152-156.
18. Thai TP, Houghton PE, Campbell KE, Woodbury MG (2002) Ultraviolet light C in the treatment of chronic wounds with MRSA: a case study. *Ostomy Wound Manage*, **48**(11): 52-60.
19. Thai TP, Keast DH, Campbell KE, Woodbury MG, Houghton PE (2005) Effect of ultraviolet light C on bacterial colonization in chronic wounds. *Ostomy Wound Manage*, **51**(10): 32-45.
20. Boker A, Rolz-Cruz G, Cumbie B, Kimball AB (2007) A single-center, prospective, open-label, pilot study of the safety, local tolerability, and efficacy of ultraviolet-C (UVC) phototherapy for the treatment of great toenail onychomycosis. *J Am Acad Dermatol*, **58**(2): AB82.
21. Kloth C (1995) Physical modalities in wound management: UVC, therapeutic heating and electrical stimulation. *Ostomy Wound Manage*, **41**(5): 18-20.
22. Ploydaeng M, Rajatanavin N, Rattanakaemakorn P (2021) UV-C light: A powerful technique for inactivating microorganisms and the related side effects to the skin. *Photodermatol Photoimmunol Photomed*, **37**:12-19.
23. Yel M, Guven T, Turker H (2014) Effects of ultraviolet radiation on the stratum corneum of skin in mole rats. *J Radiation Res App Sci*, **7**(4): 506-511.
24. Yamano N, Kunisada M, Kaidzu S, Sugihara K, Nishiaki-Sawada A, et al. (2020) Long-term Effects of 222-nm ultraviolet radiation C steri-

- lizing lamps on mice susceptible to ultraviolet radiation. *Photochem Photobiol*, **96**(4): 853-862.
25. Ikehata H, Mori T, Kamei Y, Douki T, Cadet J, Yamamoto M (2020) Wavelength- and tissue-dependent variations in the mutagenicity of cyclobutane pyrimidine dimers in mouse skin. *Photochem Photobiol*. **96**(1): 94-104.
26. Reischl S, Henrich J, Schaubberger G (2000) Time course and dose-response-relationship of erythema of the pigs induced by UVB- and UVC-radiation. In: 13th international congress on photobiology, San Francisco, 1–6 July 2000; p 1-6.
27. Govani SM, Waljee AK, Stidham RW, Higgins PDR (2015) Increasing ultraviolet light exposure is associated with reduced mortality from *Clostridium difficile* infection. *United Eur Gastroenterol J*, **3**: 208-214.
28. Ghaly S, Kaakoush NO, Lloyd F, Gordon L, Forest C, Lawrance IC, Hart PH (2018) Ultraviolet irradiation of skin alters the faecal microbiome independently of vitamin D in mice. *Nutrients*, **10**: 1069.
29. Biasin M, Bianco A, Pareschi G, Cavalleri A, Cavatorta C, Fenizia C, et al. (2021) UV-C irradiation is highly effective in inactivating SARS-CoV-2 replication. *Sci Rep*, **11**: 6260.
30. Buonanno M, Welch D, Shuryak I, Brenner DJ (2020) Far-UVC light (222nm) efficiently and safely inactivates airborne human coronaviruses. *Sci Rep*, **10**: 10285.
31. Raeiszadeh M and Adeli B (2020) A critical review on ultraviolet disinfection systems against covid-19 outbreak: Applicability, validation, and safety considerations. *ACS Photonics*, **7**: 2941-2951.
32. Bhardwaj SK, Singh H, Deep A, Khatri M, Bhaumik J, Kim K-H, Bhardwaj N (2021) UVC-based photoinactivation as an efficient tool to control the transmission of coronaviruses. *Sci Total Environ*, **792**: 148548.
33. Hessling M, Hönes K, Vatter P, Lingenfelder C (2020) Ultraviolet irradiation doses for coronavirus inactivation – review and analysis of coronavirus photoinactivation studies. *GMS Hyg Infect Control*, **15**: Doc08.

