

Diagnostic value of dental cone beams computed tomography using low-dose radiation technique for diagnosis of wrist fractures

M. Aljamal^{1*}, A. Qutit², M. Abuzaid³, N. Omarah⁴, M. Zahri⁵, M. Fairus⁶

¹Department of Medical Imaging, Faculty of Allied Medical Sciences, Arab American University, Jenin, Palestine

²Tower Dental X-ray Center, Nablus, Palestine

³Medical Diagnostic Imaging Departments, College of Health Sciences, University of Sharjah, Sharjah, United Arab Emirates

⁴Department of Medical Imaging, Ministry of Health, Nablus, Palestine

⁵Oncological and Radiological Sciences Cluster, Advanced Medical & Dental Institute, University Sains Malaysia, Pulau Pinang, Malaysia

⁶Diagnostic Radiography Department, Faculty of Allied Health Sciences, Singapore Institute of Technology, Singapore

► Technical note

*Corresponding author:

Mohammad Aljamal, Ph.D.,

E-mail:

mohammad.aljamal@aaup.edu

Received: March 2024

Final revised: September 2024

Accepted: October 2024

Int. J. Radiat. Res., April 2025;
23(2): 489-492

DOI: 10.61186/ijrr.23.2.489

Keywords: Cone beam computed tomography, wrist fracture; multidetector computed tomography, dental CBCT, radiation dose.

ABSTRACT

Background: Utilizing dental cone beam computed tomography (DCBCT) in wrist bone fracture diagnosis is relatively new. This study investigated the diagnostic value of DCBCT using a low-dose radiation technique for wrist fractures. **Materials and Methods:** This study compared dental CBCT (DCBCT) with multidetector computed tomography (MDCT) and extremity CBCT in terms of radiation dose, using the dose-length product (DLP) as the primary comparison metric. Twenty-nine adult patients presenting with various wrist injuries underwent imaging with different parameters using DCBCT. Image quality was independently assessed by two radiologists using a 5-point Likert scale. **Results:** DCBCT demonstrated a significantly lower radiation dose than MDCT, though slightly higher than extremity CBCT. The optimized DCBCT protocol (70 kV, 2 mAs, 15 seconds) provided high diagnostic image quality, with an interrater agreement of 85.4%. **Conclusion:** DCBCT offers an effective, lower-radiation alternative for diagnosing wrist fractures compared to MDCT. Optimized protocols provide good image quality and could be cost-effective, particularly in regions where extremity CBCT is unavailable.

INTRODUCTION

The traditional X-ray examination is the most common approach for identifying carpal bone fractures. However, many fractures are missed with this method since it cannot detect tiny fractures due to overlapping structures and improper positioning or technique ⁽¹⁾. Radiographically, up to 39% of carpal bone fractures are missed on plain x-ray scans ⁽²⁾. While multidetector computed tomography (MDCT) offers improved detection ⁽³⁻⁵⁾. However, this approach revealed that the patient received an extremely high radiation dose ⁽¹⁾. Cone beam computed tomography was proposed in 1990 for dental applications, and recently this technology was integrated for imaging guidance in radiation treatment applications ⁽⁶⁾. Conversely, specialized cone beams computed tomography (CBCT) has been used for musculoskeletal diagnosis called extremity

CBCT ⁽⁷⁾. It was developed as a technique for identifying fractures of tiny bones, such as those of the carpus, and it has been demonstrated in several studies to be quicker and more accurate than conventional radiography ^(3, 8, 9). At the same time, it has shown a greater spatial resolution for bone pathology detection and lower radiation dose than MDCT scans ^(5, 10, 11). Several studies have used this type of CBCT to diagnose wrist fractures ^(3, 5, 10, 12). However, this device did not launch popularity due to the presence of the MDCT device as an alternative device, particularly in non-developed countries. Therefore, there is a need for an alternative method available with minimal radiation doses and it can detect fractures with high quality. Hence, dental CBCT (DCBCT) has been suggested as an alternative to diagnosing wrist fractures ⁽¹³⁾ and it has been revealed that DCBCT is superior to X-ray radiography in diagnosing wrist fractures. However, the previous

studies only focused on using extremity CBCT and MDCT as three-dimensional imaging techniques to diagnose wrist fractures (3, 4, 5, 10, 11), while there is a lack of studies on radiation dose comparisons between dental CBCT, MDCT, and extremity CBCT for imaging wrist bone fractures. To our knowledge, this study is the first to optimize imaging protocols for wrist fracture imaging using DCBCT. Accordingly, this study aims to optimize the DCBCT imaging technique for wrist bone fractures by comparing it with extremity CBCT and MDCT based on radiation dose.

MATERIALS AND METHODS

Radiation dose measurement

The radiation dose for different imaging techniques available in the DCBCT (Carestream 8100 3D, USA) system was assessed by measuring the dose length product (DLP) values using a pencil CT chamber (Raysafe x2 dosimeter, Sweden) (14). The study focused on the standard protocol of the DCBCT examination, which is usually carried out for dental imaging purposes of pediatric and adult examinations. The tube voltages and tube current combinations used were 70 keV (2 mA), 87 keV (2 mA), and 90 keV (3 mA), while the exposure time and slice thickness used were 15 seconds, and 0.15 mm, respectively. The Field of view (FOV) was fixed for all imaging to be 8 x 9 cm.

The DLP for multidetector CT (Philips 128 slice, Netherlands) and extremity CBCT (OnSight 3D Extremity System, USA) imaging of the standard carpal bone scanning were also measured using the same CT ionizing chamber for comparison purposes. The slice thickness, tube voltage, and tube current used in MDCT were 1 mm, 120 kVp, and 200 mAs, respectively. Meanwhile, the imaging parameters used in extremity CBCT were 60 kVp and 2 mA.

Imaging technique and analysis

Twenty-nine adult patients with various wrist bone injuries were imaged using the protocols available at the DCBCT scan. The distribution of patients was 21 males (72.4%) and 8 females (27.5%) aged 18-49 (mean 28 ± 8.2) years. Ten patients were scanned with low-dose protocols, ten with medium-dose protocols, and the rest with high-dose protocols. Types of fractures that were diagnosed using DCBCT are shown in table 1. This study obtained ethical approval from the local institutional review committees (RC number: 2023-0245); all patients gave their permission and volunteered willingly. The DCBCT parameters were optimized based on the best image quality with the lowest radiation dose compared to those obtained from an MDCT scan and extremity CBCT. Two consultant radiologists with a combined experience of more than ten years assessed the image quality obtained using DCBCT for wrist bones. The images

produced with various scanning parameters were examined.

Table 1. Types of fracture diagnosed using DCBCT.

Location of fracture	Number of cases
Scaphoid	5
Distal radius	10
Distal ulna	3
Trapezium	5
Hamate	1
Trapezoid	3
Capitate	2

To differentiate between image quality according to the parameters used and whether they are diagnosable, each reader was blinded from another reader. The reader submitted their scores to an impartial judge using a 5-point Likert scale (score 1: Insufficient image quality, score 2: Poor image quality, score 3: Moderate image quality, score 4: Good image quality, and score 5: Excellent image quality). The use of the Likert scale method by raters enables a more thorough analysis of the image quality that is relevant to the clinical routine. SPSS software v.29 was used to calculate the 95% confidence intervals (CI) and kappa coefficient for interrater agreement. The diagnostic confidence of all raters was assessed using a paired *t*-test.

RESULTS

The averaged measured DLP for DCBCT from the lowest to the highest imaging parameters were found to be 44.67 (95% CI 4.65 to 4.69), 69.75 (95% CI 69.7 to 69.8), and 127.7 (95% CI 128 to 128) mGy/cm, respectively. The average measured DLP for MDCT was 169.3 (95% CI 169 to 169) mGy/cm. The average DLP measured from extremity CBCT was 33.3 (95% CI 33.2 to 33.4) mGy/cm. The extremity CBCT has shown the lowest radiation dose compared to DCBCT and MDCT. In contrast, the MDCT has shown the highest radiation dose. The relative percent difference (RD) calculated between the lowest radiation dose obtained using DCBCT with that measured using extremity CBCT and MDCT was 29.1% and 116.4 %, respectively. While, RD between the highest radiation dose of DCBCT with other modalities was 117.2 % and 28%, respectively. The mean diagnostic confidence on the 5-point Likert scale for the high-dose technique DCBCT for rater 1 and 2 were 4.83 and 4.9, respectively. Meanwhile, the mean confidence for raters using medium- and low-dose techniques were 4.76 and 4.64, respectively (table 2). The percentage agreement between overall readers was 85.4 %. Kappa denoting interobserver agreement was 0.9 indicating almost perfect level of agreement. The carpal bone was scanned using DCBCT with different settings, as shown in figures 1 and 2. The optimized scanning parameters were 70 kV, 2 mA, and 15 seconds. This protocol showed a

very good image quality with the lowest radiation dose compared to a higher dose DCBCT. There was a significant improvement in lowering radiation dose in DCBCT while maintaining optimum image quality.

Table 2. The mean confidence values for medium and low dose technique.

	Low dose technique		Medium dose technique	
	Rater 1	Rater 2	Rater 1	Rater 2
Mean	4.62	4.66	4.69	4.83
Medium	5	5	5	5
min	3	3	3	4
max	5	5	5	5

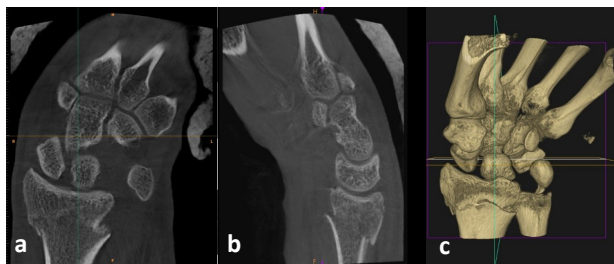


Figure 1. Dental CBCT images of an adult patient with a splint: **a.** coronal view, **b.** sagittal view, and **c.** 3D imaging scanned with high radiation dose protocol.

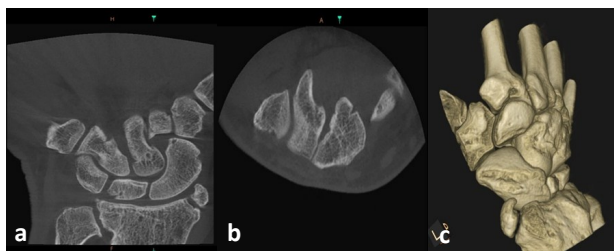


Figure 2. Dental CBCT images of an adult patient: **a.** coronal image, **b.** axial image and **c.** 3D imaging scanned with a low radiation dose technique.

DISCUSSION

The best imaging modality for suspected wrist injury depends on several factors: diagnostic ability, availability, cost, and radiation dose. It is critical to adopt imaging modalities that offer accurate diagnostic information while reducing radiation exposure to the greatest extent feasible with the lowest cost. In the case of wrist fractures, conventional X-rays are often the first imaging technique used, but they can miss the diagnosis of an undisplaced fracture. On the other hand, MDCT is a dependable tool for defining wrist injury diagnosis; however, it is associated with high radiation doses (11). While extremity CBCT has shown an excellent ability to diagnose wrist fractures with the lowest radiation dose (5). However, the main factor preventing this technology's spread was the lack of availability in some countries particularly non-developed countries. Therefore, this study aimed to assess the ability of DCBCT after optimizing imaging protocol as an alternative method to detect wrist

fractures.

The present study found that the examination protocol in DCBCT can be optimized to achieve good image quality while using a lower radiation dose than in MDCT, and is comparable to that in extremity CBCT. The DCBCT and extremity CBCT have shown a lower radiation dose compared to MDCT. This is consistent with a previous review by Posadzy *et al.* (15) who concluded that CBCT technology has a lower radiation dose compared to MDCT due to the acquisition procedure, field of view size, and the use of a flat detector. It was also found even with applying a high radiation dose technique DCBCT still has a lower radiation dose compared to MDCT. This is consistent with other studies indicating that DCBCT has a lower radiation dose compared to MDCT (16,17). In contrast, our finding showed that using the lowest imaging protocol in DCBCT, it was difficult to achieve a lower radiation dose than that obtained from extremity CBCT. This is attributed to the type of extremity CBCT used in the study and X-ray examination parameters, this finding is supported by Koivisto *et al.* (10) which noticed a difference in the output of effective dose according to the extremity CBCT device used for imaging.

It was found that DCBCT can be considered an alternative, viable imaging approach for wrist imaging which is similar to a study by Borel *et al.* (13) who suggested that the DCBCT could be used as a diagnosis tool for occult scaphoid. They have found that dental CBCT proved more effective than radiography for detecting occult cortical fractures in the carpus. Good overall image quality was achieved using low-dose protocols for DCBCT, which is critical to minimize the potential risks associated with radiation exposure. The optimized scanning parameters were 70 kV, 2 mA, and 15 seconds. Notably, DCBCT provides substantially good fracture detection, even at a lower dosage (Figure 2). DCBCT also achieved a high capacity to detect cortical bone and articulation surfaces with minimal artifacts, as it offers superior spatial resolution to MDCT. This result is in line with a study by Borel *et al.* (13) who concluded that DCBCT allows high-contrast features like bone to be better depicted. It is important to note that DCBCT could be used in place of MDCT to detect bone fractures, as it can produce a three-dimensional image similar to other devices. However, it has been observed that DCBCT is not as effective as MDCT in detecting joint diseases, tumors, and histological diseases, due to its low contrast-to-noise ratio. Pauwels *et al.* (18) have reported this matter and concluded that there are notable differences in noise, contrast resolution, and spatial resolution between DCBCT and MDCT equipment. This issue has been reported also by Zamani *et al.* (19) stated that DCBCT equipment is typically only useful for viewing high-contrast structures.

From another perspective, the price of the DCBCT

image in the area where research has been conducted does not exceed \$50, which includes the extremity CBCT image, but the price of examination of an MDCT device may reach \$130. Hence, DCBCT is considered more cost-effective than MDCT for imaging applications, since it is smaller, cheaper, and emits less radiation than MDCT systems. The simplified technological design of CBCT scanners may lead to cheaper manufacturing and maintenance costs⁽²⁰⁾. Additionally, DCBCT scanners are often easier and quicker to learn. This is a crucial factor in promoting the use of this technology for diagnosing wrist bone fractures.

The study's findings provide a feasible technique for improving the DCBCT imaging routine as a diagnostic tool for wrist bone fractures. However, there are certain limits to this analysis. First, the study utilized a single system, so the findings may not be directly comparable to those of other vendors. Future studies should add the scanner types and their effect dependency into their results. Second, the DCBCT approach has a longer acquisition time than MDCT, making it more susceptible to movement artifacts. As a result, we had to stabilize the arm to reduce movement artifacts. Finally, a larger field of view is recommended to cover more areas in wrist imaging.

CONCLUSION

This study highlights the potential for optimizing the DCBCT imaging protocol as a valuable diagnostic tool for wrist bone fractures while minimizing the potential risks associated with radiation exposure.

Funding: None.

Ethical consideration: The study complied fully with the ethical standards and norms set out by the regional institutional review committees (RC number: 2023-0245).

Conflicts of Interest: The authors declare no conflict of interest.

Authors' Contribution: M.A. conceived the idea. M.A., A.Q., and N.O. gathered the images and related literature. M.A. and A.Q. carried out the method implementation. M.A., Y.A., M.Z., and M.F. carried out results and analysis. All the authors read, modified, and approved the final version of the manuscript.

REFERENCES

1. Bäcker HC, Wu CH, Strauch RJ (2020) Systematic Review of Diagnosis of Clinically Suspected Scaphoid Fractures. *J Wrist Surg*, **9** (1): 81-9.

2. Balci A, Basara I, Çekdemir EY, et al. (2015) Wrist fractures: sensitivity of radiography, prevalence, and patterns in MDCT. *Emerg Radiol*, **22** (3): 251-6.
3. Gibney B, Smith M, Moughty A, et al. (2019) Incorporating Cone-Beam CT Into the Diagnostic Algorithm for Suspected Radiocarpal Fractures: A New Standard of Care? *AJR Am J Roentgenol*, **213** (5): 1117-23.
4. Ludlow JB (2018) Hand-wrist, knee, and foot-ankle dosimetry and image quality measurements of a novel extremity imaging unit providing CBCT and 2D imaging options. *Med Phys*, **45** (11): 4955-63.
5. Murphy MC, Gibney B, Walsh J, et al. (2022) Ultra-low-dose cone-beam CT compared to standard dose in the assessment for acute fractures. *Skeletal Radiol*, **51** (1): 153-9.
6. Ragab H, Abdelaziz DM, Khalil MM, et al. (2023) Assessment of image quality of two cone-beam computed tomography of the Varian Linear accelerators: Comparison with spiral CT simulator. *International Journal of Radiation Research*, **21** (3): 491-7.
7. Grassi R, Guerra E, Berritto D (2023) Bone fractures difficult to recognize in emergency: May be cone beam computed tomography (CBCT) the solution? *Radiol Med*, **128** (1): 1-5.
8. Edlund R, Skorpil M, Lapidus G, et al. (2016) Cone-Beam CT in diagnosis of scaphoid fractures. *Skeletal Radiol*, **45** (2): 197-204.
9. Neubauer J, Benndorf M, Ehrlich-Braun C, et al. (2018) Comparison of the diagnostic accuracy of cone beam computed tomography and radiography for scaphoid fractures. *Sci Rep*, **8** (1): 3906.
10. Koivisto J, van Eijnatten M, Kiljunen T, et al. (2018) Effective radiation dose in the wrist resulting from a radiographic device, two cbct devices and one msct device: A comparative study. *Radiat Prot Dosimetry*, **179** (1): 58-68.
11. Pallaver A, Honigsmann P (2019) The role of cone-beam computed tomography (CBCT) scan for detection and follow-up of traumatic wrist pathologies. *J Hand Surg Am*, **44** (12): 1081-7.
12. Ferreira Branco D, Bouvet C, Hamard M, et al. (2022) Reliability of radio-ulnar and carpal alignment measurements in the wrist between radiographs and 3D imaging. *Eur J Radiol*, **154**: 110417.
13. Borel C, Larbi A, Delclaux S, et al. (2017) Diagnostic value of cone beam computed tomography (CBCT) in occult scaphoid and wrist fractures. *Eur J Radiol*, **97**: 59-64.
14. Hafezi L, Divband D, Deevband MR (2021) New method to organ dose assessment in cone-beam computed tomography using ImPACT software. *International Journal of Radiation Research*, **19** (4): 1049-53.
15. Posadzy M, Desimpel J, Vanhoenacker F (2018) Cone beam CT of the musculoskeletal system: clinical applications. *Insights Imaging*, **9** (1): 35-45.
16. Hashimoto K, Arai Y, Iwai K, et al. (2003) A comparison of a new limited cone beam computed tomography machine for dental use with a multidetector row helical CT machine. *Oral Surg Oral Med Oral Pathol Oral Radiol Endod*, **95** (3): 371-7.
17. Hashimoto K, Kawashima S, Araki M, et al. (2006) Comparison of image performance between cone-beam computed tomography for dental use and four-row multidetector helical CT. *J Oral Sci*, **48** (1): 27-34.
18. Pauwels R, Beinsberger J, Stamatakis H, et al. (2012) Comparison of spatial and contrast resolution for cone-beam computed tomography scanners. *Oral Surg Oral Med Oral Pathol Oral Radiol*, **114** (1): 127-35.
19. Zamani H, Falahati F, Omid R, et al. (2020) Estimating and comparing the radiation cancer risk from cone-beam computed tomography and panoramic radiography in pediatric and adult patients. *International Journal of Radiation Research*, **18** (4): 885-93.
20. Kaasalainen T, Ekholm M, Siiskonen T, et al. (2021) Dental cone beam CT: An updated review. *Phys Med*, **88**: 193-217.