

# Accuracy evaluation of digital mammography and its combination with magnetic resonance imaging in the diagnosis of ductal carcinoma in situ

R. Lin\*, G. Xiao, W. Xiu, S. Cai

Department of Radiology, Shengli Clinical Medical College of Fujian Medical University, Fujian Provincial Hospital, Fuzhou 350001, Fujian Province, China

## ABSTRACT

### ► Original article

#### \*Corresponding author:

Ruiying Lin, M.D.

E-mail: Linruiying@mjc-edu.cn

Received: May 2023

Final revised: December 2024

Accepted: January 2025

Int. J. Radiat. Res., July 2025;  
23(3): 707-713

DOI: 10.61186/ijrr.23.3.27

**Keywords:** Ductal carcinoma in situ, mammography, magnetic resonance imaging, sensitivity, specificity, diagnostic accuracy.

**Background:** It aimed to compare the efficacy of digital mammography and magnetic resonance imaging (MRI) used alone and in combination in the diagnosis of ductal carcinoma in situ (DCIS). **Material and Methods:** 78 patients with pathologically confirmed DCIS were enrolled in this retrospective study. All patients underwent digital mammography and MRI. The imaging results were graded using the Breast Imaging Reporting and Data System (BI-RADS), and the diagnostic sensitivity (Sen), specificity (Spe), and accuracy (Acc) of the two methods, both individually and in combination, were calculated. **Results:** imaging findings were classified as highly suspicious (BI-RADS grade 4 and above) or not highly suspicious (BI-RADS grade 3 and below). The Sen, Spe, and Acc of digital mammography in the diagnosis of DCIS were 68.97%, 60%, and 66.67%, respectively. The Sen, Spe, and Acc of MRI were 77.5%, 70%, and 75.64%, respectively. When the two techniques were combined, the Sen was increased to 87.93%, the Spe was 75%, and the Acc was 84.62%. There were visible distinctions in Sen and Acc between the combined use and single mammography detection ( $P < 0.05$ ). **Conclusion:** the combined use of digital mammography and MRI shows high Sen and Acc in the diagnosis of DCIS, which is more effective than single method. This article supports the use of multimodal diagnostic strategies in clinical practice to improve the diagnostic efficiency of DCIS.

## INTRODUCTION

Ductal carcinoma in situ (DCIS) is a form of breast cancer (BC) confined to the ducts of the breast, without invasion through the duct wall into surrounding normal tissues. As an early stage of BC, it is the type most detected by modern screening techniques<sup>(1,2)</sup>. Due to its non-invasive nature, DCIS is sometimes referred to as “grade 0” or “stage in situ” BC. A key characteristic of DCIS is the presence of microcalcifications-small calcium deposits that can act as potential markers of carcinogenesis<sup>(3-5)</sup>. In addition to microcalcifications, DCIS may present as an irregular mass or thickening within the breast duct, although these signs are less common than microcalcifications<sup>(6)</sup>. The risk factors for DCIS are similar to those for invasive BC, including increasing age, early menarche, late menopause, a family history of breast or ovarian cancer, and long-term use of hormone replacement therapy. Genetic factors, such as mutations in the Breast Cancer 1 (BRCA1) and Breast Cancer 2 (BRCA2) genes, are also implicated. While not all cases of DCIS progress to invasive cancer, prompt diagnosis and treatment are essential,

as a proportion of DCIS lesions may eventually develop into invasive BC<sup>(7-9)</sup>.

Imaging plays a key role in BC screening and diagnosis, especially in the detection and evaluation of DCIS. Conventional mammography, the standard method of BC screening, is effective in detecting microcalcifications and masses. However, it has low sensitivity (Sen) in dense breast tissue and may miss small or dense cancers<sup>(10,11)</sup>. The advantages of ultrasound are that it is non-invasive, non-radiative, and effective in distinguishing cystic from solid masses. However, ultrasound has limited ability to detect microcalcification, which is a key indicator of DCIS, and it is highly operator-dependent<sup>(12-14)</sup>. Digital breast tomosynthesis (DBT) can provide three-dimensional images of the breast, and this multi-layer image can reduce the image misunderstanding caused by tissue overlap. Although it represents an improvement over traditional mammography, digital mammography may still miss small lesions in high-density breast tissue<sup>(15-17)</sup>. Mammography is a specialized form of breast imaging that uses molybdenum as the target material for the X-ray source, providing high-contrast images that are

particularly effective for low-density breasts. It is also capable of detecting microcalcifications in the breast, which is crucial for the detection of DCIS<sup>(18,19)</sup>. MRI, on the other hand, utilizes magnetic fields and radio waves to produce detailed *in vivo* images. It offers high-resolution cross-sectional images of breast tissue and plays a critical role in detecting and characterizing the spread of breast cancer<sup>(20,21)</sup>. Breast MRI can also show the exact location and size of the tumor. Due to its high Sen, it is very suitable for detecting early BC and assessing the spread of known cancers. It can clearly show the structural changes in the breast, especially in high-density breast tissue.

Digital mammography and MRI each have distinct advantages in breast cancer detection, particularly in the identification of DCIS. Digital mammography is well-suited for detecting microcalcifications, whereas MRI excels at delineating tumor boundaries and the internal structure of breast tissue. In clinical practice, the combined use of these two modalities holds significant value, enhancing diagnostic accuracy (Acc) and comprehensiveness, thus aiding clinicians in formulating more precise diagnoses and treatment plans. Compared to existing literature, this study offers a novel perspective by comparing the diagnostic performance of digital mammography and MRI, both individually and in combination, for DCIS detection. Specifically, this study directly compared the Sen, specificity (Spe), and Acc of these two imaging techniques, further elucidating the potential of multimodal imaging strategies in improving the early diagnosis of DCIS. Moreover, this research provides the first in-depth exploration of the synergistic benefits of combining these two imaging techniques, an aspect that has not been fully addressed in current literature, thereby contributing new evidence to the field of breast cancer diagnosis.

## MATERIALS AND METHODS

### Study subjects

The study subjects included 78 female patients diagnosed with DCIS by pathological examination at Fujian Provincial Hospital from 2022 to 2024. The clinical data of all patients were fully preserved. The ages of the patients ranged from 26 to 55 years, with a mean age of  $40.2 \pm 2.5$  years.

Inclusion criteria: female patients who met the diagnostic criteria for DCIS and were pathologically confirmed as having DCIS; age  $\geq 18$  years, with the ability to provide independent consent; digital mammography and MRI performed prior to surgery, with clear imaging results; complete clinical and pathological data available for retrospective analysis.

Exclusion criteria: patients with progression to invasive breast cancer; patients who received neoadjuvant chemotherapy or endocrine therapy prior to surgery; patients with other severe

complications or major diseases; patients without complete clinical or pathological data.

### Digital mammography examination process

SELENIA Dimensions digital molybdenum rhodium dual target mammography machine produced by HOLOGIC (U.S) was used. This device combines the Picture Archiving and Communication System (G.E, USA) and the mammography film printer (Carestream, Canada) for image processing and printing. The system allows multiple angles to be taken, including craniocaudal views, medial and lateral views, and supplemented with lateral or tangential views as needed, as well as magnifying photography. The patient was placed in a standing position with both breasts fully exposed. Mammography was used to take craniocaudal view, medial and lateral view of bilateral breasts, and lateral or tangential view and magnifying view were taken when necessary to observe the details clearly. For patients with nipple discharge, breast ductography was performed to provide detailed visualization of the breast ducts. The image acquisition parameters were set as tube voltage 120kV, matrix  $256 \times 256$ , energy peak 140 keV, and window width 20%. The dual-phase method was used to evaluate the dynamic characteristics of the tumor. First, an image of the neck was acquired for 500,000 counts to obtain the early phase. Subsequently, a second image was acquired using the same protocol for the delayed phase. All the scanning results were uploaded to the workstation, and the data were processed by Dr. Wise software (Deepwise Medical, China). The weight of the tumor was calculated using the ShineFly Cloud Intelligence Image 3D workstation (Philips, Netherlands), and the shape and boundaries of the tumor, such as round or oval translucent areas, were further analyzed. The results of the examination were documented in detail, including the location, extent, shape, margin, internal calcification, gland density, nipple and skin condition, and axillary lymph nodes.

### Procedure of MRI examination

A 3.0T MAGNETOM Prisma MRI machine was used, manufactured by Siemens (Germany). The patient should wear appropriate medical clothing and remove all metal objects prior to the MRI. Bilateral breast positioning scan was performed, and the scanning area accurately covered both breasts. Transverse T1WI images were acquired with SE sequence and then axial fat-suppressed T2WI images were obtained by adjusting to STIR sequence. The high contrast of T2WI was used to examine water molecules and pathological tissues. The FLASH fast small angle excitation sequence was used for 3D dynamic contrast-enhanced scanning. Gd-DTPA (0.2 mmol/kg) (12 mL:5.63 g, Beijing Beilu Pharmaceutical Co., LTD., H20013088) was used as

the contrast agent, and the drug was intravenously injected. The location, range, shape, edge, and enhancement characteristics of the lesions were observed and recorded in detail. The time-signal intensity curve (TIC) was analyzed, and the possible nature of the lesions was judged according to the changes of signal enhancement patterns (continuous rise type, plateau type, and clearance type). The results of MRI and mammography were compared and analyzed, and the results of the two examinations were integrated to improve the diagnostic Acc.

### Observation and evaluation indicators

(1) Application of BI-RADS <sup>(22)</sup>: this study used BI-RADS to evaluate the diagnostic effect of digital mammography and MRI. A BI-RADS grade greater than 4 was defined as DCIS with a high possibility of malignancy, and further diagnostic measures were recommended (table 1).

**Table 1.** BI-RADS grading system.

Grading	Description
Grade 0	The current imaging information is not enough to make a complete assessment, and more imaging data or comparison with previous imaging is needed to complete the diagnosis.
Grade 1	Imaging studies does not reveal any abnormalities and the breast structure is normal.
Grade 2	Determined harmless structures are observed, such as simple cysts, stable fibroadenomas, lymph nodes, postoperative changes. Annual routine examinations are recommended.
Grade 3	The abnormalities have benign features with a very low risk of malignancy (<2%). Short-term follow-up is recommended to monitor changes, commonly in typical fibroadenomas or complex cysts.
Grade 4	
4A	Lowly suspicious, biopsy is recommended, and if the result is benign, routine or half-year follow-up can be continued.
4B	Moderately suspicious, complex cystic or poorly demarcated structures, biopsy or surgery is recommended.
4C	Highly suspicious, with irregular structure or infiltrative margins, a detailed biopsy is recommended.
Grade 5	High-degree suggestion of malignancy (>95%), with irregular shape and unclear boundary. Hyperechoic halos and surrounding structural changes are common. Clinical treatment is recommended.
Grade 6	Breast lesions that have been confirmed to be malignant by biopsy. Appropriate treatment measures should be taken immediately.

(2) Diagnostic efficacy indicators, including the Sen, Spe, and Acc of digital mammography and MRI alone or in combination in the diagnosis of DCIS, were calculated. Sen: the proportion of DCIS patients who could be correctly identified. Spe: the proportion of non-DCIS patients who could be correctly identified. Acc: the proportion of overall correct diagnosis.

(3) Analysis of image characteristics: the image characteristics of digital mammography and MRI were observed and recorded in detail, including the

location, shape, edge definition, and internal structure of the lesion.

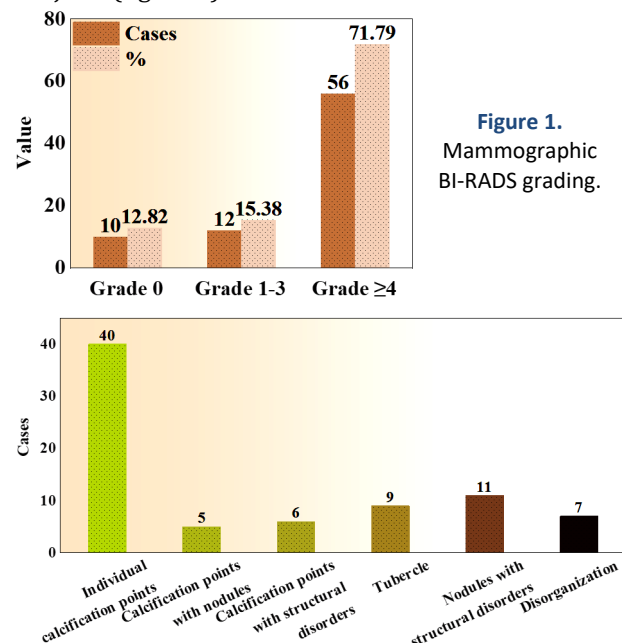
### Statistical analysis

SPSS 24.0 (IBM, USA) was employed. Measurement data were presented as mean  $\pm$  SD ( $\bar{x} \pm s$ ), and count data were statistically inferred by  $\chi^2$  test. Measurement data were in accordance with normal distribution, and  $t$  test was adopted.  $P < 0.05$  was considered statistically meaningful.

## RESULTS

### Digital mammographic findings of DCIS

Ten subjects (12.82%) had incomplete information and were categorized as grade 0. Twelve subjects (15.38%) showed no obvious abnormalities or were considered benign lesions, classified as BI-RADS grades 1 to 3. Most subjects, 56 (71.79%), exhibited highly suspicious malignant signs, which were rated as grade 4 or higher (figure 1). Solitary calcifications were observed in 40 subjects, while 5 subjects had calcifications accompanied by nodules, and 6 subjects had calcifications associated with structural abnormalities. Additionally, 9 subjects exhibited solitary nodules, 11 subjects showed nodules with structural abnormalities, and 7 subjects had structural abnormalities alone. The characteristic dense microcalcifications were observed in 49 subjects (figure 2).



**Figure 2.** Mammographic findings.

### MRI findings of DCIS

Eleven cases (14.10%) had incomplete information and were classified as grade 0. The vast majority, 67 cases (85.90%), exhibited highly suspicious malignant features, which were rated as grade 4 or higher (figure 3). Among the specific MRI

findings, 50 cases demonstrated non-mass-like enhancement, 13 cases showed simple nodules, and 15 cases exhibited nodules with ductal dilatation. TIC analysis revealed that 19 cases exhibited a continuous rising pattern, 41 cases demonstrated a plateau pattern, and 18 cases showed a clearance pattern, reflecting the distinct dynamic characteristics of the lesions (figure 4).

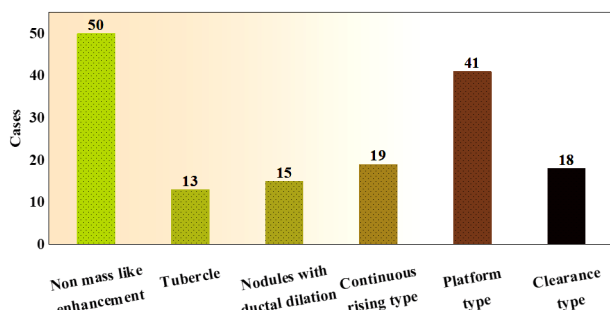
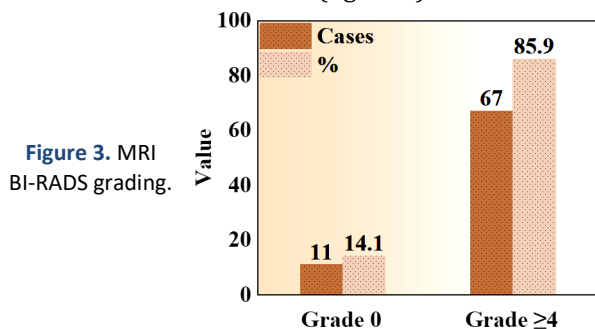


Figure 4. Mammographic images and TIC manifestations.

### Diagnosis of benign and malignant lesions

All 78 DCIS patient had a single lesion, including 41 malignant lesions and 37 benign lesions. The diameter, resistance index (RI), and elastic strain ratio of malignant lesions were higher than those of benign lesions ( $P < 0.05$ ) (figure 5).

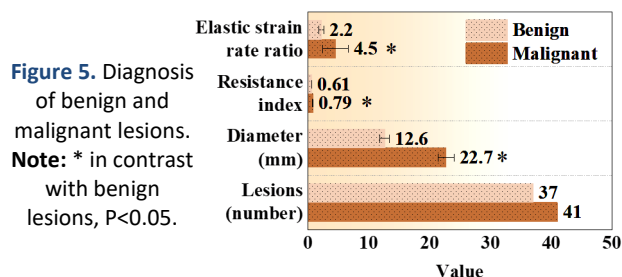


Figure 5. Diagnosis of benign and malignant lesions.  
Note: \* in contrast with benign lesions,  $P < 0.05$ .

### Diagnostic efficacy analysis

Table 2 presents the Sen, Spe, and Acc of digital mammography, MRI, and combined detection in diagnosing DCIS. The Sen, Spe, and Acc of digital mammography for diagnosing DCIS were 68.97% (40/58), 60% (12/20), and 66.67% (52/78), respectively. For MRI, these values were 77.5% (45/58), 70% (14/20), and 75.64% (59/78), respectively. Combined detection demonstrated a Sen of 87.93% (51/58), Spe of 75% (15/20), and Acc of 84.62% (66/78).

Table 2. Diagnostic efficacy analysis.

	Pathological diagnosis		Total
	Positive	Negative	
<b>Digital mammography</b>			
Positive	40	8	48
Negative	18	12	30
Total	58	20	78
<b>MRI</b>			
Positive	45	6	51
Negative	13	14	27
Total	58	20	78
<b>Combined test</b>			
Positive	51	5	56
Negative	7	15	22
Total	58	20	78

Note: MRI: magnetic resonance imaging.

Table 3 compares the Sen, Spe, and Acc of standalone imaging methods (digital mammography or MRI) with the combined detection approach. The combined detection method greatly improved Sen versus standalone digital mammography ( $P = 0.013$ ). However, neglectable difference in Sen was observed between standalone MRI and the combined detection method ( $P = 0.140$ ). Neither standalone digital mammography ( $P = 0.311$ ) nor standalone MRI ( $P = 0.723$ ) showed substantial differences in Spe when compared to the combined detection method. The combined detection method also demonstrated a marked advantage in Acc, with a notable improvement versus standalone digital mammography ( $P = 0.009$ ). However, neglectable difference in Acc was found between standalone MRI and the combined detection method ( $P = 0.160$ ).

Table 3. Contrast of single and combined detection.

Indicators	Method	Value
Sen	$C^2$ mammography and combined detection	6.170
	$P$ mammography and combined detection	0.013 *
	$C^2$ MRI and combined detection	2.175
	$P$ MRI and combined detection	0.140
Spe	$C^2$ mammography and combined detection	1.026
	$P$ mammography and combined detection	0.311
	$C^2$ MRI and combined detection	0.125
	$P$ MRI and combined detection	0.723
Acc	$C^2$ mammography and combined detection	6.819
	$P$ mammography and combined detection	0.009 *
	$C^2$ MRI and combined detection	1.973
	$P$ MRI and combined detection	0.160

Note: \*  $P < 0.05$ ; Sen: sensitivity; Spe: specificity; Acc: accuracy.

## DISCUSSION

DCIS is a precursor lesion of breast cancer. Although its prognosis is generally favorable, early diagnosis is crucial for determining an appropriate treatment plan. Digital mammography and MRI are



currently the two primary imaging modalities used for diagnosing DCIS in clinical practice<sup>(23, 24)</sup>. However, each method has inherent limitations, and thus, combined detection may offer more comprehensive diagnostic information. This study aims to evaluate the diagnostic performance of digital mammography, MRI, and their combination in diagnosing DCIS, and to compare these methods with existing clinical practices. The results indicated that standalone digital mammography demonstrates moderate Sen (68.97%) and Acc (66.67%) in diagnosing DCIS. These findings are consistent with those reported in the literature<sup>(25)</sup>. Numerous studies have shown that mammography offers certain advantages for detecting DCIS, particularly in identifying small calcifications. However, due to the diverse imaging features of DCIS, single mammography may fail to comprehensively capture the characteristics of the lesion, especially when calcifications are absent or other structural changes are present, which can reduce its Sen<sup>(26)</sup>. MRI, on the other hand, shows superior performance in diagnosing DCIS, with a Sen of 77.5% and an Acc of 75.64%. These results align with previous studies, as MRI provides more accurate soft tissue imaging of the breast, especially for DCIS lesions that present as nodules without obvious calcifications, where MRI demonstrates higher Sen. Furthermore, MRI, through dynamic contrast-enhanced imaging, provides superior visualization of tumor vasculature, which is crucial for assessing the nature of the lesion. Combined detection demonstrated a markedly better diagnostic performance versus standalone imaging modalities. The Sen (87.93%), Spe (75%), and Acc (84.62%) of combined detection were all notably superior to those of standalone digital mammography and MRI. This finding further corroborates the advantage of combined imaging in enhancing the Acc of early breast disease diagnosis. Digital mammography excels in detecting small calcifications, while MRI offers detailed soft tissue imaging. Together, these modalities provide a more comprehensive evaluation of breast lesions<sup>(27)</sup>. Therefore, combined detection greatly improves the diagnostic Sen for DCIS, enabling earlier identification of potential malignant lesions.

The study by Zhao *et al.* (2021) aimed to develop a model for breast cancer diagnosis by integrating dynamic contrast-enhanced MRI (DCE-MRI) and mammographic radiomic features<sup>(28)</sup>. Feature selection and model construction were performed using support vector machines (SVM), and the performance of standalone MRI, mammography, and the combination of both was compared across training and test datasets. The results showed that the Acc of standalone DCE-MRI was 83.2%, while combining MRI and mammography increased the Acc to 89.6%. In an independent test dataset, the Acc of

DCE-MRI was 78.8%, while the combination of MRI and mammography achieved an Acc of 83.3%. The combination of MRI and mammography notably improved Spe, increasing it from 69.6% to 82.1%. This study found a great difference in Sen between standalone mammography and combined detection ( $P < 0.05$ ), indicating that combined detection markedly enhances the early diagnostic capability of DCIS. These findings are consistent with the results of Zhao *et al.*, where the Sen advantage of combined detection primarily stems from the high Sen of mammography to small calcifications and the excellent diagnostic capability of MRI in detecting masses and infiltration. However, in terms of Spe, the differences between standalone mammography and MRI versus combined detection did not reach statistical significance ( $P > 0.05$ ). This suggests that although combined detection offers superior Sen, it does not markedly enhance the ability to exclude non-DCIS lesions (*i.e.*, Spe). This finding implies that while combined detection improves Sen, it may also lead to an increased rate of false positives, particularly when the imaging features of benign lesions such as fibroadenomas or other benign conditions resemble those of DCIS<sup>(29)</sup>. In terms of Acc, the advantage of combined detection was also significant, especially when compared to standalone mammography ( $P = 0.009$ ), further validating the value of combined detection in improving diagnostic precision. However, no significant difference was observed between standalone MRI and combined detection ( $P = 0.160$ ), suggesting that, given the high Sen of MRI, the additional benefit of combined detection in terms of Acc is relatively limited<sup>(30)</sup>.

In terms of imaging features, the BI-RADS scores for digital mammography were predominantly categorized as 4 or above, indicating its ability to effectively identify high-risk lesions<sup>(30)</sup>. In particular, the presence of calcifications often suggests potential malignant changes, which is consistent with the findings of this study. The BI-RADS scores for MRI also primarily fell within the 4 or above range, with most lesions exhibiting non-mass enhancement or nodules with associated ductal dilation, features that are highly characteristic of DCIS. Through TIC analysis, we also observed distinct signal variation patterns at different time points, which could assist in further distinguishing the nature and stage of the lesions<sup>(31, 32)</sup>. In the diagnosis of benign versus malignant lesions, this study found that the diameter, resistance index, and elastic strain ratio of malignant lesions were notably superior to those of benign lesions. This suggests that these imaging characteristics have high reference value in differentiating benign from malignant lesions. For clinicians, these imaging indicators can serve as supplementary criteria, further enhancing the diagnostic Acc for DCIS.

## CONCLUSION

A total of 78 patients with DCIS were examined by digital mammography and MRI, and the effectiveness of these two imaging techniques in the diagnosis of DCIS was verified. Although MRI alone performed better than mammography in terms of Sen, Spe, and Acc, the combination of the two imaging techniques could markedly improve the diagnostic Sen and Acc. In particular, the combined detection suggested visible advantages in improving the Spe and reducing the misdiagnosis rate. A limited number of patients may have affected the generalization of the results. A larger sample may provide more data to support the current findings. In addition, as a retrospective study, the design of this article may be subject to selection bias and review bias, and future studies could overcome these limitations by having a prospective design. It is recommended to consider the combination of digital mammography and MRI in the diagnosis of DCIS. Future studies should expand the sample size and have a prospective design.

**Ethics approval and consent to participate:** This study had been approved by the Ethics Committee of Fujian Provincial Hospital (Approval No. FPH021, Approval Date: 2023.3.,10).

**Consent to participate:** Not applicable.

**Data availability statement:** The original contributions presented in the study are included in the article.

**Conflict of interest:** The authors declare that there are no conflicts of financial interest.

**Funding:** The authors declare that this study received no financial funding.

**Author contributions:** R.L., was responsible for the overall design of the study, data analysis, manuscript writing, and revisions, ensuring the overall quality and academic rigor of the research. G.X., contributed to data collection and analysis, particularly providing significant input in the processing of imaging data and diagnostic efficacy analysis, and assisted with manuscript writing and revisions. W.X., primarily handled patient data organization and analysis, participated in experimental design and research method optimization, and provided academic support for manuscript writing. S.C., contributed to the research design and data collection, particularly playing a key role in MRI imaging technical support and data processing, and assisted with manuscript revision and editing. All authors were involved in the conceptualization and implementation of the research, and jointly reviewed the final version of the manuscript to ensure the accuracy and completeness of the content.

## REFERENCES

1. Knowlton CA, Jimenez RB, Moran MS (2022) DCIS: risk assessment

- in the molecular era. *Seminars in Radiation Oncology*, **32**(3): 189-197.
2. Farante G, Toesca A, Magnoni F, Lissidini G, Vila J, Mastropasqua M, et al. (2022) Advances and controversies in management of breast ductal carcinoma in situ (DCIS). *European Journal of Surgical Oncology*, **48**(4): 736-741.
3. Ma T, Semsarian CR, Barratt A, Parker L, Pathmanathan N, Nickel B, Bell KJL (2023) Should low-risk DCIS lose the cancer label? An evidence review. *Br Can Res Treat*, **199**(3): 415-433.
4. Hayward MK and Weaver VM (2021) Improving DCIS diagnosis and predictive outcome by applying artificial intelligence. *Biochimica et Biophysica acta. Reviews on Cancer*, **1876**(1): 188555(1-11).
5. Pinder SE, Thompson AM, Wesserling J (2022) Low-risk DCIS. What is it? Observe or excise? *Virchows Archiv*, **480**(1): 21-32.
6. Petrone I, Santos ECD, Binato R, Abdelhay E (2023) Epigenetic alterations in DCIS progression: what can lncRNAs teach Us? *Int'l J Mol Sci*, **24**(10): 8733(1-16).
7. Yamamoto K, Matsumoto H, Matsumoto S, Sakai R, Kitao A, Watanabe M (2023) Unexpected appearance of KMT2A: MLLT10 fusion transcript in acute myeloid leukemia with t(5;11)(q31;q23.3). *Cancer Genetics*, **272-273**: 41-46.
8. Tang G, Li S, Toruner GA, Jain P, Tang Z, Hu S, et al. (2023) Clinical impact of 5'MYC or 3'MYC gain/loss detected by FISH in patients with aggressive B-cell lymphomas. *Cancer Genetics*, **272-273**: 1-8.
9. Narod SA and Sopik V (2022) Countercurrents: DCIS or cancer? Why all the confusion? *Current Oncology*, **29**(7): 4936-4940.
10. Elder K, Matheson J, Nickson C, Box G, Ellis J, Mou A, et al. (2023) Contrast enhanced mammography in breast cancer surveillance. *Br Can Res Treat*, **199**(2): 221-230.
11. Grimm LJ, Neely B, Hou R, Selvakumaran V, Baker JA, Yoon SC, et al. (2021) Mixed-methods study to predict upstaging of DCIS to invasive disease on mammography. *AJR. American Journal of Roentgenology*, **216**(4): 903-911.
12. Shi J, Chen L, Wang B, Zhang H, Xu L, Ye J, Liu Y, Shao Y, Sun X, Zou Y (2023) Diagnostic value of ultrasound elastography in the differentiation of breast invasive ductal carcinoma and ductal carcinoma in situ. *Current Medical Imaging*, **19**(3): 286-291.
13. Ban K, Tsunoda H, Watanabe T, Kaoku S, Yamaguchi T, Ueno E, Hirokaga K, Tanaka K (2020) Characteristics of ultrasonographic images of ductal carcinoma in situ with abnormalities of the ducts. *Journal of Medical Ultrasonics (2001)*, **47**(1): 107-115.
14. Gao L, Lai X, Zhang J, Jiang Y, Li J (2023) Sonographic prediction of intraductal papillary carcinoma with partially cystic breast lesions. *BMC Medical Imaging*, **23**(1): 3(1-7).
15. Comstock CE, Gatsonis C, Newstead GM, Snyder BS, Gareen IF, Bergin JT, et al. (2020) Comparison of abbreviated breast MRI vs digital breast tomosynthesis for breast cancer detection among women with dense breasts undergoing screening. *JAMA*, **323**(8): 746-756.
16. Bernardi D, Gentilini MA, De Nisi M, Pellegrini M, Fantò C, Valentini M, et al. (2020) Effect of implementing digital breast tomosynthesis (DBT) instead of mammography on population screening outcomes including interval cancer rates: Results of the Trento DBT pilot evaluation. *Breast*, **50**: 135-140.
17. Liu H and Weng J (2022) A comprehensive bioinformatic analysis of cyclin-dependent kinase 2 (CDK2) in glioma. *Gene*, **822**: 146325(1-15).
18. Jochelson MS and Lobbes MBI (2021) Contrast-enhanced mammography: state of the art. *Radiology*, **299**(1): 36-48.
19. Sechopoulos I, Teuwen J, Mann R (2021) Artificial intelligence for breast cancer detection in mammography and digital breast tomosynthesis: state of the art. *Seminars in Cancer Biology*, **72**: 214-225.
20. Bartram A, Gilbert F, Thompson A, Mann GB, Agrawal A (2021) Breast MRI in DCIS size estimation, breast-conserving surgery and oncoplastic breast surgery. *Cancer Treatment Reviews*, **94**: 102158(1-7).
21. Greenwood HI, Wilmes LJ, Kelil T, Joe BN (2020) Role of breast MRI in the evaluation and detection of DCIS: opportunities and challenges. *Journal of Magnetic Resonance Imaging*, **52**(3): 697-709.
22. Shankar PR, Davenport MS, Helvie MA (2020) Prostate MRI and quality: lessons learned from breast imaging rad-path correlation. *Abdom Radiol (NY)*, **45**(12): 4028-4030.
23. Reig B, Kim E, Chhor CM, Moy L, Lewin AA, Heacock L (2023) Problem-solving breast MRI. *Radiographics*, **43**(10): e230026(1-16).
24. Yamaguchi R, Watanabe H, Mihara Y, Yamaguchi M, Tanaka M (2023) Histopathology of non-mass-like breast lesions on ultrasound. *Journal of Medical Ultrasonics (2001)*, **50**(3): 375-380.
25. Liu Z, Yao B, Wen J, Wang M, Ren Y, Chen Y, et al. (2024) Voxel-wise mapping of DCE-MRI time-intensity-curve profiles enables visualiz-

- ing and quantifying hemodynamic heterogeneity in breast lesions. *European Radiology*, **34**(1): 182-192.
26. Gong X, Yuan S, Xiang Y, Fan L, Zhou H (2023) Domain knowledge-guided adversarial adaptive fusion of hybrid breast ultrasound data. *Computers in Biology and Medicine*, **164**: 107256(1-13).
  27. Saadatmand S, Geuzinge HA, Rutgers EJT, Mann RM, de Roy van Zuidewijn DBW, Zonderland HM, et al.; FaMRIsC study group (2019) MRI versus mammography for breast cancer screening in women with familial risk (FaMRIsC): a multicentre, randomized, controlled trial. *The Lancet Oncology*, **20**(8): 1136-1147.
  28. Zhao YF, Chen Z, Zhang Y, Zhou J, Chen JH, Lee KE, et al. (2021) Diagnosis of breast cancer using radiomics models built based on dynamic contrast enhanced MRI combined with mammography. *Frontiers in Oncology*, **11**: 774248(1-11).
  29. Liu H and Li Y (2022) Potential roles of cornichon family AMPA receptor auxiliary protein 4 (CNIH4) in head and neck squamous cell carcinoma. *Cancer Biomarkers: Section A of Disease Markers*, **35**(4): 439-450.
  30. Panigrahi B, Fernandes K, Mullen LA, Oluyemi E, Myers KS, Philip M, Carlo PD, Ambinder EB (2023) Solitary Dilated Ducts Revisited: Malignancy Rate and Implications for Management. *Acad Radiol*, **30**(5): 807-813.
  31. Zhou J, Li M, Liu D, Sheng F, Cai J (2023) Differential Diagnosis of Benign and Malignant Breast Papillary Neoplasms on MRI With Non-mass Enhancement. *Acad Radiol*, **30** (Suppl 2): S127-S132.
  32. Meurs CJC, van Rosmalen J, Menke-Pluijmers MBE, Siesling S, Westenend PJ (2023) Predicting lymph node metastases in patients with biopsy-proven ductal carcinoma in situ of the breast: development and validation of the DCIS-met model. *Ann Surg Oncol*, **30**(4): 2142-2151.

