

Preoperative assessment of gastric cancer using multi-slice spiral ct perfusion imaging: A study of its diagnostic value

F. Peng¹, J. Song^{2#}, Y. Zhang^{3#}, Q. Peng^{4*}

¹Department of Radiology, Beijing Luhe Hospital, Capital Medical University, Beijing, China

²Department of Radiology, the Second Affiliated Hospital Of Hainan Medical University, Hainan Haikou 570311, China

³Department of Breast Armor Surgery, the Second Affiliated Hospital Of Hainan Medical University Hainan Haikou 570311, China

⁴Large aperture CT room, Shandong Cancer Hospital, Jinan City, Shandong Province, 250117 China

► Original article

ABSTRACT

*Corresponding author:

Qingguo Peng, M.D.

E-mail: jack6558@163.com

Received: March 2025

Final revised: May 2025

Accepted: May 2025

Int. J. Radiat. Res., October 2025;
23(4): 889-894

DOI: 10.61186/ijrr.23.4.8

Keywords: Stomach neoplasms, multidetector computed tomography, perfusion imaging, preoperative period, neoplasm staging, hemodynamics.

#Co-authors: These authors contributed equally to this work.

Background: Globally, gastric cancer (GC) continues to be a primary driver of cancer deaths, as delayed diagnoses frequently lead to unfavorable clinical outcomes. Accurate preoperative assessment is critical for optimizing treatment strategies and enhancing patient outcomes. This research analyzed the preoperative evaluation value of multi-slice spiral computed tomography (MSCT) perfusion imaging in GC. **Material and Methods:** A cohort of 112 GC patients was recruited between January 2022 and April 2024 for quantification of MSCT perfusion metrics, including blood flow (BF), blood volume (BV), permeability surface (PS), and mean transit time (MTT). **Results:** Advanced-stage GC exhibited significantly higher BF, BV, and PS than early-stage disease ($P<0.05$). TNM stage progression (Ia+Ib \rightarrow III+IIIIa \rightarrow III+IV) correlated with increasing BF, BV, and PS ($P<0.05$), while tumor location showed no significant parameter differences. Well-differentiated tumors had higher BF and PS but lower MTT than poorly differentiated cases ($P<0.05$). Patients without lymph node metastasis (LNM) or distant metastasis demonstrated reduced perfusion parameters, with BF and PS being statistically lower in non-metastatic groups ($P<0.05$). **Conclusion:** These findings suggest that MSCT perfusion imaging effectively reflects hemodynamic changes and provides valuable insights into tumor staging, differentiation, and metastasis, supporting its clinical utility in preoperative GC evaluation.

INTRODUCTION

Gastric cancer (GC) is a common digestive system malignancy that poses a certain threat to patients' health despite a reduced risk of morbidity and mortality ^(1, 2). According to statistics, GC ranks fifth in terms of prevalence globally and is a major cause of cancer-related deaths in humans, with nearly 50 percent of new cases occurring in China ⁽³⁾. In China, there are approximately 820000 new GC cases and nearly 600,000 associated deaths each year, with a 5-year survival rate of less than 20% ^(4, 5). The prognosis of GC patients is unsatisfactory, mainly due to delayed diagnosis, limited medical resources, and the need to improve medical technology ^(6, 7). Surgery remains the major treatment modality for GC patients ⁽⁸⁾, and accurate preoperative evaluation (clinical staging, differentiation degree, lymph node metastasis [LNM], distant metastasis, etc.) is of great clinical significance for improving patient outcomes and ensuring the full play of surgical efficacy.

Multi-slice spiral computed tomography (MSCT) utilizes rapid spiral scanning technology that delivers excellent spatial resolution and is equipped with

advanced post-processing capabilities. It has thin-slice and volumetric scanning functions and can realize the visualization of lesions and their surrounding affected lumens or organs through multiplanar reconstruction ⁽⁹⁾. This technique has been applied to a certain extent in GC staging, with high accuracy in diagnosing depth of invasion, peripheral organ infiltration, and LNM ^(10, 11). However, this technology is not so ideal for the display of perfusion. MSCT perfusion imaging is a functional imaging approach for blood flow based on MSCT, which can indirectly reveal the blood perfusion and help determine the blood supply of lesions. In the study of Hao R *et al.* ⁽¹²⁾, MSCT perfusion imaging applied to elderly individuals with severe acute pancreatitis (SAP) helped predict the risk of peripancreatic infection. This technique is also effective in predicting the risk of recurrence in individuals undergoing surgery for early-stage GC ⁽¹³⁾.

The current research on the preoperative evaluation value of MSCT perfusion imaging for GC patients is relatively limited. Accordingly, this study analyzes the correlation of the performance of various MSCT perfusion imaging parameters with the

preoperative clinicopathological characteristics of GC patients. This study provides three novel contributions: (1) A systematic correlation between MSCT perfusion parameters (BF, BV, PS, MTT) and clinicopathological features (differentiation, TNM stage, metastasis) in GC, offering a comprehensive preoperative assessment tool. (2) Identification of PS as the most sensitive parameter for distinguishing advanced and metastatic GC, highlighting its underexplored role in tumor vascular permeability. (3) Discovery of an inverse hemodynamic pattern (higher BF/PS but lower MTT in well-differentiated GC), challenging conventional perfusion models. These findings advance MSCT perfusion imaging as a functional biomarker for personalized GC management.

MATERIALS AND METHODS

General data

The hospital's Ethics Committee has granted approval for this research (Approval Number: 2024023). First, we selected 112 GC patients who visited our hospital between January 2022 and April 2024. Inclusion criteria: All patients underwent pathological examination by gastroscopy and met the GC diagnostic criteria⁽¹⁴⁾, with no mental illness or cognitive dysfunction, complete clinical data, and a life expectancy >3 months. Exclusion criteria: Contraindications to MSCT perfusion imaging; non-initial treatment; serious cardiovascular, lung, brain, and kidney dysfunction; other malignancies; contagious diseases or blood disorders.

Imaging methods

Scanning was performed using Philips Brilliance 64-slice spiral CT (Royal Philips, Amsterdam, the Netherlands). Details can be seen in Figure 1. All subjects underwent a 6-hour fasting before scanning. Prior to examination, the patient removed metal foreign bodies and drank 800 mL of water within half an hour to fill the stomach cavity. Then, the patient lay flat on the scanning bed in the supine position, with 20 mg of anisodamine hydrochloride (Minsheng Pharmaceutical, Hangzhou, China) injected 15 min before scanning. Routine CT plain scans were first performed on the subject to observe the level of GC lesion and use it as the target level for MSCT perfusion imaging. Then, 80 mL of iohexol (Tianrui Pharmaceutical, Zhejiang, China) was administered via the elbow vein at an injection rate of 5.0 mL/s for contrast-enhanced scanning. The parameters for scanning were: 120 kV for the voltage, 200 mAs for the tube current, 5.0 mm for both the scanning layer thickness and the reconstruction layer thickness, and 1.0 for the pitch. Following scanning, the original images were processed by the CTPerfusion 4 analysis software of the ADW 4.4 workstation, with 0-140 as the threshold and the abdominal aorta as the input

artery, to generate the region of interest (ROI) time-density curves of the abdominal aorta. Then, the ROI was placed in the parenchyma of the GC lesion, the blood perfusion parameters of the tumor were measured and recorded, and parameters such as BF, BV, PS, and MTT of the contrast agent were obtained.

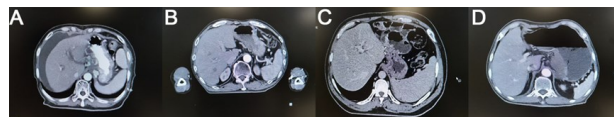


Figure 1. MSCT imaging results. **A.** Case 1, female, 59 years old, gastric malignant tumor. **B.** Case 2, male, 61 years old, gastric malignant tumor. **C.** Case 3, female, 54 years old, gastric malignant tumor. **D.** Case 4, male, 79 years old, gastric malignant tumor.

Endpoints

The relationship between MSCT perfusion parameters (BV, BF, PS, and MTT) and tumor differentiation, LNM, distant metastasis, tumor growth site, and TNM stage of GC patients was analyzed. The clinical stages of all patients were recorded, which were mainly divided into early and advanced (middle and late) stages. Using the staging criteria set by the American Joint Committee on Cancer (AJCC), the TNM staging was determined as Ia+Ib, III+IIla, or III+IV⁽¹⁵⁾. Tumor growth sites include gastric antrum-pylorus, body, and fundus-cardia. The differentiation of tumors (low or high) was also recorded in all patients.

Statistical methods

This study used statistical software SPSS 20.0 (IBM Corporation, Armonk, NY, USA) for data analysis. Categorical and continuous data are represented by cases (percentage) (n (%)) and mean \pm SEM, respectively. The χ^2 test and independent samples t-test were utilized for the comparison of categorical and continuous data, respectively. When comparing continuous data across multiple groups, one-way ANOVA was employed. A statistical significance level of $P < 0.05$ was adopted for all analyses.

RESULTS

Cohort data of 112 GC patients

The mean age of the 112 GC patients was (62.76 \pm 8.82) years, including 81 males and 31 females, with an average weight of (60.59 \pm 10.25) kg; most of them were in the advanced stage (58.04%), with stage III+IV GC (38.39%), the tumor located in the gastric antrum-pylorus (43.77), high differentiation (66.96%), and the presence of LNM (74.11%), and distant metastasis (60.71%) (table 1).

MSCT perfusion parameters of GC individuals at different clinical stages

Advanced-stage GC exhibited markedly elevated perfusion parameters as opposed to early-stage disease. BF increased from 68.11 \pm 8.87 mL/100g/min

(early) to 83.18 ± 29.52 mL/100g/min (advanced) ($P=0.003$), reflecting heightened tumor vascularity in aggressive disease. BV rose from 8.06 ± 3.99 mL/100g to 10.32 ± 4.89 mL/100g ($P=0.022$), suggesting increased vascular recruitment. PS surged from 26.70 ± 9.40 mL/100g/min to 35.71 ± 9.50 mL/100g/min ($P<0.001$), indicative of vascular hyperpermeability in advanced tumors. MTT remained unchanged (9.79 ± 3.47 s vs. 11.15 ± 5.22 s, $P=0.312$), implying preserved vascular efficiency despite disease progression (figure 2). These trends highlight perfusion imaging's sensitivity to tumor angiogenesis and vascular remodeling.

Table 1. Cohort data of 112 gastric cancer individuals.

Indicators	n=112
Age (years)	62.76±8.82
Sex	
Male	81 (72.32)
Female	31 (27.68)
Weight (kg)	60.59±10.25
Clinical staging	
Early stage	47 (41.96)
Advanced stage	65 (58.04)
TNM staging	
Ia+Ib	30 (26.79)
III+IIIa	39 (34.82)
III+IV	43 (38.39)
Tumor site	
Gastric antrum-pylorus	49 (43.75)
Gastric body	37 (33.04)
Gastric fundus-cardia	26 (23.21)
Differentiation degree	
Low	37 (33.04)
High	75 (66.96)
Lymph node metastasis	83 (74.11)
Distant metastasis	68 (60.71)

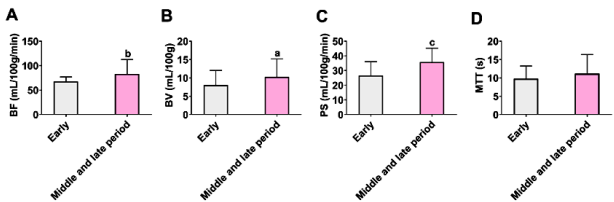


Figure 2. MSCT perfusion parameters of GC individuals at different clinical stages. **A.** Blood flow (BF) at different clinical stages. **B.** Blood volume (BV) at different clinical stages. **C.** Permeability surface (PS) at different clinical stages. **D.** Mean transit time (MTT) at different clinical stages. Note: a $P<0.05$, b $P<0.01$, and c $P<0.001$ vs. early GC patients.

MSCT perfusion parameters of GC individuals at different TNM stages

Perfusion parameters escalated progressively with TNM staging. Stage III+IV tumors demonstrated remarkably higher BF (92.45 ± 33.21 mL/100g/min) than Ia+Ib (65.12 ± 7.84 mL/100g/min, $P<0.01$) and III+IIIa (78.33 ± 24.56 mL/100g/min, $P<0.05$) groups. BV and PS followed similar patterns: BV in stage III+IV (12.89 ± 5.01 mL/100g) exceeded Ia+Ib (8.20 ± 3.45 mL/100g, $P<0.01$) and III+IIIa (9.97 ± 4.12 mL/100g, $P<0.05$), while PS peaked at 38.50 ± 8.92 mL/100g/min in stage III+IV versus 25.31 ± 8.76

mL/100g/min in Ia+Ib ($P<0.001$). MTT remained stable across stages ($P>0.05$) (figure 3). These findings correlate TNM progression with escalating vascular activity, emphasizing perfusion imaging's role in staging precision.

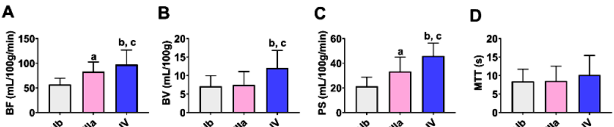


Figure 3. MSCT perfusion parameters of gastric cancer (GC) individuals at different TNM stages. **A.** Blood flow (BF) at different TNM stages. **B.** Blood volume (BV) at different TNM stages. **C.** Permeability surface (PS) at different TNM stages. **D.** Mean transit time (MTT) at different TNM stages. Note: a $P<0.05$ and b $P<0.01$ versus Ia+Ib; c $P<0.05$ versus III+IIIa.

MSCT perfusion parameters at different tumor sites in GC patients

No noteworthy differences in BF, BV, PS, or MTT were observed across tumor locations (antrum-pylorus, body, fundus-cardia) ($P>0.05$) (figure 4). This suggests tumor hemodynamics are independent of anatomical site, potentially simplifying imaging protocols for diverse GC subtypes.

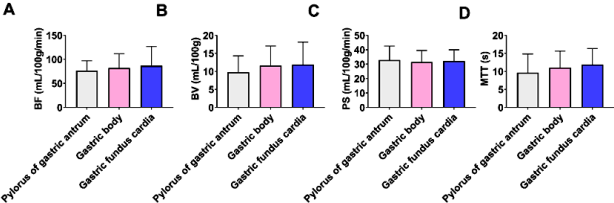


Figure 4. MSCT perfusion parameters at different tumor sites in gastric cancer (GC) patients. **A.** Blood flow (BF) at different tumor sites in GC patients. **B.** Blood volume (BV) at different tumor sites in GC patients. **C.** Permeability surface (PS) at different tumor sites in GC patients. **D.** Mean transit time (MTT) at different tumor sites in GC patients.

MSCT perfusion parameters of GC patients with different differentiation degrees

Well-differentiated tumors exhibited distinct hemodynamic profiles: BF (102.01 ± 34.76 mL/100g/min vs. 76.92 ± 20.50 mL/100g/min, $P=0.002$) and PS (34.59 ± 11.43 mL/100g/min vs. 29.59 ± 10.15 mL/100g/min, $P=0.014$) were elevated as opposed to poorly differentiated tumors, while MTT was reduced (9.68 ± 4.89 s vs. 11.73 ± 5.25 s, $P=0.027$) (figure 5). Paradoxically, higher perfusion in well-differentiated tumors may reflect preserved vascular architecture, contrasting with chaotic angiogenesis in aggressive subtypes.

MSCT perfusion parameters in GC patients with or without LNM

Non-metastatic patients ($n=29$) demonstrated substantially lower PS (27.10 ± 9.51 mL/100g/min vs. 37.99 ± 9.91 mL/100g/min, $P<0.001$) and BV (8.21 ± 4.26 mL/100g vs. 12.16 ± 4.77 mL/100g, $P<0.001$) in relative to LNM-positive cases ($n=83$). BF and MTT showed no remarkable differences ($P>0.05$) (figure 6). Reduced PS and BV in non-metastatic tumors may reflect diminished vascular permeability and

recruitment, aligning with restrained metastatic potential.

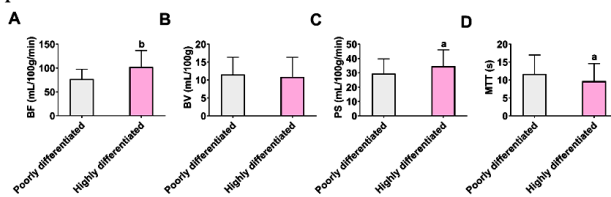


Figure 5. MSCT perfusion parameters in gastric cancer (GC) individuals with different differentiation degrees. **A.** Blood flow (BF) in GC individuals with different differentiation degrees. **B.** Blood volume (BV) in GC individuals with different differentiation degrees. **C.** Permeability surface (PS) in GC patients' different differentiation degrees. **D.** Mean transit time (MTT) in GC patients with different differentiation degrees. Note: aP<0.05 and bP<0.01 versus patients with poorly differentiated GC.

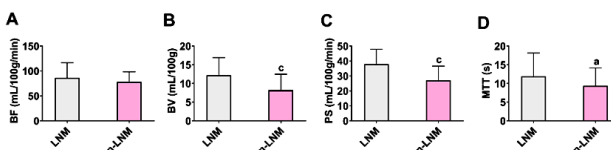


Figure 6. MSCT perfusion parameters in gastric cancer (GC) individuals with or without lymph node metastasis (LNM). **A.** Blood flow (BF) in GC individuals with and without LNM. **B.** Blood volume (BV) in GC individuals with and without LNM. **C.** Permeability surface (PS) in GC individuals with and without LNM. **D.** Mean transit time (MTT) in GC individuals with and without LNM. Note: aP<0.05 and cP<0.001 vs. GC patients with LNM.

MSCT perfusion parameters in GC patients with or without distant metastasis

Non-metastatic patients (n=44) displayed lower BF (78.00 ± 31.37 mL/100g/min vs. 94.16 ± 34.09 mL/100g/min, $P=0.031$) and PS (30.43 ± 12.10 mL/100g/min vs. 39.37 ± 6.23 mL/100g/min, $P<0.001$) as opposed to metastatic cases (n=68). BV and MTT remained comparable ($P>0.05$) (figure 7). The pronounced PS reduction in non-metastatic tumors underscores its utility in identifying indolent disease, potentially guiding therapeutic decisions.

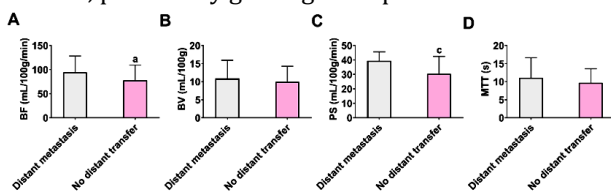


Figure 6. MSCT perfusion parameters in gastric cancer (GC) individuals with or without lymph node metastasis (LNM). **A.** Blood flow (BF) in GC individuals with and without LNM. **B.** Blood volume (BV) in GC individuals with and without LNM. **C.** Permeability surface (PS) in GC individuals with and without LNM. **D.** Mean transit time (MTT) in GC individuals with and without LNM. Note: aP<0.05 and cP<0.001 vs. GC patients with LNM.

DISCUSSION

The pathogenesis of GC is multifactorial, involving genetic, environmental, and infectious factors (e.g., *Helicobacter pylori* infection) (16). Early-stage GC has

inconspicuous symptoms, some of which overlap with the clinical presentations of chronic gastric diseases, which can easily lead to misdiagnosis and missed diagnosis, resulting in the miss of the optimal treatment timing and an adverse prognosis (17, 18). Therefore, it is necessary to optimize the preoperative evaluation of GC individuals.

Many researchers have made academic contributions to the preoperative evaluation of GC patients. For example, Dong *et al.* (19) found that a nomogram based on CT phenotypes and Lauren classification demonstrates excellent predictive power for undetected peritoneal metastasis in advanced GC individuals. As reported by Gao *et al.* (20), the application of preoperative white light endoscopy and magnification endoscopy in the preoperative assessment of endoscopic submucosal dissection in early-stage GC individuals is helpful in accurately judging the information such as lesion type, lesion scope, and infiltration depth, which is conducive to improving the complete resection rate and reducing the risk of re-operation. In our research results, BF, BV, and PS were distinctly higher in individuals with advanced GC than in those with early-stage GC. The manifestations of MSCT perfusion parameters in patients with Ia+Ib, III+IIla, and III+IV GC increased as the TNM stage elevated, among which BF and PS showed significant differences in the above stages, while GC patients at stage III+IV had significantly higher BV than those at stage Ia+Ib or III+IIla. None of the four MSCT perfusion parameters were substantially linked with different tumor sites in GC individuals.

Compared with individuals with poorly differentiated GC, BF and PS were statistically up-regulated, while MTT was markedly down-regulated in patients with well-differentiated GC. In addition to BF, the values of BV, PS, and MTT were substantially diminished in GC individuals without LNM. In the research of Li *et al.* (21), MSCT perfusion imaging could indirectly mirror the angiogenesis process of esophageal cancer, in which PS was notably lower in esophageal cancer patients without LNM than in those with LNM, which is similar to our findings. BF and PS were also statistically down-regulated in GC patients without distant metastasis. Among the above MSCT perfusion parameters, PS performed the best. This may be related to the great difference between tumor vessels and normal vessels in terms of vascular wall structural integrity. If the vascular wall structure is intact, the gap between cells will be relatively larger, leading to increased permeability (22, 23). This is followed by BF and BV. This could be explained by the fact that tumor growth and metastasis are inseparable from the blood supply, and BF and BV are also associated with changes as tumor invasion progresses (24, 25). Many previous studies have indicated the clinical value of MSCT perfusion imaging in tumors. As reported by Feng *et al.* (26), MSCT

perfusion imaging for portal vein tumor thrombosis helps evaluate the antiangiogenic effect of Endostar and provides quantitative functional information. In the study of Xu *et al.* ⁽²⁷⁾, MSCT perfusion imaging parameters such as BF, BV, and PS could help screen patients with breast cancer and benign breast tumors, with certain potential for qualitative diagnosis of breast lesions and breast cancer. Cao *et al.* ⁽²⁸⁾ also pointed out that MSCT perfusion imaging has certain evaluation value in the treatment of liver tumors with high-intensity focused ultrasound, assisting in obtaining quantitative information on tumor vascularity and angiogenesis.

This study is not without limitations. First, the single-center design and modest cohort size (n=112) limit generalizability, particularly for rare subgroups. Second, the cross-sectional design precludes assessment of perfusion parameters' prognostic value. Longitudinal studies tracking postoperative results are needed to establish causality. Third, while we standardized imaging protocols, variations in contrast injection timing or cardiac output could influence perfusion measurements. Emerging technologies like AI-driven motion correction may mitigate such confounders. Finally, the lack of molecular subtyping (e.g., HER2, EBV status) hinders exploration of biological heterogeneity in hemodynamic profiles. Given the genomic diversity of GC, future studies should integrate molecular data to stratify perfusion patterns by subtype.

CONCLUSION

In summary, MSCT perfusion imaging can reflect the hemodynamic changes of GC patients and has potential clinical value for the preoperative evaluation of GC patients. To a certain extent, it can help determine pathological information such as the clinical staging, TNM staging, differentiation degree, LNM, and distant metastasis of GC patients.

Ethics approval and consent to participate: This study recruited 112 gastric cancer (GC) patients who visited our hospital during the period from January 2022 to April 2024. The hospital's ethics committee gave its approval (Approval Number: 2024023) for the research.

Competing interests: No conflict of interest exists.

Acknowledgements: Not applicable.

Author contributions: F.P., J.S. and Y.Z. contributed equally. F.P. was responsible for the conceptualization and design of the study, oversaw the data collection process, and carried out the CT perfusion analysis. J.S. and Y.Z. managed patient enrollment, collected clinical data, and drafted the manuscript. Q.P. provided critical revisions, oversaw the project, and served as corresponding author. All authors contributed to data interpretation, manuscript revisions, and approved the final version.

Funding: Chongqing Science and Technology Plan Project (123456).

REFERENCES

- Xu R, Chen XD, Ding Z (2022) Perioperative nutrition management for gastric cancer. *Nutrition*, **93**: 111492.
- Jaroenlapnopparat A, Bhatia K, Coban S (2022) Inflammation and gastric cancer. *Diseases*, **10**(3): 35.
- Zhang Y and Yu J (2020) The role of MRI in the diagnosis and treatment of gastric cancer. *Diagn Interv Radiol*. **26**(3): 176-182.
- Ferlay J, Colombet M, Soerjomataram I, *et al.* (2021) Cancer statistics for the year 2020: An overview. *Int J Cancer*, **149**(4): 778-789.
- Ilic M and Ilic I (2022) Epidemiology of stomach cancer. *World J Gastroenterol*, **28**(12): 1187-1203.
- Gao H, Wan Y, Fan X, *et al.* (2021) The Role of cholinesterase in differential diagnosis between gastric cancer and benign gastric diseases. *Clin Lab*, **67**(2): 200525.
- Li Y, Hu X, Lin R, *et al.* (2022) Single-cell landscape reveals active cell subtypes and their interaction in the tumor microenvironment of gastric cancer. *Theranostics*, **12**(8): 3818-3833.
- López Sala P, Leturia Etxeberria M, Inchausti Iguñiz E, *et al.* (2023) Gastric adenocarcinoma: A review of the TNM classification system and ways of spreading. *Radiologia (Engl Ed)*, **65**(1): 66-80.
- Huang W, Wang L, Ye H (2024) Study on the application of multislice spiral CT in the diagnosis and evaluation of radiotherapy efficacy for esophageal cancer. *International Journal of Radiation Research*, **22**(4): 823-829.
- Zhao S, Bi Y, Wang Z, *et al.* (2022) Accuracy evaluation of combining gastroscopy, multi-slice spiral CT, Her-2, and tumor markers in gastric cancer staging diagnosis. *World J Surg Oncol*, **20**(1): 152.
- Liu W, Li Y, Zhang X, *et al.* (2022) Preoperative T and N restaging of rectal cancer after neoadjuvant chemoradiotherapy: An accuracy comparison between MSCT and MRI. *Front Oncol*, **11**: 806749.
- Hao R, Sun Y, Hu Y (2024) A comprehensive study on the diagnostic value of multi-slice computed tomography for peripancreatic infection in elderly with severe acute pancreatitis. *Gastroenterology Res*, **17**(2): 82-89.
- Li CF, Wang DP, Xue YW (2018) Evaluation of a multi-slice spiral computed tomography perfusion for the prediction of the recurrence of gastric cancer. *Future Oncol*, **14**(19): 1953-1963.
- Ajani JA, D'Amico TA, Bentrem DJ, *et al.* (2022) Gastric cancer, Version 2.2022, NCCN Clinical Practice Guidelines in Oncology. *J Natl Compr Canc Netw*, **20**(2): 167-192.
- Mlanda GM, Xue Y, Zhou XG, *et al.* (2022) Revisiting the 8th AJCC system for gastric cancer: A review on validations, nomograms, lymph nodes impact, and proposed modifications. *Ann Med Surg (Lond)*, **75**: 103411.
- Yang WJ, Zhao HP, Yu Y, *et al.* (2022) Updates on global epidemiology, risk and prognostic factors of gastric cancer. *World J Gastroenterol*, **29**(16): 2452-2468.
- Ugai T, Sasamoto N, Lee HY, *et al.* Is early-onset cancer an emerging global epidemic? Current evidence and future implications. *Nat Rev Clin Oncol*, **19**(10): 656-673.
- Liu X, Wang X and Mao T, *et al.* (2023) Characteristic analysis of early gastric cancer after Helicobacter pylori eradication: a multicenter retrospective propensity score-matched study. *Ann Med*, **55**(1): 2231852.
- Dong D, Tang La, Li ZY, *et al.* (2019) Development and validation of an individualized nomogram to identify occult peritoneal metastasis in patients with advanced gastric cancer. *Ann Oncol*, **30**(3): 431-438.
- Gao YL, Zhang YH, Cao M (2022) Preoperative evaluation of endoscopic submucosal dissection for early gastric cancer. *Medicine (Baltimore)*, **101**(37): e30582.
- Li Q, Cui D, Feng Y, *et al.* (2021) Correlation between microvessel density (MVD) and multi-spiral CT (MSCT) perfusion parameters of esophageal cancer lesions and the diagnostic value of combined CtBP2 and P16. *J Gastrointest Oncol*, **12**(3): 981-990.
- Wautier JL and Wautier MP (2022) Vascular permeability in diseases. *Int J Mol Sci*, **23**(7): 3645.
- Steeg PS (2021) The blood-tumor barrier in cancer biology and therapy. *Nat Rev Clin Oncol*, **18**(11): 696-714.
- Kanugula AK, Adapala RK, Jamiyar A, *et al.* (2021) Endothelial TRPV4 channels prevent tumor growth and metastasis via

- modulation of tumor angiogenesis and vascular integrity. *Angiogenesis*, **24(3)**: 647-656.
25. Majidpoor J and Mortezaee K (2021) Steps in metastasis: an updated review. *Med Oncol*, **38(1)**: 3.
26. Feng G, Lei Z, Wang D, *et al.* (2014) The evaluation of anti-angiogenic effects of Endostar on rabbit VX2 portal vein tumor thrombus using perfusion MSCT. *Cancer Imaging*, **14(1)**: 17.
27. Xu N, Lei Z, Li XL, *et al.* (2013) Clinical study of tumor angiogenesis and perfusion imaging using multi-slice spiral computed tomography for breast cancer. *Asian Pac J Cancer Prev*. **14(1)**: 429-33.
28. Cao X and Jiang X (2013) Evaluating the effect of high-intensity focused ultrasound therapy on liver tumors using multislice CT perfusion. *Oncol Lett*, **5(2)**: 511-514.