

# Ultrasound-guided paravertebral nerve block for pain management in pediatric patients undergoing radiotherapy for mediastinal tumors

Y. Lin<sup>1</sup>, T-F. Qu<sup>2\*</sup>, S. Li<sup>3</sup>, J-U Xu<sup>2</sup>, H-Q. Jin<sup>4</sup>

<sup>1</sup>Department of Anesthesiology, Baoding Hospital of Beijing Children's Hospital, Capital Medical University, Baoding, China

<sup>2</sup>Department of Anesthesiology, Baoding No.2 Central Hospital, Baoding, China

<sup>3</sup>Operating Room, Baoding No.2 Central Hospital, Baoding, China

<sup>4</sup>Department of Operation and Anaesthesia, Baoding Hospital of Beijing Children's Hospital, Capital Medical University, Baoding, China

## ABSTRACT

### ► Original article

#### \*Corresponding author:

Tianfang Qu, M.D.,

E-mail: qu520twin@163.com

Received: July 2025

Final revised: August 2025

Accepted: October 2025

Int. J. Radiat. Res., January 2026;  
24(1): 199-204

DOI: 10.61186/ijrr.24.1.30

**Keywords:** Radiotherapy, Mediastinal Neoplasms, Pain Management, Ultrasonography, Pediatric Patients.

**Background:** To evaluate the effectiveness of ultrasound-guided paravertebral nerve block (PVB) in reducing radiotherapy-associated pain in pediatric patients with mediastinal tumors. **Materials and Methods:** Thirty children (ages 1-16) receiving radiotherapy after mediastinal tumor surgery were randomly assigned to two groups: control (routine analgesia, n=15) and observation (ultrasound-guided PVB, n=15). Radiotherapy was delivered to the mediastinal region using conventional fractionated external beam protocols (2 Gy per fraction, total dose 40-60 Gy). Pain intensity was assessed by Visual Analogue Scale (VAS) at 0-, 12-, 24-, and 48-hours post-radiotherapy. Analgesic consumption, time to first rescue analgesic, incidence of radiotherapy-related side effects (skin irritation, fatigue), recovery time, and adverse reactions were compared between groups. **Results:** The observation group had significantly lower VAS scores at all time points compared to controls ( $p < 0.05$ ). Time to first rescue analgesic was longer ( $7.61 \pm 0.64$  vs.  $4.35 \pm 0.52$  h,  $p < 0.01$ ), and overall analgesic use was reduced in the PVB group ( $p < 0.05$ ). Radiotherapy-related side effects, including skin irritation (13.3% vs. 40%) and fatigue (26.6% vs. 53.3%), were less frequent in the PVB group ( $p < 0.05$ ). Recovery outcomes were also improved, with shorter ICU stays and earlier resumption of daily activities ( $p < 0.05$ ). **Conclusion:** Ultrasound-guided PVB is an effective adjunct for managing radiotherapy-induced pain in pediatric mediastinal tumor patients. It reduces pain scores, prolongs analgesia, lowers radiotherapy-related side effects, and accelerates recovery, providing a safer and more effective approach to pediatric pain management.

## INTRODUCTION

Mediastinal tumors in children encompass a wide range of malignancies, including lymphomas, germ cell tumors, and thymic lesions. Because of their anatomical location, these tumors often involve or compress vital structures such as the heart, trachea, esophagus, and major blood vessels, making both treatment and supportive care particularly challenging<sup>(1-3)</sup>. Pain control is a central aspect of clinical management in these patients. Effective analgesia not only improves comfort but also enhances treatment compliance, facilitates recovery, and reduces psychological distress, which is especially important in pediatric patients. Radiotherapy is an integral component of treatment for mediastinal tumors. While highly effective in tumor control, radiotherapy is associated with a range of acute and late complications, among which pain is one of the most common and distressing. Acute radiation-related pain may arise from

inflammatory reactions in the skin and mucosa, esophagitis, or nerve irritation in the mediastinal region. In the longer term, fibrosis and neuropathic pain can develop, further complicating recovery. Children are particularly vulnerable to these effects because of their heightened pain sensitivity and their difficulty in expressing or localizing discomfort<sup>(4-6)</sup>. If inadequately managed, radiotherapy-induced pain can interfere with nutritional intake, limit mobility, and lead to interruptions in therapy, ultimately compromising treatment outcomes. Conventional analgesic regimens rely heavily on systemic opioids and nonsteroidal anti-inflammatory drugs (NSAIDs). While opioids are effective, their use in children is constrained by side effects such as nausea, vomiting, respiratory depression, and the risk of dependence. Similarly, NSAIDs and acetaminophen may provide only partial relief and are limited by gastrointestinal or renal toxicity when used repeatedly<sup>(7)</sup>. Pediatric pharmacokinetics further complicate dosing and heighten the risk of adverse

reactions. Consequently, the need for safe, effective, and minimally invasive alternatives for managing radiotherapy-related pain in children remains unmet. Regional anesthesia techniques have been increasingly used as adjuncts to multimodal pain control. Among them, the paravertebral nerve block (PVB) has gained attention for thoracic and abdominal procedures. PVB involves injecting local anesthetic adjacent to the thoracic vertebrae, providing unilateral somatic and sympathetic blockade across multiple dermatomes. The use of ultrasound guidance has greatly improved the safety and accuracy of this technique, allowing clinicians to visualize the pleura, ribs, and transverse processes during the block and thereby minimize complications<sup>(8, 9)</sup>. Numerous studies in surgical patients have demonstrated that ultrasound-guided PVB reduces postoperative pain scores, lowers opioid consumption, and facilitates earlier mobilization<sup>(10)</sup>. Despite the documented success of PVB in postoperative settings, little is known about its role in alleviating radiotherapy-associated pain. Radiotherapy induces pain through distinct mechanisms-skin and mucosal inflammation, tissue edema, and neural irritation-that are often not fully relieved by systemic medications alone. Given these challenges, ultrasound-guided PVB has the potential to provide targeted and sustained analgesia, reduce reliance on systemic drugs, and improve the overall safety profile of pediatric cancer care.

To our knowledge, this is among the first clinical investigations to specifically examine the effect of ultrasound-guided paravertebral nerve block on radiotherapy-associated pain in pediatric patients with mediastinal tumors. Unlike prior studies that focused primarily on surgical pain, this research emphasizes the underexplored but clinically important problem of radiation-induced pain. By assessing both analgesic outcomes and recovery parameters, the study aims to provide new evidence to guide safer and more effective pediatric pain management strategies.

## MATERIALS AND METHODS

### General information

Between March 2021 and November 2022, thirty pediatric patients who underwent mediastinal tumor surgery followed by adjuvant radiotherapy at the Thoracic Oncology Department of Baoding Hospital of Beijing Children's Hospital were prospectively enrolled. Patients ranged in age from 1 to 16 years (mean age  $7.59 \pm 2.25$  years), including 17 males and 13 females. Randomization was performed using a computer-generated sequence. The control group (n=15) received routine postoperative analgesia, while the observation group (n=15) received ultrasound-guided paravertebral nerve block (PVB) in addition to routine analgesia.

### Inclusion criteria

- Age 1–20 years
  - Both genders included
  - Histologically confirmed mediastinal tumor with surgery followed by radiotherapy
  - ASA physical status I–II
- Signed informed consent obtained from guardians

### Exclusion criteria

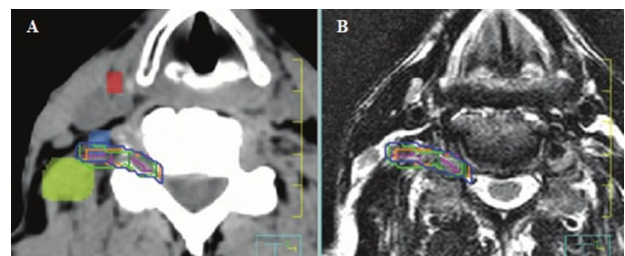
- Known allergy to local anesthetics
  - Severe dysfunction of heart, lungs, liver, or kidneys
  - Coagulation disorders or bleeding diathesis
  - Chronic pain disorders or regular analgesic use
  - History of failed/complicated PVB
- Guardians refused participation

### Research ethics

This study was conducted in accordance with the Declaration of Helsinki. Ethical approval was obtained from the Ethics Committee of Baoding Hospital of Beijing Children's Hospital (Approval No. BDCH2021-021; Date: March 1, 2021). The study was prospectively registered in the Chinese Clinical Trial Registry (ChiCTR2100034576; Registration Date: March 5, 2021). Written informed consent was obtained from the guardians of all patients.

### Radiotherapy procedure

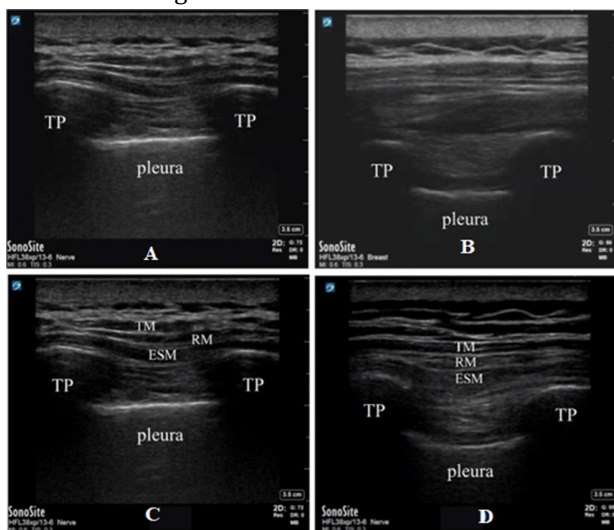
Radiotherapy was delivered using a Varian ClinacX Linear Accelerator (Varian Medical Systems, Palo Alto, USA) with 6 MV X-rays. Dose prescription was 2.0 Gy per fraction, 5 fractions per week, with a total dose of 40–60 Gy depending on tumor type and stage. Patients were immobilized with Konsberg™ thermoplastic masks (Guangzhou Konsberg Medical Technology Co., Ltd., China). Treatment planning was performed with the Eclipse™ Planning System (Varian Medical Systems, USA). Plans were generated using three-dimensional conformal radiotherapy (3D-CRT) or intensity-modulated radiotherapy (IMRT) (figure 1).



**Figure 1.** Fusion of CT and MR images was used to delineate the brachial plexus for IMRT planning. The CT scan (A) and MR image (B) illustrate the right brachial plexus, contoured separately by multiple specialists. On the CT, the anterior scalene muscle (blue), middle scalene muscle (green), and a pathological lymph node (red) are highlighted.

### Paravertebral nerve block procedure

In the observation group, thoracic PVB was performed under ultrasound guidance. A Mindray M9 Ultrasound System (Mindray Medical International Ltd., Shenzhen, China) equipped with a high-frequency linear probe (6–13 MHz) was used. A 22-gauge, 80-mm insulated needle (Tuoren™, Henan Tuoren Medical Device Co., Ltd., China) was advanced to the thoracic paravertebral space under aseptic conditions. The local anesthetic was Ropivacaine Hydrochloride Injection (Hengrui Medicine Co., Ltd., Jiangsu, China), administered at 0.4 ml/kg per level, not exceeding maximum recommended dose. Correct injection was confirmed by ultrasound visualization of pleural displacement. Sample ultrasound images are shown in figure 2.



**Figure 2.** Ultrasound-guided thoracic paravertebral and erector spinae blocks, ultrasound-guided paravertebral and erector spinae blocks were performed at T4–5 using 30 ml of 0.5% ropivacaine. Pleural displacement confirmed paravertebral injection, while the erector spinae block was placed between the erector spinae muscle and transverse processes. Images show pre- and post-injection views.

### Analgesic medications

Patients in the control group received routine systemic analgesics, including:

- Morphine Hydrochloride Injection (Yichang Humanwell Pharmaceutical Co., Ltd., Hubei, China)
- Parecoxib Sodium Injection (Jiangsu Hengrui Medicine Co., Ltd., China)

Tramadol Hydrochloride Injection (Shenyang First Pharmaceutical Factory, Shenyang, China)

Dosages were weight-adjusted (mg/kg). Rescue medication was given if VAS  $\geq 5$ .

### Pain assessment

Pain was assessed using the Visual Analog Scale (VAS, 0–10 cm) immediately after radiotherapy and at 12, 24, and 48 hours post-treatment. Hourly evaluations were conducted during the first 12 hours.

### Recovery outcomes and adverse effects

Length of ICU stay, total hospital stay, and time to resumption of daily activities were recorded. Radiotherapy-related side effects (skin irritation, esophagitis, fatigue) were graded using CTCAE v5.0 criteria. Adverse drug reactions (nausea, vomiting, hypotension, dizziness, respiratory depression) were documented.

### Statistical analysis

Data were analyzed using SPSS version 22.0 (Beijing SPSS Co., Ltd., China). Continuous data were expressed as mean  $\pm$  standard deviation (SD) and compared using Student's t-test. Categorical variables were expressed as n (%) and compared with  $\chi^2$  test. Statistical significance was defined as  $p < 0.05$ .

## RESULTS

### Patient characteristics

A total of 30 pediatric patients receiving radiotherapy following mediastinal tumor resection were included. Baseline demographic and clinical data (age, sex, weight, height) were comparable between the two groups, with no statistically significant differences ( $p > 0.05$ ) (table 1). This ensured that subsequent comparisons of radiotherapy-related outcomes were not confounded by baseline imbalances.

**Table 1.** Baseline characteristics of patients.

Variable	Control Group (n=15)	PVB Group (n=15)	p-value
Male/Female	10/5	7/8	0.668
Age (years)	7.33 $\pm$ 2.68	7.51 $\pm$ 2.47	0.721
Weight (kg)	23.58 $\pm$ 3.44	22.39 $\pm$ 2.85	0.514
Height (cm)	124.26 $\pm$ 2.44	122.33 $\pm$ 2.05	0.335

### Pain scores during radiotherapy

Pain intensity associated with radiotherapy was significantly lower in the observation (PVB) group compared with the control group at all recorded time points. Immediately after treatment, and at 12-, 24-, and 48-hours post-radiotherapy, children who received ultrasound-guided PVB reported consistently reduced VAS scores (table 2). This demonstrates that PVB provided not only immediate but also prolonged pain relief throughout the critical window of radiation-induced acute pain.

**Table 2.** VAS pain scores following radiotherapy.

Time Point	Control Group (n=15)	PVB Group (n=15)	p-value
Immediately after RT	6.49 $\pm$ 1.35	4.73 $\pm$ 1.22	0.034
12 h after RT	5.21 $\pm$ 1.05	3.34 $\pm$ 0.68	0.016
24 h after RT	3.88 $\pm$ 0.72	2.56 $\pm$ 0.52	0.005
48 h after RT	3.05 $\pm$ 0.51	1.74 $\pm$ 0.43	0.021

### Time to first rescue analgesia

The time to the first requirement for rescue analgesics after radiotherapy was significantly prolonged in the PVB group (7.61  $\pm$  0.64 h) compared

with the control group ( $4.35 \pm 0.52$  h,  $p=0.003$ ) (table 3). This finding indicates that PVB substantially extended the effective analgesic duration of each radiotherapy session.

**Table 3.** Time to first rescue analgesia after radiotherapy.

Group	Time (h)	p-value
Control (n=15)	$4.35 \pm 0.52$	
PVB (n=15)	$7.61 \pm 0.64$	0.003

### Analgesic consumption during radiotherapy

As shown in table 4, the cumulative doses of systemic analgesics were markedly lower in the PVB group. This confirms that the addition of ultrasound-guided PVB reduced reliance on morphine, parecoxib, and tramadol for controlling radiotherapy-associated pain.

**Table 4.** Analgesic consumption within 48 hours after radiotherapy.

Drug (mg/kg)	Control Group (n=15)	PVB Group (n=15)	p-value
Morphine	$0.16 \pm 0.03$	$0.11 \pm 0.02$	0.002
Parecoxib	$0.68 \pm 0.17$	$0.45 \pm 0.11$	0.037
Tramadol	$1.48 \pm 0.30$	$0.94 \pm 0.22$	0.026

### Radiotherapy-related toxicities

Acute toxicities attributable to radiotherapy were systematically evaluated. Patients in the PVB group showed a significantly lower incidence of radiation dermatitis (skin irritation) and fatigue compared to the control group. The total reaction rate (including skin, mucosal, and systemic symptoms) was markedly reduced in the PVB group (26.6% vs. 80%,  $p=0.012$ ) (table 5).

**Table 5.** Incidence of radiotherapy-related side effects.

Side Effect	Control Group (n=15)	PVB Group (n=15)	p-value
Skin Irritation (%)	6 (40%)	2 (13.3%)	0.031
Fatigue (%)	8 (53.3%)	4 (26.6%)	0.039
Esophagitis (%)	3 (20%)	1 (6.6%)	0.075
Total (%)	12 (80%)	4 (26.6%)	0.012

### Recovery outcomes

Children in the PVB group had faster clinical recovery following radiotherapy. Both ICU stay and hospital length of stay were significantly shorter, and return to daily activities was quicker compared to controls (all  $p<0.05$ ). Results or recovery outcomes is shown in table 6.

**Table 6.** Recovery outcomes post-radiotherapy.

Outcome	Control Group (n=15)	PVB Group (n=15)	p-value
ICU Stay (h)	$16.35 \pm 3.57$	$10.28 \pm 2.41$	0.027
Hospital Stay (days)	$9.36 \pm 1.45$	$7.24 \pm 1.08$	0.006
Time to Resume Daily Activities	$3.44 \pm 0.52$	$2.26 \pm 0.46$	0.019

### Adverse reactions during radiotherapy

Treatment-related adverse events, primarily associated with systemic analgesic administration (nausea, vomiting, dizziness, hypotension), were observed in 33.3% of patients in the control group versus only 13.3% in the PVB group (table 7). No

major complications such as nerve injury, pleural puncture, or respiratory depression were reported.

**Table 7.** Adverse reactions during radiotherapy.

Adverse Event (%)	Control Group (n=15)	PVB Group (n=15)
Nausea/Vomiting	13.3%	6.6%
Dizziness	6.6%	6.6%
Hypotension	6.6%	0%
Respiratory Depression	6.6%	0%
Total (%)	33.3%	13.3%

## DISCUSSION

The present study investigated the role of ultrasound-guided paravertebral block (PVB) as an adjunct to systemic analgesia in pediatric patients undergoing radiotherapy for mediastinal tumors. Our findings demonstrate that PVB significantly reduces radiotherapy-associated pain, prolongs the time to first rescue analgesic, lowers total analgesic consumption, decreases acute radiation-related toxicities, and improves recovery outcomes compared to conventional systemic analgesia.

Pain associated with radiotherapy is a frequent and distressing problem in children, largely due to acute skin and mucosal inflammation, nerve irritation, and procedural stress. In our study, VAS scores were consistently lower in the PVB group across all time points. These results are consistent with adult thoracic oncology studies, where PVB has been shown to significantly decrease pain intensity after breast radiotherapy and thoracic procedures<sup>(11, 12)</sup>. Albi-Feldzer *et al.* demonstrated that preoperative PVB reduced both acute and chronic pain in breast cancer patients<sup>(13)</sup>, while Liu and An reported improved pain control and reduced opioid use with PVB in thoracic surgery<sup>(14)</sup>. Our study extends these findings to pediatrics, where evidence has been limited.

Opioid consumption was substantially reduced in the PVB group. This aligns with reports by Chen *et al.*, who showed that ultrasound-guided regional blocks lowered perioperative opioid use in breast surgery<sup>(15)</sup>. Similarly, Turhan *et al.* found that PVB achieved superior pain relief compared to other thoracic blocks in thoracoscopic surgery, with reduced reliance on systemic opioids<sup>(16)</sup>. Minimizing opioid exposure is particularly important in children due to the risk of respiratory depression, sedation, and long-term dependence<sup>(17)</sup>. By reducing morphine, parecoxib, and tramadol requirements, PVB provides a safer analgesic strategy during radiotherapy.

A novel finding of this study is the association between PVB and reduced radiotherapy-related side effects, including skin irritation and fatigue. The incidence of these complications was significantly lower in the PVB group. While direct evidence linking nerve blocks to radiation toxicity is limited, indirect mechanisms may explain this effect. Effective pain control reduces stress responses, enhances treatment

compliance, and may limit the amplification of inflammatory cascades induced by radiation (18). Ferayet *al.* also reported that effective pain management strategies improved tolerance to thoracic procedures and accelerated recovery (19). Our data support the hypothesis that improved analgesia indirectly mitigates some acute radiation toxicities in children.

Children receiving PVB demonstrated shorter ICU and hospital stays, as well as earlier return to daily activities. Enhanced recovery protocols increasingly emphasize regional anesthesia as a cornerstone for improving postoperative and post-treatment outcomes (20). Sharma *et al.* reviewed chest wall and abdominal blocks and confirmed that PVB facilitates faster mobilization and earlier discharge (21). Our findings corroborate these observations and highlight the particular importance in pediatrics, where prolonged hospitalization can disrupt psychological well-being, schooling, and family dynamics.

The incidence of treatment-related adverse reactions was lower in the PVB group, with fewer cases of nausea, vomiting, hypotension, and no respiratory depression. These results mirror those of Hegazyet *al.*, who showed that ultrasound-guided PVB is safe and carries a lower complication profile than blind or thoracoscopic-guided approaches (22). The absence of major complications in our cohort supports the use of ultrasound guidance, which increases accuracy and safety, especially in small pediatric anatomical structures.

Alternative regional blocks, such as erector spinae plane (ESP) block and serratus anterior plane block, have been proposed for thoracic analgesia (23). Systematic reviews by Leong *et al.* (24) and Chen *et al.* (15) found both ESP and PVB to be effective, though PVB often produced superior analgesic effects. A recent randomized study by Zhang *et al.* confirmed that PVB provided stronger pain control than serratus anterior plane block in thoracoscopic surgery (25). Our results support the preference for PVB in pediatric thoracic oncology patients, particularly in the context of radiotherapy, where sustained pain relief is required.

The present findings highlight the clinical value of integrating ultrasound-guided PVB into multimodal pain management protocols for children receiving thoracic radiotherapy. By reducing acute pain and systemic analgesic use, PVB not only improves comfort but also enhances compliance with radiation schedules, reduces acute toxicities, and accelerates recovery. Given the limited data in pediatric populations, our study adds important evidence supporting the expansion of regional anesthesia techniques into oncology radiotherapy settings.

This study has several limitations that should be considered when interpreting the results. First, the relatively small sample size of 30 patients reduces

the statistical power and limits the generalizability of the findings. Second, as this was a single-center study, the results may not fully represent outcomes in other institutions with different patient populations or clinical practices. Third, the follow-up period focused only on short-term effects, meaning that potential long-term consequences such as late radiation toxicity, chronic neuropathic pain, or quality-of-life outcomes were not assessed. In addition, heterogeneity in tumor histology and radiotherapy regimens may have introduced variability in treatment response, which could have influenced the observed results. Finally, psychological aspects, including anxiety and emotional distress—which are particularly relevant in pediatric oncology—were not systematically evaluated, representing another important gap that future studies should address.

Future multicenter, randomized controlled trials with larger cohorts are needed to validate these findings. Studies should include longer follow-up to assess chronic pain, late radiation toxicities, and psychosocial outcomes. Comparative trials between PVB and other regional techniques such as ESP block may also clarify the optimal approach for pediatric radiotherapy patients.

**Acknowledgments:** The authors would like to thank the patients and their families for their participation and cooperation in this study. We also acknowledge the nursing staff and radiation therapists at Baoding Hospital of Beijing Children's Hospital for their valuable support in patient care and data collection.

**Funding:** The research is supported by: Baoding Science and Technology Plan Project, Efficacy and Safety of Extrapleural Block for Post thoracoscopic Surgery Treatment of Coronary Heart Disease Patients, (No. 2341ZF038)

**Conflict of Interest:** The authors declare that they have no competing interests related to this work.

**Ethical Considerations:** This study was conducted in accordance with the ethical principles of the Declaration of Helsinki. Approval was obtained from the Ethics Committee of Baoding Hospital of Beijing Children's Hospital (Approval No. BDCH2021-021; Date: March 1, 2021). The trial was registered in the Chinese Clinical Trial Registry (ChiCTR2100034576; Registration Date: March 5, 2021). Written informed consent was obtained from the guardians of all participants prior to enrollment.

**Authors' Contributions:** Y.L.: Conceptualization, methodology, data acquisition, drafting of the manuscript. T-F.Q.: Study design, supervision, critical revision of the manuscript. S.L.: Data collection, patient care, and analysis. J-Y.X.: Statistical analysis, data interpretation. H-Q.J.: Radiotherapy planning, technical support, and manuscript review. All authors read and approved the final manuscript.

**Use of AI in manuscript preparation:** No artificial

intelligence tools were used in the preparation of this manuscript. All sections were written, revised, and finalized solely by the authors.

## REFERENCES

- Cui W, Huang D, Liang H, *et al.* (2021) Tubeless video-assisted thoracoscopic surgery in mediastinal tumor resection. *Gland Surg*, **10**: 1387-1396.
- Chen JQ, Yang XL, Gu H, *et al.* (2021) The role of serratus anterior plane block during in video-assisted thoracoscopic surgery. *Pain Ther*, **10**: 1051-1066.
- Kim SH (2022) Anatomical classification and clinical application of thoracic paraspinal blocks. *Korean J Anesthesiol*, **75**: 295-306.
- Chin KJ, Versyck B, Pawa A (2021) Ultrasound-guided fascial plane blocks of the chest wall: a state-of-the-art review. *Anaesthesia*, **76** (Suppl 1): 110-126.
- Vinsard PA and Niesen AD (2023) Regional anesthesia for scapulothoracic fixation surgery: Anatomic review and case series. *Clin Anat*, **36**: 896-899.
- Xuan C, Yan W, Wang D, *et al.* (2022) Efficacy of different analgesia treatments for abdominal surgery: A network meta-analysis. *Eur J Pain*, **26**: 567-577.
- Yang J, Zhao M, Zhang XR, *et al.* (2022) Ropivacaine with dexmedetomidine or dexamethasone in a thoracic paravertebral nerve block combined with an erector spinae plane block for thoracoscopic lobectomy analgesia: A randomized controlled trial. *Drug Des Devel Ther*, **16**: 1561-1571.
- Hummel A, Gaucher D, Wang P, *et al.* (2023) Higher intra-operative narcotic requirements and weakness with quadratus lumborum compared to paravertebral nerve block for total hip arthroplasty. *Arch Orthop Trauma Surg*, **143**: 6849-6855.
- Wang Y, Wu G, Liu Z, *et al.* (2023) Effect of oxycodone combined with ultrasound-guided thoracic paravertebral nerve block on postoperative analgesia in patients with lung cancer undergoing thoracoscopic surgery: protocol for a randomized controlled study. *BMJ Open*, **13**: e074416.
- Chin KJ, Versyck B, Elsharkawy H, *et al.* (2021) Anatomical basis of fascial plane blocks. *Reg Anesth Pain Med*, **46**: 581-599.
- Harkouk H, Fletcher D, Martinez V (2021) Paravertebral block for the prevention of chronic postsurgical pain after breast cancer surgery. *Reg Anesth Pain Med*, **46**: 251-257.
- Penta DL, Saldanha U, Liu H (2023) Paravertebral block for analgesia following excision of osteochondroma of the scapula: A case report. *J Biomed Res*, **37**: 401-404.
- Albi-Feldzer A, Dureau S, Ghimouz A, *et al.* (2021) Preoperative paravertebral block and chronic pain after breast cancer surgery: A double-blind randomized trial. *Anesthesiology*, **135**: 1091-1103.
- Liu X and An J (2022) Effects of serratus anterior plane block and thoracic paravertebral nerve block on analgesia, immune function and serum tumor markers in patients after thoracoscopic radical resection of lung cancer. *Nagoya J Med Sci*, **84**: 506-515.
- Chen W, Zhou X, Li H, *et al.* (2023) Analgesic effectiveness of preoperative ultrasound-guided erector spinae plane block versus paravertebral nerve block for breast surgery: A systematic review and meta-analysis of four randomized controlled trials. *Pain Pract*, **23**: 511-522.
- Turhan Ö, Sivriköz N, Sungur Z, *et al.* (2021) Thoracic paravertebral block achieves better pain control than erector spinae plane block and intercostal nerve block in thoracoscopic surgery: A randomized study. *J Cardiothorac Vasc Anesth*, **35**: 2920-2927.
- Xie C, Sun N, Sun K, *et al.* (2020) Lung ultrasound and diaphragmatic excursion assessment for evaluating perioperative atelectasis and aeration loss during video-assisted thoracic surgery: a feasibility study. *Ann Palliat Med*, **9**: 1506-1517.
- Kawagoe I, Hayashida M, Satoh D, *et al.* (2021) Postoperative analgesia in patients undergoing robot-assisted thoracic surgery: a comparison between thoracic epidural analgesia and intercostal nerve block combined with intravenous patient-controlled analgesia. *Ann Palliat Med*, **10**: 1985-1993.
- Feray S, Lubach J, Joshi GP, *et al.* (2022) PROSPECT guidelines for video-assisted thoracoscopic surgery: a systematic review and procedure-specific postoperative pain management recommendations. *Anesthesiology*, **77**: 311-325.
- Geradon P and Lavand'homme P (2022) Use of regional analgesia to prevent the conversion from acute to chronic pain. *Curr Opin Anaesthesiol*, **35**: 641-646.
- Sharma R, Damiano J, Al-Saidi I, *et al.* (2023) Chest wall and abdominal blocks for thoracic and abdominal surgeries: A review. *Curr Pain Headache Rep*, **27**: 587-600.
- Hegazy MA, Awad G, Abdellatif A, *et al.* (2021) Ultrasound versus thoracoscopic-guided paravertebral block during thoracotomy. *Asian Cardiovasc Thorac Ann*, **29**: 98-104.
- Chin KJ and El-Boghdady K (2021) Mechanisms of action of the erector spinae plane (ESP) block: a narrative review. *Can J Anaesth*, **68**: 387-408.
- Leong RW, Tan ESJ, Wong SN, *et al.* (2021) Efficacy of erector spinae plane block for analgesia in breast surgery: a systematic review and meta-analysis. *Anaesthesia*, **76**: 404-413.
- Zhang Y, Fu Z, Fang T, *et al.* (2022) A comparison of the analgesic efficacy of serratus anterior plane block vs paravertebral nerve block for video-assisted thoracic surgery: a randomized controlled trial. *Wideochir Inne Tech Maloinwazyjne*, **17**: 134-142.