

Application of preoperative DCE-MRI quantitative parameters combined with serum VEGFR-3 in the evaluation of mediastinal lymph node metastasis of adenocarcinoma of lung

J. Yang¹, P. Guo², D. Zhou¹, L. Ding¹, P. Jiang^{1*}

¹Department of Radiology, Huanggang Central Hospital, Huanggang, Hubei, China

²Department of Laboratory Medicine, Huanggang Central Hospital, Huanggang, Hubei, China

► Original article

*Corresponding author:

Peng Jiang, Ph.D.,

E-mail:

hgszxyycgzs201106@163.com

Received: May 2025

Final revised: July 2025

Accepted: August 2025

Int. J. Radiat. Res., January 2026;
24(1): 215-219

DOI: 10.61186/ijrr.24.1.32

Keywords: Adenocarcinoma of lung, magnetic resonance imaging, vascular endothelial growth factor receptor-3, lymphatic metastasis, diagnosis.

ABSTRACT

Background: To observe the expression of serum vascular endothelial growth factor receptor-3 (VEGFR-3) and dynamic contrast-enhanced magnetic resonance imaging (DCE-MRI) quantitative parameters in patients with lung adenocarcinoma (AOL) mediastinal lymph node metastasis (MLNM), and analyze the relationship between the above parameter and MLNM of AOL. **Materials and Methods:** One hundred patients with AOL, they were divided into MLNM group and non-MLNM group. Two groups were compared in the DCE-MRI quantitative parameters [Rate constant (Kep), volume transfer constant (Ktrans), extravascular extracellular volume fraction (Ve), and apparent diffusion coefficient (ADC)] and serum VEGFR-3 expression, and the relationship between the above index parameters and MLNM in patients with AOL was analyzed. **Results:** Compared with the non-MLNM group, the Ktrans, Kep, Ve value and expression of serum VEGFR-3 in the MLNM group were higher, the ADC value was lower ($P < 0.05$). Logistics regression analysis showed that preoperative fasting serum VEGFR-3 expression was related to MLNM in patients with AOL, and high VEGFR-3 expression might be a risk factor for MLNM in patients with AOL ($OR > 1$, $P < 0.05$). The ROC curve showed that the AUC of VEGFR-3 and DCE-MRI quantitative parameters to predict MLNM in patients with AOL was greater than 0.70. **Conclusion:** The DCE-MRI quantitative parameters combined with serum VEGFR-3 expression has a certain value in the preoperative assessment of MLNM in patients with AOL.

INTRODUCTION

The pathological characteristics of adenocarcinoma of Lung (AOL) are the basis for clinical treatment and intervention decisions⁽¹⁾. The key and difficult points in clinical diagnosis and treatment of AOL are whether the mediastinal lymph nodes metastasize, which is also the key to formulating reasonable intervention measures⁽²⁾. In the past, the existence of mediastinal lymph node metastasis (MLNM) for AOL patients mainly depended on pathological examination. However, as an invasive operation, pathological examination is highly subjective in terms of sample collection, and the risk of pathological tissue dropping out during the sample collection is high⁽³⁾. Therefore, relying on pathological tissue examination is still limited in various prognosis evaluation, staging diagnosis and treatment, and various scientific research means, and it is particularly necessary to explore non-invasive, accurate, repeatable examination means capable of obtaining quantitative and functional information of lymph nodes⁽⁴⁾.

With the development of magnetic resonance imaging (MRI) hardware performance and software

imaging sequences, dynamic contrast-enhanced-MRI (DCE-MRI) has become a new MRI functional imaging technology⁽⁵⁾. Based on the anatomical and morphological changes, this technique forms an accurate multi-mode magnetic resonance imaging examination dominated by the pathological microenvironment, such as water molecule dispersion between tissues and tissue micro-perfusion, which provides an objective and scientific reference for the volume work in the examination of pathological features of AOL⁽⁶⁾. However, some studies have pointed out that the simple reliance on imaging examinations is still biased⁽⁷⁾, so the combination of biological indicators on this basis was considered.

As we all know, neoangiogenesis plays an important role in the occurrence and progression of cachexia. Vascular endothelial growth factor receptor -3 (VEGFR-3) is a vascular endothelial growth factor receptor that plays a key role in the generation of lymphatic vessels^(8, 9). In the latest study, the relationship between VEGFR-3 and AOL has been preliminarily verified⁽¹⁰⁾. However, no studies have evaluated MLNM in patients with VEGFR-3 and AOL.

Therefore, this study combines the quantitative

parameters of DCE-MRI with the expression of VEGFR-3 to establish a multimodal evaluation model, which overcomes the limitations of single imaging or biomarker in the diagnosis of MLNM, and provides a scientific basis for optimizing surgical decision-making and individualized treatment.

MATERIALS AND METHODS

Research objects

Period: January 2021 to May 2023; Subjects: 100 patients with AOL. All the research subjects knew the purpose of the study and signed the consent form. There were 53 males and 47 females, aging from 45 to 73 years old, with the average age of (59.12±3.15) years old. This study has been approved by the Ethics committee of our hospital (No. HG20200908), and all subjects signed an informed consent form.

Inclusion and exclusion criteria

Inclusion criteria: ① AOL met the relevant requirements of the reference ⁽¹¹⁾ and were confirmed by pathological tissues; ② All of them are primary AOL; ③ All patients had AOL for the first time, and the malignant tumor diseases in other parts were excluded. Exclusion criteria: ① Patients with immunological diseases; ② Patients with coagulation dysfunction or hematological system diseases; ③ Allergic constitution; ④ Patients with encapsulated pleural effusion; ⑤ Patients who have received disease-related therapies such as chemoradiotherapy before entering the group; ⑥ Patients with mental disorders or low compliance could not cooperate with the study to develop smoothly.

DCE-MRI examination

Instrument: GE Discovery MR 750 3.0T magnetic resonance scanner (USA). Before examination, the patient was asked to withdraw the metal substances from his body, and to lie in the supine position with both hands raised above his head. The upper edge of the coil was corresponding to the upper edge of the scapula. In case that normal breathing was not affected, the abdominal belt was tightened to make the coil close to the anterior chest, and then the high-pressure syringe was connected. Then, the imaging sequence was acquired using enhanced scanning in sagittal position. After the enhanced image was acquired, the contrast medium (3.0mL/s, 0.12mmol/Kg, Bayer, Germany) was injected into the high-pressure syringe, and the non-intermittent scanning was completed by injecting 15mL normal saline at the same speed. During the scanning process, blood vessels, calcification, necrotic tissue, fat were avoided, the region of interest was selected, measure three times and take the mean value: rate constant (Kep), volume transfer constant (Ktrans), extravascular extracellular volume fraction (Ve), apparent diffusion coefficient (ADC) ⁽¹¹⁾.

Detection of serum VEGFR-3

Five milliliters of fasting elbow venous blood was collected from patients before operation. The blood samples were centrifuged at 2000r/min (r:10cm) for 10min, the expression of serum VEGFR-3 was detected by ELISA, kit was purchased from Shanghai Future Industrial Co., LTD. (China).

Indicators of observation

The differences of DCE-MRI parameters and VEGFR-3 between MLNM group and non-MLNM group were analyzed, and the diagnostic value of DCE-MRI combined with VEGFR-3 for MLNM in AOL patients was analyzed.

Statistical methods

SPSS 25.0 software (IMB, USA) was selected to process the data. Measurement data were described as ($\bar{x}\pm s$), and the sample *t* test was used. The count data were expressed as percentages using the χ^2 test. The receiver operating characteristic (ROC) was used to test the value of main indexes for predicting the risk of MLNM in patients with AOL and evaluated by the area under curve (AUC) (table 1). The test level was $\alpha=0.05$.

Table 1. AUC predicted value.

AUC	Predictive value
AUC≤0.5	No
0.5<AUC≤0.7	Low
0.7<AUC≤0.9	Medium
AUC>0.9	High

RESULTS

MLNM of AOL

Among the 100 patients with AOL, 62 cases (62.00%) with MLNM were detected by histopathological examination, and 38 cases (38.00%) without MLNM. Figure 1 illustrates the DCE-MRI images of a subject. A 54-year-old female presented with metastatic carcinoma in the fibrous tissue of the left axillary lymph node.

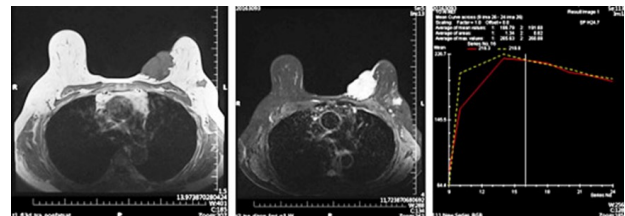


Figure 1. DCE-MRI findings in a patient (a 54-year-old woman).

Comparison of examination results

The comparison of gender, age, tumor node metastasis classification (TNM) stage, lesion diameter, differentiation degree and venous infiltration between the two groups ($P>0.05$). Compared with the non-MLNM group, the Ktrans, Kep, Ve value and expression of serum VEGFR-3 in the MLNM group were higher, the ADC value was lower ($P<0.05$, table 2).

Table 2. Comparison of baseline data, DCE-MRI parameters and DCE-MRI.

Indicator	MLNM group (n=62)	Non-MLNM group (n=38)	Statistical values	P
Gender (Male/Female)	35/27	18/20	$\chi^2=0.780$	0.377
Age (≥ 60 years/ < 60 years)	35/27	20/18	$\chi^2=0.139$	0.709
TNM stage (I-II/III-IV)	30/32	15/23	$\chi^2=0.010$	0.921
Lesion diameter (< 5 cm/ ≥ 5 cm)	28/34	18/20	$\chi^2=0.046$	0.830
Degree of differentiation (Undifferentiated and poorly differentiated/Medium and high differentiated)	25/37	12/26	$\chi^2=0.773$	0.379
Venous infiltration (Yes/No)	22/40	10/28	$\chi^2=0.910$	0.340
Ktrans ($\bar{x} \pm s$, min)	0.51 \pm 0.15	0.36 \pm 0.12	$t=5.222$	<0.001
Kep ($\bar{x} \pm s$, min)	2.38 \pm 0.66	1.86 \pm 0.23	$t=4.678$	<0.001
Ve ($\bar{x} \pm s$)	0.23 \pm 0.09	0.19 \pm 0.07	$t=2.339$	0.021
ADC ($\bar{x} \pm s$, 10^3 mm ² /s)	0.95 \pm 0.31	1.41 \pm 0.29	$t=7.379$	<0.001
VEGFR-3 ($\bar{x} \pm s$, pg/ml)	112.02 \pm 20.15	68.52 \pm 10.50	$t=12.307$	<0.001

Note: rate constant (Kep), volume transfer constant (Ktrans), extravascular extracellular volume fraction (Ve), apparent diffusion coefficient (ADC), vascular endothelial growth factor receptor-3 (VEGFR-3), tumor node metastasis classification (TNM).

The effect of DCE-MRI combined with VEGFR-3 in the diagnosis of MLNM

The preoperative fasting serum VEGFR-3 expression in patients with AOL and DCE-MRI quantitative parameters were respectively taken as test variables, and the MLNM was taken as state variable (1=metastasis and 0=non-metastasis) and ROC curve was drawn (figures 2 and 3). The ROC curve showed that the AUC of VEGFR-3 and DCE-MRI quantitative parameters to predict MLNM in patients with AOL was >0.70 , and the predictive value was ideal (table 3).

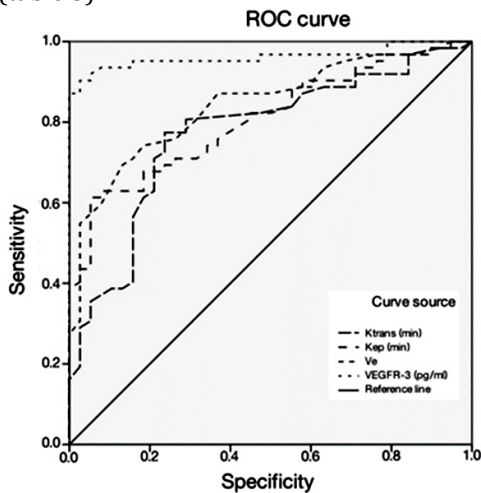


Figure 2. Ktrans, Kep, Ve and serum VEGFR-3 predicting MLNM of patients with AOL.

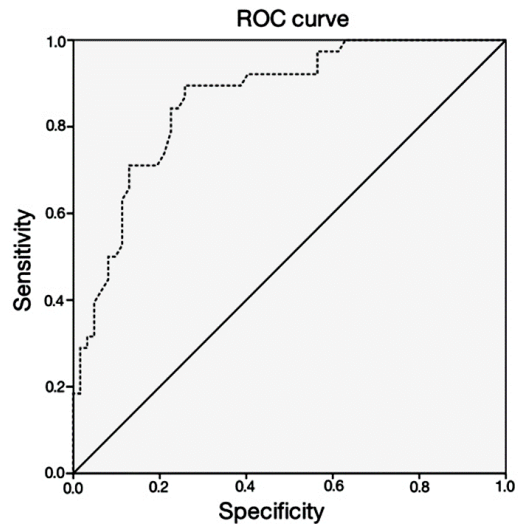


Figure 3. ADC value predicting MLNM of patients with AOL.

Table 3. Efficacy analysis of DCE-MRI quantitative parameters combined with serum VEGFR-3 in prediction of MLNM in patients with AOL.

Indicator	AUC	95% CI of AUC	Standard error	P	Cut-off value	Sensitivity	Specificity	Youden's index
Ktrans	0.774	0.680-0.868	0.048	<0.001	0.285	0.887	0.711	0.598
Kep	0.806	0.723-0.889	0.042	<0.001	0.960	0.984	0.895	0.879
Ve	0.843	0.767-0.919	0.039	<0.001	0.155	0.903	0.605	0.508
ADC	0.863	0.791-0.934	0.036	<0.001	0.845	0.974	0.613	0.587
VEGFR-3	0.962	0.923-1.000	0.020	<0.001	60.120	0.984	0.789	0.773

Note: rate constant (Kep), volume transfer constant (Ktrans), extravascular extracellular volume fraction (Ve), apparent diffusion coefficient (ADC), vascular endothelial growth factor receptor-3 (VEGFR-3), area under curve (AUC), 95% confidence interval (95%CI).

DISCUSSION

In this study, the Ktrans, Kep, Ve value and expression of serum VEGFR-3 in the MLNM group were higher, the ADC value was lower, indicating that clinical detection of DCE-MRI quantitative parameters and serum VEGFR-3 expression in AOL patients could be used as the basis for judging MLNM. The reasons might be as follows: ① For AOL patients with MLNM, the cancer tissues showed exuberant cell metabolism, high expression of vascular endothelial growth factor and increased angiogenesis to meet the nutritional needs of the lesions. However, due to the immature neovascular tube wall, lack of integrity of the basement membrane, increased vascular microcirculation perfusion, high vascular permeability, and relatively active contrast agent, the Ktrans and Kep values in the quantitative parameters of DCE-MRI were relatively high (12-14); ② For AOL patients with MLNM, the malignant tumor cells have low differentiation and strong proliferation ability, the cells are closely arranged, the diffusion of water

molecules in the lesion tissue is limited, and the ADC value is low^(15,16); ③ With the increase of vascular permeability, the vascular barrier was damaged, and the contrast agent penetrated outside the blood vessel through the vascular barrier. Then the contrast agent entered the tissue space, and the V_e value was increased significantly^(17,18); ④ VEGFR-3 is a specific receptor for vascular endothelial growth factor C, and the high expression of vascular endothelial growth factor C has been confirmed to be related to lymphangiogenesis and lymphatic network structure remodeling. High expression of VEGFR-3 leads to the destruction of local immune microenvironment, and directly participates in the lymphangiogenesis of cancer lesions, accelerating the growth, proliferation and migration of lymphatic endothelial cells. VEGFR-3 not only participates in lymphangiogenesis, but also accelerates the invasion of cancer cells into lymphatic vessels, leading to an increased risk of MLNM⁽¹⁹⁻²¹⁾.

The ROC curve showed that the AUC of VEGFR-3 and DCE-MRI quantitative parameters to predict MLNM in patients with AOL was >0.70, and the predictive value was ideal, suggesting that DCE-MRI quantitative parameters examination and laboratory serum VEGFR-3 expression monitoring can be performed clinically for patients with AOL before operation, aiming to determine whether patients are accompanied with MLNM. These results also provide a new idea for future clinical judgment of MLNM, which is of great clinical significance for ensuring the prognosis and health of AOL patients.

However, in this study, due to the limited sample size and time factor, no long-term follow-up visit was conducted for included subjects. The reliability of research conclusions needs to be verified and supported by means of increasing the sample size and postoperative follow-up items in the future.

CONCLUSION

DCE-MRI quantitative parameters combined with serum VEGFR-3 expression have a certain value in the preoperative assessment of MLNM in patients with AOL. These findings provide new research directions for the diagnosis of MLNM in the future.

Conflicts of Interest: The authors report no conflict of interest.

Availability of data and materials: The data that support the findings of this study are available from the corresponding author upon reasonable request.

Funding: Not applicable.

Acknowledgements: Not applicable.

Ethical consideration: The Ethics Committee of Huanggang Central Hospital approved the study (NO. HG20200908).

Authors' contribution: P.J. and J.C.Y. conceived and designed the study, J.C.Y. and P.F.G. wrote and revised

the manuscript, D.Z. collected and analyzed the data, L.D. visualization the data. All authors read and approved the final submitted manuscript.

REFERENCES

- Zhao Y, Chen Q, Li P, et al. (2025) The Aurora-A/NPAT/Wnt- β -catenin pathway enhances the metastasis and stemness of lung cancer cells. *International Journal of Radiation Research*, **23**(1): 147-154.
- Zhu J, Cao K, Zhao M, et al. (2023) Improvement of ACK1-targeted therapy efficacy in lung adenocarcinoma using chloroquine or bafilomycin A1. *Mol Med*, **29**(1): 6.
- Cornellas L, Saez de Gordo A, Bartolome A, Larque AB, Tomas X (2023) Talar metastasis of mucinous lung adenocarcinoma with fluid-fluid levels: a rare presentation mimicking a benign tumor. *Skeletal Radiol*, **52**(2): 257-262.
- Chen L, Zeng X, Wu Y, et al. (2019) A study of the correlation of perfusion parameters in high-resolution GRASP MRI with microvascular density in lung cancer. *J Magn Reson Imaging*, **49**(4): 1186-1194.
- Li X, Huang W, Holmes JH (2024) Dynamic contrast-enhanced (DCE) MRI. *Magn Reson Imaging Clin N Am*, **32**(1): 47-61.
- Zhou Y, Zhou G, Zhang J, et al. (2021) Radiomics signature on dynamic contrast-enhanced MR images: a potential imaging biomarker for prediction of microvascular invasion in mass-forming intrahepatic cholangiocarcinoma. *Eur Radiol*, **31**(9): 6846-6855.
- Wang N, Gaddam S, Wang L, et al. (2020) Six-dimensional quantitative DCE MR multitasking of the entire abdomen: Method and application to pancreatic ductal adenocarcinoma. *Magn Reson Med*, **84**(2): 928-948.
- Chang TM, Chu PY, Lin HY, et al. (2022) PTEN regulates invasiveness in pancreatic neuroendocrine tumors through DUSP19-mediated VEGFR3 dephosphorylation. *J Biomed Sci*, **29**(1): 92.
- Sluimer JC and Biessen EAL (2021) Arterial lymphangiogenesis ReSPONDING 2 a new cue: the R-spondin2/LRG4 axis limits VEGFR3-mediated lymphangiogenesis and reverse cholesterol transport. *Cardiovasc Res*, **117**(6): 1417-1419.
- Qin T, Liu Z, Wang J, et al. (2020) Anlotinib suppresses lymphangiogenesis and lymphatic metastasis in lung adenocarcinoma through a process potentially involving VEGFR-3 signaling. *Cancer Biol Med*, **17**(3): 753-767.
- Heo SH, Jeong YY, Shin SS, et al. (2010) Apparent diffusion coefficient value of diffusion-weighted imaging for hepatocellular carcinoma: correlation with the histologic differentiation and the expression of vascular endothelial growth factor. *Korean J Radiol*, **11**(3): 295-303.
- Kim H, Morgan DE, Schexnaider P, et al. (2019) Accurate therapeutic response assessment of pancreatic ductal adenocarcinoma using quantitative dynamic contrast-enhanced magnetic resonance imaging with a point-of-care perfusion phantom: A pilot study. *Invest Radiol*, **54**(1): 16-22.
- Ren J, Yuan Y, Tao X (2022) Histogram analysis of diffusion-weighted imaging and dynamic contrast-enhanced MRI for predicting occult lymph node metastasis in early-stage oral tongue squamous cell carcinoma. *Eur Radiol*, **32**(4): 2739-2747.
- Park S, Park JG, Jun S, et al. (2020) Differentiation of bone metastases from prostate cancer and benign red marrow depositions of the pelvic bone with multiparametric MRI. *Magn Reson Imaging*, **73**: 118-124.
- Li L, Yu T, Sun J, et al. (2022) Prediction of the number of metastatic axillary lymph nodes in breast cancer by radiomic signature based on dynamic contrast-enhanced MRI. *Acta Radiol*, **63**(8): 1014-1022.
- Zhang Q, Guo J, Ouyang H, et al. (2022) Added-value of dynamic contrast-enhanced MRI on prediction of tumor recurrence in locally advanced cervical cancer treated with chemoradiotherapy. *Eur Radiol*, **32**(4): 2529-2539.
- Jin T, Zhang H, Liu X, et al. (2021) Enhancement degree of brain metastases: correlation analysis between enhanced T2 FLAIR and vascular permeability parameters of dynamic contrast-enhanced MRI. *Eur Radiol*, **31**(8): 5595-5604.
- Saleh MM, Abdelrahman TM, Madney Y, et al. (2020) Multiparametric MRI with diffusion-weighted imaging in predicting response to chemotherapy in cases of osteosarcoma and Ewing's sarcoma. *Br J Radiol*, **93**(1115): 20200257.

19. Schneider S, Köllges R, Stegmann JD, et al. (2022) Resequencing of VEGFR3 pathway genes implicate GJC2 and FLT4 in the formation of primary congenital chylothorax. *Am J Med Genet A* 188(5):1607-1611.
20. Monaghan RM, Page DJ, Ostergaard P, Keavney BD (2021) The physiological and pathological functions of VEGFR3 in cardiac and lymphatic development and related diseases. *Cardiovasc Res*, **117**(8): 1877-1890.
21. Shibata MA, Shibata E, Tanaka Y, Shiraoka C, Kondo Y (2020) Soluble Vegfr3 gene therapy suppresses multi-organ metastasis in a mouse mammary cancer model. *Cancer Sci*, **111**(8): 2837-2849.

