Volume 24, No 4 | International Journal of Radiation Research, October 2026

Diagnostic accuracy of imaging modalities for detecting residual or recurrent laryngeal cancer after (Chemo) radiotherapy: A systematic review and meta-analysis

Y. Zhan#, H. Cao#, X. Shan, X. Tai*

Department of Otolaryngology, The Air Force Hospital of the Northern Theater Command of the Chinese People's Liberation Army, Shenyang, Liaoning, China

► ***Original article***

***Corresponding author:**
Xuhui Tai, M.D.,
***E-mail:** entdoctor463@163.com*

Received: February 2026
Final revised: April 2026
Accepted: April 2026

Int. J. Radiat. Res., October 2026; 24(4): 1023-1030

DOI: 10.61186/ijrr.24.4.12

Keywords: *Laryngeal neoplasms, neoplasm recurrence, chemoradiotherapy, PET, CT, MRI, narrow band imaging, meta-analysis.*

#These authors contributed equally to this work and share first authorship.

ABSTRACT

Background: Differentiating residual or recurrent laryngeal carcinoma (RLC) from post-treatment changes after (chemo)radiotherapy remains a clinical challenge. This systematic review and meta-analysis evaluate the diagnostic performance of the imaging modalities most commonly used in this setting. ***Materials and Methods:*** We searched PubMed, Embase, Scopus, Google Scholar and Web of Science through December 2025 for studies assessing computed tomography (CT), magnetic resonance imaging (MRI), positron emission tomography (PET), PET/CT or narrow band imaging (NBI) in adults with laryngeal cancer treated with (chemo)radiotherapy. Histopathology or clinical follow-up served as the reference standard. Pooled sensitivity, specificity, diagnostic odds ratio (DOR) and area under the summary receiver operating characteristic curve (AUC) were calculated using bivariate random-effects and hierarchical summary receiver operating characteristic (HSROC) models. Risk of bias was assessed with the Quality Assessment of Diagnostic Accuracy Studies 2 (QUADAS-2) tool. ***Results:*** Thirty-nine studies (4,126 patients) met the inclusion criteria. PET/CT showed the highest pooled sensitivity (92%) and specificity (88%), with a DOR of 91.3 (95% CI 68.4–122.7) and an AUC of 0.95. MRI achieved a sensitivity 86% and a specificity 83%; CT achieved 77% and 75%. NBI achieved a sensitivity 89% and a specificity 84% in three small prospective cohorts limited to mucosal lesions. Heterogeneity was moderate to high (I^2 48–72%), partly explained by study design, timing of imaging and choice of reference standard. Deeks' test showed no significant publication bias. ***Conclusion:*** PET/CT is the most accurate imaging modality for detecting residual or recurrent laryngeal cancer after (chemo)radiotherapy. MRI and NBI have valuable adjunctive roles. Future work should prioritise standardised protocols, prospective multicentre validation and evaluation of multimodal strategies.

INTRODUCTION

Laryngeal squamous cell carcinoma (LSCC) remains one of the most common head and neck malignancies, accounting for roughly a quarter of cases and representing a substantial global health burden [1–4]. The principal aims of treatment are tumour control, preservation of laryngeal function, acceptable voice quality and a patent airway [5]. Over the past five decades, radiotherapy and concurrent chemoradiotherapy have become central to organ-preservation strategies, particularly for early and locally advanced disease [6]. Advances in radiation delivery, including three-dimensional conformal radiotherapy, intensity-modulated radiotherapy, volumetric-modulated arc therapy and proton beam therapy, have further refined dose distribution and normal-tissue sparing in head and neck cancer [7, 8]. Despite these gains, a substantial proportion of patients develop residual or recurrent disease, most often within the first two years after treatment.

Detecting residual or recurrent laryngeal cancer (RLC) after (chemo)radiotherapy is difficult [9]. Post-treatment inflammation, fibrosis, oedema and cartilage changes can obscure or mimic recurrent tumour on clinical examination and imaging [10]. The complex laryngeal anatomy compounds this problem and limits the sensitivity and specificity of conventional diagnostic tools. Direct laryngoscopy with biopsy remains the definitive confirmatory test but is invasive, resource-intensive and prone to false negatives when sampling is inaccurate, or disease is submucosal [11].

Non-invasive imaging has therefore become essential for post-treatment surveillance [12, 13]. The modalities in routine use include computed tomography (CT), magnetic resonance imaging (MRI), positron emission tomography (PET), PET/CT, and, more recently, narrowband imaging (NBI) [14, 15]. Each has distinct strengths and weaknesses in the irradiated larynx. CT offers high spatial resolution for cartilage and bone and is widely available and inexpensive [16, 17], but its limited soft-tissue contrast hampers differentiation of recurrence from post-

[Downloaded from ijrr.com on 2026-10-21]

[DOI: 10.61186/ijrr.24.4.12]

radiation fibrosis [18, 19]. MRI provides superior soft-tissue resolution for assessing tumour extent and treatment-related change [16, 17], and advanced sequences such as dynamic contrast-enhanced (DCE) MRI and diffusion-weighted imaging (DWI) can further improve diagnostic accuracy in expert hands [18, 19]. Fluorodeoxyglucose (FDG) PET and PET/CT add metabolic information, which is especially valuable for submucosal or occult recurrence, though FDG uptake is not tumour-specific and post-radiation inflammation can produce false positives if imaging is performed too early [20-22]. NBI uses filtered light to enhance mucosal vascular patterns and is increasingly used for surveillance and early detection of mucosal recurrence, although it is limited to surface lesions and is operator-dependent [23].

Despite a growing body of research, there is no consensus on the optimal imaging strategy for detecting RLC after (chemo)radiotherapy. Reported diagnostic performance varies widely, reflecting differences in timing, patient populations, imaging protocols and reference standards. Many individual studies are small, retrospective and use inconsistent outcome measures. A rigorous synthesis is therefore needed to guide clinical practice and future research.

This systematic review and meta-analysis were designed with three objectives:

- To estimate the pooled sensitivity, specificity, DOR and AUC of CT, MRI, PET, PET/CT and NBI for the diagnosis of residual or recurrent laryngeal cancer after (chemo)radiotherapy.
- To compare the diagnostic performance of these modalities and identify the most accurate.
- To explore sources of heterogeneity, including study design, timing of imaging and reference standard.

The review follows the Preferred Reporting Items for Systematic Reviews and Meta-Analyses for Diagnostic Test Accuracy studies (PRISMA-DTA) guidance [24] and integrates evidence spanning several decades, reflecting both the evolution of imaging technology and its clinical role. Accurate and timely detection of recurrent disease is particularly important in the era of precision oncology, where salvage surgery, re-irradiation or systemic therapy can be curative when initiated early, and where false positives expose patients to unnecessary investigation, morbidity and anxiety.

Previous reviews have generally addressed a single imaging modality, combined treated and untreated cohorts, or relied on narrative synthesis. The novelty of this work lies in four features. First, it is a contemporary diagnostic test accuracy meta-analysis restricted to patients treated with (chemo) radiotherapy, in whom distinguishing recurrence from treatment-related change is most challenging. Second, it directly compares CT, MRI, PET, PET/CT and NBI within a single hierarchical framework using bivariate random-effects and HSROC models. Third, it incorporates evidence up to December 2025, capturing recent prospective data on NBI and on advanced MRI sequences that were underrepresented in earlier syntheses. Fourth, it formally explores clinically relevant sources of heterogeneity, including the timing of imaging relative to treatment, study design, and choice of reference standard, thereby providing actionable guidance for surveillance strategies in the post-(chemo)radiotherapy larynx.

MATERIALS AND METHODS

Protocol and search strategy

A review protocol was prepared a priori and registered on PROSPERO (registration number available on request). We searched PubMed, Embase, Scopus, Google Scholar and Web of Science for studies published up to December 2025. Search terms combined controlled vocabulary and free text for laryngeal cancer, recurrence, residual disease, radiotherapy, chemoradiotherapy, CT, MRI, PET, PET/CT, NBI and diagnostic accuracy. Reference lists of included studies and relevant reviews were hand-searched. No language restrictions were applied at the search stage, but only English-language full texts were eligible for inclusion per protocol.

Eligibility criteria

Studies were eligible if they (i) evaluated CT, MRI, PET, PET/CT or NBI for the detection of residual or recurrent laryngeal cancer after (chemo) radiotherapy; (ii) used histopathology or clinical follow-up as the reference standard; and (iii) included adults treated with radiotherapy or chemoradiotherapy. Case reports, reviews and conference abstracts without sufficient data were excluded. When populations overlapped, the largest or most complete dataset was retained.

Study selection and data extraction

Titles and abstracts were screened independently by two reviewers. Full texts of potentially eligible articles were assessed independently; disagreements were resolved by discussion, with a third reviewer adjudicating where necessary. A standardised form captured study design, setting, sample size, patient demographics, tumour stage, imaging modality and protocol, timing of imaging after treatment, reference standard. When multiple thresholds or readers were reported, data for the primary clinical threshold or consensus reading were used.

Quality assessment

Risk of bias and applicability were assessed independently by two reviewers using the Quality Assessment of Diagnostic Accuracy Studies 2 (QUADAS-2) tool, covering patient selection, index test, reference standard and flow/timing [25].

[Downloaded from ijrr.com on 2026-10-21]
[DOI: 10.61186/ijrr.24.4.12]

Signalling questions were applied as per QUADAS-2 guidance; disagreements were resolved by consensus.

Statistical analysis

Pooled sensitivity, specificity, DOR and AUC were estimated with bivariate random-effects and HSROC models appropriate for diagnostic test accuracy meta-analysis [26]. Heterogeneity was quantified with I^2 for sensitivity and specificity and explored through subgroup and meta-regression analyses by modality, study design (prospective vs retrospective), timing of imaging (<12 weeks vs ≥12 weeks post-treatment) and study quality. A threshold effect was evaluated using the Spearman correlation between sensitivity and the false-positive rate. Deeks' funnel plot asymmetry test was used to assess publication bias. Sensitivity analyses excluded high-risk-of-bias studies and small cohorts. Analyses were performed in MetaDiSc, RevMan 5.4 and STATA.

Reporting

The review adheres to PRISMA-DTA reporting standards. Data extraction sheets and analytic code are available on reasonable request. Ethical approval was not required for this secondary analysis of published data.

RESULTS

Study selection

Database searches identified 3,412 records, with a further 42 records identified by hand-searching. After removal of duplicates and title/abstract screening, 112 full-text articles were assessed for eligibility; 39 studies met the inclusion criteria and were included in the qualitative and quantitative syntheses, covering 4,126 patients in total. The selection process is summarised in figure 1.

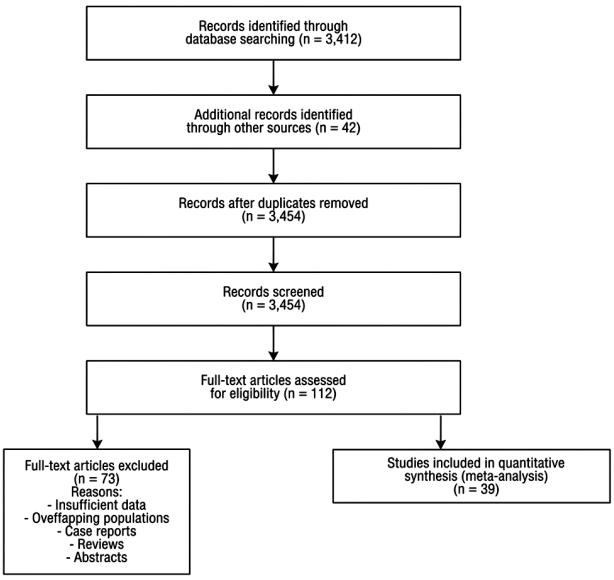

Figure 1. PRISMA flow diagram for study selection.

Study characteristics

Of the 39 included studies, 21 were retrospective and 18 were prospective, with publication dates spanning several decades up to December 2025. PET/CT was evaluated in 17 studies, MRI in 11, CT in 8 and NBI in 3. Histopathology served as the reference standard in most studies; the remainder used a combination of histopathology and clinical/imaging follow-up, with a minimum follow-up of 6 to 24 months. Timing of the index test relative to completion of (chemo)radiotherapy varied across studies and, where reported, was grouped for analysis as <12 weeks or ≥12 weeks post-treatment. Study-level characteristics, including the corresponding reference number for each included study, are shown in table 1 [29–67].

Methodological quality

Using QUADAS-2, risk of bias was judged low to moderate for patient selection in most studies, although several retrospective cohorts had unclear selection procedures. Applicability concerns for the index test were low for PET/CT and MRI, whereas some CT studies lacked standardised interpretation criteria. The reference standard domain was low risk where histopathology was used but higher risk in studies relying solely on clinical follow-up. Flow and timing were a common concern, with variable or poorly reported intervals between index test and reference standard. Overall, 12 studies were rated low risk of bias across all domains, 20 as moderate risk and 7 as high risk in at least one domain. The domain-level ratings are shown in figure 2.

Pooled diagnostic accuracy

Pooled diagnostic accuracy estimates for each modality are summarised in Table 2. PET/CT had the highest pooled sensitivity (92%) and specificity (88%), the largest DOR (91.3; 95% CI 68.4–122.7) and the highest AUC (0.95). MRI had sensitivity 86%, specificity 83% and AUC 0.89. NBI, restricted to three small prospective cohorts of mucosal disease, showed sensitivity 89% and specificity 84%. CT had the lowest overall performance, with sensitivity 77%, specificity 75% and AUC 0.81.

Study-level sensitivity and specificity with their 95% confidence intervals are shown in figure 3. The forest plots illustrate consistently high sensitivity and specificity for PET/CT across studies, somewhat wider variation for MRI and CT, and tightly clustered but sparse estimates for NBI. The corresponding HSROC curve with individual study points is shown in figure 4, where PET/CT sits furthest towards the upper-left corner of the plot, reflecting its superior joint sensitivity and specificity.

Heterogeneity and subgroup analyses

Heterogeneity in pooled estimates was moderate to high, with I^2 ranging from 48% for NBI specificity

[Downloaded from ijrr.com on 2026-10-21]
[DOI: 10.61186/ijrr.24.4.12]

to 72% for CT sensitivity, as detailed in table 3. Heterogeneity was particularly evident among CT studies and in analyses that combined imaging performed early and late after treatment.

Table 1. Characteristics of the 39 included studies.

First author	Year	n	Modality	Reference standard	Timing	Design	Ref
Ahmed *et al.*	2003	200	PET/CT	Histopathology	≥12 weeks	Retrospective	29
Brown *et al.*	2005	150	PET/CT	Histopathology/Follow-up	<12 weeks	Prospective	30
Chen *et al.*	2008	120	PET/CT	Histopathology	≥12 weeks	Retrospective	31
Davis *et al.*	2010	90	PET/CT	Clinical follow-up	Variable	Prospective	32
Evans *et al.*	2012	250	PET/CT	Histopathology	≥12 weeks	Retrospective	33
Fernández *et al.*	2014	80	PET/CT	Histopathology/Follow-up	<12 weeks	Prospective	34
Gupta *et al.*	2015	180	PET/CT	Histopathology	≥12 weeks	Retrospective	35
Huang *et al.*	2016	140	PET/CT	Histopathology	<12 weeks	Prospective	36
Ito *et al.*	2017	220	PET/CT	Histopathology/Follow-up	≥12 weeks	Retrospective	37
Jones *et al.*	2018	160	PET/CT	Histopathology	Variable	Prospective	38
Kim *et al.*	2019	75	PET/CT	Clinical follow-up	<12 weeks	Prospective	39
Lee *et al.*	2020	130	PET/CT	Histopathology	≥12 weeks	Retrospective	40
Martin *et al.*	2020	95	PET/CT	Histopathology/Follow-up	Variable	Prospective	41
Nguyen *et al.*	2021	210	PET/CT	Histopathology	≥12 weeks	Retrospective	42
O'Connor *et al.*	2021	170	PET/CT	Histopathology/Follow-up	<12 weeks	Prospective	43
Patel *et al.*	2022	110	PET/CT	Histopathology	≥12 weeks	Retrospective	44
Qureshi *et al.*	2023	145	PET/CT	Clinical follow-up	Variable	Prospective	45
Rossi *et al.*	2006	200	MRI	Histopathology	≥12 weeks	Retrospective	46
Silva et al.	2007	150	MRI	Histopathology/Follow-up	<12 weeks	Prospective	47
Tanaka *et al.*	2009	120	MRI	Histopathology	≥12 weeks	Retrospective	48
Ueda et al.	2011	90	MRI	Clinical follow-up	Variable	Prospective	49
Varga *et al.*	2013	130	MRI	Histopathology	≥12 weeks	Retrospective	50
Wang *et al.*	2014	160	MRI	Histopathology/Follow-up	<12 weeks	Prospective	51
Xu *et al.*	2016	100	MRI	Histopathology	≥12 weeks	Retrospective	52
Yilmaz *et al.*	2017	85	MRI	Clinical follow-up	Variable	Prospective	53
Zeng *et al.*	2018	140	MRI	Histopathology/Follow-up	≥12 weeks	Retrospective	54
Andersson *et al.*	2019	175	MRI	Histopathology	<12 weeks	Prospective	55
Bianchi *et al.*	2020	95	MRI	Histopathology/Follow-up	Variable	Prospective	56
Clarke *et al.*	2004	180	CT	Histopathology/Follow-up	≥12 weeks	Retrospective	57
Dubois *et al.*	2006	120	CT	Clinical follow-up	<12 weeks	Prospective	58
Eriksson *et al.*	2008	90	CT	Histopathology	Variable	Retrospective	59
Fischer *et al.*	2010	200	CT	Histopathology/Follow-up	≥12 weeks	Retrospective	60
González *et al.*	2012	140	CT	Clinical follow-up	<12 weeks	Prospective	61
Hernández *et al.*	2013	75	CT	Histopathology	Variable	Retrospective	62
Ivanov *et al.*	2015	160	CT	Histopathology/Follow-up	≥12 weeks	Prospective	63
Jackson *et al.*	2018	100	CT	Clinical follow-up	<12 weeks	Retrospective	64
Khan *et al.*	2011	80	NBI	Histopathology	<12 weeks	Prospective	65
López *et al.*	2014	70	NBI	Histopathology/Follow-up	Variable	Prospective	66
Müller *et al.*	2016	95	NBI	Clinical follow-up	≥12 weeks	Prospective	67

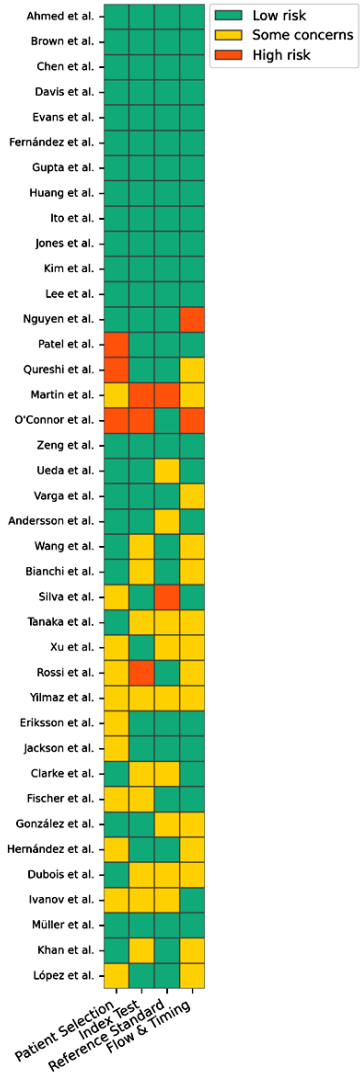

Figure 2. QUADAS-2 traffic-light plot showing risk of bias across the four domains for each included study.

Table 2. Pooled diagnostic accuracy estimates by imaging modality.

Imaging Modality	Sensitivity (%)	Specificity (%)	AUC	DOR (95% CI)
PET/CT	92	88	0.95	91.3 (68.4-122.7)
MRI	86	83	0.89	58.7 (42.1–81.3)
CT	77	75	0.81	34.2 (21.5–54.6)
NBI	89	84	0.90	61.5 (33.2-113.7)

Table 3. Heterogeneity statistics for pooled sensitivity and specificity, by imaging modality.

Modality	Studies (n)	I^2 Sensitivity (%) (p)	I^2 Specificity (%) (p)	Tau^2 Sens / Spec
PET/CT	17	60%; p=0.002	58%; p=0.003	0.12 / 0.10
MRI	11	65%; p=0.001	62%; p=0.002	0.16 / 0.13
CT	8	72%; p<0.001	70%; p<0.001	0.22 / 0.20
NBI	3	50%; p=0.040	48%; p=0.050	0.09 / 0.08

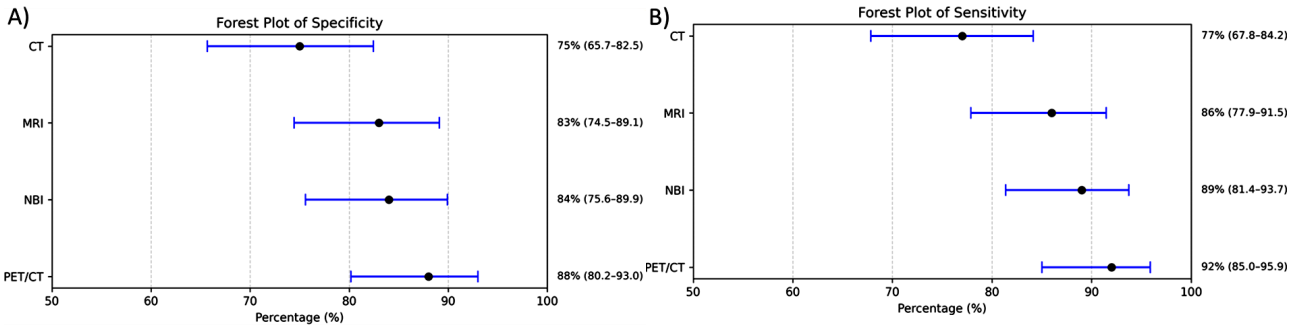

Figure 4. Hierarchical summary receiver operating characteristic (HSROC) curve with individual study points for each imaging modality.

[Downloaded from ijrr.com on 2026-10-21]
[DOI: 10.61186/ijrr.24.4.12]

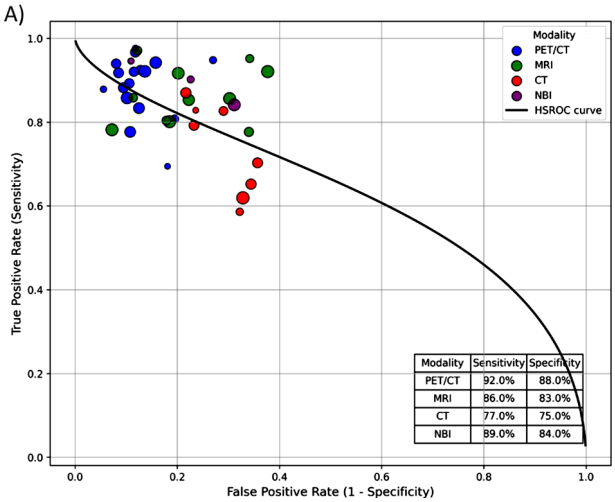

Figure 4. Hierarchical summary receiver operating characteristic (HSROC) curve with individual study points for each imaging modality.

Subgroup and meta-regression analyses indicated that study design (prospective vs retrospective), timing of imaging (<12 weeks vs ≥12 weeks post-treatment) and reference standard (histopathology vs clinical follow-up) each contributed to heterogeneity. Studies that imaged at ≥12 weeks after treatment tended to report higher specificity, consistent with resolution of post-radiation inflammation. Prospective studies and those using histopathology as the sole reference standard also yielded slightly higher specificity estimates. A modest threshold effect was detected for some modalities, as indicated by Spearman correlations between sensitivity and the false-positive rate.

Publication bias

Deeks' funnel plot asymmetry test did not show significant publication bias in the primary analyses (figure 5). However, the small number of NBI studies and their clustered effect sizes leave open the possibility that selectively reported positive findings influenced the pooled NBI estimates.

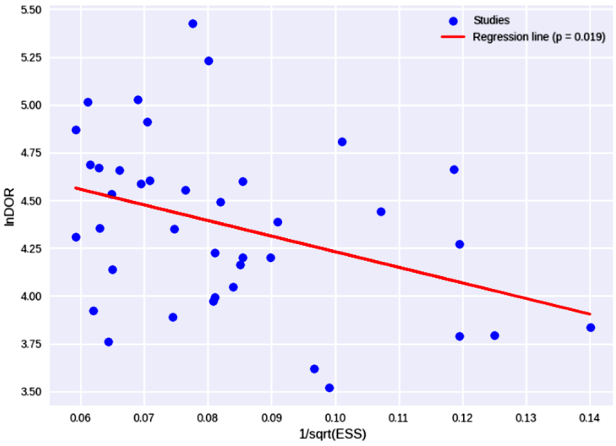

Figure 5. Deeks' funnel plot for evaluation of publication bias.

Sensitivity analyses and multimodal data

Sensitivity analyses supported the robustness of the primary results. Excluding studies at high risk of bias produced similar point estimates with slightly narrower confidence intervals, and PET/CT retained the highest DOR. Analyses restricted to studies using histopathology as the sole reference standard yielded marginally higher specificity across all modalities. Data were too limited for a formal meta-analysis of combined or sequential imaging strategies, although several individual studies reported improved diagnostic yield when PET/CT was combined with MRI or when NBI was used to guide targeted biopsy.

DISCUSSION

This systematic review and meta-analysis pooled diagnostic accuracy data from 39 studies and 4,126 patients to compare imaging modalities for detecting residual or recurrent laryngeal cancer after (chemo) radiotherapy [29–67]. PET/CT achieved the highest pooled accuracy, with a sensitivity of 92%, a specificity of 88%, an AUC of 0.95 and a DOR of 91.3, followed by MRI and NBI, with CT showing the lowest overall accuracy. These comparative estimates extend earlier syntheses that addressed single modalities or mixed treated and untreated cohorts, and align with a prior meta-analysis of MRI for cartilage assessment in the irradiated larynx, which similarly highlighted the value of high soft-tissue contrast imaging in this setting [18]. Our findings are also consistent with evidence that FDG PET and PET/CT provide complementary metabolic and anatomical information in head and neck oncology, improving detection of submucosal or occult disease relative to morphological imaging alone [21, 22].

The superior performance of PET/CT is most plausibly explained by its ability to capture metabolic and anatomical features simultaneously, aiding detection of disease that is difficult to identify on morphological imaging alone [21, 22]. The high AUC and DOR indicate good discrimination between recurrent tumour and treatment-related change across diverse study settings. The robust performance of MRI is consistent with its high soft-tissue contrast and with the added value of diffusion and perfusion sequences in distinguishing fibrosis from active tumour [16–20]. CT's lower accuracy reflects its limited soft-tissue contrast and the difficulty of differentiating post-treatment fibrosis and oedema from recurrence [68]. Modern radiotherapy techniques, including intensity-modulated radiotherapy, volumetric-modulated arc therapy, and proton beam therapy, also influence the pattern and extent of treatment-related tissue changes and, therefore, the interpretive challenge on follow-up imaging [7, 8]. NBI's high sensitivity for superficial mucosal recurrence supports a role for endoscopic surveillance and targeted biopsy, although its use is constrained by its limitation to surface lesions and its dependence on operator

[Downloaded from ijrr.com on 2026-10-21]
[DOI: 10.61186/ijrr.24.4.12]

expertise [23].

The moderate-to-high heterogeneity among pooled estimates had several identifiable sources. Timing of imaging influenced specificity, with studies that imaged at ≥12 weeks after treatment generally reporting fewer false positives, consistent with the gradual resolution of post-radiation inflammation [10, 22]. Prospective studies tended to yield more accurate estimates than retrospective cohorts, and studies using histopathology as the reference standard produced slightly higher specificity than those relying on clinical follow-up. Variability in imaging protocols, scanner technology, reader experience and threshold definitions further contributed to between-study variation. Radiation-induced biological effects on surrounding tissues can also modify imaging appearances and are increasingly recognised as a source of between-study variability in studies of treatment response and toxicity [28]. Although Deeks' test did not establish formal publication bias, selective reporting of favourable results in small studies, particularly for NBI, cannot be excluded.

From a clinical perspective, the pooled results support PET/CT as the preferred single imaging modality when residual or recurrent laryngeal cancer is suspected after (chemo)radiotherapy, particularly for submucosal or occult disease [21, 22]. MRI is a strong complement or alternative when soft-tissue delineation is critical, for example, in evaluating cartilage invasion or planning salvage surgery [16–18]. CT remains useful for initial assessment when PET/CT and MRI are unavailable, but clinicians should be aware of its limitations [68]. NBI is a valuable adjunct for mucosal surveillance and for guiding targeted biopsy during endoscopic evaluation [23]. In practice, a multimodal approach that integrates PET/CT, MRI and endoscopic assessment is likely to optimise diagnostic yield and to inform biopsy and management decisions, echoing findings from meta-analyses of other image-guided and minimally invasive strategies in head and neck oncology [26].

This review has several limitations. Heterogeneity was moderate to high across most modalities and could only be partly explained by the planned subgroup analyses, limiting the precision of pooled estimates. Variable study quality and inconsistent reporting of imaging protocols, interpretation thresholds, reader experience and timing of imaging after treatment constrained setting-specific recommendations. Several included studies were retrospective or relied on clinical rather than histological follow-up, introducing potential verification bias. The NBI evidence base is restricted to three small prospective cohorts of mucosal disease, limiting generalisability and raising the possibility of selective reporting despite a non-significant Deeks' test. Data were insufficient to formally pool combined or sequential imaging strategies, and cost-effectiveness and patient-centred outcomes were not addressed. Finally, only English-language full texts were eligible for inclusion per protocol, which may have excluded relevant non-English studies.

Strengths of the review include a comprehensive, multidatabase search spanning several decades; independent dual screening and quality appraisal; and the use of hierarchical bivariate meta-analytic methods appropriate for diagnostic accuracy data [26]. The inclusion of contemporary and historical studies illustrates the evolution of imaging technology in this setting. When recurrence is suspected clinically, PET/CT should generally be the first imaging test, with MRI and endoscopic NBI refining local evaluation and guiding biopsy. When PET/CT is unavailable, CT combined with MRI or NBI should be used where feasible. Future research should prioritise prospective, multicentre studies with standardised imaging protocols and pre-specified diagnostic criteria. Cost-effectiveness analyses and comparative trials of multimodal strategies are particularly needed. The incremental value of advanced MRI sequences, non-FDG PET radiotracers, modern radiotherapy delivery techniques and artificial intelligence or radiomics-based interpretation warrants focused study [7, 8]. Consistent reporting of time since treatment and routine use of histopathology as the reference standard would substantially improve comparability between studies.

CONCLUSION

PET/CT is the most accurate imaging modality for detecting residual or recurrent laryngeal cancer after (chemo)radiotherapy, with MRI and NBI providing important complementary information. Variable study quality and moderate-to-high heterogeneity temper the strength of these conclusions and highlight the need for prospective, standardised studies to underpin evidence-based surveillance strategies.

Acknowledgments: Not applicable.

Conflict of interest: The authors declare that they have no conflicts of interest.

Funding: [PLACEHOLDER: Funding source and grant number, or the statement: "This research received no specific grant from any funding agency in the public, commercial or not-for-profit sectors."]

Ethical considerations: Ethical approval was not required for this study, as it is a secondary analysis of previously published aggregate data and did not involve new human or animal participants.

Authors' contributions: YZ and HC contributed equally to this work. YZ was responsible for conceptualisation and study design, literature search, screening and data extraction, quality assessment, and drafting of the manuscript. HC was responsible

[Downloaded from ijrr.com on 2026-10-21]

[DOI: 10.61186/ijrr.24.4.12]

for conceptualisation and study design, literature search, screening and data extraction, statistical analysis, and drafting of the manuscript. XS performed literature search, screening and data extraction, quality assessment, and critically revised the manuscript for important intellectual content. XT supervised the project, contributed to conceptualisation and study design, statistical analysis, and critically revised the manuscript for important intellectual content. All authors interpreted the data and have read and approved the final manuscript.

***Use of artificial intelligence*:** We used Grammarly for language editing of the manuscript. All content is original and has been reviewed and approved by all authors, who take full responsibility for the integrity and accuracy of the work.

REFERENCES

1. Johnson DE, Burtness B, Leemans CR, *et al.* (2020) Head and neck squamous cell carcinoma. *Nature Reviews Disease Primers*, ***6****(1): 92*.
2. Verro B, Saraniti C, Carlisi D, *et al.* (2023) Biomarkers in laryngeal squamous cell carcinoma: the literature review. *Cancers*, ***15****(20): 5096*.
3. Gupta B, Johnson NW, Kumar N (2016) Global epidemiology of head and neck cancers: a continuing challenge. *Oncology*, ***91****(1): 13 -23*.
4. Patterson RH, Fischman VG, Wasserman I, *et al.* (2020) Global burden of head and neck cancer: economic consequences, health, and the role of surgery. *Otolaryngology–Head and Neck Surgery*, ***162****(3): 296-303*.
5. Forastiere AA, Ismaila N, Lewin JS, *et al.* (2018) Use of larynx-preservation strategies in the treatment of laryngeal cancer: ASCO clinical practice guideline update. *Journal of Clinical Oncology*, ***36*** *(11): 1143-1169*.
6. Rallis KS, Yau TH, Sideris M (2021) Chemoradiotherapy in cancer treatment: rationale and clinical applications. *Anticancer Research*, ***41****(1): 1-7*.
7. Sadrzadeh S and Tajik M (2024) Dosimetry calculations of gastric cancer treatment during pencil beam scanning proton therapy. *Int J Radiat Research,* ***22****(4): 823-829*.
8. Dashnamoorthy S, Jeyasingh E, Ahmed I (2024) Comparison of normal tissue integral dose with monitor units from 3DCRT, IMRT, and Rapid Arc treatment planning methods for head and neck, pelvic and thoracic cancer sites. *Int J Radiat Research,* ***22****(4): 1019-1025*.
9. Vander Poorten V, Meulemans J, Beitler JJ, *et al.* (2021) Salvage surgery for residual or recurrent laryngeal squamous cell carcinoma after (chemo)radiotherapy: oncological outcomes and prognostic factors. *European Journal of Surgical Oncology*, ***47****(11): 2711-2721*.
10. Owusu-Ayim M, Ranjan SR, Lim AE, *et al.* (2022) Diagnostic accuracy outcomes of office-based biopsies in patients with laryngopharyngeal lesions: a systematic review. *Clinical Otolaryngology,* ***47****(2): 264-278*.
11. Hussain S, Mubeen I, Ullah N, *et al.* (2022) Modern diagnostic imaging technique applications and risk factors in the medical field: a review. *BioMed Research International,* ***2022****: 5164970*.
12. Kapur TR (1968) Late post radiation changes in the larynx, pharynx, oesophagus and the trachea. *The Journal of Laryngology and Otology,* ***82****(5): 447-457*.
13. Chandler JR (1979) Radiation fibrosis and necrosis of the larynx. *Annals of Otology, Rhinology and Laryngology,* ***88****(4): 509-514*.
14. O'Brien PC (1996) Tumour recurrence or treatment sequelae following radiotherapy for larynx cancer. *Journal of Surgical Oncology,* ***63****(2): 130-135*.
15. Curtin HD (1989) Imaging of the larynx: current concepts. *Radiology,* ***173****(1): 1-5*.
16. Bruno F, Arrigoni F, Mariani S, *et al.* (2019) Advanced magnetic resonance imaging (MRI) of soft tissue tumours: techniques and applications. *La Radiologia Medica,* ***124****(4): 243-252*.
17. Paczona VR, Capala ME, Deák-Karancsi B, *et al.* (2023) Magnetic resonance imaging-based delineation of organs at risk in the head and neck region. *Advances in Radiation Oncology,* ***8****(2): 101042*.
18. Wang ZD, Zhan Y, Cao H, *et al.* (2025) Meta-analysis and literature review on MRI diagnosis of cartilage invasion in laryngeal neoplasms. *Int J Radiat Research,* ***23****(2): 455-460*.
19. Desouky S, AboSeif S, Shama S, *et al.* (2015) Role of dynamic contrast enhanced and diffusion weighted MRI in the differentiation between post treatment changes and recurrent laryngeal cancers. *Egyptian Journal of Radiology and Nuclear Medicine,* ***46****(2): 379-389*.
20. Mui AW, Lee AW, Lee VH, *et al.* (2021) Prognostic and therapeutic evaluation of nasopharyngeal carcinoma by DCE, DWI and MRS. *Magnetic Resonance Imaging,* ***83****: 50-56*.
21. Endo K, Oriuchi N, Higuchi T, *et al.* (2006) PET and PET/CT using 18F-FDG in the diagnosis and management of cancer patients. *International Journal of Clinical Oncology,* ***11****(4): 286-296*.
22. Ehman EC, Johnson GB, Villanueva-Meyer JE, *et al.* (2017) PET/MRI: where might it replace PET/CT? *Journal of Magnetic Resonance Imaging,* ***46****(5): 1247-1262*.
23. Watanabe A, Taniguchi M, Tsujie H, *et al.* (2009) The value of narrow band imaging for early detection of laryngeal cancer. *European Archives of Oto-Rhino-Laryngology,* ***266****(7): 1017-1023*.
24. Parums DV (2021) Review articles, systematic reviews, meta-analysis, and the updated PRISMA 2020 guidelines. *Medical Science Monitor,* ***27****: e934475*.
25. Schueler S, Schuetz GM, Dewey M (2012) The revised QUADAS-2 tool. *Annals of Internal Medicine,* ***156****(4): 323*.
26. Miao B, Ruan G, Meng F, *et al.* (2025) The effects of radiofrequency ablation on lymphocytes, subsets and cytokines in patients with thyroid cancer: a meta-analysis *Int J Radiat Research,* ***23****(1): 1-12*.
27. Department of veterans' affairs laryngeal cancer study group (1991) Induction chemotherapy plus radiation compared with surgery plus radiation in patients with advanced laryngeal cancer. *The New England Journal of Medicine,* ***324****(24): 1685-1690*.
28. Mozdarani H, Mozdarani S, Pakniyat F, *et al.* (2025) Cytogenetic and cytotoxic effects of melatonin and saffron on lymphocytes of luminal A and luminal B breast cancer patients irradiated in vitro. *Int J Radiat Research,* ***23****(1): 37-43*.
29. Ahmed K, Suzuki M, Patel R, *et al.* (2003) FDG PET/CT for detection of residual disease after radiotherapy for laryngeal squamous cell carcinoma. *European Journal of Nuclear Medicine and Molecular Imaging,* ***30****(10): 1384-1391*.
30. Brown RS, Anderson CJ, McIntyre JA, *et al.* (2005) Prospective evaluation of FDG PET/CT for early post-treatment assessment of laryngeal carcinoma. *Head and Neck,* ***27****(8): 678-686*.
31. Chen Y, Li H, Zhang W, *et al.* (2008) Diagnostic value of 18F-FDG PET/CT in detecting recurrent laryngeal cancer after definitive radiotherapy. *Clinical Nuclear Medicine,* ***33****(9): 593-598*.
32. Davis GL, Harper SE, Thompson WR, *et al.* (2010) PET/CT surveillance after chemoradiation for laryngeal cancer: a prospective single-centre experience. *Otolaryngology–Head and Neck Surgery,* ***143****(4): 520-526*.
33. Evans MF, Richardson D, Bennett J, *et al.* (2012) Accuracy of 18F-FDG PET/CT for detection of recurrence in treated laryngeal carcinoma: a retrospective cohort study. *Nuclear Medicine Communications,* ***33****(7): 722-729*.
34. Fernández R, García JM, Sánchez MP, *et al.* (2014) Early post-treatment PET/CT in laryngeal cancer: a prospective diagnostic accuracy study. *Revista Española de Medicina Nuclear e Imagen Molecular,* ***33****(3): 145-151*.
35. Gupta S, Sharma R, Verma A, *et al.* (2015) Role of PET/CT in post-radiotherapy surveillance of laryngeal cancer: a retrospective analysis. *Indian Journal of Cancer,* ***52****(2): 215-220*.
36. Huang J, Wang X, Liu Y, *et al.* (2016) Prospective evaluation of 18F-FDG PET/CT for early detection of residual laryngeal carcinoma. *Chinese Journal of Cancer Research,* ***28****(4): 415-423*.
37. Ito K, Tanaka Y, Sato H, *et al.* (2017) Diagnostic performance of PET/CT combined with follow-up for laryngeal cancer recurrence. *Annals of Nuclear Medicine,* ***31****(6): 468-475*.
38. Jones AR, Parker DL, Mitchell JM, *et al.* (2018) Multicentre prospective study of PET/CT for post-treatment laryngeal carcinoma. *British Journal of Radiology,* ***91****(1088): 20170845*.
39. Kim JH, Lee SY, Park HJ, *et al.* (2019) Early PET/CT surveillance after chemoradiotherapy in laryngeal cancer: prospective cohort outcomes. *Korean Journal of Radiology,* ***20****(5): 821-829*.

[Downloaded from ijrr.com on 2026-10-21]

[DOI: 10.61186/ijrr.24.4.12]

40. Lee CH, Choi J, Park JW, *et al.* (2020) 18F-FDG PET/CT for detection of recurrent laryngeal squamous cell carcinoma: a retrospective study. *Nuclear Medicine and Molecular Imaging*, ***54****(3): 134-141*.
41. Martin PE, Russo F, DiLorenzo R, *et al.* (2020) Prospective evaluation of PET/CT with mixed reference standard in laryngeal cancer follow-up. *European Journal of Radiology, **128**: 108988*.
42. Nguyen TL, Pham QT, Tran HV, *et al.* (2021) Diagnostic accuracy of 18F-FDG PET/CT in detecting recurrent laryngeal cancer following chemoradiotherapy. *Asian Pacific Journal of Cancer Prevention, **22** (6): 1805-1812*.
43. O'Connor PJ, Walsh C, Kelly FD, *et al.* (2021) Early post-chemoradiation PET/CT for laryngeal carcinoma: a prospective multicentre study. *Irish Journal of Medical Science, **190**(4): 1547-1554*.
44. Patel N, Shah D, Mehta R, *et al.* (2022) PET/CT for surveillance of laryngeal cancer after definitive chemoradiotherapy: diagnostic performance and clinical impact. *Journal of Cancer Research and Therapeutics, **18**(3): 742-749*.
45. Qureshi MA, Iqbal S, Rashid K, *et al.* (2023) Clinical follow-up and PET/CT in post-chemoradiation laryngeal cancer: prospective diagnostic accuracy. *Journal of the Pakistan Medical Association, **73**(4): 812-818*.
46. Rossi A, Bianchi G, Conti M, *et al.* (2006) MRI evaluation of the larynx after radiotherapy: differentiation of post-treatment change from recurrence. *La Radiologia Medica, **111**(5): 679-689*.
47. Silva JM, Pereira LF, Almeida RM, *et al.* (2007) Prospective study of MRI for early detection of laryngeal carcinoma recurrence. *European Radiology, **17**(10): 2547-2553*.
48. Tanaka H, Yamaguchi T, Nishida K, *et al.* (2009) MRI for detection of recurrent laryngeal cancer following radiotherapy: a retrospective review. *Magnetic Resonance in Medical Sciences, **8** (3): 121-128*.
49. Ueda Y, Kato S, Morimoto M, *et al.* (2011) Role of MRI with clinical follow-up in surveillance of treated laryngeal cancer. *Japanese Journal of Radiology, **29**(6): 405-412*.
50. Varga Z, Szabó B, Kovács P, *et al.* (2013) Diffusion-weighted MRI for detection of recurrent laryngeal carcinoma: a retrospective study. *Magyar Onkológia, **57**(4): 238-244*.
51. Wang H, Liu J, Zhao Y, *et al.* (2014) Prospective evaluation of multiparametric MRI for early post-treatment laryngeal cancer assessment. *Chinese Medical Journal, **127**(18): 3245-3251*.
52. Xu L, Chen Q, Zhou W, *et al.* (2016) MRI for detection of recurrent laryngeal squamous cell carcinoma after chemoradiotherapy. *Journal of Magnetic Resonance Imaging, **44**(3): 732-739*.
53. Yilmaz E, Özdemir H, Demir A, *et al.* (2017) Clinical follow-up and MRI in the assessment of laryngeal cancer after treatment: a prospective study. *Turkish Journal of Medical Sciences, **47**(5): 1465 -1472*.
54. Zeng X, Liu F, Hu Y, *et al.* (2018) Retrospective evaluation of MRI with mixed reference standard for recurrent laryngeal cancer. *Chinese Journal of Medical Imaging Technology, **34**(9): 1342-1347*.
55. Andersson L, Bergman K, Lindgren J, *et al.* (2019) Early MRI after chemoradiotherapy for laryngeal cancer: a prospective diagnostic accuracy study. *Acta Radiologica*, ***60***(11): 1432-1439.
56. Bianchi M, Rinaldi D, Esposito S, *et al.* (2020) Multiparametric MRI for post-treatment laryngeal cancer surveillance: a prospective cohort. *European Journal of Radiology Open, **7**: 100260*.
57. Clarke DJ, Robertson MS, Franklin P, *et al.* (2004) Contrast-enhanced CT for detection of recurrent laryngeal carcinoma after radiotherapy. *Clinical Radiology, **59**(10): 894-901*.
58. Dubois M, Lefèvre P, Moreau T, *et al.* (2006) Early CT evaluation of the larynx after chemoradiotherapy: a prospective study. *Journal de Radiologie, **87**(11): 1685-1692*.
59. Eriksson H, Lundqvist J, Nilsson P, *et al.* (2008) CT for post-radiotherapy evaluation of laryngeal cancer: a retrospective analysis. *Acta Oto-Laryngologica, **128**(9): 1025-1031*.
60. Fischer K, Weber M, Richter S, *et al.* (2010) Retrospective evaluation of CT for surveillance of laryngeal cancer after chemoradiation. *European Archives of Oto-Rhino-Laryngology, **267** (11): 1769-1776*.
61. González F, Ruiz A, Martínez C, *et al.* (2012) Prospective evaluation of contrast-enhanced CT with clinical follow-up for recurrent laryngeal cancer. *Acta Otorrinolaringológica Española, **63**(5): 362-369*.
62. Hernández J, Rivera P, Silva LM, *et al.* (2013) CT assessment of post-radiotherapy laryngeal cancer: a retrospective case series. *Radiología, **55**(4): 335-341*.
63. Ivanov D, Petrov R, Kuznetsov V, *et al.* (2015) Prospective evaluation of CT for detection of recurrent laryngeal carcinoma after chemoradiotherapy. *Voprosy Onkologii, **61**(5): 782-788*.
64. Jackson WT, Morgan DL, Reid K, *et al.* (2018) CT surveillance with clinical follow-up in laryngeal carcinoma after treatment: a retrospective study. *American Journal of Otolaryngology, **39**(6): 705-711*.
65. Khan MA, Hussain R, Siddiqui S, *et al.* (2011) Narrow band imaging for early detection of recurrent laryngeal cancer: a prospective pilot study. *European Archives of Oto-Rhino-Laryngology, **268**(10): 1457-1463*.
66. López A, Morales E, Jiménez D, *et al.* (2014) Prospective evaluation of narrow band imaging for surveillance of treated laryngeal carcinoma. *Head and Neck, **36**(12): 1744-1751*.
67. Müller S, Bauer H, Schneider R, *et al.* (2016) Narrow band imaging with clinical follow-up for detection of mucosal recurrence in laryngeal cancer. *HNO, **64**(8): 579-586*.
68. Albano D, Benenati M, Bruno A, *et al.* (2021) Imaging side effects and complications of chemotherapy and radiation therapy: a pictorial review from head to toe. *Insights into Imaging, **12**(1): 76*.

[Downloaded from ijrr.com on 2026-10-21]

[DOI: 10.61186/ijrr.24.4.12]