

Post-operative radiotherapy of keloids. A 10-years experience of kilovoltage irradiation

A. Pontoriero^{1*}, A. Potami², G. Iatì², S. Comitini³, M. Venza⁴,
N. Settineri⁵, S. Pergolizzi¹, C. De Renzis¹

¹Department of Biomedical Sciences and Morphological and Functional Images, University of Messina, Messina, Italy

²A.O.U. "G. Martino" Operative Unit of Radiation Oncology, Messina, Italy

³A.O.U. "Cannizzaro" Department of Plastic Surgery, Catania, Italy

⁴Department of Experimental Medical-Surgical, Specialized and Dentistry, University of Messina, Messina, Italy

⁵A.O.U. RR "Papardo-Piemonte" Department of Medical Physics, Messina, Italy

► Original article

ABSTRACT

* Corresponding author:

Dr. Antonio Pontoriero,

Fax: +90 2213192

E-mail: apontoriero@unime.it

Revised: Jan. 2015

Accepted: Feb. 2015

Int. J. Radiat. Res., July 2015;
13(3): 201-204

DOI: 10.7508/ijrr.2015.03.001

Background: Keloids are benign fibrous dermal tumors originating from skin injury after surgery, piercing or others wounds. **Materials and Methods:** Sixty-two patients with keloids were treated postoperatively using orthovoltage irradiation. The total dose delivered was 12 Gy in three consecutive days, 4Gy per fraction. Treatment started 24 h after surgery. The median follow-up was 44.5 months. **Results:** Grade 1 erythema was observed in 48% of patients (30/62); 20/62 patients (32%) showed telangiectasia and altered skin pigmentation as late toxicities. In 10/62 (16%) a clinical relapse was observed. **Conclusion:** The postoperative orthovoltage radiotherapy for keloids is a valid and tolerated method that reduces the risk of recurrence. **Aims:** evaluate the role of post-operative superficial orthovoltage radiotherapy in the management of keloids.

Keywords: Keloids, kilovoltage, radiotherapy.

INTRODUCTION

The skin injury, after surgery or piercing, is the leading cause of generating keloids that are benign fibrous dermal tumors. The reason is attributed to an excessive collagen formation during tissue repair after skin injury that can sometimes evolve in an unfavourable way with pathological scar formation ⁽¹⁾.

Indeed, keloids are the result of intensive and abnormal fibroblastic reaction after trauma or skin lesions that usually are located in areas of high skin tension. Keloids have a high recurrence rate after surgical resection, don't regress spontaneously but they spread on the surrounding healthy skin surface ⁽²⁾.

The physio-pathological mechanisms are not yet fully known. Among the several hypothesis

one ascribed the cause to a defect in the regulatory mechanisms of cell growth that don't recognize the healing, resulting in continued proliferation of fibroblasts for continuous activation of cell growth factors. This process contributes to the presence of baggy fiber collagen, eosinophilic and jalin ⁽³⁾.

The final clinical result of keloid formation is the development of an aesthetically unpleasant scar, and if located in certain areas of the skin (popliteal fossa, neck, forearm), may induce significant functional limitations. The injury has a marked predilection for the upper half of the body with head, neck, chest, shoulders and arms as a common location.

However other areas of the body may also damage the skin in the evolution of a keloid. In recent years, the most frequently location

observed is in the ear lobe, often associated with the use of new habitual piercing. In the US, the incidence of keloids on earlobes after piercing, estimated from a survey of 1000 women, is around 2.5% (3-5, 7).

Keloids are not uncommon in patients genetically predisposed to multiple lesions, related to previous surgery or trauma (3). Today there are several treatment options for the keloids care: laser therapy, corticosteroid therapy, intralesional chemotherapy, and use of ultrasound, excision followed by intralesional injection of corticosteroids, excision and use of radiotherapy with interstitial technique (8).

The post-operative orthovoltage radiotherapy, applied within 24 hours after surgery (6-8), is a valid therapeutic strategy for reducing the frequency of recurrence of these lesions.

Recently it was reported that the application of high doses of radiation in a short period of time (three days) establishes a biologically equivalent dose-response and, as result, an improvement in local control (8,9). The success rates reported in literature with adjuvant radiotherapy treatment is around 70-90% (7,8). In this study we addressed the effect of ionizing radiation after surgical excision on the recurrence rate of keloids.

MATERIALS AND METHODS

In our protocol all patients were irradiated on the skin area interested by the surgical scar where was located the keloid. The irradiation had been delivered within 24h after surgical treatment (figure 1). This study was approved by the Institutional Review Board (Department of Radiation Therapy, University of Messina).

The surgical scar was covered with transparent polyurethane adhesive bandage. It allowed us to analyze the affected area without touching the wound, thus reducing the risk of sepsis. In fact, the emergence of post-operative sepsis significantly increases the risk of recurrence.

The thickness of the screen depends of the quality of the orthovoltage beams employed. Lesions thicker than a centimetre were treated with superficial orthovoltage (250 kVp), while for the smallest lesions were used energies from 80 to 120 kVp. For the treatment we used a Philips, the Compactix II, capable of producing photons X from 80 to 250 kVp with prescription of maximum dose to the surface. In all patients the dose was 12 Gy/3Fx on the surface of the surgical scar. The statistical software used was OriginPro 8.6 (OriginLab Corporation, Northampton MA Usa). All variables were expressed as the mean, and standard deviation was calculated for each value. On the x-axis were the depths of measure and on the y-axis were the dose values normalized to depth 0.

RESULTS

From January 2001 to December 2009 at the Operative Unit of Radiation Oncology of University of Messina, 62 keloid patients were treated; 22 males and 40 females, with a median age of 30 years (range 11-74 years). Median follow-up time was 44.5 months (range 14-108). Patients' characteristics are summarized in table 1. Within 24 months of treatment, keloids relapse was observed in 16% of the patients; precisely, within one year in 8 patients and after the first year and within 24 months in 2 patients (figure 2). The acute toxicity to the first control was observed in 30 patients with erythema

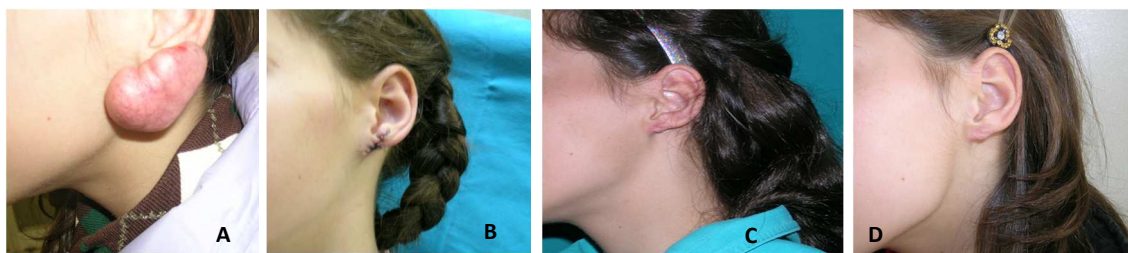


Figure 1. A case of left earlobe keloid (A) treated with surgery (B) and radiotherapy. A control after 6 months (C) and after 1 year (D).

Table 1. Patients' characteristics.

Patients (n)	62
Age (y)	
Mean	30
Range	11-74
Gender (n/%)	
Male	22 (35%)
Female	40 (65%)
Site Treated	
Ear	30 (48%)
Breast/chest wall	10 (16%)
Back	8 (13%)
Extremity	8 (13%)
Face/neck	6 (10%)

(75%) and desquamation (25%). The late toxicity was observed in 51 patients and was described with hyper or hypopigmentation (61%) and telangiectasia (39%).

DISCUSSION

After surgical excision alone an unacceptable high rate of keloid recurrence occurs. We examined the use of orthovoltage therapy for postoperative prophylactic treatment of keloids. Despite the negative view of postoperative radiotherapy expressed in the review by Leventhal *et al.* ⁽¹⁰⁾, there is a reasonably strong body of literature ⁽¹¹⁾ supporting postoperative radiotherapy for keloids opposed to surgery alone. As for keloids an important issue is that radiotherapy has to be delivered in a maximum of 10 days irrespective of fractionation. For this reason we treated in 3 days (4Gy per fraction with a total dose of 12Gy). According to Flickinger's ⁽¹¹⁾ radiobiological analysis, a 90% control rate should be observed in our patients; on the contrary we obtained an 84% control

rate. Probably we delivered a low total dose (12Gy) and higher doses than those employed by us should be employed in the adjuvant setting. In fact to obtain a 95% control rate it has been estimated that it is necessary to deliver 16.2Gy (electron beam) and 19.2 Gy (Cobalt 60) for earlobe keloids and 22.2Gy (electrons) and 24.8 Gy (Cobalt 60) for non-earlobe keloids ⁽¹¹⁾. According to BED formula we delivered 28Gy3 and 16.8Gy10 in three consecutive days without interruption; it is noteworthy that our patients were treated soon after surgical approach. Under this point of view we should underline we are inside a unique clinical scenario of irradiation soon after surgical procedure and this might also play (very short kick-off times for cell lines replications) an important role for Tumor Control Probability despite the relatively low BEDs obtained.

For similar doses the lower recurrence rates after keloid resection have been observed using electron beam or Co-60 teletherapy with respect to the low-energy X-rays which have more rapid dose fall-off with depth, such as orthovoltage ⁽¹¹⁾.

However, in order to investigate the use of orthovoltage irradiation, our data suggest an adequate irradiation of keloid with a valid physical profile of the beam (depth-dose curve) (figure 3). The corrected choice of kVp energy justifies our recurrence rates (16%) comparable with other groups which have reported similar 5-years relapse rate ^(9, 12, 13). Only one study reported a recurrence rate of 32.7% with a mean follow-up of 2 years ⁽¹⁴⁾.

The recurrence rate seems to be related to the keloids' site (ear vs. non-ear) ⁽⁷⁾; We don't observe any difference about the recurrence between the earlobe keloids and others sites; due to the low patients number no firm

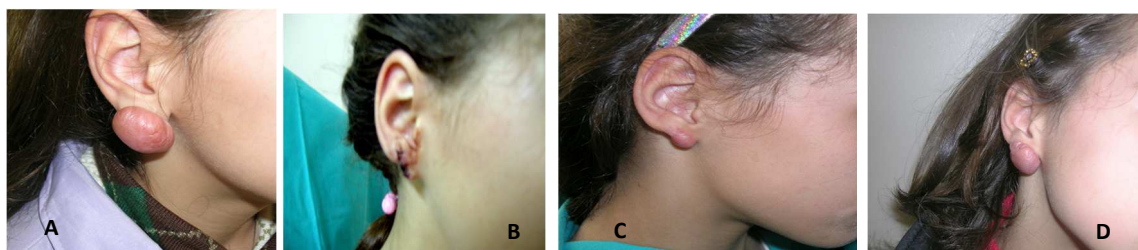


Figure 2. A case of the keloid recurrence in the right earlobe. The patient was treated in the same way in the left earlobe and she has not had recurrence. In the right earlobe (A) treated with surgery (B) and radiotherapy presents a recurrence after 6 months (C). The recurrence after 1 year (D).

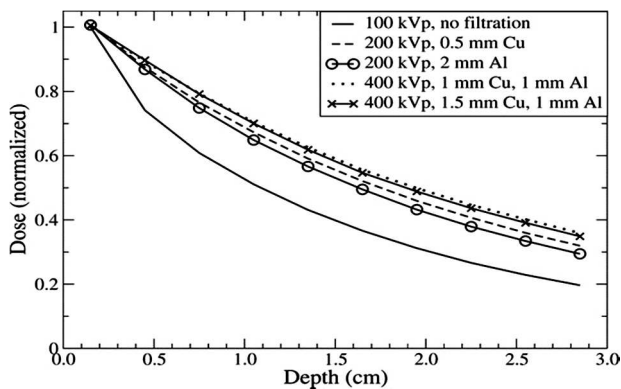


Figure 3. Percentage depth dose.

conclusion could be made on this issue.

In our patients negligible acute and late toxicities have been observed in agreement with literature data on this topic. A risk in the use of radiation therapy to treat benign lesions is the occurrence of radiation-induced cancers. However, only few studies (8, 15, 16, 17) report on radiation-induced tumours (i.e. fibrosarcoma, basal cell carcinoma, thyroid carcinoma and breast cancer) in keloids patients treated with irradiation. However we suggest that radiotherapy for keloids should be delivered with appropriate protections, especially in children.

CONCLUSION

Keloids are benign lesions characterized by recurrence. They may be aesthetically large and may provoke functional limitations with remarkable entity. This aspect justifies the use of ionizing radiation after surgical excision. The post-operative orthovoltage irradiation is well tolerated with aesthetic results guaranteed with minimal side late complications.

Conflicts of interest: none to declare.

REFERENCES

1. Murray JC (1994) Keloids and hypertrophic scars Title of the article? *Clin Dermatol*, **12**: 27-37.
2. Szulgit G, Rudolph R, Wandel A, Tenenhaus M, Panaos R and Gardner H (2002) Alterations in fibroblast alpha1beta1 integrin collagen receptor expression in

keloids and hypertrophic scars. *J Invest Dermatol*, **118**: 409–415.

3. Klumppar DI, Murray JC, Anscher M (1994) Keloids treated with excision followed by radiation therapy. *J Am Acad Dermatol*, **31**: 225–31.
4. Huhn JL, Johnson L, St Clair W (2007). Adjuvant radiation of bilateral postauricular keloids: an illustration of technique. *Medical Dosimetry*, **32**: 278-280.
5. Kovalic JJ and Perez CA (1989). Radiation therapy following keloidectomy: A 20-year experience. *Int J Radiat Oncol Biol Phys*, **17**: 77–80.
6. Malaker K, Vijayraghavan K, Hodson I, Al Yafi T (2004) Retrospective analysis of treatment unresectable keloids with primary radiation over 25 years. *Clinical Oncology*, **16**: 290–298.
7. Sclafani AP, Gordon L, Chadha M, Romo T 3rd (1996) Prevention of earlobe keloid recurrence with postoperative corticosteroid injections versus radiation therapy: a randomized, prospective study and review of the literature. *Dermatol Surg*, **22**: 569–574.
8. Ragoowansi R, Cornes PGS, Moss AL, Glees JP (2003) Treatment of keloids by surgical excision and immediate postoperative single fraction radiotherapy. *Plast Reconstr Surg*, **111**: 1853–1859.
9. Doornbos JF, Stoffel TJ, Hass AC, Hussey DH, Vigliotti AP, Wen BC, Zahra MK, Sundeen V (1990) The role of kilovoltage irradiation in the treatment of keloids. *Int J Radiat Oncol Biol Phys*, **18**: 833–839.
10. Leventhal D, Furr M, Reiter D (2006) Treatment of keloids and hypertrophic scars: A meta-analysis and review of the literature. *Arch Facial Plast Surg*, **8**: 362–368.
11. Flickinger JC (2011) A radiobiological analysis of multicenter data for postoperative keloid radiotherapy. *Int J Radiation Oncology Biol. Phys*, **79**: 1164–1170.
12. Speranza G, Sultanem K, Muanza T (2008) Descriptive study of patients receiving excision and radiotherapy for keloids. *Int J Radiat Oncol Biol Phys*, **71**: 1465–1469.
13. Caccialanza M, Piccinno R, Schiera A (2002) Postoperative radiotherapy of keloids: A twenty-year experience. *Eur J Dermatol*, **12**: 58–62.
14. Ogawa R, Mitsuhashi K, Hyakusoku H, Miyashita T (2003) Postoperative electron-beam irradiation therapy for keloids and hypertrophic scars: Retrospective study of 147 cases followed for more than 18 months. *Plast Reconstr Surg*, **111**: 547–553.
15. Botwood N, Lewanski C, Lowdell C (1999) Case report: The risks of treating keloids with radiotherapy. *Br J Radiol*, **72**: 1222–1224.
16. Borok TL, Bray M, Sinclair I, Plafker J, LaBirth L, Rollins C (1988) The role of ionizing irradiation for 393 keloids. *Int J Radiat Oncol Biol Phys*, **15**: 865–870.
17. Ogawa R, Yoshitatsu K, Yoshida K, Miyashita T. (2009). Is radiation therapy for keloids acceptable? The risk of radiation induced carcinogenesis. *Plast Reconstr Surg*, **124**: 1196-1201.