

# Optimal timing of computed tomography for assessing lymph nodes after neoadjuvant chemoradiotherapy for rectal cancer

C.L. Lai<sup>1</sup>, M.J. Lai<sup>2</sup>, C.H. Liu<sup>3</sup>, C.C. Wu<sup>1</sup>, S.W. Jao<sup>1</sup>, C.W. Hsiao<sup>1\*</sup>

<sup>1</sup>Division of Colon and Rectal Surgery, Department of Surgery, Tri-Service General Hospital, National Defense Medical Center, Taipei, Taiwan, Republic of China

<sup>2</sup>Division of Clinical Pathology, Department of Pathology, Tri-Service General Hospital, National Defense Medical Center, Taipei, Taiwan, Republic of China

<sup>3</sup>Department of Radiology, Tri-Service General Hospital, National Defense Medical Center, Taipei, Taiwan, Republic of China

## ABSTRACT

### ► Original article

#### \*Corresponding author:

Dr. Cheng-Wen Hsiao,

Fax: +886 2 8792 7372

E-mail: [dr.hsiao@msa.hinet.net](mailto:dr.hsiao@msa.hinet.net)

Revised: Feb. 2016

Accepted: March 2016

*Int. J. Radiat. Res.*, October 2016;  
14(4): 279-285

DOI: 10.18869/acadpub.ijrr.14.4.279

**Background:** This study assessed the optimal timing of computed tomography for detection of metastatic disease in locoregional lymph nodes in patients with rectal cancer who have undergone chemoradiotherapy. **Materials and Methods:** This observational retrospective study was performed in a single institution. All patients with locally advanced rectal cancer treated with chemoradiotherapy, followed by a total mesorectum excision from January 1, 2003 to December 31, 2012, were included. Lymph node metastases evident on preoperative computed tomography were compared with postoperative pathologic lymph node status. **Results:** The study population consisted of 108 patients: Group A (nodal negative on preoperative computed tomography, n = 52) and Group B (nodal positive on preoperative computed tomography, n = 56). Analysis of the computed tomography scans in Group A revealed a high ability (98.07%) to predict negative lymph nodes, compared to 58.92% for predicting positive lymph nodes in Group B. **Conclusion:** The results of this study suggest that the optimal timing of computed tomography for assessing lymph nodes after neoadjuvant chemoradiotherapy for rectal cancer is after 6 weeks; this timing might be key for prediction of complete clinical responses.

**Keywords:** *Computed tomography, chemoradiotherapy, rectum cancer, complete clinical response.*

## INTRODUCTION

Up to 70% of patients with nonmetastatic rectal cancer present with locoregionally advanced disease <sup>(1)</sup>. Locally advanced rectal cancer (LARC) is generally defined as T3–T4 or node-positive, and neoadjuvant chemoradiotherapy (CRT) followed by a total mesorectum excision (TME) is the current standard treatment <sup>(2)</sup>.

Neoadjuvant CRT has become the standard treatment for patients with LARC, allowing a reduction in local recurrences and an increased preservation of the sphincter <sup>(3,4)</sup>. Preoperative

CRT followed by surgery 6–8 weeks later induces a pathologic complete response (pCR) in up to 15%–30% of cases <sup>(3-5)</sup> and is associated with a low rate of local recurrence and excellent long-term survival. Recent trends have suggested the possibility of forgoing planned surgical resections after neoadjuvant treatment in cases of extensive tumor response, and several studies have assessed the use of a non-operative “watch and wait” policy in patients with clinical complete response (cCR), and limited resection in those with partial response (nodal negative), respectively <sup>(3,4)</sup>. However, identification of patients with true

pCR before surgical resection continues to be a challenge.

Traditionally, preoperative staging for rectal cancer includes a digital rectal assessment, colonoscopy, transrectal ultrasonography (TRUS), pelvic computed tomography (CT), magnetic resonance imaging (MRI), and positron emission tomography (PET) (6). Current imaging techniques are reportedly highly accurate in the primary staging of rectal cancer; however, the CRT course extensively modifies cancer tissue and surrounding structures, causing overgrowth fibrosis, wall thickness, muscle disarrangement, tumor necrosis, calcification, and inflammatory infiltration. As a result, the same imaging techniques are far less accurate when used for restaging; although PET is a promising tool for assessing tumor response after CRT; a general consensus has not been reached (7).

Generally, lower rates of performance for all staging modalities have been reported for N staging than for T staging, and the number, size, outer shape, and density of nodes remains the most reliable and frequently used criterion to define N status (6). We selected CT as our modality due to its high reproducibility and availability. Compared with the other commonly used techniques, CT scans are more widely accessible, faster, less expensive, and less operator-dependent. Moreover, a single scan allows for assessment of both local tumors and distant metastases (3). The primary aims of this study were to determine the optimal CT timing to predict the nodal status in LARC patients after preoperative CRT as well as to determine whether patients could avoid undergoing TME.

## MATERIALS AND METHODS

### Patient selection

The study group consisted of a consecutive series of patients who underwent surgery for primary rectal cancer (up to 10 cm from the anal verge) at Tri-Service General Hospital, National Defense Medical Center, Taipei, Taiwan, and Republic of China from 2003 to 2012. All patients had biopsy-verified rectal adenocarcinomas. This retrospective study was

conducted after obtaining approval from the Institutional Review Board of the Tri-Service General Hospital, Taipei, Taiwan and fully informed consent was obtained from all patients.

Tumor staging (including primary and preoperative stages included clinical history, physical examination, colonoscopy, chest X-ray, liver and pelvic CT, and tumor marker (carcinoembryonic antigen and CA19-9 level) assessment. As a general rule, the highest stage for each parameter evaluated (T, N, circumferential margin, adjacent organ involvement, M) was considered to be the definitive tumor stage if there was a disagreement between the results of the different staging modalities (8).

Only patients with LARC who underwent a preoperative pelvic CT scan, complete CRT, and TME at our institution were included in the study; patients who received a preoperative imaging modality other than CT, could not complete the CRT course, or who underwent surgery without a TME were excluded, and those with clinical stage T0-T2N0, and M1 status were also excluded (figure 1). Based on preoperative CT findings, patients were subdivided into two groups: Group A, in which the patients' preoperative CTs were nodal negative (n = 52), and Group B, in which the preoperative CTs were nodal positive (n = 56).

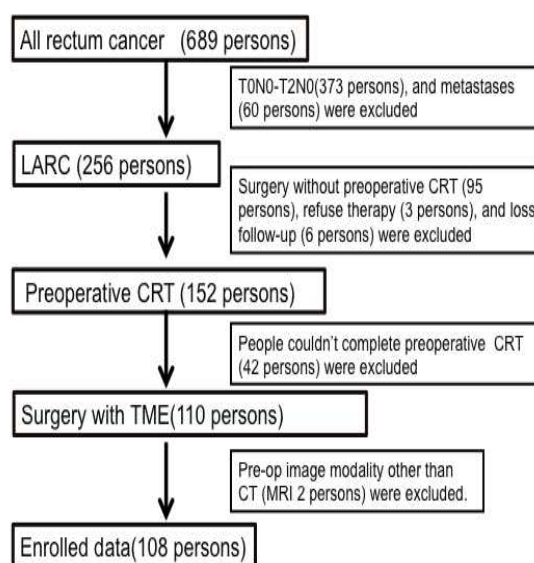


Figure 1. Flowchart of patient selection.

### Treatment

Patients selected for preoperative CRT were required to meet all of the following criteria: (a) biopsy-confirmed rectal adenocarcinoma; (b) tumor located up to 10 cm from the anal verge; (c) preoperative stage of T3-4 and/or node-positive, and (d) an Eastern Cooperative Oncology Group performance status of 0-2<sup>(2)</sup>.

Five-fluorouracil (5-FU), as a single drug or in combination with other drugs (leucovorin, carboplatin or oxaliplatin), was administered by bolus or continuous venous infusion (CVI). During this study, one standard regimen was used: initially, 5-FU was administered by a bolus (5-FU 350 mg/m<sup>2</sup>/day) with a low-dose leucovorin bolus (LV 10 mg/m<sup>2</sup>/day) for 5 days on days 1–5 and 29–33 in combination with RT (45 Gy in 25 fractions or 54 Gy in 30 fractions)<sup>(9)</sup>.

For patients who underwent neo-adjuvant treatments, surgery was planned after the completion of the preoperative CRT and CT. The TME technique was used as the standard for tumor resection. As a rule, the inferior mesenteric artery was divided at its origin, and a standard lymph node dissection was performed. The total mesorectum was removed with a sharp dissection along the avascular plane between the fascia propria and the parietal tissue under direct observation or laparoscopy<sup>(9)</sup>.

### Imaging techniques

All patients were administered a rectal enema on the morning of the day of the CT examination (the day after completion of the preoperative CRT). CT was performed using a helical CT scanner (Somatom Emotion, Siemens Medical Systems, Erlangen, Germany) with the patient in a supine position. IV contrast medium was administered (2 mL/kg; Omnipaque 300 mL, Nycomed Imaging A.S., Oslo, Norway), and 3-mm slices were made through the pelvis from the anal verge to the iliac crest. All images were retrospectively reviewed by three radiologists experienced in abdominal CT scanning who were blinded to the results of the other staging modalities and to the surgical and pathological findings. Cases for which 100% agreement was not achieved with this independent reading, a

consensus reading was reached between the three radiologists. The size of the largest node or soft tissue nodule was documented, but the location of nodes was not recorded. Nodes in the mesorectal envelope that met all three criteria were considered negative. Lymph nodes that: 1) could not be detected or which were <5 mm transverse diameter, 2) lacked irregular borders, and 3) lacked enlarged or clustered lymph nodes were considered negative for metastases. Those which met any of these three criteria were scored as N positive<sup>(2, 10)</sup>.

### Histopathology

Surgical specimens were assessed using the Quirke protocol<sup>(11)</sup>, and two histopathologists performed identification of the lymph nodes through inspection, palpation, and dissection of the specimens without any fat clearing techniques. For the purposes of this study, the following data were retrieved: tumor location, size, depth of invasion into the rectal wall, total number of lymph nodes/positive lymph nodes, grading of the differentiation, and presence of distant metastases. Cancer staging was assessed following the American Joint Committee on Cancer TNM classification<sup>(12)</sup>. A cPR was defined as the absence of viable tumor cells after a histologic examination of the surgical specimen.

### Statistical analysis

For each patient, the largest lymph node size was considered independent of the number of lymph nodes. Patients with one or more lymph nodes equal to or greater than the cut-off size were defined as N-positive. Radiological findings were compared with histopathology results in both groups in order to determine the lymph node status. For nodes greater than the 5-mm cut-off size (the minimum size at which lymph nodes were considered metastatic), the following parameters were calculated: sensitivity, specificity, negative predictive value (NPV), and positive predictive value (PPV) (table 2).

Chi-square tests were used to analyze the association between CT timing and LN status for preoperative re-staging, after adjusting for potential confounding covariates. The

differences in the distributions of the continuous variables were also assessed by Chi-square tests (table 3). P-values <0.05 were considered

statistically significant. The statistical analyses were performed using SPSS version 15.0 (SPSS Inc., Chicago, IL, USA).

**Table 1.** General characteristics of studied patients.

Patient	N- group: 52	N+ group: 56	Total: 108	P-value
Age	66.60(±14.78)	64.25(±15.76)	60.18(±15.38)	0.201
Male	33(63.46%)	34(60.71%)	67(62.03%)	0.323
Female	19(36.54%)	22(39.29%)	41(37.97%)	0.436
The day of CT after CRT	39.94(±12.07)	40.75(±18.57)	40.08(±15.93)	0.105
LN number (total removed)	10.82(±4.03)	13.31(±5.10)	12.24(±4.48)	0.261
Metastatic LN number	0.04(±1.05)	2.23(±2.87)	1.01(±2.20)	0.690
Tumor size	1.80cm(±1.07)	2.31cm(±1.13)	2.26cm(±1.09)	0.458
Type of surgery	LAR:50 APR:2	LAR:52 APR:4	LAR:102 APR:6	0.531

Abbreviation: CT= computed tomography, N-=Nodal negative via preoperative CT, N+=Nodal positive via preoperative CT, CRT= chemoradiation therapy, LAR= low anterior resection, APR= anterior perineal resection

**Table 2.** N status (CT compared with pathological result).

CT N status	Pathological N status		Results
	NO	N1,N2	
N- (52)	NO: 51	N1: 1 N2: 0	NPV 98.07% (95%CI: 88.42~99.90%)
N+ (56)	NO: 23	N1: 24 N2: 9	PPV 58.92% (95%CI: 45.01~71.63%)
	Specificity 68.92% (95%CI: 56.96~78.89%)	Sensitivity 97.05% (95%CI: 82.95~99.85%)	

Abbreviation: N-=Nodal negative, N+=Nodal positive, NPV=Negative predict value, PPV=Positive predict value

**Table 3.** N status of CT with different time.

N status	6>weeks	6<weeks	P-value <sup>a</sup>	P-value <sup>b</sup>
N-	(%96.3)26/27	(%100)25/25	0.924	0.206
N+	(%50)16/32	(%70.8)17/24	0.017	

<sup>a</sup>  $\chi^2$  test was used to analyze the association between the CT timing and the LN status for preoperative re-staging and was adjusted for potential confounding covariates.

<sup>b</sup>  $\chi^2$  test assessed the differences in the distributions for the continuous variables

Abbreviation: N-=Nodal negative, N+=Nodal positive

## RESULTS

### Patients

The study population consisted of 108 patients: 52 were nodal negative via preoperative CTs (Group A) and 56 were nodal positive via preoperative CTs (Group B). The demographic characteristics of the patients, including age and sex, day of CT after CRT, resection LN number, LN metastases numbers, tumor size, and type of surgery are summarized in table 1.

### Pelvic CT scan

We compared pelvic CT scan results with those of the pathological analyses; the sensitivity, specificity, PPV, and NPV were

97.05%, 68.92%, 58.92%, and 98.07%, respectively. These results are summarized in table 2.

We compared CT images taken at different times and subsequently divided the patients into two groups (status 1-6 and after 6 weeks post CRT) using Chi-square test in both groups. The results showed no statistical significances in either group, with p-values for Group A and B of 0.924, and 0.017, respectively. Comparison of CT timing with sensitivity and NPV using Chi-square test resulted in a p-value of 0.206, as summarized in table 3. Table 4 shows the results of comparison of the nodal positive and nodal negative groups at 1-6 and after 6 weeks, with an adjusted odds ratio of 1.607 in the after 6 weeks group. Moreover, although not



**Table 4.** Sensitivity of CT in different timing by N status.

		Numbers (%)	N+(pathological/CT)			N-(pathological/ CT)		
			Numbers(%)	AdjustedOR	%95CI	Numbers(%)	AdjustedOR	%95CI
CT Timing	6>weeks	59	(%50)16/32	1	reference	(%96.3)26/27	1	reference
	6<weeks	49	(%70.8)17/24	1.607	5.307 ~0.486	(%100)25/25	n/a	
Total		108						

Abbreviation: CT= Computed Tomography, N+=Nodal positive, N-=Nodal negative, OR=odds ration, CI=confidential interval  
n/a= not available

statistically significant, we were still able to predict with high accuracy the NPV of CT status 6 weeks after CRT.

## DISCUSSION

“Watch and wait” policies avoid postoperative complications and minimize the risk of adverse functional outcomes in patients with cCRs (13-16). However, “watch and wait” and organ-sparing strategies after neoadjuvant CRT requires accurate identification of cCR; therefore, detection of nodal involvement plays a crucial role in these selected cases. Thus, to avoid surgical resection exclusively for pathologic confirmation of a complete response, it is necessary to identify any residual nodal disease risk. However, restaging lymph nodes after neoadjuvant CRT may also be complex, as radiotherapy may reshape and modify node size and texture. The objective of this study was to determine the optimal timing of a preoperative pelvic CT scan to accurately detect LNs. The results of this study revealed high NPV in pelvic CT scans of nodal negative patients.

Local surgery alone is considered adequate therapy for treatment of early rectal cancer (clinical stage I), whereas preoperative neoadjuvant CRT appears to be the best approach for advanced rectal cancer (clinical stages II-III). Several clinical trials have demonstrated that patients with cCR following CRT have both better outcomes and very low rate of mesorectal lymph node metastases (17); thus, “watch and wait” and organ-sparing strategies have been advocated for these cancers (13-16).

Some studies have proposed TRUS and MRI as additional modalities for staging of rectal cancer. However, neither have been shown to be

clearly superior to pelvic CT scans for predicting lymph node status. TRUS is a widely available staging modality with high accuracy for T staging, but its accuracy for N staging has been questioned. MRI is a promising staging modality, particularly for predicting circumferential margin involvement, but its superiority to pelvic CT scans for predicting lymph node status has yet to be demonstrated (13). FDG F-2-deoxy-D-glucose (FDG)-PET might be more accurate than these procedures, but it remains a costly and rarely available method (2,6,18). Currently, pelvic CT scan is the most commonly used imaging modality; its accuracy for restaging rectal cancer patients is a crucial issue, as treatment is staging-related.

Several studies have evaluated the accuracy of pelvic CT scans for re-staging; comparison of our results of LN status obtained by using CT (sensitivity: 58.92%) to those of other studies (sensitivity: 50%–70%) (3, 6), revealed no statistically significant differences. Pomerri *et al.* and our study observed generally disappointing findings for PPV, but NPV showed significant results (8). The NPV in our study was 98.07% (95% confidence interval [CI]:88.42%–99.90%), which appears to be significant for prediction of LN-negative status, and addresses the crucial need to consider conservative organ-preserving treatment. It is important that CT scans accurately predict a negative nodal status before a pathological report. For this reason, this study also determined the optimal timing for the NPV of pelvic CTs.

In our analysis, CT had an accuracy of 77.8% (PPV+NPV) when using a cut-off value of 5 mm, which is similar to the results of the study (82%) by De Nardi P. *et al.*(3); however, other studies have reported low accuracy (62%–74%) by using a 5-mm cut-off (3). We observed that CT did not retain its accuracy and had difficulty

differentiating between fibrosis and metastatic LNs after CRT treatment; therefore, clinical over staging was highly likely during the prediction of positive lymph nodes, not only after CRT but also at the initial diagnosis. Thus, negative lymph nodes are highly predictable with pelvic CT. Due to their high predictive value in nodal negative patients; we were able to use digital rectal examinations, colonoscopies, and pelvic CTs for follow-up assessments of tumor recurrence.

Recent studies that sought to further improve outcome in patients with LARC found that prolonging the interval beyond 6 weeks after CRT was advantageous, mainly in terms of tumor down staging and pCR rates <sup>(19)</sup>, but the impact of the CRT interval of nodal regression were remain controversial <sup>(5,19)</sup>. Based on the results of our study, we were able to predict a high NPV of CT both before 6 weeks and after 6 weeks after CRT.

Our study had several limitations. First, Wang et al. reported that many as 94% of involved nodes may be smaller than 5 mm <sup>(20)</sup>; thus, although we utilized a cut-off size of 5 mm, metastases of  $\leq 5$  mm could not be identified using this technique. CT cut-offs of 2 or 3 mm would presumably result in higher NPV, and thus more strongly to support our observations. Second, while three radiologists with different levels of clinical experience independently interpreted the CT results, we minimized potential bias related to their different levels of experience. Third, tumor recurrences should be considerable with LARC with a cCR without a TME, and Habr-Gama *et al.* reported that local recurrences may develop in 31% of patients with an initial cCR in cases of early regrowth (12 months) and that more than half of these recurrences develop within 12 months of follow-up. Salvage therapy is possible in 90% of recurrences, resulting in 94% local disease control and 78% organ preservation <sup>(4)</sup>. Fourth, we obtained high NPV by CT scan, but 1 of the 52 patients was under-staged; thus, a more specific test such as MRI or PET should be considered as a second screening modality, which might lead to a good diagnostic capacity. Fifth, the literature describing this approach is primarily retrospective and single-institution in nature, with small numbers. Due to these

limitations, a multicenter prospective study is necessary to confirm our data and to support the use of these findings for rectal cancer management.

## CONCLUSION

This study showed that pelvic CT scans might be a useful and cost-effective staging modality in countries where MRI and TRUS are not widespread. High NPV was observed in pelvic CTs after CRT, both before and after 6 weeks; while there were no statistically significant differences between the two groups. PPV was much more accurate after 6 weeks. The results of this study suggest that the optimal timing of CT for assessing lymph nodes of LARC after CRT was after 6 weeks, a timing which might be key for predicting cCR. With confidence in a predicted cCR, patients under a “watch and wait” policy may benefit by avoiding a TME, thus lowering their risks of post-operative complications or stoma creation.

**Conflict of interest:** *The authors state that there are no financial or personal relationships with other people or organizations that could inappropriately influence this work.*

## REFERENCES

1. Gunderson LL, Jessup JM, Sargent DJ, Greene FL, Stewart A (2010) Revised tumor and node categorization for rectal cancer based on surveillance, epidemiology, and end results and rectal pooled analysis outcomes. *J Clin Oncol*, **28(2)**: 256–263.
2. Pommeri F, Maretto I, Pucciarelli S, Rugge M, Burzi S, Zandonà M, *et al.* (2009) Prediction of rectal lymph node metastasis by pelvic computed tomography measurement. *Eur J Surg Oncol*, **35(2)**: 168-73.
3. De Nardi P and Carvello M (2013) How reliable is current imaging in restaging rectal cancer after neoadjuvant therapy? *World J Gastroenterol*, **19(36)**: 5964-5972.
4. Habr-Gama A, Gama-Rodrigues J, São Julião GP, Proscurschim I, Sabbagh C, Lynn PB, *et al.* (2014) Local recurrence after complete clinical response and watch and wait in rectal cancer after neoadjuvant chemoradiation: impact of salvage therapy on local disease control. *Int J Radiat Oncol Biol Phys*, **88(4)**: 822-8.
5. Garcia-Aguilar J, Smith DD, Avila K, Bergsland EK, Chu P, Krieg RM, *et al.* (2011) Optimal timing of surgery after

- chemoradiation for advanced rectal cancer: preliminary results of a multicenter, nonrandomized phase II prospective trial. *Ann Surg*, **254(1)**: 97-102.
6. Martellucci J, Scheiterle M, Lorenzi B, Roviello F, Cetta F, Pinto E, et al. (2012) Accuracy of transrectal ultrasound after preoperative radiochemotherapy compared to computed tomography and magnetic resonance in locally advanced rectal cancer. *Int J Colorectal Dis*, **27(7)**: 967-73.
  7. Mak D, Joon DL, Chao M, Wada M, Joon ML, See A, et al. (2010) The use of PET in assessing tumor response after neoadjuvant chemoradiation for rectal cancer. *Radiother Oncol*, **97(2)**: 205-11.
  8. Pomerri F, Pucciarelli S, Maretto I, Zandonà M, Del Bianco P, Amadio L, et al. (2011) Prospective assessment of imaging after preoperative chemoradiotherapy for rectal cancer. *Surgery*, **149**: 56-64.
  9. Pucciarelli S, Friso ML, Toppan P, Fornasiero A, Carnio S, Marchiori E, et al. (2000) Preoperative combined radiotherapy and chemotherapy for middle and lower rectal cancer: preliminary results. *Ann Surg Oncol*, **7**:38-44.
  10. de Vries FE, da Costa DW, van der Mooren K, van Dorp TA, Vrouwenraets BC. (2014) The value of pre-operative computed tomography scanning for the assessment of lymph node status in patients with colon cancer. *Eur J Surg Oncol*, **40(12)**: 1777-81.
  11. Quirke P, Durdey P, Dixon MF, Williams NS (1986) Local recurrence of rectal adenocarcinoma due to inadequate surgical resection. Histopathological study of lateral tumour spread and surgical excision. *Lancet*, **2(8514)**: 996-9.
  12. Hari DM, Leung AM, Lee JH, Sim MS, Vuong B, Chiu CG, et al. (2013) AJCC Cancer Staging Manual 7th edition criteria for colon cancer: do the complex modifications improve prognostic assessment? *J Am Coll Surg*, **217(2)**: 181-90.
  13. Smith JD, Ruby JA, Goodman KA, Saltz LB, Guillem JG, Weiser MR, et al. (2012) Nonoperative management of rectal cancer with complete clinical response after neoadjuvant therapy. *Ann Surg*, **256(6)**: 965-72.
  14. Park JS, Jang YJ, Choi GS, Park SY, Kim HJ, Kang H, et al. (2012) Accuracy of preoperative MRI in predicting pathology stage in rectal cancers: node-for-node matched histopathology validation of MRI features. *Dis Colon Rectum*, **57(1)**: 32-8.
  15. Habr-Gama A, Perez RO, Nadalin W, Sabbaga J, Ribeiro U Jr, Silva e Sousa AH Jr, et al. (2004) Operative versus non-operative treatment for stage 0 distal rectal cancer following chemo- radiation therapy: Long-term results. *Ann Surg*, **240**: 711-717.
  16. Maas M, Beets-Tan RG, Lambregts DM, Lammering G, Nelemans PJ, Engelen SM, et al. (2011) Wait-and-see policy for clinical complete responders after chemoradiation for rectal cancer. *J Clin Oncol*, **29**: 4633-4640.
  17. Pucciarelli S, Capirci C, Emanuele U, Toppan P, Friso ML, Pennelli GM, et al. (2005) Relationship between pathologic T-stage and nodal metastasis after preoperative chemoradiotherapy for locally advanced rectal cancer. *Ann Surg Oncol*, **12**: 111-6.
  18. Maizlin ZV, Brown JA, So G, Brown C, Phang TP, Walker ML, et al. (2010) Can CT replace MRI in preoperative assessment of the circumferential resection margin in rectal cancer? *Dis Colon Rectum*, **53(3)**: 308-14.
  19. Wasserberg N (2014) Interval to surgery after neoadjuvant treatment for colorectal cancer. *World J Gastroenterol*, **20(15)**: 4256-62.
  20. Wang C, Zhou Z, Wang Z, Zheng Y, Zhao G, Yu Y, et al. (2005) Patterns of neoplastic foci and lymph node micrometastasis within the mesorectum. *Langenbecks Arch Surg*, **390(4)**: 312-8.

