

Anti-inflammatory role of piperine against rat lung tissue damage induced by gamma-rays

A.A. Elkady and S.S. Tawfik

Health Radiation Research Department, National Center for Radiation Research and Technology (NCRRT), 29 Nasr City, Cairo, Egypt, Egyptian Atomic Energy Authority, Cairo, Egypt

ABSTRACT

Background: Radiation-induced acute lung damages are refractory side effects in lung cancer radiotherapy (RT). Prospective study investigates the possible role of piperine (Pip) as anti-inflammatory agent against γ -rays-induced lung tissue lesions in an applicable rat model. **Materials and Methods:** Fifty-six Sprague-Dawley rats were divided into four groups: Control, rats were administered the vehicle by gastric tube for 6-weeks, Pip-treated, (each rat received 40mg Pip/kg body-weight; once daily, orally for 6weeks), irradiated, (animals subjected to a single dose of whole body γ -rays (12Gy), and Pip-treated & irradiated, (each rat received the Pip-dosages, then one hour later after the last treatment, rats were exposed to 12Gy γ -rays. **Results:** The administration of Pip to rats pre-irradiation was significantly abolish the radiation-induced alleviation in lungs catalase (CAT) and glutathione peroxidase (PGx) activities and reduced glutathione (GSH) content and significantly limited the elevation in serum tumor necrosis factor- α (TNF- α), interleukin-1 β (IL-1 β) and interleukin-6 (IL-6) levels compared to irradiated group. The histopathological findings in lung tissues of irradiated group, showed partial desquamation of bronchiolar epithelial with peri-bronchiolar round cell infiltration and serous exudates, in some cases lung presented sero-fibrinous pneumonia with emphysema and collapse of some alveoli with thickness of inter-alveolar septa, while in Pip-treated & irradiated group, lung tissues showed minimum injury with or without few degenerative changes. **Conclusion:** Pip acts as a potent scavenger of free radicals to prevent and/or ameliorates the harmful effects of γ -rays. To our knowledge, this is the preliminary report of Pip mediated γ -rays induced lung inflammation *in-vitro*.

Keywords: Antioxidant, piperine, γ -rays, lung, pneumonia, rats.

► Original article

*Corresponding authors:

Dr. Ahmed A. Elkady,

E-mail:

elkadyah13@gmail.com

Revised: March 2017

Accepted: April 2017

Int. J. Radiat. Res., January 2018;
16(1): 75-84

DOI: 10.18869/acadpub.ijrr.16.1.75

INTRODUCTION

Radiation-induced inflammation and production of reactive oxygen species (ROS) play a critical role in lung tissue reaction⁽¹⁾. Recently, research has focused on finding effective and reliable anti-inflammatory agents that can protect tissues against radiation-induced damage⁽²⁾.

Inflammation is a complex biological feedback of vascular tissues to injurious provocations, such as pathogens, damaged cells or irritants. It is caused by release of chemicals

from tissues and migrating cells. Most actively related are the leukotrienes and interleukins⁽³⁾. Pneumonitis and lung fibrosis are the major radiation-induced complications following thoracic radiotherapy (RT)⁽⁴⁾. Radiation can interrupt epithelial integrity leading to edema, enrolment of leukocytes, and a cascade of molecular events that alters the microenvironment. Furthermore; it produces a self-sustaining cycle of inflammation and chronic oxidative stress⁽⁵⁾.

Piperine (Pip) is bioactive compound originated from natural sources used as a flavor,

spice and its major alkaloid present in *piper nigrum* and *piper longum* (6). Previous studies have shown that Pip has many biological functions, including antioxidant, anti-cancer, lung tumor inhibitor, analgesic and anti-inflammatory (7-11) activities. It is reported that a single dose of 11-13 Gy γ -rays is sufficient to produce radiation-induced pulmonary toxicity such as pneumonitis for this cause single dose of 12 Gy γ -rays was applied in the present study (12). In the present work, an acute radiation sickness model was successfully established in rats to explore the potential anti-inflammatory role of Pip against rat lung tissue damages induced by γ -rays, which was not previously known.

MATERIALS AND METHODS

Animals

Male Sprague-Dawley rats (age 9–10 weeks), weighing 110–120g, obtained from the Holding Company for Biological Products and Vaccines (Helwan, Cairo, Egypt) were used in the experiment. Animals were kept under standard conditions and were allowed free access to a standard requirement diet and water *ad libitum*. Animals were kept under a controlled lighting condition (light: dark, 13–11 hours). Animals were acclimatized to the experimental conditions prior to Pip dosing for 3 days. This study complies with National Institutes of Health guidelines.

Radiation processing

It was performed by using gamma cell-40 (Cesium-137) located at NCRRT, Nasr City, Cairo, Egypt. Animals were irradiated with a single dose of γ -rays (12Gy) delivered at a dose rate of 0.42 Gy/ minutes at the time of experimentation. Animals were not anesthetized before irradiation.

Reagents

Pip (purity: >98%,) was purchased from Sigma-Aldrich, USA, Scheme 1. All other chemicals used were of the highest purity grade available.

Experimental design

Fifty-six rats were divided randomly into four groups, control group (n=12), rats received orally by gastric tube an appropriate equivalent volume of distilled water (vehicle of Pip) for 6 weeks. Irradiated group (n=20), received the vehicle as in control group for 6 weeks, after one hour of the last dose, rats were whole body exposed to an acute single dose of 12Gy γ -rays. Pip-treated group (n=12), rats received Pip, orally by gastric tube at dose of 40mg/ kg body weight according to Atal *et al.* (13), once daily for 6 weeks. Pip-treated & irradiated group (n=12), rats received Pip doses as in Pip-treated group for 6 weeks, then one hour post the last dose, rats were whole body irradiated with an acute single dose of 12Gy γ -rays. At the 2nd day post radiation exposure, only 10 rats, from each group were randomly sacrificed.

A high number of animals was used in the irradiated groups (n=20), because of the elevated mortality rate that may occur in such γ -rays irradiated group. In the present experiment, the mortality not exceeds 30% of the total number of γ -irradiated group and zero percentage of mortality for the other groups.

Samples collection

After an overnight fast, blood samples from each rat were collected by retro-orbital puncture using blood capillary tubes. Serum was obtained immediately by centrifugation of blood samples at 3000xg for 10minutes. Lungs were directly separated after sacrifice, washed with ice-cold saline and excised immediately in cold 0.9% NaCl, then removed and rinsed in chilled 0.15M Tris KCl buffer, pH 7.4 to yield 10% (w/v) homogenate using, Homogenizer type MNW-302, Poland, then the lung homogenates were centrifuged at 800xg for 5minutes at 4°C to separate the tissue debris. The homogenates supernatant were subjected to biochemical analysis.

For the histopathological investigation, lung tissue specimens were collected and fixed in 10% buffered formalin solution followed by dehydration, clearing and embedding in paraffin. Paraffin sections of 5-micron thickness were sliced and stained routinely with Haematoxylin

and Eosin (H&E) reagent, according to Bancroft and Stevens ⁽¹⁴⁾ and examined with a light microscope (Olympus, Japan).

Estimation of biochemical parameters

Detection of serum tumor necrosis factor alpha (TNF- α), Interleukin-1 β (IL-1 β) and Interleukin-6 (IL-6) activities were performed by Enzyme-Linked Immunosorbent Assays (ELISA) technique (BioSource International, Camarillo, CA, USA) according to the manufacturer's instructions. Each sample assay was repeated three times. The absorbance was read at 450nm with a microplate reader (Thermo Scientific Multiskan MK3, USA).

CAT was assayed colorimetrically at 620nm and expressed as unit (μmol of H_2O_2 consumed/min) per mg protein as described by Sinha. The reaction mixture (1.5 ml) contained 1.0 ml of 0.01 M phosphate buffer pH 7.0, 0.1 ml of tissue homogenate and 0.4 ml of 2 M H_2O_2 . The reaction was stopped by adding 2.0 ml of dichromate-acetic reagent (5% potassium dichromate and glacial acid mixed in 1:3 ratio) ⁽¹⁵⁾.

Reduced GSH levels were determined in lung tissue by the methods described by Ellman, which is based on the reduction of Ellman's reagent [5,5-dithiobis-(2-nitrobenzoic acid)] by SH-groups to form 1mole of 2-nitro-5-mercaptobenzoic acid/mole of SH. The nitro-mercaptobenzoic acid has an intense yellow color and can be determined by spectrophotometer ⁽¹⁶⁾. The GPx activity in lung tissue was determined according to the method of Lawrence and Burk ⁽¹⁷⁾. This method is based on measuring the oxidation of reduced nicotinamide adenine dinucleotide phosphate (NADPH) using hydrogen peroxide as the substrate. A reaction mixture of 1ml contained 50mM potassium phosphate buffer (pH 7), 1mM EDTA, 1mM NaN_3 , 0.2mM NADPH, 1 unit/ml oxidized glutathione reductase and 1mM GSH was prepared. The prepared lung homogenate was centrifuged at 105,000 for 15minutes at 4°C. 0.1ml of the supernatant was added to 0.8ml of the reaction mixture and the solution was incubated for 5 minutes at 25°C. 0.1 ml of 0.25 mM hydrogen peroxide solution was added

to initiate the reaction. Absorbance was measured at 340nm for 5minutes, and an extinction coefficient of 6.22×10^{-3} was used for calculation. The results were expressed as μmol unit/ minute/g tissue. One unit is defined as the amount of GPx enzyme that will cause the oxidation of 1.0 μmol of NADPH to NADP^+ per minute at 25°C. The changes in the absorbance at 340nm were recorded at 1-minute interval for 5minutes. In lung homogenate, protein content was determined according to the method of Lowry *et al.*, using bovine serum albumin as standard ⁽¹⁸⁾.

Statistical analysis

Data were analyzed using SPSS software (version 19.0). One way analysis of variance (ANOVA) followed by LSD as Post Hoc test were used. The results obtained were expressed by mean \pm standard deviation. P-values < 0.05 were considered to be statistically significant ⁽¹⁹⁾.

RESULTS

Effects of Pip on γ -rays-induced inflammatory cytokines

Administration of Pip alone without γ -irradiation to rats resulted in non-significant changes in all inflammatory cytokines and biochemical parameters which were studied (tables 1 and 2).

As shown in table 1, significant augmentation in some inflammatory cytokines represented in serum TNF- α , IL-1 β and IL-6 levels were observed in irradiated group compared with corresponding values of control group. The administration of Pip before exposure to γ -rays significantly limited the elevation in those inflammatory markers levels compared to irradiated group.

Also, the effects of γ -rays on endogenous antioxidant status are shown in table 2. γ -rays induced significant diminution in the lung CAT, GPx activities and GSH content compared with control group. Administration of Pip for 6 consecutive weeks prior to γ -rays-exposure resulted in significant increases in the activities

of lung CAT, GPx and content of GSH compared to irradiated group.

Histopathological finding

An alveolar duct arises from respiratory bronchiole and numerous alveoli open into the alveolar duct. The oval alveoli lined by simple squamous epithelium. Adjacent alveoli share a common inter-alveolar septum. Capillary plexuses are located in the thin septum, supported by fine connective tissue fibres, fibroblasts and other cells. At the free ends of the alveoli are narrow bands of smooth muscle which is a continuation from the muscle layer of the respiratory bronchiole (figure 1). In irradiation group, the lung showed partial desquamation of bronchiolar epithelial with mild peri-bronchiolar round cell infiltration. In some cases showed sero-fibrinous pneumonia

characterized by serous exudates in alveolar space and proliferative pneumocytes type II (figures 2,3), moreover the lesion may be advanced to lymphocytic histolytic pneumonia infiltrated by leukocytes beside emphysema, the alveoli are over distended with air, thinning and destruction of alveolar septa (figures 4 and 5). Emphysema may be associated with compression atelectasis of some alveoli which decrease in size with thickness of inter-alveolar septa (figure 6). On the other hand, the lung of treated irradiated group revealed in most cases the histological structure of lung relatively well preserved architecture with few degenerative changes, in some cases, lung tissue showed slightly thickness of inter-alveolar septa with peri bronchiolar increase leukocytes infiltration and proliferative pneumocytes type II (figures 7 and 8).

Table 1. Serum tumor necrosis factor alpha (TNF-α), Interleukin-1β (IL-1β) and Interleukin-6 (IL-6) levels in the different animal groups.

Inflammatory Cytokines	Control	Pip-treated	Irradiated	Pip-treated & Irradiated
TNF-α (pg/ml)	1.02±36.34	1.87±35.27	2.39±79.53 ^{a,b}	2.11±46.28 ^{a,b,c}
IL-1β (pg/ml)	0.74±13.63	1.12±13.10	1.91±51.89 ^{a,b}	1.92±31.33 ^{a,b,c}
IL-6 (pg/ml)	1.27±86.12	1.41±84.84	4.76±201.31 ^{a,b}	2.32±136.21 ^{a,b,c}

All values are expressed as mean ± SE

^aSignificant (P< 0.05) when compared with the control group.

^bSignificant (P< 0.05) when compared with the Pip-treated group.

^cSignificant (P< 0.05) when compared with the irradiated group.

Table 2. Lung catalase (CAT) and glutathione peroxidase (GPx) activities and reduced glutathione (GSH) content in the different animal groups.

Biochemical parameters	Control	Pip-treated	Irradiated	Pip-treated & Irradiated
CAT (U/mg protein)	0.90±2.40	1.2±2.39	1.3±1.10 ^{a,b}	1.2±1.67 ^{a,b,c}
GSH (μmol/ g tissue)	0.021±1.34	0.032±1.30	0.071±0.49 ^{a,b}	0.059±0.85 ^{a,b,c}
GPx (μmol unit/ g tissue)	0.163±1.48	0.172±1.52	0.146±0.64 ^{a,b}	0.062±1.05 ^{a,b,c}

All values are expressed as mean ± SE

^aSignificant (P< 0.05) when compared with the control group.

^bSignificant (P< 0.05) when compared with the Pip-treated group.

^cSignificant (P< 0.05) when compared with the irradiated group.

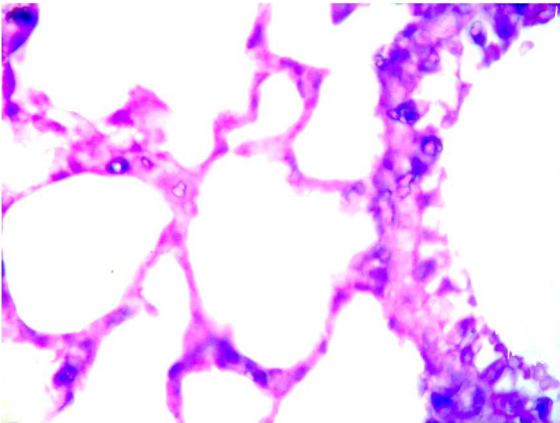


Figure 1. Lung of control group showing normal structure (H&Ex 400).

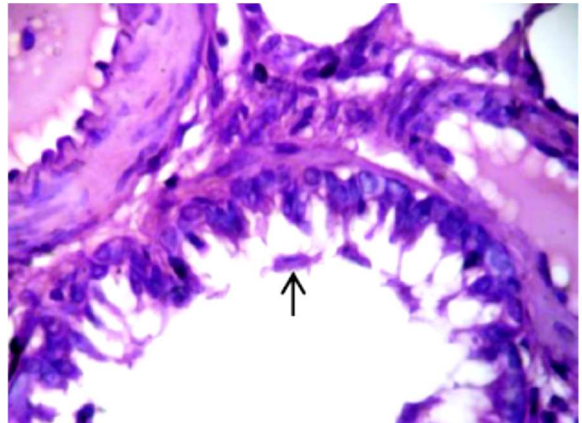


Figure 2. Lung of irradiated group showing partial desquamation of bronchiolar epithelial (↑) with mild peri-bronchiolar round cell infiltration (H&Ex 400).

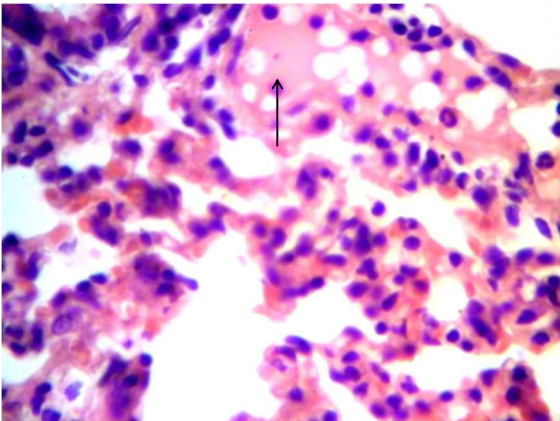


Figure 3. Lung of irradiated group showing sero-fibrinous exudates (↑) and proliferation pneumocytes type II (H&Ex 400).

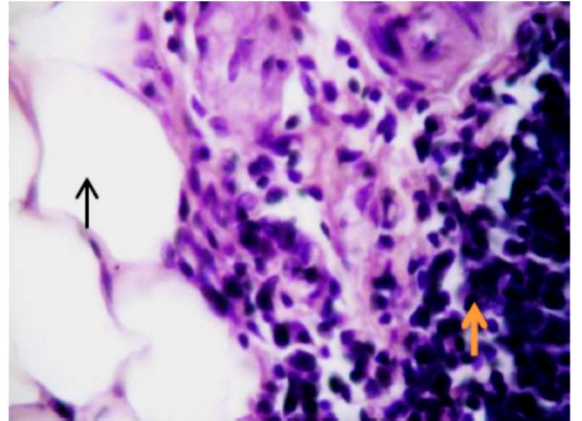


Figure 4. Lung of irradiated group showing pneumonia (↑) with emphysema (↑) (H&Ex 400).

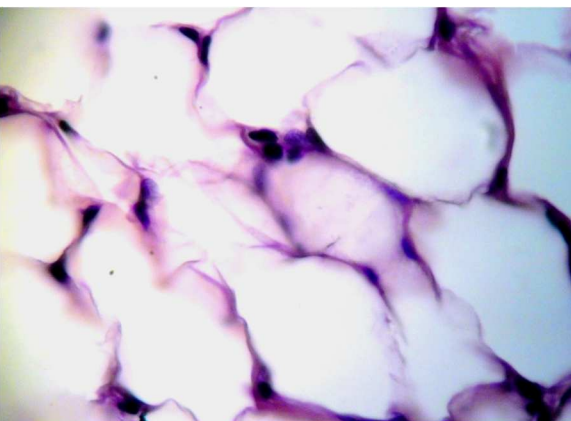


Figure 5. Lung of irradiated group showing emphysema (H&Ex 400).

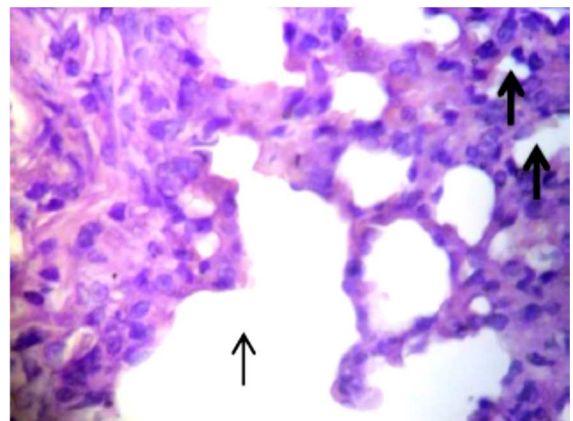


Figure 6. Lung of irradiated group showing emphysema (↑) and collapse (↑) of some alveoli with thickness of inter-alveolar septa (H&Ex 400).

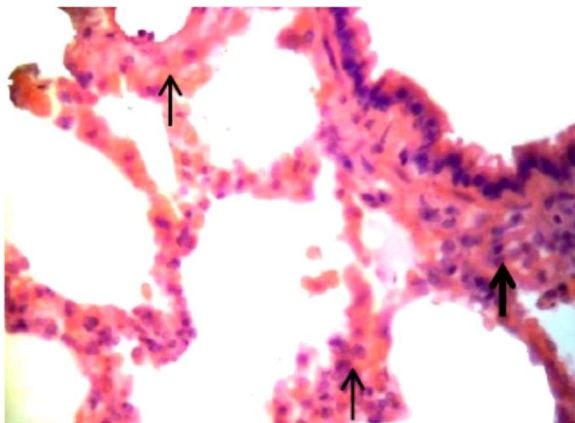


Figure 7. Lung of Pip-treated & irradiated group showing slightly thickness of inter-alveolar septa (↑) with peri-bronchiolar leukocytes infiltration (↑) (H&E× 400).

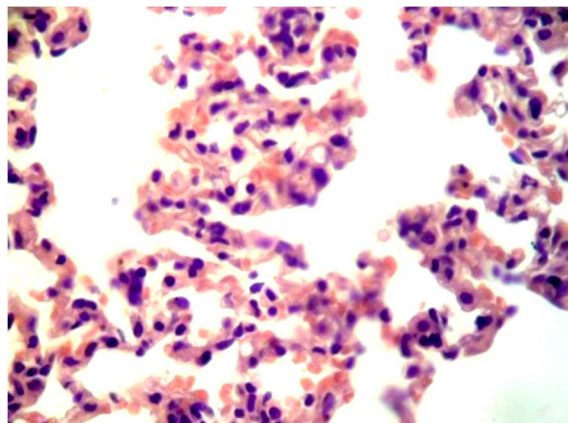


Figure 8. Lung of Pip-treated & irradiated group showing normal histological structure with increase of pneumocytes type II (H&E× 400).

DISCUSSION

Radiation sickness is an inflammatory disease (20). Many reports have shown that γ -rays can induce lung inflammation (12). Radiation pneumonitis has been widely studied and well-confirmed to several thoracic RT; hence, it is a major focus of RT protocol planning (4). In the present study, rat lung tissue damage induced by γ -rays was relieved by Pip, as an anti-inflammatory agent in agreement with the results of Zhai *et al.* study (21). These results showed that Pip could significantly alleviate inflammation injury of mouse endometritis.

Histopathology changes showed that γ -rays induced serious injury to the lung of rats (22), including interstitial inflammatory cells, markedly thickened alveolar walls, collapsed alveoli, foam-like cells and, collagen deposition in the alveolar space and damage to the lung tissue structure (12).

Previous study on the acute exposure to γ -rays increased the secretion of inflammatory cytokines, which is consistent with the findings of a previous study by Palma *et al.* (23). In the present study, Pip showed anti-inflammatory effects by inhibiting significantly the γ -rays-induced increased level of pro inflammatory markers (TNF- α , IL-1 β and IL-6). Furthermore, the results of the present study are in agreement with those of a previous study by Li *et al.* (6).

TNF- α and IL-1 β play a role in starting the

inflammatory responses (21). In general, a cascade of inflammatory processes is controlled through the production of pro inflammatory mediators. Improved expression of pro inflammatory cytokines, chemokines, and adhesion molecules, and their close interactions facilitate pro-inflammatory pathways by recruiting and migrating inflammatory cells from blood to tissues (24). Up-regulation of TNF- α and IL-1 β level is key in the regulation of host immune responses in lung after exposure to γ -rays in the rat (25). The decrease of IL-1 β expression in Pip-treated & irradiated group showed that Pip could control inflammation. IL-6, which is sharply and quickly produced in infections and tissue injury responses, contributes to the host defense through the stimulation of immune reactions (26). Additionally, both total body and localized irradiation resulted in significant increase in TNF, IL-1 and IL-6 levels in circulating blood of rats (27). Pip contains pentacyclic oxindole group which is effective for immunomodulation activity due to its complex properties such as anti-oxidative, anti-apoptotic, and cytokine release (7,28). The amelioration which occurred in assessed inflammatory markers in Pip-treated & irradiated group suggested that Pip agent could have potent anti-inflammatory role (6), reported that there are several experimental evidences which support the protective effect of Pip in acute injury induced by a variety of pharmacological or harmful agents, mediated by

products of oxidative stress.

Most of the toxic effects of ionizing radiation to tissue are due to the generation of FOR which triggers formation of several inflammatory intermediates⁽²⁹⁾. To overcome such events, living cells are equipped with integrated endogenous enzymatic and antioxidant systems such as CAT, GPx and GSH⁽³⁰⁾. The activity of CAT is important in relation to the scavenging of FOR generated by ionizing radiation⁽³¹⁾, then the fact that Pip add-on before radiation seems to inhibit their decline in activity.

A smaller trial suggest a benefit for using the ethanol extract of Pip during radiation-exposure in Swiss mice, Pip attenuated the elevated levels of glutamate pyruvate transaminase, alkaline phosphatase, lipid peroxidation and restored GSH in the liver and serum of irradiated animals⁽³²⁾. Pip seems to be beneficial in inflammatory diseases accompanied by severe pain⁽³³⁾. It has been reported that prophylactic Pip offered protection against small intestine ischemia-reperfusion injury and improved the inflammatory responses in rats⁽³⁴⁾. Further, Pip has also used to assess its potential as an inhibitor agent in gastric cancer of rats⁽¹¹⁾. These studies indicate the different therapeutic potential of Pip in variety of diseases.

Reduced GSH is the main intracellular antioxidant and has multiple biological functions. It acts directly as ROS scavenger and as a substrate for GPx to reduce H₂O₂⁽³⁵⁾. Reduced GSH is a vital determinant of cellular radio sensitivity because it can react with a variety of electrophilic compounds⁽³⁶⁾.

The depletion of GSH contents in irradiated group may be due to the reaction of reduced GSH with free radicals resulting in the formation of thiyl radicals that associate to produce oxidized glutathione (GSSG). Moreover, the availability of reduced GSH can also be limited either by deficiency in synthesis, enhanced efflux, or inefficient reduction of GSSG⁽³⁷⁾. Significant increase in lung reduced GSH contents and CAT, GPx activities were observed in Pip-treated & irradiated animals. GSH offers protection against FOR following exposure to ionizing radiation⁽³⁸⁾. The ameliorative action of Pip observed may be attributed to its

anti-inflammatory properties. Additionally, the mechanism of Pip anti-inflammatory property may be due to its possible antioxidant activity⁽³⁹⁾. Oral supplementation of Pip revealed an increase in the lung of rat antioxidant defense system by increasing the activities of enzymatic antioxidants CAT and GPx, and non-enzymatic antioxidants GSH⁽⁴⁰⁾.

Cytokine discharge in response to ionizing-radiation is a recognized phenomenon and may play a major role in subsequent radiation-induced lung toxicity⁽⁴¹⁾. Several tissue macrophages respond to any toxic-event by secreting cytokines such as TNF- α ⁽⁴²⁾. As evidenced in the present study, γ -irradiation resulted in increased serum TNF- α , indicating the role of this cytokine in irradiation-induced inflammatory processes, while depression of the TNF- α response by Pip implicates the anti-inflammatory role of Pip on the release of this pro-inflammatory cytokine.

The histopathological findings of the present study indicated that irradiated group revealed partial desquamation of bronchiolar epithelial with mild peri-bronchiolar round cell infiltration. In some cases showed serous pneumonia characterized by serous exudates in alveolar space and proliferative pneumocytes type II. moreover the lesion may be advanced to lymphocytic histolytic pneumonia, beside emphysema may be associated with compression atelectasis of some alveoli with thickness of inter-alveolar septa. These findings are in agreement with these reported by Abratt and Morgn⁽⁴³⁾ and O'Sullivan and Levin⁽⁴⁴⁾. Lung tissue injury implied the induction of numerous cytokines in blood which form the basis for the associated multicellular interactions and the release of FOR and neutrophilic alveolitis through the radiation injury was reduced by Pip⁽⁴⁵⁾. Lung has very high blood supply and large surface area, the lung is highly susceptible to oxidative stress mediated injury. Furthermore, these oxidants also activate inflammatory responses in the lungs through activation of transcription of pro-inflammatory mediator genes⁽⁴⁶⁾. The initial damage in the lung leads to the infiltration of activated inflammatory cells into the lung parenchyma and release of

different cytokines such as TNF- α . These eventually result in collagen deposition in the lung tissue (47).

The activated fibroblasts generate improved amounts of extracellular matrix proteins that interfere with the normal lung architecture (48).

Owing to the fact that Pip is a potent agent in reducing cytokine markers and the levels of FOR shown in development of RT-induced lung inflammation (39), this experimental study was designed with a concern that Pip might play a role in the prevention of pulmonary toxicity secondary to radiation.

No data demonstrating the effects of Pip in radiation-induced pulmonary toxicity was available in the literature. Nonetheless, in a study by Sunila *et al.*, they suggested the benefit of using ethanol extract of Pip for protecting liver of irradiated Swiss mice (32). It is reported that a single dose of 11-13Gy γ -rays is sufficient to produce radiation-induced pulmonary toxicity such as radiation pneumonitis (12), for this cause single dose of 12Gy γ -rays was applied in the present study.

Histopathological results of Pip-treated & irradiated group showed relatively well conserved architecture in lung tissues without necrosis, in few cases slightly degenerative changes in pulmonary tissues may be appear. Also such result agreement with the data of the present biochemical study indicated that, Pip ameliorated the inflammatory processes induced lung tissue damage in rats exposed to γ -rays. These findings are in agreement with these reported by Bang *et al.*, they showed that Pip significantly reduced the inflammatory area in the ankle joints of rats (49).

CONCLUSION

All of the results indicated that Pip may be a potential anti-inflammatory drug in lung tissue damage induced by γ -rays. Pip acts in the lung tissues as a potent scavenger of free radicals to prevent or ameliorate the toxic effects of γ -irradiation as shown in the biochemical and histopathological studies. Also, Pip might provide lung substantial protection against

γ -rays-induced inflammatory markers.

Measurement of cytokine markers concentrations during RT could help predict lung toxicity and lead to new therapeutic strategies.

ACKNOWLEDGEMENTS

We are thankful to our colleagues, Health Radiation Research Department for providing laboratory conveniences, and members of the National Center for Radiation Research and Technology (NCRRT), Egyptian Atomic Energy Authority for providing the necessary irradiation facilities. This work was done in the NCRRT, Egypt.

Conflicts of interest: Declared none.

REFERENCES

1. Hill RP, Zaidi A, Mahmood J, Jelveh S (2011) Investigations into the role of inflammation in normal tissue response to irradiation. *Radiother Oncol*, **101(1)**: 73-79.
2. Verma V (2016) Relationship and interactions of curcumin with radiation therapy. *World J Clin Oncol*, **7(3)**: 275-83.
3. Anilkumar M (2010) Ethnomedicinal plants as anti-inflammatory and analgesic agents. In: Chattopadhyay D, editor. *Ethnomedicine: a source of complementary therapeutics*. Kerala: Research Signpost, pp. 267-293.
4. Li B, Chen SH, Lu HJ, Tan Y (2016) Predictive values of TNF- α , IL-6, IL-10 for radiation pneumonitis. *Int J Radiat Res*, **14(3)**: 173-79.
5. Ghafoori P, Marks LB, Vujaskovic Z, Kelsey CR (2008) Radiation-induced lung injury. *Assessment, management, and prevention*. *Oncology (Williston Park)*, **22(1)**:37-47.
6. Li Y, Li K, Hu Y, Xu B, Zhao J (2015) Piperine mediates LPS induced inflammatory and catabolic effects in rat intervertebral disc. *Int J Clin Exp Pathol*, **8(6)**: 6203-13.
7. Meghwal M and Goswami TK (2013) Piper nigrum and piperine: an update. *Phytother Res*, **27**: 1121-30.
8. Greenshields AL, Doucette CD, Sutton KM, Madera L, Annan H, Yaffe PB, Knickle AF, Dong Z, Hoskin DW (2015) Piperine inhibits the growth and motility of triple-negative breast cancer cells. *Cancer Lett*, **357(1)**: 129-40.
9. Pradeep CR and Kuttan G (2002) Effect of piperine on the inhibition of lung metastasis induced B16F-10 melanoma cells in mice. *Clin Exp Metastasis*, **19(8)**: 703-8.
10. Tasleem, F, zhar I, Ali SN, Perveen S, Mahmood ZA (2014) Analgesic and anti-inflammatory activities of Piper nigrum

- L. *Asian Pac J Trop Med*, **7S1**: S461-8.
11. Xia Y, Pham NK, Yoon HY, Lian S, Joo YE, Chay KO, Kim KK, Jun YD (2015) Piperine inhibits IL-1 β -induced IL-6 expression by suppressing p38 MAPK and STAT3 activation gastric cancer cells. *Mol Cell Biochem*, **398(1-2)**: 147-56.
 12. Almeida C, Nagarajan D, Tian J, Leal SW, Wheeler K, Munley M, Blackstock W, Zhao W (2013) The role of alveolar epithelium in radiation-induced lung injury. *PLoS One*, **8(1)**: e53628.
 13. Atal S, Agrawal RP, Vyas S, Phadnis P, Rai N (2012) Evaluation of the effect of piperine per se on blood glucose level in alloxan-induced diabetic mice. *Acta Pol Pharm*, **69(5)**: 965-9.
 14. Bancroft JD and Stevens AE (1996) Theory and Practice of Histological Techniques. 4th ed. Edinburgh; Churchill Livingstone, p, 766.
 15. Sinha AK (1972) Colorimetric assay of catalase. *Anal Biochem*, **47(2)**: 389-94.
 16. Ellman GL (1959) Tissue sulfhydryl groups. *Arch Biochem Biophys*, **82(1)**: 70-7.
 17. Lawrence RA, Burk RF (1976) Glutathione peroxidase activity in selenium-deficient rat liver. *Biochem Biophys Res Commun*, **71(4)**: 952-8.
 18. Lowry OH, Rosebrough NJ, Farr AL, Randall RJ (1951) Protein measurement with the Folin phenol reagent. *J Biol Chem*, **193(1)**: 265-75.
 19. Snedecor GW and Cochran WG (1989) Statistical Methods, 8th Edition, Wiley-Blackwell, p. 503.
 20. Soyol D, Jindal A, Singh I, Goyal PK (2007) Protective capacity of Rosemary extract against radiation induced hepatic injury in mice. *Int J Radiat Res*, **4(4)**: 161-68.
 21. Zhai WJ, Zhang ZB, Xu NN, Guo YF, Qiu C, Li CY, Deng GZ, Guo MY (2016) Piperine Plays an Anti-inflammatory Role in Staphylococcus aureus Endometritis by Inhibiting Activation of NF- κ B and MAPK Pathways in Mice. *Evid Based Complement Alternat Med*, Article ID 85972088.
 22. Qibin S, Weiguo H, Yuxin C, Xubin, Hao C (2014) Establishment of a rat model of radiation-induced lung injury. *Int J Radiat Res*, **12(3)**: 223-27.
 23. Palma DA, Senan S, Tsujino K, Barriger RB, Rengan R, Moreno M, Bradley JD, Kim TH, Ramella S, Marks LB, De Petris L, Stitt L, Rodrigues G (2013) Predicting radiation pneumonitis after chemoradiation therapy for lung cancer: an international individual patient data meta-analysis. *Int J Radiat Oncol Biol Phys*, **85(2)**: 444-50.
 24. Kumar S, Singhal V, Roshan R, Sharma A, Rembhotkar, GW. Ghosh B (2007) Piperine inhibits TNF-alpha induced adhesion of neutrophils to endothelial monolayer through suppression of NF-kappaB and IkappaB kinase activation. *Eur J Pharmacol*, **575(1-3)**: 177-86.
 25. Linard C, Marquette C, Mathieu J, Pennequin A, Clarencon D, Mathe D (2004) Acute induction of inflammatory cytokine expression after gamma-irradiation in the rat: Effect of an NF-kappa inhibitor. *Int J Rad Onco Biol Phys*, **58(2)**: 427-34.
 26. Nogueira DS, Gazzinelli-Guimaraes PH, Barbosa FS, Resende NM, Silva CC, de Oliveira LM, Amorim CC, Oliveira FM, Mattos MS, Kraemer LR, Caliari MV, Gaze S, Bueno LL, Russo RC, Fujiwara RT (2016) Multiple Exposures to *Ascaris suum* Induce Tissue Injury and Mixed Th2/Th17 Immuneresponse in Mice. *PLoS Negl Trop Dis*, **10(1)**: e0004382.
 27. Haveman J, Geerdink AG, Rodermond HM (1998) TNF, IL-1 and IL-6 in circulating blood after total-body and localized irradiation in rats. *Oncol Rep*, **5(3)**: 679-83.
 28. Zhao JQ, Du GZ, Xiong YC, Wen YF, Bhadauria M, Nirala SK (2007) Attenuation of beryllium induced hepatorenal dysfunction and oxidative stress in rodents by combined effect of gallic acid and piperine. *Arch Pharm Res*, **30(12)**: 1575-83.
 29. Schaeue D, Micewicz ED, Ratikan JA, Xie MW, Cheng G, McBride WH (2015) Radiation and inflammation. *Semin Radiat Oncol*, **25(1)**: 4-10.
 30. Xia L, Chen S, Dahms HU, Ying X, Peng X (2016) Cadmium induced oxidative damage and apoptosis in the hepatopancreas of *Meretrix meretrix*. *Ecotoxicology*, **25(5)**: 959-69.
 31. Salem AM, Mohammad TF, Ali MA, Mohamed EA, Hassan HF (2016) Ellagic and ferulic acids alleviate gamma radiation and aluminium chloride-induced oxidative damage. *Life Sci*, **160**: 2-11.
 32. Sunila ES and Kuttan G (2005) Protective effect of Piper longum fruit ethanolic extract on radiation induced damages in mice: a preliminary study. *Fitoterapia*, **76(7-8)**: 649-55.
 33. Bukhari IA, Pivac N, Alhumayyd MS, Mahesar AL, Gilani AH (2013) The analgesic and anticonvulsant effects of piperine in mice. *J Physiol Pharmacol*, **64(6)**: 789-94.
 34. Akyildiz HY, Karabacak A, Akyuz M, Sözüer E, Akcan A (2013) Effects of piperine in experimental intestinal ischemia reperfusion model on rats. *TJTES*, **19(5)**: 387-91.
 35. Hamed RR, Saleh NS, Shokeer A, Guneidy RA, Abdel-Ghany SS (2016) Glutathione and its related enzymes in the gonad of Nile Tilapia (*Oreochromis niloticus*). *Fish Physiol Biochem*, **42(1)**: 353-64.
 36. Jayakumar S, Kunwar A, Sandur SK, Pandey BN, Chaubey RC (2014) Differential response of DU145 and PC3 prostate cancer cells to ionizing radiation: role of reactive oxygen species, GSH and Nrf2 in radiosensitivity. *Biochim Biophys Acta*, **1840(1)**: 485-94.
 37. Korge P, Calmettes G, Weiss JN (2015) Increased reactive oxygen species production during reductive stress: the roles of mitochondrial glutathione and thioredoxin reductases. *Biochim Biophys Acta*, **1847(6-7)**: 514-525.
 38. Singha I and Das SK (2016) Scavenging and antioxidant properties of different grape cultivars against ionizing radiation-induced liver damage *ex-vivo*. *Indian J Exp Biol*, **54(4)**: 280-5.
 39. Nilani P, Kasthuribai N, Duraisamy B, Dhamodaran P, Ravichandran S, Ilango K, Suresh B (2009) *In-vitro* antioxidant activity of selected antiasthmatic herbal constituents. *Anc Sci Life*, **28(4)**: 3-6.
 40. Selvendiran K, Senthilnathan P, Magesh V, Sakthisekaran D (2004) Modulatory effect of Piperine on mitochondrial antioxidant system in Benzo(a) pyrene-induced experimental lung carcinogenesis. *Phytomedicine*, **11(1)**: 85-9.

41. Ding NH, Li JJ, Sun LQ (2013) Molecular mechanisms and treatment of radiation-induced lung fibrosis. *Curr Drug Targets*, **14(11)**: 1347-56.
42. Kang YE, Kim JM, Joung KH, Lee JH, You BR, Choi MJ, Ryu MJ, Ko YB, Lee MA, Lee J, Ku BJ, Shong M, Lee KH, Kim HJ (2016) The roles of adipokines, proinflammatory cytokines, and adipose tissue macrophages in obesity-associated insulin resistance in modest obesity and early metabolic dysfunction. *PLoS One*, **11(4)**: e0154003.
43. Abratt RP and Morgan GW (2002) Lung toxicity following chest irradiation in patients with lung cancer. *Lung Cancer*, **35(2)**: 103-9.
44. O'Sullivan B and Levin W (2003) Late radiation-related fibrosis: pathogenesis, manifestations, and current management. *Semin Radiat Oncol*, **13(3)**: 274-89.
45. Rube CE, Rodemann HP, Rube C (2004) The Relevance of Cytokines in the Radiation-Induced Lung Reaction. *Strahlenther Onkol*, **180(9)**: 541-9.
46. Yao H and Rahman I (2011) Current concepts on oxidative/ carbonyl stress, inflammation and epigenetics in pathogenesis of chronic obstructive pulmonary disease. *Toxicol Appl Pharmacol*, **254(2)**: 72-85.
47. Hemmati AA, Rezaie A, Darabpour P (2013) Preventive effects of pomegranate seed extract on bleomycin-induced pulmonary fibrosis in rat. *Jundishapur J Nat Pharm Prod*, **8(2)**: 76-80.
48. Kurundkar AR, Kurundkar D, Rangarajan S, Locy ML, Zhou Y, Liu RM, Zmijewski J, Thannickal VJ (2016) The matricellular protein CCN1 enhances TGF- β 1/SMAD3-dependent profibrotic signaling in fibroblasts and contributes to fibrogenic responses to lung injury. *FASEB J*, **30(6)**: 2135-50.
49. Bang JS, Oh DH, Choi HM, Sur BJ, Lim SJ, Kim JY, Yang HI, Yoo MC, Hahm DH, Kim KS (2009) Anti-inflammatory and antiarthritic effects of piperine in human interleukin 1 β -stimulated fibroblast-like synoviocytes and in rat arthritis models. *Arthritis Res Ther*, **11(2)**: R49.