

• **Review Article****Radiotherapy techniques for intracranial tumours****M.A. Mosleh-Shirazi^{1,2*}**¹ Radiotherapy Department, Namazi Hospital, Shiraz University of Medical Sciences, Shiraz, Iran² Joint Department of Physics, Royal Marsden Hospital and Institute of Cancer Research Sutton, Surrey, UK

Intracranial tumours often require radiotherapeutic approaches that differ from other sites. Their specific requirements merit a specialized discussion. A brief review of radiotherapy techniques to treat intracranial tumours is presented with emphasis on the author's own experience and work, where appropriate. A clinical introduction is presented first followed by a description of both conventional and modern techniques. Examples from clinical practice are also given. The issues discussed include direct simulation, 2D and 3D treatment planning, the use of CT and other imaging modalities, field shaping and non-coplanar techniques. While new technological advances have paved the way for many potential clinical benefits, in the modern radiotherapy era, simple conventional techniques still have a role to play in routine clinical practice. As new technologies are introduced into relatively under-resourced centres, they should be used judiciously and appropriately to maximize benefit to the whole patient population. Iran. J. Radiat. Res., 2006; 4 (2): 53-62

Keywords: Cranial radiotherapy, brain tumours, intracranial tumours, radiotherapy techniques, treatment planning.

INTRODUCTION

The central nervous system (CNS) consists of the brain and the spinal cord. CNS tumours are relatively rare (<2% of all cancers and cancer deaths). Their incidence with age has two peaks, one in childhood (5-9 years) and the other >50 years where it increases with age. They can be malignant or benign. Even benign tumours can be critical due to their location in brain tissue (e.g., compressing the surrounding tissue) and possibly fatal.

Radiosensitivity differs among CNS tumours, e.g., high-grade gliomas are generally radioresistant while medulloblastoma is more radiosensitive. Radiotherapy (RT) is usually given following surgery and can be radical (with curative intent) or palliative (to relieve

symptoms). For instance, treatment of CNS germinomas and medulloblastoma is likely to be curative while only short-term palliation is achieved with high-grade astrocytomas.

The majority of CNS tumours develop within the brain. Figure 1 shows a schematic classification of intracranial tumours according to site. However, some tumours, e.g., medulloblastoma, ependymoma, germinoma and CNS lymphoma can spread to the spine via the cerebrospinal fluid pathways.

In this paper, RT of intracranial tumours will be reviewed briefly with more emphasis on the methods that have been developed and/or used at the Royal Marsden Hospital, UK.

Organs at risk

There are several normal organs that are at risk in cranial RT. They may influence the choice of the treatment planning technique that is used depending on the prescribed dose and fractionation, the patient's age and prognosis, the location of the target and the history of the disease (e.g., previous treatments). Such organs at risk include the hair follicles, the eyes (especially lenses), the lacrimal glands, the optic nerves and chiasm, the pituitary gland, the hypothalamus, the parotid glands, the cochleae, the brainstem, the temporal lobes of the brain, the mouth, the thyroid gland and the normal (non-target) brain. Some of these organs are depicted in figure 2. Side effects may include

***Corresponding author:**

Dr. Mohammad Amin Mosleh-Shirazi, Radiotherapy Department, Namazi Hospital, Shiraz University of Medical Sciences, Shiraz 71936-13311, Iran.

Fax: +98 711 6260135

E-mail: mosleh_amin@hotmail.com

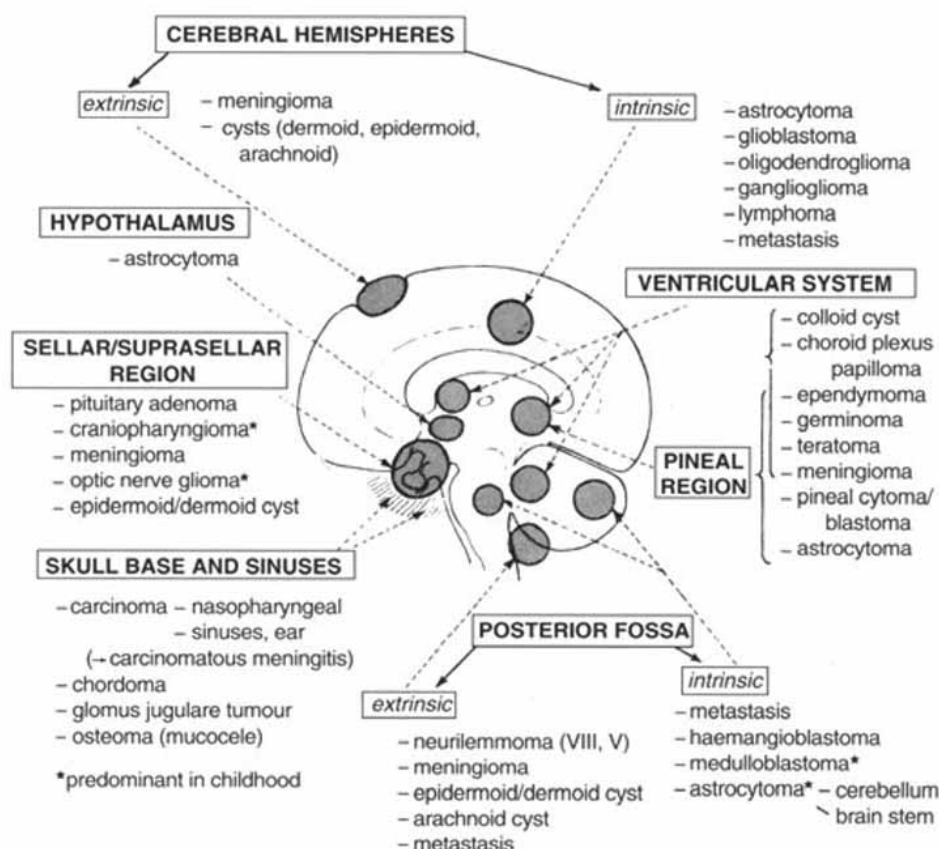


Figure 1. A schematic classification of intracranial tumours according to site (From Ref.25).

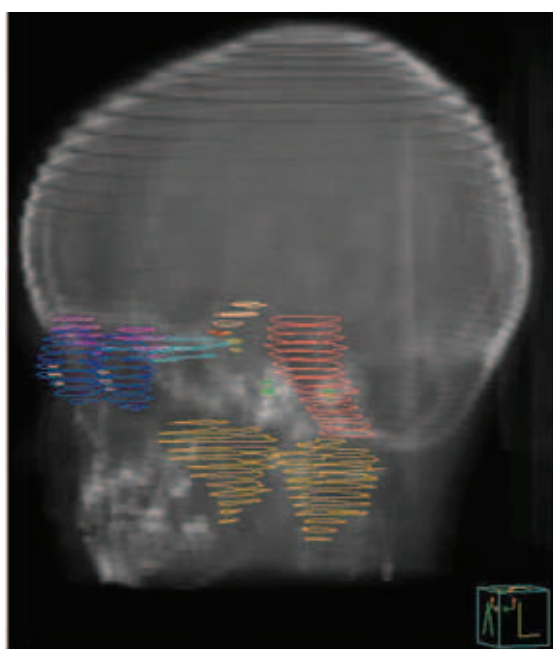


Figure 2. Some of the organs at risk in cranial radiotherapy. The eyes, lenses, lacrimal glands, optic nerves, optic chiasm, pituitary gland, hypothalamus, brainstem, cochleae and parotid glands are outlined.

visual deficits (optical apparatus), dry eyes (lacrimal glands), endocrine deficits (pituitary/hypothalamus), hearing defects (cochleae), cognitive impairment (supratentorial brain, i.e., the brain tissue superior to the tentorium therefore excluding the posterior fossa), memory loss (temporal lobes), cerebrovascular events (blood vessels), dry mouth (parotid glands), sore mouth (lining of the oral cavity), hair loss (hair follicles), cancer induction (all tissues) and possibly death (brain stem).

As an example, radiation-induced hair loss will be discussed in greater detail here, as it often receives limited attention. Although not life threatening, hair loss can be one of the most stressful side effects for patients undergoing cranial irradiation (especially paediatric/adolescent patients treated with curative intent). Temporary hair loss is dose-dependent. It occurs about 2-3 weeks after irradiation and usually resolves within 2-3

months after completion of RT. Doses as low as 2 Gy in a single fraction have been shown to cause temporary hair loss ⁽¹⁾. As for long-term hair loss after cranial irradiation, a dose-response relationship had not been obtained until recently. The average human scalp follicle is approximately 4.5 mm deep. For a group of patients, the probability of alopecia remaining one year after irradiation correlated with the follicle dose calculated at that depth resulting in the relationship shown in figure 3 ⁽²⁾. A 43 Gy dose to the follicles led to moderate or severe long-term hair loss in 50% of the patients while a 25 Gy dose was associated with a <20% risk. For megavoltage x-rays, the peak dose occurs deeper in tissue at higher beam energies therefore offering better 'skin sparing', as demonstrated in figure 4 by the calculated dose at the 4.5 mm depth of the follicles. However, this only holds where the contribution to the follicle dose from other beams is negligible (e.g., no beam overlap at or near the surface). In fact, differences in beam energy (range 4-10 MV) did not correlate with long-term hair loss in that study (however there is some clinical experience contrary to that). Moreover, the dose reduction on the beam exit side of the patients' scalp due to scatter inequilibrium

(analogous to dose 'build-up' at the entrance surface) was measured at the depth of the follicles to be only 1% for 4-10 MV beams. This data shows that avoidance of long-term hair loss may not be achievable for a significant proportion of the patients for typically large fields and simple techniques (such as parallel-opposed beams) used to treat aggressive tumours, especially when the prescription dose is ≥ 50 Gy. The size of the target volume permitting, the use of multiple non-overlapping fields (or arcs) can help reduce follicle dose. Using lower density/thickness immobilisation casts ⁽³⁾, cutting out the field area from the cast and replacing the cast with a stereotactic frame can also reduce follicle dose. In whole-brain RT, shielding the circumference of the skull can reduce follicle dose as well as the use of intensity-modulated radiotherapy (IMRT) to avoid the high doses in that region and/or through a complex hair-sparing approach ⁽⁴⁾.

Conventional treatment planning

The conventional technique for planning of cranial RT is based on simulator images. However, with the exception of parallel-opposed pairs aimed at palliation, most centres increasingly use CT images (and sometimes other image modalities) for

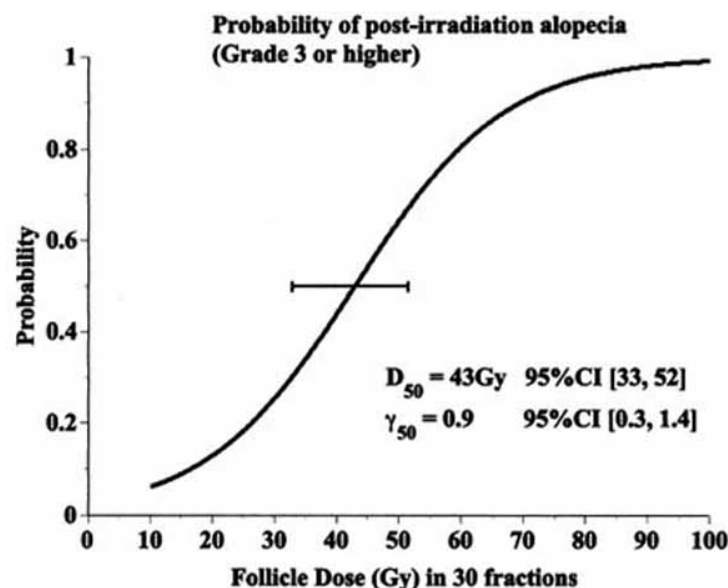


Figure 3. Dose-response relationship for moderate or severe hair loss one year after completion of radiotherapy. D_{50} = follicle dose at which 50% of the patients suffer hair loss after one year. γ_{50} = slope of the curve at 50% probability. CI = confidence interval (From Ref.2).

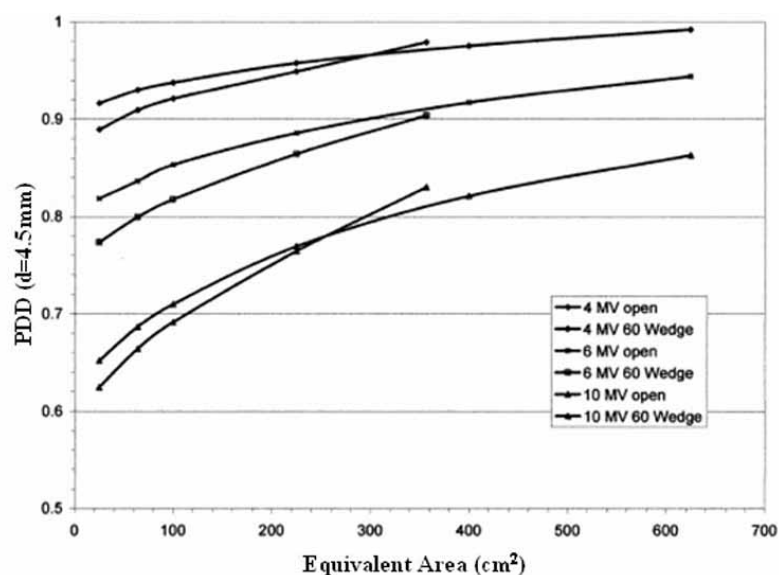


Figure 4. Percentage depth-dose at the average depth of hair follicles (4.5 mm) for various beam energies and different field areas. Dose to follicles increases with decreasing beam energy and increasing field area (From Ref.2).

treatment planning. The conventional methods can be divided into two types: (1) using single fields or parallel-opposed pairs directly defined at simulation, (2) using a 2D target volume reconstructed on a transverse or inclined patient contour. In both cases, all tissues are normally assumed to be equivalent to water.

Direct simulation

This simple method is still used nowadays in advanced centres but mostly for palliative cases. It normally requires only a simple monitor unit (MU) calculation and therefore the patient can start treatment almost immediately after simulation. The field borders and any required shielding are defined directly with respect to visible bony anatomy often aided by information from diagnostic scans. The dose may be prescribed as 'applied' (i.e., to the depth of dose maximum of the field in question), at a given depth in tissue, or as a mid-plane dose (MPD) halfway in tissue between opposing beams. When the target volume is closer to one side of the brain than the other, or if sparing of critical structures on one side is required, the delivered dose can be weighted asymmetrically (e.g., by a 2:1 ratio) either by offsetting the depth of the dose prescription

point or by specifying the ratio of the beam MUs.

2D treatment plan based on a target volume

This method allows the use of wedges and more complicated beam geometries. Treatment planning computers have been used for this purpose for at least the last 20 years. The process normally starts by obtaining an orthogonal pair of simulator radiographs (usually anterior-posterior and lateral) on each of which the clinician draws the target area after simulation. Alternatively, the target area can be defined during simulation and marked using the simulator field wires. An external transverse contour of the patient's cast is obtained normally through the centre of the target volume. (If appropriate, the plane in which the contour is taken may be inclined instead of exactly transverse but here we assume a vertical plane for simplicity). If the contour is taken manually, it is then transferred to paper. The target volume, demagnified from radiographs to the plane of the centre of the target, is then reconstructed (drawn) within the external contour. Organs at risk may also be contoured. The contour lines are then digitised into a treatment planning system. A

treatment plan is then produced typically using 2-4 coplanar beams depending on the size and position of the target volume. The prescription (normalisation) point is usually the centre of the target volume. In order to cover the target volume by the 95% isodose as required, the field borders have to extend outside it (by typically 6 mm for a 6 MV beam) to account for the field edge penumbra.

In such 2D treatment plans, the dose distribution is only obtained in the central plane (unless multiple contours are taken). The contours are assumed to stay the same superior and inferior to the centre.

Modern treatment planning

The limitations of conventional 2D planning mean that more modern methods are used increasingly. Such methods employ CT to define the patient anatomy for target localisation and dose calculation in 3D (the former sometimes being in conjunction with other imaging modalities). They also use accurate dose calculation algorithms to compute the dose taking account of the surrounding tissues in 3D. Advanced cranial treatment planning usually utilizes non-coplanar beams (i.e., with their central axes not contained in a single plane). Some of the issues regarding modern cranial treatment planning are discussed below.

CT-based treatment planning

Using CT images as the basis for the treatment plan has the following main advantages over conventional 2D planning:

1. The target volume can be delineated on multiple tomographic slices to minimize assumptions made about the variation of the target shape superior and inferior to the centre.
2. CT images can be co-registered with those from other modalities (e.g., MRI) to take advantage of the additional information contained in them.
3. Electron density of the tissues (the required quantity for dose calculation) can be derived from the image intensity values (Hounsfield units) in order to take account of the inhomogeneities in tissue densities

when calculating dose.

4. Non-coplanar beams can be readily planned and visualised using CT images providing the required anatomical extent is imaged.
5. The images are geometrically correct (i.e., do not suffer from distortion, apart from possible artefacts such as streaks from high-density dental fillings) so that geometric corrections are not required and the beam set-up information with respect to the patient is directly obtainable from them.

Some planning systems such as the Philips Pinnacle require the user to enter a CT-to-density conversion table. An accurate conversion table specific to the CT scanner used is recommended to obtain correct dose calculations based on voxel-by-voxel inhomogeneity correction. The conversion table in Pinnacle is in the form of CT number (numerically equal to Hounsfield units plus 1000) versus physical (mass) density. Density values are used through linear interpolation from the nearest data points in the conversion table in order to (i) look up mass attenuation coefficients and (ii) scale the dose deposition kernel to include the effects of inhomogeneities on scattered radiation. A common method of acquiring the conversion data from CT numbers to density information is by scanning a calibration phantom. The effect of the data used to devise a table through the calibration phantom method has been studied for cranial RT ⁽⁵⁾. Using additional data points in the CT-to-density table, with densities measured for the actual inserts used in the experiment as opposed to being looked up from published or manufacturers' data, reduced unnecessary systematic errors in calculated dose. However, the magnitude of the effect is small ($\leq 0.5\%$) for cranial RT.

Non-coplanar treatments

Depending on the size of the planning target volume (PTV), advantages may be gained by using non-coplanar beams, both in terms of critical structure avoidance and reduction of beam overlap, thus reducing

normal tissue doses. Figure 5 shows the difference in normal tissue cumulative dose volume histograms (DVHs) for a spherical volume treated by three fields, arranged in a coplanar and non-coplanar manner. In both cases, the fields are maximally separated in space (i.e., 120° separation for the coplanar plan and orthogonal fields for the non-coplanar). Brain tumours are ideally suited to non-coplanar planning due to the good access that is achievable. Figure 6 shows some beam arrangements that can be used for brain tumours. Planning studies of sellar and parasellar PTVs of fairly regular shape with volumes in the range $15\text{--}110\text{ cm}^3$ have shown that no additional normal brain sparing is obtained from increasing the number of fields above 4-6 ^(6, 7). No improvement was shown in the volume of brain receiving intermediate to high doses ($\geq 60\%$ of prescription dose) beyond 4-6 fields. With larger PTVs the benefits of using a large number of fields diminish further while for small irregular PTVs a large number of fields can be advantageous. Increasing the number of fields spreads the low doses around an increasing volume of normal brain, which may be an issue in terms of cancer induction in children and young patients. In practice, smaller numbers of fields correspond to shorter treatment times and, if shielding blocks are used, to reduced mould room time.

A major characteristic of IMRT is that it

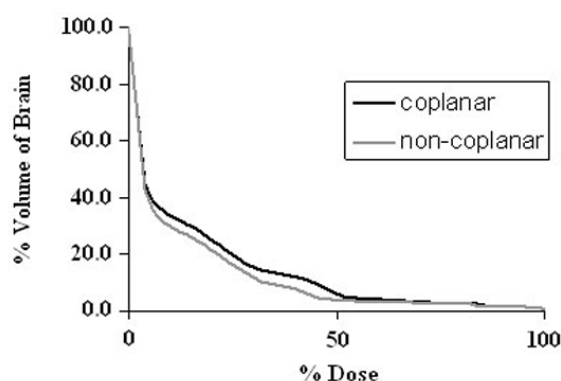


Figure 5. Cumulative dose volume histograms for a spherical target volume treated by three maximally separated fields, arranged in coplanar and non-coplanar arrangements. (Courtesy E.J. Adams, Royal Marsden NHS Foundation Trust, Surrey, UK)

can produce a concave dose distribution within transverse patient planes. The greater access offered by non-coplanar cranial fields' means that such concave dose distributions can be produced without using IMRT, as shown in figure 7.

The following additional points should be considered when using non-coplanar fields:

1. It is necessary to obtain a larger CT set than usual, as there has to be sufficient tissue for the beams to pass through. For brain tumours, it is necessary to scan from the jaw region to the top of the head. Also, it may be necessary to reduce the CT slice separation in order to get adequate resolution to design accurate conformal blocks or multileaf collimator (MLC) fields and to obtain good quality digitally reconstructed radiographs (DRRs) (see point 3 below).
2. Possible collisions between the gantry and patient/couch have to be considered. As a general rule, collisions are less likely when the couch and gantry are not given rotations of the same sense, i.e. if the gantry has a positive rotation; the couch has a negative one. For some immobilisation devices, there will be undesirable beam orientations, e.g. for patients in a stereotactic frame, beams which would enter through the frame should be avoided. Also, the beam exits need to be considered, e.g. for young patients, exiting through the thyroid should be avoided.
3. Non-coplanar treatments may include fields that cannot be simulated or verified via electronic portal imaging due to collisions between couch/patient and intensifier/imager. This, however, does not normally pose a problem as the position of the isocentre is usually verified by taking straight lateral and anterior-posterior images rather than using the actual beam directions. DRRs may be used to 'virtually simulate' fields which cannot be imaged using the conventional simulator; this may give additional useful information in some cases.

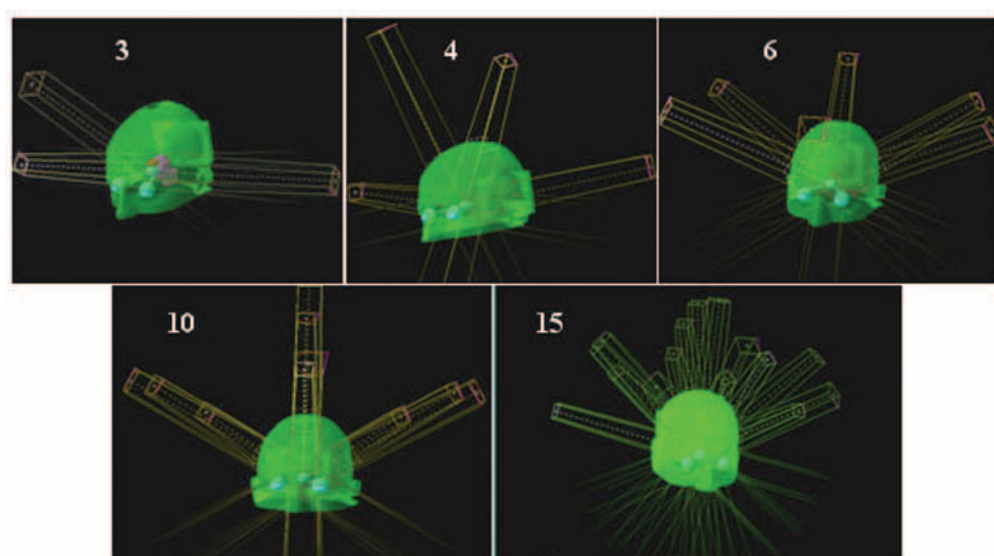


Figure 6. Possible beam arrangements for 3-field coplanar and 4-, 6-, 10- and 15-field non-coplanar plans.

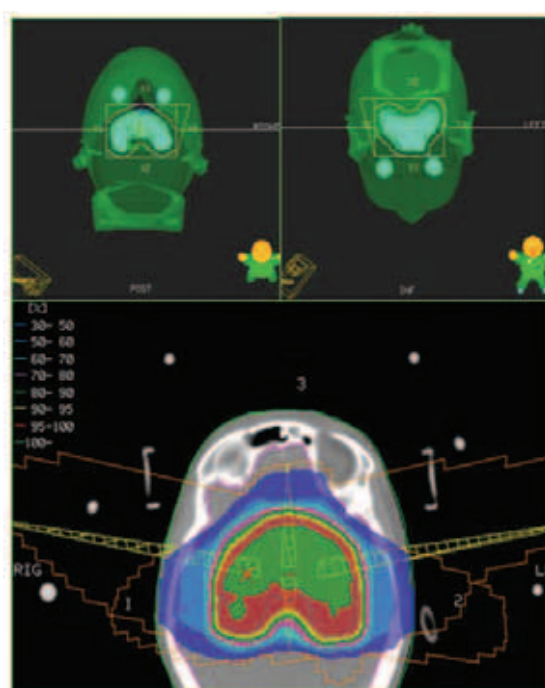


Figure 7. Non-coplanar posterior-superior (top left) and anterior-superior (top right) oblique beams with 5 mm wide multileaf collimation fitted to a concave PTV. Bottom: The concave 'IMRT-like' high-dose distribution from these beams together with right- and left-posterior-inferior oblique fields.

Use of different imaging modalities

Although CT is very useful in treatment planning because of the anatomical and electron density information it provides, it is often not the ideal modality to see the tumour. For example, many tumours in the brain and head and neck regions are more

clearly defined in MR images than CT^(8, 9). In such cases, it is useful to utilise information from both modalities following co-registration of the two images, using MR to define the GTV and then the geometrically accurate CT to calculate the treatment plan. The co-registration may be performed manually⁽¹⁰⁾ or automatically using software^(11, 12). It is important to note that the information on the extent of the GTV within the CT and MR images are complementary and the MRI-delineated target should be checked on CT⁽⁹⁾. Nuclear medicine images, such as those obtained from single-photon emission computed tomography (SPECT) or positron emission tomography (PET) can also yield useful information as well as functional magnetic resonance imaging (fMRI).

Brain activation studies can also present useful information⁽¹³⁾. Patients are given various stimuli during imaging by either PET or fMRI in order to see the functional parts of the normal brain. This then indicates which regions may be critical in terms of adverse effects on normal brain function and these can therefore be avoided. This may be of particular importance in children.

Field shaping

Shaped fields give better conformation of the high dose region to the PTV and reduce the volume of normal tissue receiving a high

dose. Shaping of the fields is achieved using either lead alloy blocks or MLCs. The former give more precise shaping at the cost of additional mould room and patient treatment time. Recent advances in technology have led to the development of micro/mini MLCs that have leaf widths (projected to the isocentre) of typically 2-5 mm; these give improved shaping compared to the standard MLCs with leaf width of 10 mm (see figure 8).

Specialized techniques

Using stereotaxy or IMRT adds further levels of complexity to the methods discussed above. A detailed discussion of stereotaxy and intensity modulation in intracranial RT is, of course, outside the scope of this review. However, some of the issues discussed in this paper also apply to either or both techniques.

Stereotaxy is a specialized sub-type of intracranial RT. Stereotactic techniques fall broadly into two categories: methods based on a linear accelerator (linac) or those performed using the Gamma Knife ⁽¹⁴⁻¹⁷⁾. In turn, linac-based techniques divide into arcs (with circular collimators or dynamic MLC) ⁽¹⁸⁾ and multiple fixed conformal fields ^(7, 19, 20). Gamma Knife and linac arcs are suited to radiosurgery (single session) while multiple fixed fields on a linac are suited to fractionated stereotactic radiotherapy.

IMRT can also be used in intracranial RT although this site has not been an area of focus for IMRT. Excellent immobilisation can be achieved for intracranial RT which provides the platform for a reasonably safe application of this complex technique and/or a reduction in target margin. However, the fact that IMRT has not been used for

intracranial RT as much as in, for instance, the head and neck or prostate, is at least partly due to the rival stereotactic techniques as well as the rareness of concave target volumes (a strong point of IMRT) such as the one in figure 7. Whole-ventricular RT is an example of the presence of such a concave target and can benefit from IMRT ^(21, 22). However, the use of IMRT in conjunction with a large number of fields normally leads to an increased volume of 'low-level' irradiation to the normal brain, which carries an increased risk of secondary cancer induction especially in children and young adults ⁽²³⁾.

Examples in clinical practice

Table 1 summarizes the RT techniques normally used at the Royal Marsden Hospital for the treatment of gliomas (diseases ranging from benign to highly malignant), which vary depending on the stage of the disease, being more complex for small low-grade tumours. Another example in which the technique used depends on the individual situation is meningioma (a predominantly benign disease). In this case, the complexity of the treatment varies from involved-field RT (generally a simple technique with beam shaping to only target the disease area) to stereotactic conformal radiotherapy (SCRT; a fractionated multiple-beam treatment) or stereotactic radiosurgery (single-fraction irradiation normally using arcs), depending on the tumour being benign or malignant, the surgical excision being complete or incomplete, and if the treatment is for recurrent disease or not. For acoustic neuromas (benign, slowly-growing diseases),




Figure 8. Comparison of the level of conformity to the PTV (red structure) in order to avoid the eyes (blue structures) that is achieved with three different field-shaping devices.

Table 1. Typical radiotherapy techniques currently used at the Royal Marsden Hospital, UK, to treat gliomas. GTV = gross tumour volume. SCRT = stereotactic conformal radiotherapy.

Grade	High		Low	
GTV size	All	All	>4 cm diameter	<4 cm diameter
Intent	Palliative	Radical	Radical	Radical
Standard technique	Simulator-planned, Parallel-opposed pair	CT-planned, 3-4 coplanar fields	CT-planned, 3-6 coplanar or non-coplanar fields	CT-planned, 4-6 field non-coplanar SCRT (target defined on CT-MR registered images)

customisation of the technique depends on the size and shape of the tumour: SCRT is normally used but in cases of small spherical lesions, stereotactic arcs can be implemented as they offer further normal-tissue sparing for such target types. Craniopharyngiomas and pituitary tumours are benign and preferably treated with SCRT due to their proximity to the optic nerves. Immobilisation technique depends on the disease and patient tolerance ranging from simple thermoplastic casts to a high-precision 'conformal' shell system ⁽²⁴⁾ and to paediatric ⁽⁵⁾ and adult ⁽⁶⁾ stereotactic frames.

Radiotherapy of brain metastases

Metastases form another category of intracranial tumours and require a different approach. The treatment of metastases in the brain depends on the primary cancer and the extent of metastatic spread. At the Royal Marsden Hospital, metastases from previously untreated small cell lung cancer are treated with whole-brain RT (after chemotherapy). Germ cell tumour metastases are also given whole-brain RT after chemotherapy but may also receive a stereotactic boost. For other primary tumour types, multiple metastases receive whole-brain RT while solitary metastases of <3.5-4 cm diameter are treated with radiosurgery using stereotactic arcs (or surgery).

DISCUSSION

In practice, RT resources are not unlimited and therefore should be utilised in the most

beneficial way to the whole patient population. As the more complex treatment techniques require more resources, they should be used primarily in cases where the efficacy of the treatment and the patient's prognosis warrant it. For example, a child with low-grade glioma is expected to survive for many years ⁽²⁰⁾ and it is highly relevant to employ any available resources (e.g., multi-modality imaging and stereotactic/intensity-modulated/proton RT) to reduce cognitive, endocrine and growth side effects. Patient tolerance also plays an important part; it is generally not appropriate to subject a patient to a long and complicated treatment regime where only short-term palliation is possible and the patient may suffer more as a result of the demands of the treatment technique compared to a simple one. As an increasing number of new technologies become available, they should be used judiciously and appropriately to maximize benefit to the whole patient population.

REFERENCES

1. Hamilton CS, Potten CS, Denham JW, O'Brien PC, Kron T, Ostwald P, Wright S, Ramsden J (1997) Response of human hair cortical cells to fractionated radiotherapy. *Radiother Oncol*, **43**: 289-92.
2. Lawenda BD, Gagne HM, Gierga DP, Niemierko A, Wong WM, Tarbell NJ, Chen GT, Hochberg FH, Loeffler JS (2004) Permanent alopecia after cranial irradiation: dose-response relationship. *Int J Radiat Oncol Biol Phys*, **60**: 879-87.
3. Carl J and Vestergaard A (2000) Skin damage probabilities using fixation materials in high-energy photon beams. *Radiother Oncol*, **55**: 191-8.
4. Roberge D, Parker W, Niazi TM, Olivares M (2005)

- Treating the Contents and Not the Container: Dosimetric Study of Hair-sparing Whole Brain Intensity Modulated Radiation Therapy. *Technol Cancer Res Treat*, **4**: 567-70.
5. Mosleh-Shirazi MA, Hansen VN, Childs PJ, Warrington AP, Saran FH (2004) Commissioning and implementation of a stereotactic conformal radiotherapy technique using a general-purpose planning system. *J Appl Clin Med Phys*, **5**: 1-14.
 6. Perks JR, Jalali R, Cosgrove VP, Adams EJ, Shepherd SF, Warrington AP, Brada M (1999) Optimization of stereotactically-guided conformal treatment planning of sellar and parasellar tumors, based on normal brain dose volume histograms. *Int J Radiat Oncol Biol Phys*, **45**: 507-13.
 7. Ajithkumar TV, Mosleh-Shirazi MA, Burke K, Brada M (2002) Can we gain from complexity? Optimization of stereotactically-guided conformal radiotherapy of brain tumours based on normal brain dose volume histograms. *Radiother Oncol*, **64**: S83.
 8. Thornton AF, Jr., Sandler HM, Ten Haken RK, McShan DL, Fraass BA, La Vigne ML, Yanke BR (1992) The clinical utility of magnetic resonance imaging in 3-dimensional treatment planning of brain neoplasms. *Int J Radiat Oncol Biol Phys*, **24**: 767-75.
 9. Khoo VS, Adams EJ, Saran F, Bedford JL, Perks JR, Warrington AP, Brada M (2000) A Comparison of clinical target volumes determined by CT and MRI for the radiotherapy planning of base of skull meningiomas. *Int J Radiat Oncol Biol Phys*, **46**: 1309-17.
 10. Mosleh-Shirazi MA and South CP (2005) How precise is manual CT-MRI registration for cranial radiotherapy planning? *Iran J Radiat Res*, **3**: 53-62.
 11. Maintz JB and Viergever MA (1998) A survey of medical image registration. *Med Image Anal*, **2**: 1-36.
 12. West J, Fitzpatrick JM, Wang MY, Dawant BM, Maurer CR, Jr., Kessler RM, Maciunas RJ, Barillot C, Lemoine D, et al. (1997) Comparison and evaluation of retrospective intermodality brain image registration techniques. *J Comput Assist Tomogr*, **21**: 554-66.
 13. Sharma R and Sharma A (2004) Physiological basis and image processing in functional magnetic resonance imaging: neuronal and motor activity in brain. *Biomed Eng Online*, **3**: 13.
 14. Gerosa M, Nicolato A, Foroni R (2003) The role of gamma knife radiosurgery in the treatment of primary and metastatic brain tumors. *Curr Opin Oncol*, **15**: 188-96.
 15. Stieber VW, Bourland JD, Tome WA, Mehta MP (2003) Gentlemen (and ladies), choose your weapons: Gamma knife vs. linear accelerator radiosurgery. *Technol Cancer Res Treat*, **2**: 79-86.
 16. Stieber VW and Ellis TL (2005) The role of radiosurgery in the management of malignant brain tumors. *Curr Treat Options Oncol*, **6**: 501-8.
 17. Deinsberger R and Tidstrand J (2005) Linac radiosurgery as a tool in neurosurgery. *Neurosurg Rev*, **28**: 79-88.
 18. Meeks SL, Buatti JM, Bova FJ, Friedman WA, Mendenhall WM (1998) Treatment planning optimization for linear accelerator radiosurgery. *Int J Radiat Oncol Biol Phys*, **41**: 183-97.
 19. Minniti G, Saran F, Traish D, Soomal R, Sardell S, Gonsalves A, Ashley S, Warrington J, Burke K, Mosleh-Shirazi A, Brada M. (2007) Fractionated stereotactic conformal radiotherapy following conservative surgery in the control of craniopharyngiomas. *Radiother Oncol*, **82**: 90-5.
 20. Saran FH, Baumert BG, Khoo VS, Adams EJ, Garre ML, Warrington AP, Brada M (2002) Stereotactically guided conformal radiotherapy for progressive low-grade gliomas of childhood. *Int J Radiat Oncol Biol Phys*, **53**: 43-51.
 21. Raggi E, Mosleh-Shirazi MA, Saran FH (2005) Whole ventricular irradiation (WVRT) in intracranial germ cell tumors (CNS GCTs): an evaluation of conformal and intensity modulated radiotherapy (IMRT) planning. *Neuro-oncol*, **7**: 532-533.
 22. Rogers SJ, Mosleh-Shirazi MA, Saran FH (2005) Radiotherapy of localised intracranial germinoma: time to sever historical ties? *Lancet Oncol*, **6**: 509-19.
 23. Soomal R, Mosleh-Shirazi MA, Saran F, Brada M (2002) What is the cost of cochlea avoidance in paediatric medulloblastoma? Evaluation of 3D conformal and IMRT planning techniques for the posterior fossa boost. *Radiother Oncol*, **64**: S81.
 24. Mosleh-Shirazi MA, Taylor H, Warrington AP, Saran FH (2006) Measurement of the immobilisation efficacy of a head fixation system. *Iran J Radiat Res*, **4**: 1-6.
 25. Lindsay KW, Bone I, Callander R (1991) Neurology and neurosurgery illustrated 2nd ed: Churchill Livingstone.