

Peri-operative radiotherapy for the prevention of post-operative fibrosis on rats

H.S. Kiziltan¹, A.H. Eris¹, I. Meral², H. Seyithanoglu³, T. Dundar³, F. Eren⁴, N. Unver⁵, T. Aydin⁴, A. Mayadagli^{1*}, A.G. Bayir⁶, M. Celikten⁷

¹Department of Radiation Oncology, Bezmialem Vakif University, Faculty of Medical, 34093 Fatih, Istanbul, Turkey

²Department of Physiology, Faculty of Medical, Bezmialem Vakif University, 34093 Fatih, Istanbul, Turkey

³Department of Neurosurgery, Bezmialem Vakif University 34093 Faculty of Medical, Fatih, Istanbul, Turkey

⁴Department of Physical Therapy and Rehabilitation, Bezmialem Vakif University, Faculty of Medical, 34093 Fatih, Istanbul, Turkey

⁵Department of Pathology, Bezmialem Vakif University, Faculty of Medical, 34093 Fatih, Istanbul, Turkey

⁶Department of Nutrition and Dietetics, Bezmialem Vakif University Faculty of Medical, 34093 Fatih, Istanbul, Turkey

⁷Department of Animal Scientific Research Center, Bezmialem Vakif University Medical Faculty 34093 Fatih, Istanbul, Turkey

ABSTRACT

► Short Report

*Corresponding authors:

Dr. Alpaslan Mayadagli,

E-mail: alpdrag@hotmail.com

Revised: August 2017

Accepted: January 2018

Int. J. Radiat. Res., October 2018;
16(4): 481-485

DOI: 10.18869/acadpub.ijrr.16.4.481

Background: Post-operative fibrosis related pains and functional anomalies can be serious problems for patients. Radiotherapy (RT) could inhibit fibrosis which may occurs post-operation especially following laminectomy. Therefore, this study was designed to investigate the effect of peri-operative RT on the prevention of post-operative fibrosis and scar formation on rats. **Materials and Methods:** Twenty three male Wistar albino rats, were divided into three experimental groups. Laminectomy was performed to L3 and L4 lumbar vertebral regions of group L and L+R rats. The rats in L+R group in addition to this procedure also received peri-operative RT on the laminectomy area. A total dose of 700 cGy of RT was applied as a single fraction using electrons. Control rats received no treatment. A rotarod test was performed at 20, 30 and 40 rpm/min speed rates to determine the physical performances of the rats. **Results:** The results have indicated statistically significant ($P<0.05$) differences for the 30 rpm/min rotarod test between the L and L+R groups. Histopathologically, significant differences were observed in epidural fibrosis, fibroblast cell density and arachnoid adhesion between the L and L+R groups. **Conclusion:** It was concluded that peri-operative RT may provide a significant advantage for prevention post-laminectomic of scar tissue formation.

Keywords: Laminectomy, peri-operative radiotherapy, fibrosis, rotarod tests.

INTRODUCTION

Background

Fibrosis which may occurs post operation can cause physical and psychological distress and pain due to pressure it may cause and visual discomfort ⁽¹⁾.

Some procedures are currently available for the prevention and treatment of these scars. Silicone-based products such as sheets and gels,

sun exposure, compression therapy, taping and the use of moisturisers may be beneficial. Intraleisional injections of corticosteroids and/or 5-fluorouracil, cryotherapy, RT, laser therapy and surgical excision have also been used as invasive treatment options in the past ^(2, 3).

X-ray and electron beam radiation inhibits cell proliferation and improves pain and clinical symptoms in a dose-dependent manner ^(4, 5). Low-dose peri-operative RT can inhibit scar

formation and peridural fibrosis on rats ⁽³⁻⁶⁾.

Previous studies have shown good electrophysiological changes to the cauda equina after low-dose electron beam external irradiation following postlaminectomy fibrosis model on rats ⁽³⁾. Therefore, this study was designed to investigate the effect of peri-operative radiotherapy on the prevention of post-operative fibrosis and scar formation on rats.

MATERIALS AND METHODS

Animals

The study was performed in Bezmialem Vakif University Animal Research Center using 23 Wistar albino rats, aging 4 months old and weighing 250 to 300 g. All animals were housed in the Bezmialem Vakif University Experimental Animal Centre under standard laboratory conditions (12 h light/dark cycle), and a constant temperature (25 °C) and humidity (50-60 %). They were allowed free access to food and water. All animal use procedures were approved by the Laboratory Animals Ethical Committee, Bezmialem Vakif University. At the beginning of the experiment, the rats were divided into three experimental groups, laminectomy applied (L, n=9), laminectomy and peri-operative radiotherapy applied (L+R, n=9) and non-treated control (C, n=5) rats.

Laminectomy

General anesthesia was achieved with 5 mg/kg xylazine (Rompun, Bayer, Istanbul, Turkey) and 60-100 mg/kg ketamine hydrochloride (Ketalar, Eczacıbası, Istanbul, Turkey) injection into group L rats. L3-4 total laminectomy was performed with a small rongeur and high-speed drill (Aesculap Microtrone GD 412, Tuttlingen, Germany). The ligamentum flavum and epidural fat tissue were excised. Durameter and nerve roots were exposed.

Radiotherapy

Treatment planning was performed using the computed tomographic simulator to define the

anatomy and target volume. External beam radiation was performed with 6-MeV electron beam using Varian Linear Accelerator (MNT, Health Care and Trade Corporation, Turkey, Bozlu Holding). The L3-4 posterior epidural space was used as the target volume. The margins used were 1.5×2 cm which adequately covered the target volume. Radiotherapy was applied totally using a 700 cGy dose in a single fraction perioperatively. The 85 and 95% radiation field isodose curves was covered up to 2.5 cm and 1.2 cm depth depth respectively (figure 1).

Rotarod test

The rotarod test was applied to the rats one week after the operation for determining their physical performances one week following the operation. The rats were placed in a walking cylinder platform, and allowed to run on the rotating cylinder for a maximum of 180 seconds at 20, 30 and 40 rpm/min speed rates over 3 consecutive days, performed 4 times per day in 1 hour intervals and the maximum endurance time (fall down time) was determined for each rat. The maximum values obtained were then considered as the real performance value.

Histopathology

After the rats were sacrificed at the end of the 6 weeks The sections were stained with hematoxylin and eosin and Masson's trichrome. Each specimen was scored for the extent of fibrosis, density of cells, and arachnoidal involvement of fibrosis. The extent of fibrosis along the dura was graded according to the scale described by He *et al.* ⁽⁷⁾: Grade 0, dura mater was free of scar tissue; Grade 1, only thin fibrous bands were observed between the scar tissue and duramater; Grade 2, continuous adherence was observed, but it affected less than two-thirds of the laminectomy defect; and Grade 3, scar tissue adherence was large, affecting more than two-thirds of the laminectomy defect, or the adherence extended to the nerve roots. The extent of fibrosis was determined for each slide, and the distribution of grades was determined for each group.

Statistical analysis

The data presented is expressed as mean \pm standard error (SE). Kruskal Wallis test was used to analyze the differences between each

groups. For statistical analysis, we used Instat Statistical Package Program (Instat Graphpad Software v5.0, San Diego, CA, USA). $P < 0.05$ was considered to be statistically significant.

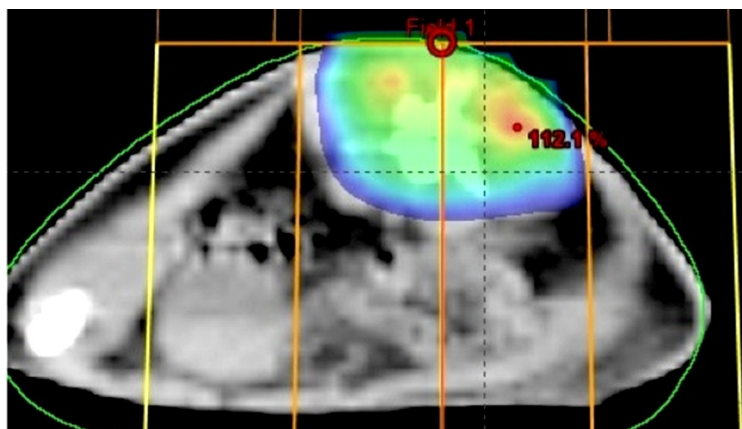


Figure 1. Radiotherapy planning with electron beams on rats.

RESULTS

Although grade 3 epidural fibrosis was observed in 4 of the 9 rats in the L group and 1 of 9 rats of L+R group (figure 2), (table 1). Arachnoid adhesion was present at a rate of 88,8 % in L and 44,4 % in the L+R group. No statistical difference ($P > 0.05$) was observed

between the L and L+R groups relating to 20 rpm/min or 40 rpm/min rotarod performance test. However, a significant difference ($P < 0.05$) was observed between L and L+R groups related to 30 rpm/min rotarod performance test (table 2). Minimal seroma was observed on 2 rats of L+R group 48 hours after the RT on post-operative site.

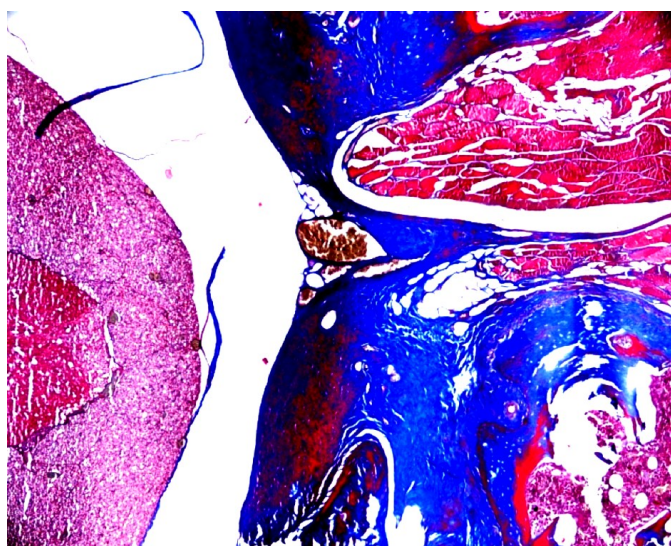


Figure 2. Grade 3 epidural fibrosis in a rat from the laminectomy group (Masson's trichrome; original magnification, X40).

Table 1. Rat groups and pathologic results were shown according to epidural fibrosis, fibroblast cell density and arachnoid adhesion of rats that received or non-received peri-operative radiotherapy

Rat Groups, pathology	L	L+R
Epidural fibrosis		
Grade 0	0	4
Grade 1	2	4
Grade 2	3	0
Grade 3	4	1
Fibroblast cell density		
Grade 1	3	8
Grade 2	3	0
Grade 3	3	1
Arachnoid adhesion		
Present	8	4
Absent	1	5

L:Laminectomy L+R: Laminectomy and radiotherapy

Table 2. The mean, median and maximum values of 30rpm/min for maximum test data.

Groups (30rpm/min)	N	Mean	S. Deviation	Median	Minimum	Maximum
L	9	103.33	50.59	99	22	180
L+R	9	142.11	41.1	159	85	180

Abbreviations: L:Laminectomy L+R: Laminectomy and radiotherapy S:Standart N: Number

because we used rotarod test for the evaluating motor functions of rats. This test was used in order to test the effect of drugs and nervous system injuries (17,18). A significant difference was observed between L and L+R groups for the 30 rpm/min rotarod tests. This study also demonstrated significant differences regarding to epidural fibrosis, fibroblast cell density and arachnoid adhesion according to pathologic reviewing between the peri-operative radiotherapy received and non-received rats. Some authors state that low dose RT might cause carcinogenesis. the literature indicates that there is only very few and doubtful radiation induced malignancy for low dose electron beam RT (19, 20).

It was concluded that the low-dose RT safely improved the scar tissue and related neurologic symptoms when applied as peri-operative. Further studies may be performed to evaluate low dose electron beam radiation to prevent surgical scars related complications to intestinal obstruction, peritoneal adhesions and urethral strictures.

Conflicts of interest: Declared none.

REFERENCES

1. Finnegan WJ, Fenlin JM, Marvel JP, Nardini RJ, Rothman RH (1979) Result of surgical intervention in the symptomatic multiply-operated back patient. Analysis of sixty-seven cases followed for three to seven years. *J Bone Joint Surg Am*, 61: 1077–1083.
2. Meaume S, Le Pillouer-Prost A, Richert B, Roseeuw D, Vadoud J (2014) Management of scars: updated practical guidelines and use of silicones. *Eur J Dermatol*, **24** (4): 435-43.
3. Ji J1, Tian Y, Zhu YQ, Zhang LY, Ji SJ, Huan J, Zhou XZ, Cao JP (2015) Ionizing irradiation inhibits keloid fibroblast cell proliferation and induces premature cellular senescence.

DISCUSSION

The laminectomy related epidural scar tissue and peridural fibrosis are primary causes of complication (8,9). Surgical excision alone results in 45–100 % recurrence (10). The recurrence rates of keloids decrease to 20 % from 45-100 % by RT. RT is accepted as the most effective treatment for severe keloids, according to the international clinical recommendations on scar management (6, 11-13).

Low-dose irradiation reduces arachnoidal, peridural fibrosis and post-laminectomy syndrome, and improves neuropathic complications. It has been demonstrated that external RT can inhibit post-surgical scar tissues and epidural fibrosis at least for the spinal membrane method (6, 7, 15, 16).

The most preferred radiation dose was 700-900 cGy with 6-9 MeV electron or 4-6 MV X beam energy as performed peri-operative period because it does not increase toxicity or carcinogenesis (4, 5, 15).

We preferred the electron beam RT in this study because it was a non-invasive and safe modality in comparison to other treatment methods.

Our study was unique from previous studies

- J Dermatol*, **42**(1):56-63.
4. Gerszten PC, Moosy JJ, Bahri S, Kalend A, Martínez AJ (1999) Inhibition of peridural fibrosis after laminectomy using low-dose external beam radiation in a rat model. *Neurosurgery*, **44**(3): 597-602.
 5. Gerszten PC, Moosy JJ, Flickinger JC, Welch WC (2003) Low-dose radiotherapy for the inhibition of peridural fibrosis after reexploratory nerve root decompression for postlaminectomy syndrome. *J Neurosurg*, **99**(3): 271-7.
 6. Borok TL, Bray M, Sinclair I, Plafker J, LaBirth L, Rollins C (1988) Role of ionizing irradiation for 393 keloids. *Int J Radiat Oncol Biol Phys*, **15**: 865-70.
 7. He Y, Revel M, Loty B (1995) A quantitative model of post-laminectomy scar formation. Effects of a nonsteroidal anti-inflammatory drug. *Spine*, **20**: 557-563.
 8. Gabriel EM and Friedman AH (1996) The failed back surgery syndrome. In: Wilkins RH, Rengachary DD, editors. New York: McGraw-Hill, *Neurosurgery*, 3863-3870.
 9. LaRocca H and Macnab I (1974) The laminectomy membrane. *J Bone Joint Surg Br*, **56**: 545-550.
 10. Berman B and Bieleley HC (1996) Adjunct therapies to surgical management of keloids. *Dermatol Surg*, **22**: 126-30.
 11. Kovalic JJ and Perez CA (1989) Radiation therapy following keloidectomy: a 20-year experience. *Int J Radiat Oncol Biol Phys*, **17**: 77-80.
 12. Mustoe TA, Cooter RD, Gold MH, Hobbs FD, Ramelet AA, Shakespeare PG, Stella M (2002) International clinical recommendations on scar management. *Plast Reconstr Surg*, **110**: 560-71.
 13. De Cicco L, Vischioni B, Vavassori A, Gherardi F, Jereczek-Fossa BA, Lazzari R, Cattani F (2014) Postoperative management of keloids: Low-dose-rate and high-dose-rate brachytherapy. *Brachytherapy*, **17**: 1538-4721(14)00025-7.
 14. Kim KD (2004) Low-dose radiotherapy for the inhibition of peridural fibrosis after reexploratory nerve root decompression for postlaminectomy syndrome. *J Neurosurg*, **100**(4): 400-1.
 15. Bora H, Aykol SV, Akyürek N, Akmansu M, Ataoglu O (2001) Inhibition of epidural scar tissue formation after spinal surgery: external irradiation vs. spinal membrane application. *Int J Radiat Oncol Biol Phys*, **1;51**(2): 507-13.
 16. Wang LZ, Ding JP, Yang MY, Chen B (2014) Forty-five cases of chest keloids treated with subcutaneous super-tension-reduction suture combined with postoperative electron-beam irradiation. *Dermatol Surg*, **40**(12): 1378-84.
 17. Jones BJ and Roberts DJ (1968) The quantitative measurement of motor inco-ordination in naive mice using an accelerating rotarod. *J Pharm Pharmacol*, **20**(4): 302-4.
 18. Balamuralikrishnan B1, Balachandar V, Kumar SS, Stalin N, Varsha P, Devi SM, Arun M (2012) Evaluation of chromosomal alteration in electrical workers occupationally exposed to low frequency of electro magnetic field (EMFs) in Coimbatore population, India. *Asian Pac J Cancer Prev*, **13**(6): 2961-6.
 19. Edsmyr F, Larsson LG, Onyango J, Wanguru S, Wood M (1974) Radiation therapy in the treatment of keloids in East Africa. *Acta Radiol Ther Phys Biol*, **13**: 102-6.
 20. Ogawa R, Yoshitatsu S, Yoshida K, Miyashita T (2009) Is radiation therapy for keloids acceptable? The risk of radiation-induced carcinogenesis. *Plast Reconstr Surg*, **124** (4): 1196-201.

