Volume 16, No 4 | International Journal of Radiation Research, October 2018

Significance of MIBI scintigraphy in a patient with hydatid cyst and parathyroid adenoma

Sh. Rafieian[1], S. Farzanefar[2], M. Abbasi[2*]

[1]*Department of Thoracic Surgery, Vali-Asr Hospital, School of Medicine, Tehran University of Medical Sciences, Tehran, Iran*

[2]*Department of Nuclear Medicine, Vali-Asr Hospital, School of Medicine, Tehran University of Medical Sciences, Tehran, Iran*

► ***Case report***

Corresponding authors:
Mehrshad Abbasi, MD,
Fax: *+ 98 21 66 57 51 03*
E-mail: *meabbasi@tums.ac.ir*

Revised: September 2017
Accepted: Oct 2017

Int. J. Radiat. Res., October 2018; 16(4): 505-507

DOI: 10.18869/acadpub.ijrr.16.4.505

ABSTRACT

A 17-year-old boy with hyperparathyroidism exhibited a large cyst in the left hemi-thorax on his chest X-ray. The cyst was identified as a hydatid cyst. He was referred for biphasic methoxy isobutyl isonitrile (MIBI) parathyroid scan. A discrete ectopic parathyroid was detected in the left upper mediastinum in addition to accumulation of the MIBI tracer in the cyst wall. Using radio-guided occult lesion localization with an injection of 3 mCi 99m Tc - MIBI in the morning of the operation day, an ectopic adenoma was detected with a gamma probe within the thymus, resected with a consequent decline of serum high parathyroid hormone (PTH). This report is remarkable in two different aspects: the importance of radio-guided localization of ectopic adenoma, which in this case was within the thymus, and the accumulation of MIBI in hydatid cyst wall, as a unique report of this condition.

Keywords: *MIBI, SPECT, Radio-guided surgery, hydatid cyst, parathyroid adenoma.*

CASE PRESENTATION

The patient was a 17-year-old boy complaining of generalized pain in the bones, especially in the dorsal torso. The pain evolved, about 2 years prior, at the dorsal thoracic area and progressed all over the body. During the work-ups, the parathyroid hormone (PTH) levels were as high as 589 pg/ml. The patient was referred to a thoracic surgeon, who found a large cystic lesion, possibly a pulmonary hydatid cyst, which is not epidemiologically rare in the region. The thoracic surgeon prescribed a biphasic methoxy isobutyl isonitrile (MIBI) scan to localize the adenoma. At the department of nuclear medicine, the patient was injected with 15 mCi ^{99m}Tc MIBI (Pars Isotope, Tehran, Iran) and underwent a planar and single photon emission tomography (SPECT) imaging 15 and 120 minutes later. A double head gamma camera (ADAC Forte, Philips, Milpitas, CA) was used with a 128×128 matrix size, 3-degree azimuth, and 15 minute stops. The thyroid uptake in the initial 15-minute image was washed out in the 120-minute delayed image, however, a discrete adenoma was localized in the left upper mediastinum (figure 1). There was also a rim of intense activity around a photon deficient, round area, with a diameter of approximately 10 cm, corresponding to the intra-thoracic cyst, in the chest X-ray (figure 2). Adenoma was not reported in the previous ultrasonographic examination. The surgeon required a clearer anatomic localization, for which he could optionally choose either repeated biphasic MIBI with SPECT/computerized tomography or radio-guided occult lesion localization (ROLL). The ROLL was conducted with an injection of 3 mCi MIBI, 3 hours before surgery. The operation was carried out through a small collar incision and with the guidance of a gamma probe (Surgiguide, PNPMed, Tehran, Iran); the highest activity was localized within the thymus, which was resected. The most active region was

[Downloaded from ijrr.com on 2026-11-24]

marked using clips, as the possible site of the adenoma. No discrete nodule was detected surgically or noticed after a gross pathological examination. As the surgeon was not convinced that he had already found the adenoma, he extended the operation with sternotomy and dissected a few subcentimer lymph nodes in the mediastinum including the aorto-pulmonary region. Concurrently, the frozen sections identified the parathyroid adenoma within the thymus gland and the intra-operative PTH was reported to be reduced to 10.1 in the peripheral blood sample. Then the surgery was completed. The bone pain was relieved, with the follow up PTH of 5.6, two weeks after the surgery. After recovery and a gap period, the patient underwent a lateral thoracotomy for the resection of the hydatid cyst, which was accomplished without complications. No other hydatid cysts were detected elsewhere, including in the liver. The patient is doing well without any particular complication. With reporting this case, we intend to document the accumulation of MIBI in the hydatid cyst wall in literature for the first time and we highlight the importance of ROLL to detect ectopic parathyroid adenoma in complicated situations.

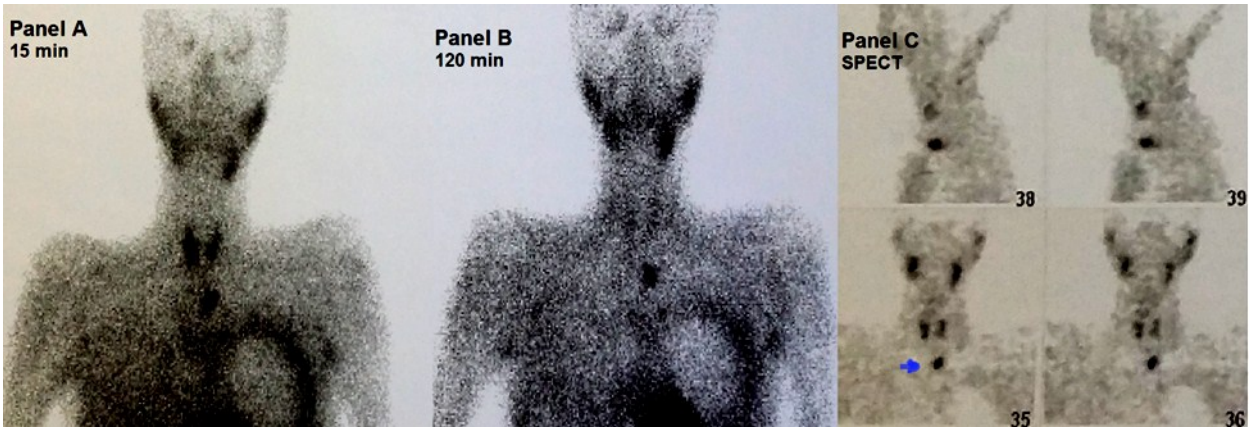

Figure 1. Biphasic MIBI scintigraphy (15- and 120-minute delayed) illustrating ectopic adenoma in both, anterior planar (panel A) and SPECT images (panel C); the activity in the hydatid cyst wall is also prominent in panel A and B, and blue marker in panel C indicates parathyroid ectopic adenoma.

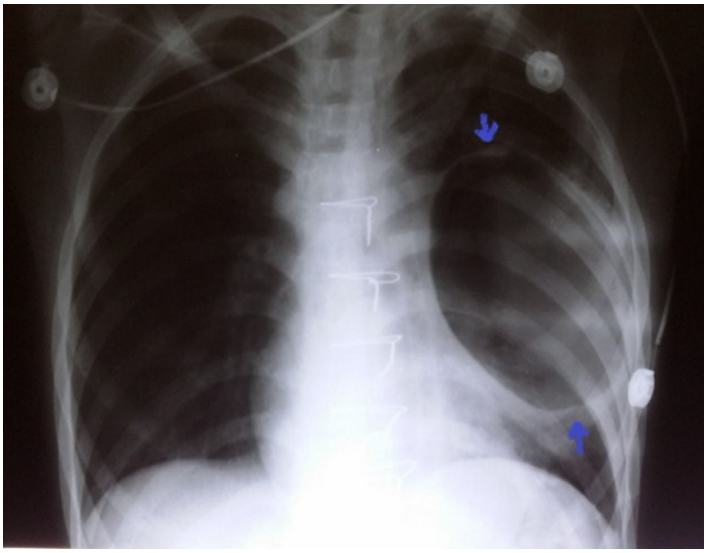

Figure 2. Intra thoracic hydatid cyst with intense accumulation of MIBI within the cyst wall. The image was acquired after the surgery for parathyroidectomy with in-place stitches; blue markers indicate hydatid cyst.

[Downloaded from ijrr.com on 2026-11-24]

DISCUSSION

This is the first report of MIBI uptake within the wall of a hydatid cyst. This disease is endemic in Iran [1] with a predilection for lungs and then liver, as noted at the referral centers including our hospital [2]. The accumulation of the MIBI in the hydatid cyst wall has not been observed before. We illustrated the chamber of the hydatid cyst as a photon-tepid area like other cysts with the intense tracer avidity in the wall. MIBI is a tumor marker agent, however, it also enters and remains within the mitochondria of the metabolically active cells including the myocardium and parathyroid adenoma [3]. Our report underscores the metabolic activity of the hydatid cyst wall.

The significance of biphasic MIBI scintigraphy for the detection and localization of adenoma is well documented [4, 5]; however, the use of MIBI as an intra-surgical guide for assistance with lesion localization is a new tool in this field [6]. ROLL is a known procedure for many operations including those for the breasts [7]. Nevertheless, the application is an advent technology in case of many other tumors including parathyroid adenoma. In the current case, the role of the ROLL was remarkable mainly due to the location of the ectopic adenoma within the thymus gland and particularly as the adenoma was not capsulated or forming a palpable nodule. The experienced thoracic surgeon did not find any palpable nodule within the thymus in this case. The appropriate and routine use of ROLL in such surgeries may assist the surgeon and reduce the operation time and extension of the surgery.

ACKNOWLEDGMENT

We thank Dr. Garivani for his assistance in preparation of the material of the images.

Human rights

The content of manuscript corresponds to international and national regulations and the material and data were handling anonymously.

Conflicts of interest*: *Declared none.

REFERENCES

1. Rokni MB (2009) Echinococcosis/hydatidosis in Iran. *Iran J Parasitol,* ***4(2)****: 1-6*.
2. Mamishi S, Sagheb S, Pourakbari B (2007) Hydatid disease in Iranian children. *J Microbiol Immunol Infect,* ***40(5)****: 428-31*.
3. Moretti JL, Hauet N, Caglar M, Rebillard O, Burak Z (2005) To use MIBI or not to use MIBI? That is the question when assessing tumour cells. *Eur J Nucl Med Mol Imaging,* ***32(7)****: 836-42*.
4. Prager G, Czerny C, Ofluoglu S, Kurtaran A, Passler C, Kaczirek K, *et al.* (2003) Impact of localization studies on feasibility of minimally invasive parathyroidectomy in an endemic goiter region. *J Am Coll Surg,* ***196(4)****: 541-8*.
5. Kunstman JW, Kirsch JD, Mahajan A, Udelsman R (2013) Parathyroid localization and implications for clinical management. *J Clin Endocrinol Metab,* ***98(3)****: 902-12*.
6. Rubello D and Mariani G (2007) Hand-held gamma probe or hand-held miniature gamma camera for minimally invasive parathyroidectomy: competition, evolution or synergy? *Eur J Nucl Med Mol Imaging,* ***34(2)****: 162-4*.
7. Paredes P, Vidal-Sicart S, Zanón G, Roé N, Rubí S, Lafuente S, *et al.* (2008) Radioguided occult lesion localisation in breast cancer using an intraoperative portable gamma camera: first results. *Eur J Nucl Med Mol Imaging,* 35***(2):*** *230-5*.

[Downloaded from ijrr.com on 2026-11-24]

[Downloaded from ijrr.com on 2026-11-24]