

The impact of spironolactone on the lung injury induced by concomitant trastuzumab and thoracic radiotherapy

G. Yavas^{1*}, C. Yavas¹, E. Celik², E. Sen³, O. Ata³, R.E. Afsar⁴

¹Department of Radiation Oncology, Selcuk University, Konya, Turkey

²Department of Pathology, Selcuk University, Konya, Turkey

³Department of Medical Oncology, Selcuk University, Konya, Turkey

⁴Department of Nephrology, Selcuk University, Konya, Turkey

ABSTRACT

► Original article

*Corresponding authors:

Dr. G. Yavas,

Fax: +90 332241 60 65

E-mail:

guler.aydinyavas@gmail.com

Revised: August 17

Accepted: October 17

Int. J. Radiat. Res., January 2019;
17(1): 87-95

DOI: 10.18869/acadpub.ijrr.17.1.87

Background: To evaluate impact of spironolactone (S) on pulmonary toxicity of concomitant use of thoracic radiotherapy (RT) and trastuzumab (T). **Materials and Methods:** Eighty rats were divided into eight groups: group (G) 1 was control group; G2, G3 and G4 were RT, S and T groups; G5, G6, G7 and G8 were RT+T, T+S, RT+S and RT+T+S groups respectively. Rats were sacrificed at 6 hour, 21 and 100 day after RT and lung samples were retrieved. **Results:** By 100th days of RT inflammation score, lung fibrosis score and TGF- expression were significantly different within study groups (p values were 0.002, 0.001 and 0.043 respectively). Inflammation score of G8 was significantly lower than inflammation scores of G2 and G5 (p values: G2-G8= 0.004, and G5-G8=0.022). Inflammation score of G2 was significantly higher than G7 (p=0.028). There were significant differences regarding to fibrosis scores between G2-G8 (p=0.015), G2-G7 (p=0.017) and G5-G8 (p=0.011). TGF-β expression was higher in both G2 and G5 when compared to G8 (p = 0.038). **Conclusion:** Our results suggested that S is an effective treatment option for improving radiation-induced pulmonary fibrosis. These findings should be clarified with further preclinical and clinical studies.

Keywords: Aldosterone, pulmonary fibrosis, radiotherapy, spironolactone, Trastuzumab.

INTRODUCTION

Radiation therapy (RT) plays an important role in the treatment of breast cancer. Radiation-induced lung injury (RILI) is a potentially life-threatening and dose-limiting side effect of breast irradiation and thus the risk should be minimized ⁽¹⁻³⁾. In addition, chemotherapy (CT), targeted therapy, and hormonal treatment used in conjunction with RT increase the risk of damage to normal tissue. Thus, reducing radiation-induced normal tissue damage is of critical importance in improving both tumor control and patient quality of life ⁽¹⁾.

RILI which is also named as “radiation pneumonopathy” is a continuous process and regarded as the result of an abnormal healing response. Subclinical early damage in pneumocytes type I progress to an acute interstitial inflammation at 6-12 weeks after the onset of RT and further to lung fibrosis after many months and years ^(1,4). Histopathologically, radiation pneumonopathy is characterized by the focal infiltration of inflammatory cells into the pulmonary interstitium, which is associated, right from the beginning, with the deposition of intercellular matrix material, leading finally to the destruction of the alveolar histo-

architecture. Clinically RILI is typically divided into two phases: pneumonitis and fibrosis. The fibrotic phase tends to manifest >3 months after treatment. Fibrosis is part of the wound-healing process. Therefore radiation fibrosis is a form of chronic lung damage that usually evolves over 4-24 months after irradiation (4).

HER-2/neu proto-oncogene is a poor prognostic factor and is amplified in 20–30% of patients with primary breast cancer. Trastuzumab, a monoclonal antibody directed against HER2, improves response, time to progression, and overall survival in both the metastatic and adjuvant settings in patients with HER2 positive breast cancer (5-7). Preclinical in vitro and in vivo studies have shown that the cascade of events through the HER2 receptor is involved in tumor radiosensitivity (8, 9), application of Trastuzumab concurrently with radiation thus increases the antitumor effect of radiation. There are some clinical evidences in the literature that Trastuzumab also radiosensibilizes human healthy tissues and in this way it could increase the toxicity of the treatment (10). A few study evaluated the side effects of Trastuzumab and RT combination and the results are contradictory (11-13). Trastuzumab-induced pneumonitis may present as rapidly progressive pulmonary infiltrate respiratory failure after the administration of 1 dose of Trastuzumab or after 6 weeks of therapy. The incidence of Trastuzumab-induced pneumonitis is 0.4–0.6% (14). Although infrequent; pulmonary toxicity due to Trastuzumab may be life-threatening (15, 16).

Mineralocorticoid receptor (MR) activation is a contributing factor in the pathophysiology of a wide range of diseases (17). Aldosterone, which is a physiological activator of MR, is partially responsible for increases in the extracellular matrix turnover, as observed in fibrosis of the cardiac, kidney and lung tissues (18, 19), and exerts its effects primarily on lung epithelium. Elevated levels of aldosterone are known to induce hypertension, alter inflammation and fibrosis and exacerbate cardiovascular diseases (20, 21). Spironolactone, an aldosterone receptor antagonist, may have the ability to ameliorate pulmonary fibrosis (22-24).

By the light of these findings we hypothesized that Spironolactone would be effective in the treatment of both RT and Trastuzumab-induced lung injury by correcting pulmonary fibrosis. In the present study we aimed to evaluate whether the use of Spironolactone would be able to ameliorate the pulmonary toxicity induced by concomitant Trastuzumab and RT. Our second aim was to investigate the impact of Spironolactone on either RILI or Trastuzumab-induced lung injury when these two agents used separately.

MATERIALS AND METHODS

Study Design

This study included 80 female Wistar-Albino rats (250-300 g); the use of which was approved by the Necmettin Erbakan University Ethical Committee. Animals were housed 4 per cage in a controlled animal holding room with a 12/12-hour light/dark cycle; temperature and relative humidity were continually monitored to provide standard laboratory conditions. Rats were divided into 8 groups (G) composed of 10 animals. Group (G) 1 was defined as control group. G2, G3 and G4 were RT, Spironolactone and Trastuzumab groups respectively. G5, G6, G7 and G8 were RT + Trastuzumab, Trastuzumab + Spironolactone, RT + Spironolactone and RT + Trastuzumab + Spironolactone groups respectively (Table 1). RT was applied under general anesthesia with intraperitoneally administered 90 mg/kg ketamine hydrochloride and 10 mg/kg xylazine. A single dose of 15 Gy was applied to the both lungs. Trastuzumab (6 mg/kg) was administered intraperitoneally and Spironolactone (80 mg/kg) was administered by oral gavage. Rats were sacrificed via cervical dislocation at 6th hour, 21st day and 100th day after RT and the lung samples were taken for microscopical examination.

Radiotherapy protocol

RT was applied under general anesthesia with intraperitoneally administered 90 mg/kg ketamine hydrochloride (Ketalar®, EWL

Eczacıbaşı Warner Lambert İlaç Sanayi ve Ticaret A.Ş., İstanbul, Turkey) and 10 mg/kg xylazine (Rompun® 2%, Bayer Kimya San. Ltd. Sti., İstanbul, Turkey). A single dose of 15 Gy was applied to the both lungs via a single anterior field to 2 cm depth with SAD (source-axis distance) technique. One cm elasto-gel bolus was used to build up the radiation dose on the lungs and to provide contour regularity. The field size was 4x4 cm and included the both lungs.

Table 1. Study groups

Group (G)	
G1	Sham-irradiated control group
G2	Radiotherapy control group
G3	Spironolactone control group
G4	Trastuzumab control group
G5	Radiotherapy+Trastuzumab group
G6	Spironolactone+Trastuzumab group
G7	Radiotherapy+Spironolactone group
G8	Radiotherapy+Trastuzumab+Spironolactone group

Trastuzumab protocol

Trastuzumab (Herceptin ®; Genentech Inc, South San Francisco, CA, USA) dose which was equivalent to 6 mg/kg adult dose was calculated for each rat and injected i.p. 2 h before the RT. The rats in G4, G6 and G8 were applied 0.5 cc 0.9% NaCl i.p.

Spironolactone protocol

Spironolactone (Aldakton-A®, Ali Raif İlaç San. A.Ş., İstanbul, Turkey) dose which was equivalent to 80 mg/kg adult dose was calculated for each rat and was administered by oral gavage. Spironolactone administration was started a week before RT and continued until the animals sacrificed.

Histopathologic evaluation

Rats were sacrificed via cervical dislocation at 6th hour, 21st day and 100th day after RT and the lung samples were taken for microscopical examination. The bilateral whole lungs of each rat were excised and fixed in 10% neutral buffered formalin. Two lobes of each lung for each rat were processed and embedded in

paraffin for light microscopic examination. The 4 µ thick sections obtained with microtome were stained with hematoxylin and eosin (H&E) to evaluate the inflammation, and with histochemical Masson Trichrome staining to identify the fibrosis in the lung. Extend of the chronic inflammatory cells including lymphocytes on alveolar walls was graded on a scale of 0 (normal) to 3 (severe). Fibrosis was defined as the thickened alveolar walls with superimposed collagen. As a quantitative end point, extend of the radiation induced fibrosis was graded on a scale of 0 (normal lung or minimal fibrous thickening) to 3 (severe fibrosis -total fibrous obliteration of the field). The pathologist was not aware of the treatment groups at the time of the histological examination of the specimens. After examining the whole sections for each rat, the average value of fibrosis and chronic inflammation per rat was taken as the fibrosis and inflammation scores and mean values of each group were calculated.

Immunohistochemistry staining and scoring procedure

Paraffin-embedded tissues of chosen slides were collected and 4 µm thick sections were prepared for immunohistochemistry. The sections were deparaffinized at 37 °C oven overnight. Immunohistochemical staining was performed by using an automatic staining machine (Ventana, Benchmark XT). The sections were boiled at sodium citrate buffer at 95 °C for 60 min and then incubated with primary antibody Anti TGF-β rabbit polyclonal antibody (ABCAM, ab92486, Cambridge, UK) at a dilution of 1:100 for 52 minutes. The sections were incubated with the secondary antibody for 20 min at room temperature, incubated with Ultra I -view detection kit and counterstained with hematoxylin for 8 min.

The immunohistochemical TGF-β stained slides were evaluated and scored by a single pathologist blinded to patients' data. On light microscopic evaluation of each 4 µm thick section, 10 different fields magnified 100X were reviewed. Immuno-reactivity scoring system (IRS) which was previously described by Wang

et al (25) was used to determine TGF- β expression levels. This system depends on multiplication of staining intensity and TGF- β positive alveolar cell percentage. The percentage of positive cells was scored as: 0, negative; 1, 1-25%; 2, 26-50%; 3, 51-75%; 4, 76-100% and the staining intensity as 0 (-), 1 (+), 2 (++), 3 (+++).

Statistical analysis

The Statistical Package for Social Sciences (SPSS) v. 15.0 was used for statistical analyses. As the pathological scores were ordinal in nature, the differences in pathological findings between the study groups were analyzed using the Kruskal- Wallis test. When an overall statistically significant difference was observed, pairwise comparisons were performed using the Mann-Whitney U test. Bonferroni correction was used for multiple comparisons. A 5 % type I error level was used for the statistical significance cutoff for overall comparisons.

RESULTS

At 6th hour of RT; inflammation, pulmonary fibrosis and TGF- β scores were not significantly different within the study groups (p values were 0.091, 0.082 and 0.154 respectively). The samples taken from RT groups (G2, G5, G7 and G8) had minimal inflammation; however we did not observe any fibrosis or TGF- β expression

even in RT groups.

By 21st day of RT; the inflammation and fibrosis score were significantly different within the study groups (p values were 0.038 and 0.038 respectively); however we could not observe any significant difference with respect to TGF- β expression (p=0.072). Both the inflammation and fibrosis scores higher in RT groups (G2, G5, G7 and G8) than the control groups (G1, G3, G4 and G6); however there weren't any significant differences between RT groups with respect to the inflammation and fibrosis scores.

By 100th days of RT the inflammation score (table 2), lung fibrosis score (table 3) and TGF- expression (table 4) were significantly different within the study groups (p values were 0.002, 0.001 and 0.043 respectively). Pair-wise comparisons revealed that the inflammation score of the G8 was significantly lower than the inflammation scores of G2, G5 and (p values were: G2-G8= 0.004, and G5-G8=0.022). Additionally the inflammation score of G2 was significantly higher than that of G7 (p=0.028). When the fibrosis and scores were compared at 100th day of RT; there were significant differences between G2-G8 (p=0.015), G2-G7 (p=0.017) and G5-G8 (p=0.011). Moreover the TGF- β expression was higher in both G2 and G5 when compared to G8 (p values were 0.038 for both).

Figure 1 shows the histochemical Masson Trichrome staining of the lung samples from each group by 100th day of RT.

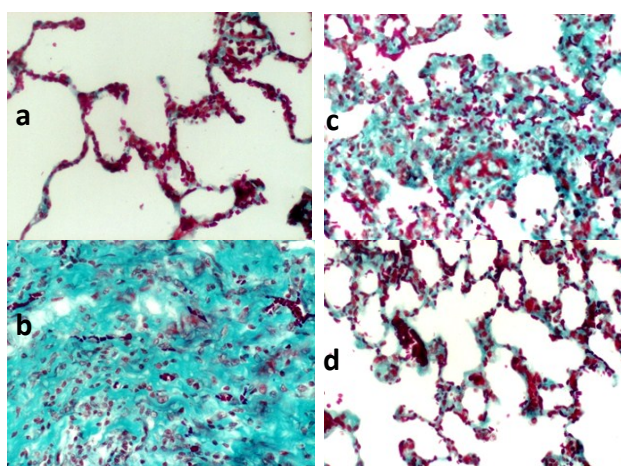


Figure 1. Histochemical Masson Trichrome staining (200X): Section from the lungs of the rats from a) Control group; b) RT+Trastuzumab group; c) RT only group; d) RT+Trastuzumab+Spironolactone group in 100th day of RT. **(a)** Control group: Normal alveolar structures with thin alveolar walls. **(b)** RT+ Trastuzumab group: There were thickening in the alveolar walls with severe fibrosis and partial lung obliteration. **(c)** RT only group: There were thickening in the alveolar walls with severe fibrosis. **(d)** RT+Trastuzumab+Spironolactone group: There were thickening in the alveolar walls with mild fibrosis

Table 2. Inflammation scores of the samples taken from lung tissue 100 days after radiotherapy.

Group (G)	Mean	Median	Minimum	Maximum	P
G1	0.67	1	0	1	0.002
G2	2.25	2	2	3	
G3	0.33	0	0	1	
G4	1.50	1.50	1	2	
G5	2.75	3	2	3	
G6	1.25	1	1	2	
G7	1.25	1	1	2	
G8	1.25	1	1	2	

Table 3. Fibrosis scores of the samples taken from lung tissue 100 days after radiotherapy

Group (G)	Mean	Median	Minimum	Maximum	P
G1	0	0	0	0	0.001
G2	2.50	2.50	2	3	
G3	0.33	0	0	1	
G4	1.50	1.50	1	2	
G5	3	3	3	3	
G6	1.25	1	1	2	
G7	1.50	1.50	1	2	
G8	0.75	1	0	1	

Table 4. TGF-β expression levels in the lung tissues 100 days after radiotherapy.

Group (G)	Mean	Median	Minimum	Maximum	P
G1	0	0	0	0	0.043
G2	3	3	3	3	
G3	0.67	1	0	1	
G4	1.50	1.50	1	2	
G5	3	3	3	3	
G6	1.50	1.50	1	2	
G7	1.50	1.50	1	2	
G8	2	2	2	2	

TGF-beta; Transforming growth factor beta.

DISCUSSION

In this study, we investigated the effect of MR antagonism, via a potent MR antagonist, Spironolactone, on the use of concomitant RT and Trastuzumab in a rat model. Our results suggested that long-term use Spironolactone improved both radiation-induced and RT + Trastuzumab induced lung toxicity. Although we observed a trend for higher scores of both inflammation and fibrosis scores in 100th days for G4 (Trastuzumab only group) than G6 (Trastuzumab+Spironolactone group), the difference was not statistically significant. Therefore Trastuzumab did not cause pulmonary fibrosis when used alone and did not deteriorate RILI. The main reason for the pulmonary fibrosis is RT. This is the first study in the literature demonstrating that MR blockade ameliorates the radiation-induced late fibrosis in lung tissues of the rats.

In a preclinical study Barut and colleagues

investigated the effect of Spironolactone aldosterone on lung injury induced by intestinal ischemia and reperfusion ⁽¹⁷⁾. Their results suggested that Spironolactone pretreatment decreased neutrophil infiltration, nitric oxide synthase induction, oxidative stress, and histopathological injury. Similarly, Atalay *et al.* demonstrated that Spironolactone is an effective form of treatment for acute lung injury ⁽²¹⁾. Ji *et al.* demonstrated the therapeutical potential of Spironolactone, which significantly reduces the pulmonary inflammatory response induced by bleomycin ⁽²⁶⁾. Spironolactone-treated lungs exhibited fewer macrophage, lymphocyte, neutrophil and eosinophils in alveoli compared with the untreated lungs. Lieber *et al.* demonstrated that Spironolactone treatment attenuates acute pulmonary inflammation induced by both bleomycin and lipopolysaccharide ⁽²⁷⁾. In various animal models, it was shown that Spironolactone can function as an antioxidant factor and protect

organs from oxidative damage by enhancing antioxidative defense systems while suppressing production of free radicals (27). However in the current study we found that Spironolactone could not attenuate Trastuzumab-induced pulmonary toxicity.

RILI is the reaction of the organ lung to radiation effects in various target cells. It starts as an exudative inflammation, with the clinical picture of interstitial pneumonia 6-12 weeks after irradiation, and proceeds to a productive chronic inflammation lasting several months and terminating, as other chronic inflammations do, in scar formation, called lung fibrosis. Numerous cytokines such as TNF- α , interleukin-1, platelet-derived growth factor, fibroblast growth factor, and TGF- β have been reported to be increased within the irradiated tissue (1,4). TGF- β levels are increased as early as 6 h after irradiation and remain elevated fibrotic lesions as long as 20 years (29,30). In the current study we sacrificed animals at 6th hour, 21st day and 100th day after RT in order to observe both pneumonitis and fibrosis phases. We found that Spironolactone was effective treatment modality for amelioration of RILI only during fibrotic phase since we observed the improvement only by 100th day.

The alveolar epithelium consists of type I and type II epithelial cells. Type I cells cover approximately 90% of the alveolar surface and type II cells are the precursors of type I cells. In steady state, the turnover time of the alveolar epithelium is approximately 4-5 weeks. However after toxic injury, type I epithelial cells are denuded and the proliferation of type II cells is stimulated up to 10-fold (31). Stimulation of type II cells promotes the secretion of growth factors and proteases and degradation of the extracellular matrix to allow removal of dead cells by normal processes (4). Pulmonary irradiation also reduces microvessel density and lung perfusion and promotes hypoxia (32). All of these injuries stimulate the recruitment of a variety of inflammatory cells to the site of the injury and it leads to establishment of chronic inflammation and fibrosis. In this phase vascular damage and collagen deposition become apparent. Vascular injury and activation

of coagulation cascade, cellular adhesion molecules, proinflammatory and profibrotic cytokines and oxidative stress seem to play a vital role in the development of radiation fibrosis (33). Aldosterone is related to extracellular matrix turnover increase, which is associated with cardiac, and possibly lung fibrosis (18,19). Lung cells have aldosterone receptors, and under physiological conditions, aldosterone participates in active sodium transport across the alveolar-capillary membrane (23, 34). It has been shown that Aldosterone aids in maintaining the fluid-free lumen of the lung (35), and is present at high concentrations in pulmonary fibrosis (24). Aldosterone thus promotes interstitial fibrosis, possibly through local dehydration. Spironolactone administration has been shown to reduce pulmonary fibrosis (35,36), as well as pulmonary congestion and edema (37), by correcting the gas diffusion capacity (38) and renal mineral status. (39). In parallel to these findings in the current study we also demonstrated that Spironolactone ameliorated the RILI.

There are both preclinical and clinical evidences showing Trastuzumab radiosensibilizes human healthy tissues and in this way it could increase the toxicity of the treatment (9,10,40). The potential synergetic effect of Trastuzumab and RT may also increase radiation morbidity when combined in the adjuvant setting. Therefore, administration of concomitant Trastuzumab and RT as be a concern. The cardiotoxic effect of Trastuzumab especially when used with antracyclin chemotherapy has been well known, though the mechanism is not yet fully understood (6). However there is limited date with respect to the late toxicity of Trastuzumab administration with RT. In a preclinical study Bese and colleagues demonstrated that, addition of Trastuzumab to thoracic irradiation either sequentially or concomitantly did not increase radiation-induced pulmonary fibrosis in rats (41). Similarly, in the present study we found that the use of concomitant Trastuzumab with thoracic RT did not further increase RILI.

The irradiation doses used in routine clinical

practice are different from the ones used in animal studies. Most patients in routine practice are treated with conventional fractionation to a total dose of 50–70 Gy. However, in recent years, stereotactic radiosurgery and intraoperative RT that use single or two to five fractions of high-dose irradiation have become popular. It has been postulated that the linear-quadratic model is an appropriate methodology for determining isoeffective doses at large dose per fraction (42). The 15 Gy single dose of RT in our study corresponds to 48–64 Gy, the most frequent dose range used in clinical practice, when α/β ratio of 2–4 is used.

High quality randomized trials have demonstrated that adjuvant Trastuzumab concomitant with or following chemotherapy in node-positive and high-risk node-negative patients with HER-2 positive early stage breast cancer improves disease free and overall survival (5, 6, 43, 44). In routine clinical practice Trastuzumab is usually given once every week or every 3 weeks intravenously. However in experimental studies conducted on rats, a single dose of Trastuzumab is usually preferred because of easy application (41, 45, 46). Accordingly, in this experimental study, a single dose of Trastuzumab, which was equivalent to 6 mg/kg adult dose was calculated for each rat and injected intraperitoneally.

Our study has some limitations that should be mentioned as well. First of all, we could not demonstrate any difference between the RT-groups with respect to the inflammation and fibrosis scores; and TGF- β expression before 100th day of RT. Although the inflammation score of RT+Trastuzumab group was higher than of RT + Trastuzumab + Spironolactone group at 21st day, this difference was not at statistically significant level. In the current study we used only light microscopy. If we used electron microscopy in addition to light microscopy we might have demonstrated some differences at ultrastructural levels at 21st day. We think that electron microscopy may further enlighten the possible interaction of RT and Spironolactone in this regard. Secondly, this study is an experimental study; therefore our results should be clarified with clinical studies.

Int. J. Radiat. Res., Vol. 17 No. 1, January 2019

In conclusion, our results suggested that the use of concomitant Trastuzumab with thoracic RT did not further deteriorate radiation-induced pulmonary injury. On the other hand, Spironolactone ameliorated the radiation-induced pulmonary fibrosis. Therefore Spironolactone is an effective treatment option for improving radiation-induced pulmonary fibrosis with long-term usage. These findings should be clarified with further preclinical and clinical studies.

Conflict of Interest

The authors declare that they have no conflict of interest.

Funding source

This work was supported by Selcuk University. There is no role of study sponsors in the study design, in the collection, analysis and interpretation of data; in the writing of the manuscript and in the decision to submit the manuscript for publication.

Conflicts of interest: Declared none.

REFERENCES

1. Graves PR, Siddiqui F, Anscher MS, Movsas B (2010) Radiation pulmonary toxicity: from mechanisms to management. *Semin Radiat Oncol*, **20**: 201–207.
2. Kocak Z, Evans ES, Zhou SM (2005) Challenges in defining radiation pneumonitis in patients with lung cancer. *Int J Radiat Oncol Biol Phys*, **62**: 635–638.
3. van der Veen SJ, Faber H, Ghobadi G et al. (2016) Decreasing irradiated rat lung volume changes dose-limiting toxicity from early to late effects. *Int J Radiat Oncol Biol Phys*, **94(1)**: 163–71.
4. Trott KR, Herrmann T, Kasper M (2004) Target cells in radiation pneumopathy. *Int J Radiat Oncol Biol Phys*, **58(2)**: 463–469.
5. Romond EH, Perez EA, Bryant J et al. (2005) Trastuzumab plus adjuvant chemotherapy for operable HER2-positive breast cancer. *N Engl J Med*, **353**: 1673–1684.
6. Piccart-Gebhart MJ, Procter M, Leyland-Jones B, Goldhirsch A, Untch M, Smith I et al. (2005) Trastuzumab after adjuvant chemotherapy in HER2-positive breast cancer. *N Engl J Med*, **353**: 1659–1672.
7. Slamon DJ, Leyland-Jones B, Shak S et al. (2001) Use of chemotherapy plus a monoclonal antibody against HER2 for metastatic breast cancer that overexpresses HER2. *N*

- Engl J Med*, **344**: 783–792.
8. Marinko T, Dolenc J, Bilban-Jakopin C (2014) Cardiotoxicity of concomitant radiotherapy and trastuzumab for early breast cancer. *Radiol Oncol*, **48(2)**: 105-112.
 9. Pietras RJ, Poen JC, Gallardo D, Wongvipat PN, Lee HJ, Slamon DJ (1999) Monoclonal antibody to HER-2/neu receptor modulates repair of radiation-induced DNA damage and enhances radiosensitivity of human breast cancer cells overexpressing this oncogene. *Cancer Res*, **59**: 1347–1355.
 10. Law AB, Evans T, Hayward RL et al. (2009) Possible radiation sensitisation by trastuzumab leading to radiation-induced myelitis. *Breast Care (Basel)*, **4**: 40–42.
 11. Belkacémi Y, Gligorov J, Ozsahin M, et al. (2008) Concurrent trastuzumab with adjuvant radiotherapy in HER2-positive breast cancer patients: acute toxicity analyses from the French multicentric study. *Ann Oncol*, **19**: 1110–6.
 12. Raben A, Sammons S, Hanlon A, et al. (2006) Comparison of acute breast and chest wall toxicity in women treated with external beam radiation with and without concurrent herceptin in a community cancer center. *Int J Radiat Oncol Biol Phys*, **66(Suppl. 1)**: S541–2. 11.
 13. Bellon JR, Gover MT, Burstein HJ, Harris JR, Harris LN (2005) Concurrent Trastuzumab and radiation therapy in the adjuvant treatment of breast cancer. *Int J Radiat Oncol Biol Phys*, **63(Suppl. 1)**: S55–6.
 14. Vahid B and Marik P (2008) Pulmonary complications of novel antineoplastic agents for solid tumors. *Chest*, **133**: 528–538.
 15. Bettini AC, Tondini C, Poletti P, Caremoli ER, Guerra U, Labianca R (2008) A case of interstitial pneumonitis associated with Guillain-Barré syndrome during administration of adjuvant trastuzumab. *Tumori*, **94**: 737.
 16. Pepels MJ, Boomars KA, van Kimmenade R, Hupperets PS (2009) Life-threatening interstitial lung disease associated with trastuzumab: case report. *Breast Cancer Res Treat*, **113**: 609.
 17. Barut F, Ozacmak VH, Turan I, Sayan-Ozacmak H, Aktunc E (2016) Reduction of acute lung injury by administration of spironolactone after intestinal ischemia and reperfusion in rats. *Clin Invest Med*, **39(1)**: E15-24.
 18. Zannad F, Alla F, Dousset B, Perez A, Pitt B (2000) Limitation of excessive extracellular matrix turnover may contribute to survival benefit of spironolactone therapy in patients with congestive heart failure: insights from the randomized aldactone evaluation study (RALES). Rales Investigators. *Circulation*, **102**: 2700-6.
 19. MacFadyen RJ, Barr CS, Struthers AD (1997) Aldosterone blockade reduces vascular collagen turnover, improves heart rate variability and reduces early morning rise in heart rate in heart failure patients. *Cardiovasc Res*, **35**: 30-4.
 20. Frieler RA, Ray JJ, Meng H, et al. (2012) Myeloid mineralocorticoid receptor during experimental ischemic stroke: effects of model and sex. *J Am Heart Assoc*, **1**: e002584.
 21. Atalay C, Dogan N, Aykan S, Gundogdu C, Keles MS (2010) The efficacy of spironolactone in the treatment of acute respiratory distress syndrome-induced rats. *Singapore Med J*, **51**: 501-5.
 22. Broillet MC, Berger A, Horisberger JD (1993) Early effects of aldosterone on the basolateral potassium conductance of A6 cells. *Pflugers Arch*, **424**: 91-3.
 23. Hirasawa G, Sasano H, Takahashi K, et al. (1997) Colocalization of 11b-hydroxysteroid dehydrogenase type II and mineralocorticoid receptor in human epithelia. *J Clin Endocrinol Metab*, **82**: 3859-63.
 24. Zhao M, Zhao M, Fang Q (1998) Spironolactone ameliorates rat pulmonary fibrosis induced by bleomycin A5. *Zhonghua Jie He He Hu Xi Za Zhi* **21**: 300-2. In Chinese.
 25. Wang W, Qiu J, Liu Z, Zeng Y, Fan J, Liu Y, Guo Y (2013) Overexpression of RING box protein-1 (RBX1) associated with poor prognosis of non-muscle-invasive bladder transitional cell carcinoma. *J Surg Oncol*, **107**: 758-61.
 26. Ji WJ, Ma YQ, Zhou X, et al. (2013) Spironolactone attenuates bleomycin-induced pulmonary injury partially via modulating mononuclear phagocyte phenotype switching in circulating and alveolar compartments. *PLoS One*, **19**: e81090.
 27. Lieber GB, Fernandez X, Mingo GG, et al. (2013) Mineralocorticoid receptor antagonists attenuate pulmonary inflammation and bleomycin-evoked fibrosis in rodent models. *Eur J Pharmacol*, **718**: 290-8.
 28. Yuan J, Jia R, Bao Y (2007) Beneficial effects of spironolactone on glomerular injury in streptozotocin-induced diabetic rats. *J Renin Angiotensin Aldosterone Syst*, **8**: 118-26.
 29. Dent P, Yacoub A, Contessa J, et al. (2003) Stress and radiation-induced activation of multiple intracellular signaling pathways. *Radiat Res*, **159**: 283–300.
 30. Martin M, Lefaix J, Delanian S (2000) TGF-beta 1 and radiation fibrosis: a master switch and a specific therapeutic target? *Int J Radiat Oncol Biol Phys*, **47**: 277-290.
 31. Kasper M and Haroske G (1996) Alterations in the alveolar epithelium after injury leading to pulmonary fibrosis. *Histol Histopathol*, **11**: 463–483.
 32. Fleckenstein K, Zgonjanin L, Chen L, et al. (2007) Temporal onset of hypoxia and oxidative stress after pulmonary irradiation. *Int J Radiat Oncol Biol Phys*, **68**: 196-204.
 33. Chen Y, Williams J, Ding I, et al. (2002) Radiation pneumonitis and early circulatory cytokine markers. *Semin Radiat Oncol*, **12**: 26-33.
 34. Fischer H and Clauss W (1990) Regulation of Na channels in frog lung epithelium: a target tissue for aldosterone action. *Pflugers Arch*, **416**: 62-7.
 35. Suzuki S, Tsubochi H, Suzuki T, et al. (2001) Modulation of transalveolar fluid absorption by endogenous aldosterone in adult rats. *Exp Lung Res*, **27**: 143-55.
 36. Tsukashita M, Marui A, Nishina T, et al. (2008) Spironolactone alleviates late cardiac remodeling after left ventricular restoration surgery. *J Thorac Cardiovasc Surg*, **136**: 58-64.
 37. Nishi I, Kawano S, Misaki M, et al. (2006) Addition of spironolactone to an angiotensin-converting enzyme inhibitor decreases lung congestion and edema in Dahl hypertensive rats. *Heart Vessels* **21**:251-5.
 38. Agostoni P, Magini A, Andreini D, et al. (2005) Spirinolac-

- tone improves lung diffusion in chronic heart failure. *Eur Heart J*, **26**: 159-64.
39. Olivera WG, Ciccolella DE, Barquin N, et al. (2000) Aldosterone regulates Na,K-ATPase and increases lung edema clearance in rats. *Am J Respir Crit Care Med*, **161**: 567-73.
40. Horton JK, Halle J, Ferraro M, et al. (2010) Radiosensitization of chemotherapy-refractory, locally advanced or locally recurrent breast cancer with trastuzumab: a phase II trial. *Int J Radiat Oncol Biol Phys*, **76(4)**: 998-1004.
41. Bese NS, Umay C, Serdengecti S, et al. (2010) The impact of trastuzumab on radiation-induced pulmonary fibrosis: results of an experimental study. *Med Oncol*, **27(4)**: 1415-9.
42. Brenner DJ (2008) The linear quadratic model is an appropriate methodology for determining isoeffective doses at large doses per fraction. *Semin Radiat Oncol*, **8**: 234-239.
43. Smith I, Procter M, Gelber RD, et al. (2007) 2-year follow-up of trastuzumab after adjuvant chemotherapy in HER2-positive breast cancer: a randomised controlled trial, **369**: 29-36.
44. Joensuu H, Kellokumpu-Lehtinen PL, Bono P, et al. (2006) Adjuvant docetaxel or vinorelbine with or without trastuzumab for breast cancer. *N Engl J Med*, **354**: 809-820.
45. Yavas G, Yildiz F, Guler S, et al. (2011) Concomitant Trastuzumab with thoracic radiotherapy: a morphological and functional study. *Ann Oncol*, **22(5)**:1120-6.
46. Yavas G, Gultekin M, Yildiz O, et al. (2017) Assessment of concomitant versus sequential trastuzumab on radiation-induced cardiovascular toxicity. *Human and Experimental Toxicology*. **36(11)**:1121-1130.

