

Smad 2/3 and CD8+ distribution pattern in liver of mice vaccinated with gamma radiation-attenuated *Schistosoma mansoni* larvae

E.N. Hafez* and M.M. Amin

Department of Health Radiation Research, National Centre for Radiation Research and Technology (NCRRT),
Egyptian Atomic Energy Authority, Cairo, Egypt

ABSTRACT

Background: Gamma radiation-attenuated vaccine has a very promising value in controlling schistosomiasis. The objective of this study is to investigate the effects of vaccination with gamma radiation-attenuated schistosomules regarding histopathological and immunohistochemical changes in mice model of human *Schistosoma mansoni* infection. **Materials and Methods:** The study is conducted upon 40 mice, divided into four groups of 10 each: uninfected control group A (normal control), *Schistosoma mansoni* infected group B (infected control), Group C subcutaneously injected with 200 Gy gamma radiation-attenuated schistosomules (vaccine control) and group D injected with the same dose of gamma radiation-attenuated schistosomules then challenged after 4 weeks by *S. mansoni* cercariae (vaccinated-challenged). Parts of liver tissues stained with Masson's trichrome (MT) stain for classifying the granulomas into cellular, fibrocellular or fibrous according to the amount of collagens; stained bluish green. Immunohistochemistry assay was then done on the other portion through expression of Smad2/3 protein and CD8+ in the extracellular matrix (ECM). **Results:** Compared to control infected group, mild histopathological changes with decrease of egg granulomas mainly cellular is detected in vaccinated-challenged group. This is accompanied with moderate immunohistochemical expression of Smad2/3 and CD8+ proteins in vaccine-control group and mild expression in vaccinated-challenged group. **Conclusion:** The results indicate that vaccination with 200 Gy gamma-irradiated schistosomules could reduce histopathological and immunohistochemical changes induced due to infection which represents an effective strategy in disease control.

Keywords: *Schistosoma mansoni*, vaccination, immunohistochemistry, histochemistry.

► Original article

***Corresponding authors:**

Eman Naser Hafez, PhD.,

E-mail:

eman_naser612@hotmail.com

Revised: October 2018

Accepted: March 2019

Int. J. Radiat. Res., October 2019;
17(4): 579-586

DOI: 10.18869/acadpub.ijrr.17.3.579

INTRODUCTION

Protective vaccination against schistosomiasis intended for reducing the pathology and controlling reinfection is the most effective means of control besides etiological therapy. However; complexity of *Schistosoma* interaction with the host's immune system turns the vaccine development to be a difficult task (1-3).

It is reported that Cercariae and

schistosomula attenuated with irradiation elicit high immunity against the disease. Although schistosomules protect themselves from the host immune system by confining antigenic molecules in surface membrane, they are considered to be a target of the immune system in the radiation-attenuated vaccine model and trigger an inflammatory reaction inhibiting their migration (4). Also, irradiation modifies expression of antigens released from or exposed at the surface causing functional impairment

although no biochemical or morphological changes has been demonstrated⁽⁵⁾.

As a result of hepatocytes infection, the release of extra cellular matrix (ECM) produced by myofibroblasts impedes the flow of solutes to the hepatocytes which lose their microvilli thereby stopping the liver functioning effectively⁽⁶⁾.

Smad2/3 pathways promote collagen synthesis in activated hepatic stellate cells (HSCs). SMAD3 is pro-fibrotic. Its deletion inhibits type I collagen expression by epithelial myofibroblasts. Whereas, SMAD2 is protective and its disruption up regulates type I collagen expression. Stimulation of the receptors on hepatic stellate cells occurs through Smad1/5 and Smad2/3 phosphorylation. Also, the production of connective tissue growth factor (CTGF) is closely related to the IL-13/ Smad pathway⁽⁷⁻⁹⁾.

Involvement of CD8⁺T cells is being increasingly appreciated in several immunopathological events during helminthic infection including schistosomiasis. They recognize the antigenic peptide in target cells and hence induce apoptosis or kill them by direct contact. Also their activity increases in chronic cases. As it reduces the growth of egg granuloma and formation new one through modulating granulomatous immunopathology associated with eggs trapped in host tissue. Several studies suggested that they play a certain role in resisting infection as they release IFN- γ that promote development of protective immunity⁽¹⁰⁻¹²⁾.

The aim of this study is to detect the effect of vaccination with gamma radiation-attenuated schistosomules in experimental schistosomiasis mansoni regarding hepatic histopathological changes as well as Smad2/3 and CD8⁺ expression.

MATERIALS AND METHODS

Attenuation of the parasite

Schistosoma mansoni schistosomulae are obtained from *Schistosoma* by the Biological

Supply Program (SBSP) at Theodor Bilharz Research Institute, Imbaba - Giza, Egypt through the perfusion technique from Hamster's lung 14 days post-infection with 4000 cercariae using citrated saline. They have been attenuated by irradiation at the (NCRRT) Cairo, Egypt using Indian Cobalt-60 gamma chamber 4000 A Irradiator. Then they were exposed to 200 Gy of gamma radiation at 2.5 Krad/h at the time of experimentation. Viability of cercariae is confirmed by microscopy^(13, 14).

Animal treatment

Forty male Swiss albino mice of six week-old weighing 18-20 g are, at the beginning of the study, randomly divided into four groups (ten each) including a normal control group (Group A) infected control group, (Group B) infected by subcutaneous (S. C.) injection with 100 *S. mansoni* cercariae/mouse, vaccine-control (Group C) vaccinated by (S.C.) injection with 500 schistosomules irradiated with 200 Gy gamma radiation and (Group D) vaccinated with the same dose of gamma radiation-attenuated schistosomules then challenged after 4 weeks by S.C. injection with 100 *S. mansoni* cercariae. All animals have been kept at 20-25°C in a 12-h light and 12-h dark cycle, maintained under specific pathogen-free conditions, with free access to standard laboratory water and chow according to the ethics committee of the National Research Center. They were euthanized under anesthesia. Liver tissues were then obtained and divided into two parts for histopathological and immunohistochemical study.

Histological examination

Liver tissues have been preserved in 10% buffered formalin then processed into paraffin blocks, serially cut into 4 μ m thickness and stained Masson's trichrome (MT) stain in order to classify the granulomas as cellular, fibrocellular or fibrous according to the amount of collagens, stained bluish green, represented in the granulomas⁽¹⁵⁾.

Immunohistochemistry

Hydrogen peroxide 0.3% in methanol for 15

minute was used to block endogenous peroxidase activity. Liver tissues were incubated overnight in goat polyclonal anti-phosphorylated SMAD2/3 antibody (sc-11769, Santa Cruz Biotechnology) after washing in phosphate-buffered saline (PBS). Primary antibodies were diluted at 1:100 in Tris-buffered saline and 0.05% albumin then tissues washed in PBS and incubated with biotin-streptavidin-peroxidase. The reaction was revealed by a mixture of 3,3'-diaminobenzidine with hydrogen peroxide. For CD8 staining, tissues were incubated with rabbit monoclonal antimouse antibodies against CD8+ cells (Abcam) followed by incubation with biotinylated goat antipolyvalent secondary antibody. Conjugation with streptavidin peroxidase enzyme then enzyme substrate chromogen solution was applied. Counter staining was performed using Mayers hematoxylin. Immunopositivity was detected as brown membranous or membrano cytoplasmic staining. The intensity was evaluated and classified as weak, mild, moderate and strong where stained cell were counted from 10 randomly chosen high power fields^(16,17).

Statistical analysis

Results were subjected to Student's *t*-test using SPSS program version 8 to determine the significance. Data are expressed as mean \pm standard error and values with $P < 0.05$, $P < 0.01$ and $P < 0.001$ are significant, highly significant and very highly significant respectively.

RESULTS

Mean \pm SE of granuloma number was 14.2 \pm 3.2 in the control infected (Group B). In vaccine-control (Group C), it was 7.5 \pm 2.1 while in vaccinated-challenged (Group D) it was 5.2 \pm 0.9 showing high significant difference with control infected group B ($P < 0.001$). Regarding collagen content in the control infected group B, it was 40.8 \pm 5.9. On comparing with the vaccine-control (Group C) and vaccinated-challenged (Group D), they show high significant

difference (18.2 \pm 3.1) and (10.5 \pm 2.1) with $P < 0.001$ (table 1, figure1).

Data in table 2 and figure 2 show that Smad2/3 in hepatocytes of normal control (Group A) was 106.5 \pm 10.6 while infected control (Group B) revealed strong deposition of it in portal tract and hepatic sinusoids (923.3 \pm 37.1) with statistically significant increase ($P < 0.001$) compared to normal control group. The expression showed moderate deposition in vaccine-control (Group C) (402.5 \pm 17.2). On the other hand, vaccinated-challenged (Group D) showed weak expression of (190.3 \pm 12.9) with high significant decrease compared to (Group B) infected control group.

Expression of CD8⁺, in normal control (Group A) was 135.1 \pm 12.8, dense deposition was recorded (663.6 \pm 43.8) with significant difference ($P < 0.001$) in (Group B) infected control group. In vaccine-control group (Group C), the positive traces were reduced (490.2 \pm 17.1) compared to (Group B). Vaccinated-challenged group (Group D) showed weak deposition of collagen (181 \pm 14.1).

Hepatopathological and immunohistochemical observations

Figure 3 represents the histopathological changes in the experimental groups. Normal control group (Group A) showed normal hepatocyte morphology where the central vein is surrounded by hepatocytes arranged in strands and separated by blood sinusoids (a). (Group B) showed dense mass of collagen fibers surrounding the egg granulomas, and spread to the space around them, or extended to neighboring lobules. (Group C) vaccine-control group showed fewer fibrocellular granulomas while vaccinated group (Group D) showed reduction in granuloma number and size with few collagen depositions.

Figure 4 shows Smad 2/3 expression in the different groups, minimal expression of Smad 2/3 in liver tissue of mice in normal control group (Group A) while infected control (Group B) showed strong positive expression. In vaccine-control mice of (Group C), the hepatic tissue exhibited moderate positive expression of Smad. Hepatocytes reacted in a weak pattern and

showed mild expression of Smad in (Group D) vaccinated-challenged.

Regarding expression of CD8⁺ (figure 5), there is no or minimal expression in control normal group (Group A) while mice of control

infected group (Group B) showed high expression. Vaccine control (Group C) showed moderate expression and there is weak expression of CD8 in vaccinated-challenge (Group D).

Table 1. Criteria of granulomatous lesions and associated histopathological changes.

Group	Granuloma Number	Collagen content	Type of infiltration	
			Cellular	Fibro Cellular
B	14.2 ± 3.2	40.8 ± 5.9	40%	60%
C	7.5 ± 2.1 **	18.2 ± 3.1 **	55%	45%
D	5.2 ± 0.9 **	10.5 ± 2.1 **	70%	30%

Table 2. Effect of vaccination with 200 Gy gamma-attenuated schistosomules on hepatic expression of Smad 2/3 and CD8 in mice of experimental groups.

Parameters	Group A Normal control	Group B Infected control	Group C Vaccine control	Group D Vaccinated challenge
Smad 2/3	106.5 ± 10.6	923.3 ± 37.1 +++	402.5 ± 17.2 +++**	190.3 ± 12.9 +****
CD8 ⁺	135.1 ± 12.8	663.6 ± 43.8 +++	490.2 ± 17.1 +****	181 ± 14.1 +****

Data are expressed as mean ± SE. number of mice in each group is ten. P values +++ < 0.001; ++ < 0.01; + < 0.5 compared to control normal group. P values *** < 0.001; ** < 0.01; * < 0.5 compared to control infected group.

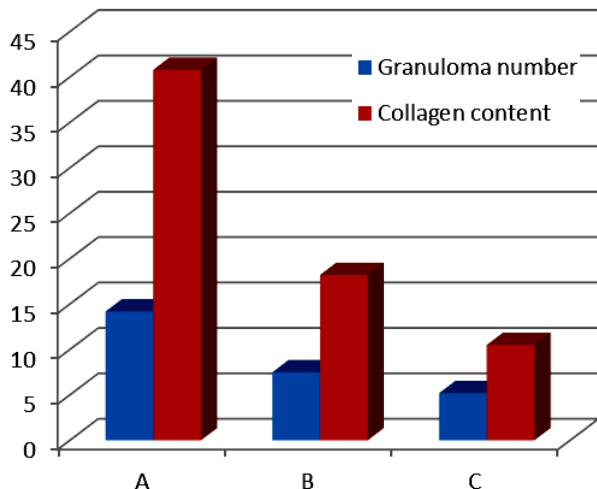


Figure 1. Granuloma number and collagen content in experimental groups.

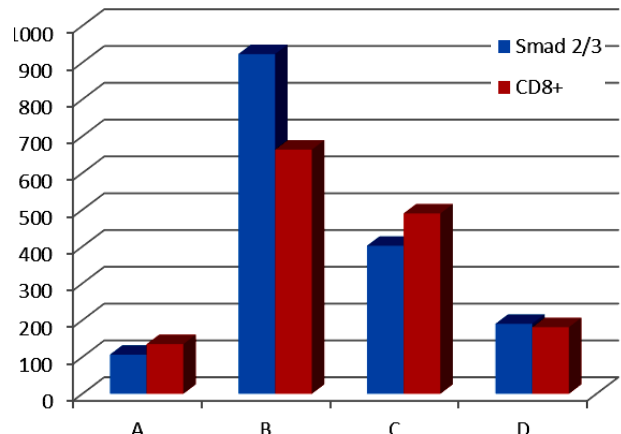


Figure 2. Expression of Smad 2/3 and CD8⁺ in experimental groups.

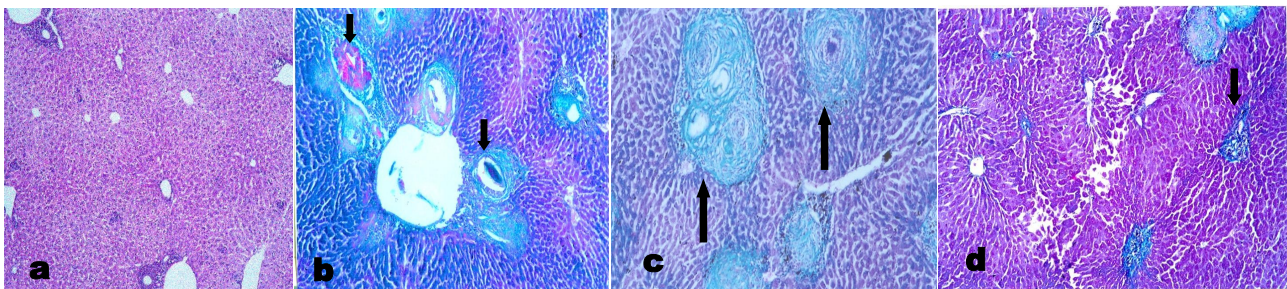


Figure 3. Liver section of mice group A stained with Masson's trichrome showing normal hepatocyte with central vein and Portal area. Pathological observations of infected control group B mice showing multiple cellular and fibrocellular granulomas with increased collagen deposition around the egg (→). The analysis shows that liver section of group C (vaccine control) has few small granulomas with less inflammatory cellular infiltrate while section of group D (vaccinated-challenged) showing reduced collagen contents with less inflammatory cellular infiltrate (→) (Magnification = 200x for a-d).

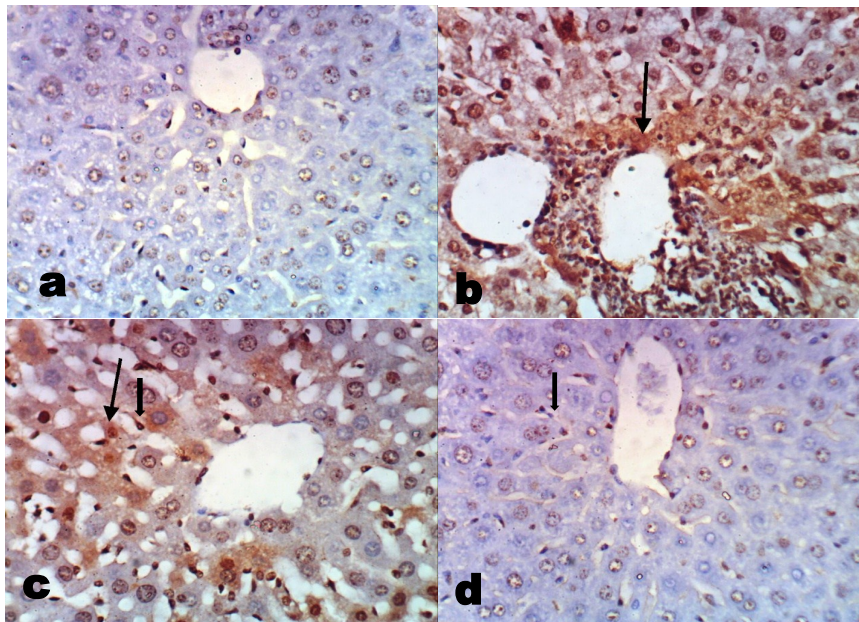


Figure 4. Expression of Smad 2/3 in liver of mice. There is no staining in normal group A, strong positive staining in control infected group b (→). Liver of mice from group C show moderate expression and weak staining in vaccinated-challenged group d (Magnification X 400 for a-d).

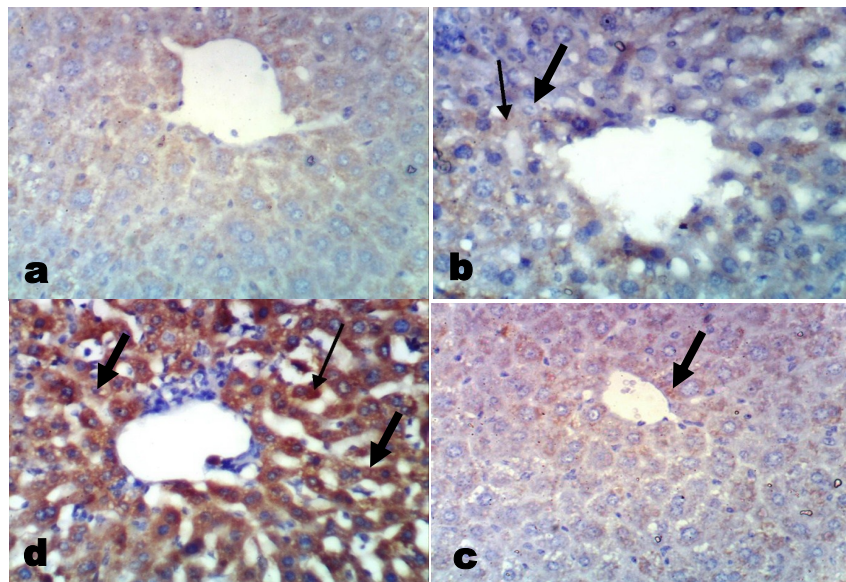


Figure 5. Immunohistochemical staining of CD8+ in liver of mice from group A showing no or minimal expression. Strong positive expression was shown in control infected group B (immunopositivity indicated by brown color) (→). Staining of CD8+ in liver of mice from group C showed moderate positive expression while group D showing weak positive expression (Magnification X 400 for a-d).

DISCUSSION

Anti-*schistosome* vaccines for use with animals have long been advocated as part of the solution to schistosomiasis control, benefitting both humans and animals and improve the local economy. Such features align with the One

Int. J. Radiat. Res., Vol. 17 No. 4, October 2019

Health Concept synergizing human and animal health ⁽¹⁸⁾. Application of live radiation-attenuated *Schistosome* larvae has received much attention and offers great promise for vaccine development. Several studies demonstrated that the optimal protection in the radiation attenuated (RA)

vaccine model is dependent on the induction of both type-1 and type-2- associated immune responses⁽¹⁹⁻²¹⁾.

The study shows severe histopathological alterations of the liver parenchyma with marked inflammatory reactions and large fibrous granulomas around the ovum in control infected group. Previous studies revealed typical hepatic lesion with extensive fibrosis around egg granuloma in chronic human *S. mansoni* pipestem. It was speculated that it may be important for attracting lymphocytes, collagen formation and blocking toxic effects of antigens released from eggs⁽²²⁻²⁴⁾.

Vaccinated-challenged group revealed fewer granulomas which are mainly cellular with decrease in collagen content. Vaccination with 200 and 250 Gy gamma radiation-attenuated schistosomules showed significant decrease in size and number of granuloma and their collagen content with increase in the local concentration of inflammatory cells which may be related to proliferation and /or increased migration of immunologically active cells into granulomas⁽²³⁾. Increasing the number of vaccinations boosts protection whereas in absence of re-stimulation the high level of protection is not sustained⁽²⁵⁾. Several investigators exhibited high levels of protection against a challenge as immunization results in alleviated liver pathology in pigs immunized by 400 μ w UV-irradiated *S. japonicum* cercariae compared with those without pre-vaccination⁽²⁶⁾. It was reported that persistence of immunizing larvae of *S. mansoni* is an important factor in induction of resistance in mice⁽²⁷⁾.

Smads are important in regulating TGF- β / Smad signaling pathway in schistosomiasis and expression of connective tissue growth factor is tightly linked to this pathway⁽²⁸⁾. In the same context, it was detected that the protein expression levels of p-Smad1, p-Smad2 and p-Smad2/3 which appear to be key elements in the signal transduction pathways responsible for fibrosis were markedly increased in infected group⁽²⁹⁾.

The current work revealed minimal expression of Smad 2/3 in normal control group meanwhile infected control group showed

densely-stained cells with marked expression of it surrounded and infiltrated in the portal areas and hepatic sinusoids. Similarly, low expression level of Smad2/3 in livers of the normal mice and significantly high expression in the cytoplasm and nucleus of cells around granulomas had been detected by Zhang *et al.*⁽³⁰⁾. A high expression of pSmad2/3 compared to the normal group was detected in both acute and chronic phases of liver injury compared to the normal group. This was speculated that *Schistosoma* eggs release soluble egg antigen (SEA) which stimulates hepatic stellate cells to switch on Smad1/2 phosphorylation, leading to liver fibrosis^(9,31). Studies of Majumdar *et al.*⁽³²⁾ showed that vaccination with soluble *leishmanial* antigen stimulated dendritic cells so restricted the parasites-induced phosphorylation of SMAD and regulated TGF- β in T regulatory cells.

Vaccine control group showed moderate expression of Smad2/3 while vaccinated-challenged group showed minimal expression of it. This was in accordance with Amin *et al.* who studied immunohistochemical changes in mice vaccinated with 200 Gy gamma irradiated schistosomules regarding expression of α -SMA, desmin, collagen type-1 and TGF- β 1 and reported moderate expression in vaccine-control group and few expressions were detected in vaccinated-challenged group. Increasing the number of vaccinations boosts protection while in the absence of re-stimulation; the high level of protection is not sustained⁽³³⁾.

Minimal expression of CD8⁺ T in normal control group and marked expression was detected in control infected group. Similar alterations were previously observed by different studies. Such studies revealed that CD8⁺ T cells are implicated in several immunopathological events during helminthic infection including acute and chronic schistosomiasis⁽³⁴⁻³⁶⁾.

The moderate expression of CD8⁺ in vaccine-control group is coincided with previous studies reported that SEA is also able to stimulate an antigen-specific cytotoxic CD8⁺ T-cell response in mice after immunization. While,

mild expression in vaccinated-challenged group in this study conforms to previous investigators who proved that immunization of mice with antigens from different stages of *Schistosoma mansoni* decreases the expression of CD²⁺. Also, it was reported that vaccination with tetraspanin-2 did increase a slight expression of Th1 cells, Th2 cells, CD8⁺ T cells. However, this increase was not statistically significant. (37-39).

CONCLUSION

It is hereby concluded that acute schistosomiasis produce inflammatory effects which lead to severe histopathological changes and marked expression of Smad 2/3 and CD8⁺. Meanwhile, the protective effect of gamma radiation-attenuated vaccine resulted in immunological responses against challenged dose and subsequently maintains the normal histopathological and immunohistochemical characteristics of hepatic tissue.

ACKNOWLEDGEMENTS

The authors wish to acknowledge the assistance given by the National Center of Radiation Research and Technology, which provided all facilities for this study.

Funding

This research did not receive any specific grant from funding agencies, public, commercial or not-for-profit organizations.

Conflicts of interest: Declared none.

REFERENCES

- Bergquist RM, Donald M (2017) Schistosomiasis vaccine development: The missing link. In *Schistosoma* Biology, Pathology, Control; Jamieson, BGM., Ed.; CRC Press: Boca Raton, FL, USA, 462–478.
- Merrifield M, Hotez PJ, Beaumier CM, Gillespie P, Strych U, Hayward T, Bottazzi ME (2016) Advancing a vaccine to prevent human schistosomiasis. *Vaccine*, **34**: 2988–2991.
- El-Ossily AAN, Yones DA, Monib MM, Hassanin SA, Khalifa RMA (2016) SDS-PAGE Protein Pattern and Antigenicity Cross Reaction of Human *Schistosomes*. *American J Infect Dis*, **12**: 20-29 .
- El Ridi R, Mohamed SH, Tallima, H (2003) "Incubation of *Schistosoma mansoni* lung-stage schistosomula in corn oil exposes their surface membrane antigenic specificities. *J Parasitol*, **89**: 1064–1067.
- Tran MH, Peatson MS, Bethony JM, Smyth DJ, Jones MK, Duke Don TA, Mcmanus DP, Correa-Oliveira R, Loukas A (2006) Tetraspanins on surface of *S. mansoni* are protective antigens against schistosomiasis. *Nat Med*, **12**: 835-40.
- Friedman SL (2008) Mechanisms of hepatic fibrogenesis. *Gastroenterol*, **134**: 1655-69.
- Baghy K, Iozzo RV, Kovalszky I (2012) Decorin-TGFβ axis in hepatic fibrosis and cirrhosis. *J Histochem Cytochem*, **60**: 262-268.
- Yoshida K, Matsuzaki K. Differential Regulation of TGF-β/Smad Signaling in Hepatic Stellate Cells between Acute and Chronic Liver Injuries. (2012) *Front Physiol*, **3**:53-60.
- Liu Y, Meyer C, Müller A, Herweck F, Li Q, Mullenbach R, Mertens PR, Dooly S, Weng HL (2011) IL-13 induces connective tissue growth factor in rat hepatic stellate cells via TGF-β-independent Smad signaling. *J Immuno*, **187**: 2814–2823.
- Williams DL, Asahi H, Botkin DJ, Stadelcker MJ (2001) *Schistosoma* infection stimulates host CD4⁺ T helper cell and B-cell responses against a novel egg antigen, thioredoxin peroxidase. *Infect Immun*, **69**: 1134–1141.
- Lin C, Donghui Z, Wenyue Z, Yuxiao Z, Min H, Bingya Y, Zhipeng X, Minjun J, Guanling W (2017) Absence of *Batf3* results in reduced liver pathology in mice infected with *Schistosoma japonicum*. *Pkarsit vector*, **10**: 306-314.
- Zhang M, Gao Y, Du X, Zhang D, Ji M (2011) Toll-like receptor (TLR) 2 and TLR4 deficiencies exert differential in vivo effects against *Schistosoma japonicum*. *Parasite Immunol*, **33**: 199–209.
- Mangold BL and Knopf PK (1978) The effect of assay conditions on the recovery of schistosomula from the lungs of normal and resistant rats infected with *S. mansoni*. *J Parasito*, **64**: 813-821.
- El Gawish MAM, Moawad MAF, Mahmoud NFA (1999) The immune response of rats inoculated with irradiated cysts of *Toxoplasma gondii*. *Egypt J Med Sci*, **20**: 1-8.
- Suvik A and Effendy AWM (2012) The Use OF Modified Masson's Trichrome Staining in Collagen Evaluation in Wound Healing Study. *Malaysian J Veter Rese*, **3**: 2 39-47.
- Matsuo SE, Fiore AP, Siguematu SM, Ebina KN, Friguglietti CUM, Ferro MC, Kulcsar MA, Kimura ET (2010) Expression of SMAD proteins, TGF-beta/activin signaling mediators, in human thyroid tissues. *Arq Bras Endocrinol Metab*, **54**: 406-12.
- Nashaat EN, Wafaa ME, Nadia SE, Salwa AS, Shima AS (2015) *Schistosoma mansoni* infection or soluble egg anti-

- gen immunization can reduce allergic airway diseases. *Menoufia Med J*, **28**: 642-649.
18. Hong Y, Pengfei C, Biniam M, Yuesheng L, Donald P (2018) *Schistosoma* Vaccines for Domestic Animals. *Trop Med Infect Dis*, **3**: 68 -80.
 19. Vasou A, Sultanoglu N, Goodbourn S, Randall RE, Kostrikis LG (2017) Targeting pattern recognition Receptors (PRR) for vaccine Adjuvantation: From Synthetic PRR Agonists to the potential of defective Interfering Particles of Viruses. *Viruses*, **9**: 186-203.
 20. Kebebe B, Sori T, Kumssa B (2016) Review on current status of vaccines against parasitic diseases of animals. *J Vet Sci Techno*, **7**: 327-334.
 21. Fonseca Ct, Carvalho GBF, Alves CC, De Melo TT (2012) *Schistosoma* Tegument Proteins in Vaccine and Diagnosis Development. *J Parasitol Res*, Article ID 541268,
 22. Chen BL, Peng J, Li FQ, Yang M, Wang Y, Chen W (2013) Exogenous bone morphogenetic protein-7 reduces hepatic fibrosis in *Schistosoma japonicum*-infected mice via transforming growth factor- β /Smad signaling. *World J Gastroenterol*, **19**: 1405-1415.
 23. Hafez EN, Gaffar SAM, El-Ahl SAS, Moawad MA (2009) Assessment of vaccination with schistosomes attenuated by using different doses of γ - radiation on experimental schistosomiasis mansoni. Thesis submitted for partial fulfillment of M.D. degree in parasitology. Faculty of medicine for girls Al-Azhar University.
 24. Yu XQ, Chen PW, Xu JZ, Xiao SH (2008) Hepatic fibrosis in schistosomiasis: egg granulomas secrete fibroblast-stimulating factor in vitro. *World J Gastroenterol*, **14**: 2905-11.
 25. Kariuki TM, Farah IO, Yole DS, Mwenda JM, Van Dam GJ, Deelder AM, Wilson RA, Coulson PS (2004) Parameters of the Attenuated *Schistosoma* Vaccine Evaluated in the Olive Baboon. *Infect Immun*, **72**: 5526-5529.
 26. Tian F, Lin D, Wu J, Gao Y, Zhang D, Ji M, Wu G (2010) Immune Events Associated with High Level Protection against *Schistosoma japonicum* Infection in Pigs Immunized with UV-Attenuated Cercariae. *Plos One*; **5**: e13408
 27. Bickle QD, Bogh HO, Johansen MV, Zhang Y (2001) Comparison of the vaccine efficacy of gamma-irradiated *Schistosoma japonicum* cercariae with the defined antigen Sj62 (IrV-5) in pigs. *Vet Parasitol*, **100**: 51-62.
 28. Weng HL, Ciucan L, Liu Y, Hamzavi J, Godoy P, Gaitantzi H, Kanzler S, Heuchel R, Ueberham U, Gebhardt R, Bretkopf K, Dooley S (2007) Profibrogenic transforming growth factor-beta/activin receptor-like kinase 5 signaling via connective tissue growth factor expression in hepatocytes. *Hepatology*, **46**(4):1257-70.
 29. Medeiros AI, Sa-Nunes A, Soares EG, Peres CM, Silva CL, Faccioli LH (2004) Blockade of endogenous leukotrienes exacerbates pulmonary histoplasmosis. *Infect Immun*, **72**:1637-1644.
 30. Zhang BB, Cai WM, Tao J, Zheng M, Liu RH (2013) Expression of Smad proteins in the process of liver fibrosis in mice infected with *Schistosoma japonicum*. *Zhongguo Ji Sheng Chong Xue Yu Ji Sheng Chong Bing Za Zhi*; **31**:89-94.
 31. Wang Y, Yang F, Xue J, Zhou X, Luo L, Ma Q, Chen Y, Zhang J, Zhang SL, Zhao L (2017) Antischistosomiasis Liver Fibrosis Effects of Chlorogenic Acid through IL-13/miR-21/Smad7 Signaling Interactions *In Vivo and In Vitro*. *Antimicrob Agents Chemother*, **61**(2): 01347-16.
 32. Majumder S, Bhattacharjee A, Chowdhury BP, Majumdar SB, Majumdar S (2014) Antigen-pulsed CpG-ODN-activated dendritic cells induce host-protective immune response by regulating the T regulatory cell functioning in *Leishmania donovani*-infected mice: critical role of CXCL10. *Frontiers in Immunol*, **5**(261): 100-108.
 33. Amin MM, Hafez EN, Marei ES (2015) Immunohistochemical Studies in Mice Liver Immunized by Attenuated *Schistosoma Mansoni* Schistosomes by Gamma Radiation. *Egy J Hospt Medi*, **61**: 406-414.
 34. Silveira-Lemos D, Costa-Silva MF, Oliveira Silveira AC, Batista MA, Oliveira-Fraga LA, Silveira AMS, Alvarez MCB, Martins-Filho OA, Gazzinelli G, Rodrigo Corrêa-Oliveira R, Teixeira-Carvalho A (2013) Cytokine Pattern of T Lymphocytes in Acute Schistosomiasis mansoni Patients following Treated Praziquantel Therapy, *J Parasitol Res*, (2013): 909134-909147.
 35. Oliveira-Prado R, Caldas IR, Teixeira-Carvalho A, Andrade MV, Gazzinelli A, Correa-Oliveira R, Cunha-Melo JR (2009) "CD4⁺ and CD8⁺ distribution profile in individuals infected by *Schistosoma mansoni*," *Scandinavian J Immunol*, **69**: 521-528.
 36. Yatim N, Cullen S, Albert ML (2017) Dying cells actively regulates adaptive immune responses. *Nat Rev Immunol*, **17**: 262-275.
 37. Pancre V, Delacre M, Herno J, Aurialt C (1999) Schistosomal egg antigen-responsive CD8 T-cell population in *Schistosoma mansoni*-infected BALB/c mice. *Immunol*, **98**: 525-534.
 38. Gabera MH, Maghraby SA, Ahmed BM.; Ruppeld A, Bahgata MM (2010) Immune Responses in Mice after Immunization with Antigens from Different Stages of the Parasite *Schistosoma mansoni*. *Naturforsch*, **65**: 289 - 30.
 39. Chen L, Chen Y, Zhang D, Houm M, Yang B, Zhang F, Zhang W, LUO X, Ji M, Wu G (2016) Protection and immunological study on two tetraspanin-derived vaccine candidates against schistosomiasis japonicum. *Parasite Immunol*, **38**: 589-598.