Volume 18, No 1 | International Journal of Radiation Research, January 2020

PTX3 levels in murine pulmonary parenchymal tissues are correlated with radiation-induced injuries

B. Sarper[1*#], M.K. Ozbilgin[2#], E. Gumustepe[3], S. Gencur[2], G.Z. Karaman[2], P. Kilicaslan[2], C. Kurtman[3]

[1]*Department of Radiation Oncology, Kocaeli University Faculty of Medicine, Kocaeli, Turkey*
[2]*Department of Histology and Embryology, Celal Bayar University Medical School, Manisa, Turkey*
[3]*Department of Radiation Oncology, Ankara University Medical Faculty, Ankara, Turkey*

► ***Original article***

Corresponding authors:
Dr. Binnaz Sarper,
Fax: *+ 90 262 303 7003*
E-mail:
sarperbinnaz@gmail.com

Revised: May 2019
Accepted: June 2019

Int. J. Radiat. Res., January 2020; 18(1): 109-115

DOI: 10.18869/acadpub.ijrr.18.1.109

[#]These authors contributed equally

ABSTRACT

Background: Pentraxins (PTX) play key roles in innate immunity and inflammatory responses. An increase in PTX3 levels may be a marker of early radiation injury in the lung. Thus, we aimed to determine the effect of radiation on PTX3 expression in a lung injury mouse model. ***Materials and Methods:*** Twenty-four 6–8-week-old mice were divided into 4 groups, one control (group 1) and three experimental groups (groups 2–4) irradiated with 6 MV photons and 5 Gy in a single fraction. Groups 2, 3, and 4 were sedated and euthanized 24, 72, and 168 h after radiation, respectively. The right lung middle lobe was then removed for histochemical examination and immunostaining for PTX3 expression, which was evaluated semi-quantitatively using H-SCORE analysis. Kolmogorov-Smirnov and Kruskal Wallis one-way analysis of variance were used for statistical analysis. ***Results*:** Immunohistochemistry of lung tissue samples showed different PTX3 expression levels across the four groups. Group 1 showed weak staining (232.50 ± 9.501), while group 2 (301.50 ± 7.472) and group 3 (283.50 ± 7.090) showed strong immunoreactivity. Group 4 showed moderate PTX3 immunoreactivity (271.50 ± 10.013). Moreover, H-score values between control and early radiation groups were statistically significant (group 1 vs. group 2, $p < 0.001$; group 1 vs. group 3, $p = 0.002$). ***Conclusion*:** PTX3 levels may be an early marker for long-term radiation effects. Our study provides insights into the pathological processes of pulmonary inflammation and acute radiation injury, and may provide novel therapeutic strategies for controlling pulmonary inflammation without eliciting radiation injury.

Keywords: *Radiation, lung injury, pentraxin-3, murine, innate immune system.*

INTRODUCTION

Lung cancer (LC) is the second most common type of cancer in men and women and the most common cause of solid tumor-related death worldwide [(1)]. Approximately 70% of LC patients are diagnosed with locally advanced or metastatic disease, which is beyond the scope of surgical excision [(2)]. Radiation therapy is an important treatment modality not only for lung cancer but also for multiple thoracic malignancies. Pulmonary complications after thoracic irradiation due to primary or metastatic malignancies adversely affect the quality of life and survival of patients. Radiation-induced lung injury can manifest as acute radiation pneumonitis and/or delayed effects that lead to pulmonary fibrosis [(3)].

Furthermore, in the event of a radiation accident or attack, advanced clinical countermeasures are needed for screening and medical management of the exposed population. In such scenarios, biomarkers that can accurately quantify radiation exposure would be useful for triage management by first responders [(4)]. Therefore, detection of radiation-induced lung injury at an early stage is necessary for successful therapy and improved survival rates and quality of life. Additionally, the

[Downloaded from ijrr.com on 2026-11-24]

[DOI: 10.18869/acadpub.ijrr.18.1.109]

elucidation of radiation injury mechanisms will also guide the development of "radiation mitigators." Radiation mitigators are studied in order to prevent early and late side effects in patients exposed to radiation due to accident or attack [5].

Cytokines are small proteins secreted by cells and are known to play important roles in mediating radiation toxicity, which was first reported by Rubin *et al.* [6]. In a murine study, Sproull *et al.* [7] evaluated the efficacy of a novel combination of radiation responsive proteins—Fms-like tyrosine kinase 3 (Flt3) ligand (FL), serum amyloid A (SAA), matrix metalloproteinase 9 (MMP9), fibrinogen beta (FGB), and pentraxin-3 (PTX3)—in predicting the received dose after whole or partial body irradiation. The role of these inflammatory molecules in tissue response to irradiation has also been associated with an abscopal effect through adaptive immune responses [8].

Pentraxins (PTX) are a family of cytokines that play an important role in the innate immune system. There are two subgroups of PTX, long and short; PTX3 is an example of long PTX, while C reactive protein belongs to the short PTX subgroup [9]. The human and mouse PTX3 homologs are 82% identical [10,11] and the PTX3 mature protein is 40 kDa in size [12]. PTX3 is produced by many cell types after various stimuli and plays a key role in innate immunity and inflammatory responses [13-15]. This cytokine also interacts with several ligands, including those of growth factors, extracellular matrix components, and select pathogens, playing a role in complement activation and facilitating pathogen recognition by phagocytes, thereby acting as an antibody predecessor. PTX3 has also been implicated in wound healing/tissue remodeling, fertility, cardiovascular diseases, and infectious diseases [16]. In lungs, acute lung injury activates the innate immune system and PTX3 levels increase rapidly within 24 hours. It has been suggested that a high level of PTX3 activates the local innate immune system, which protects lung tissue against the injury to which it has been exposed [17].

Therefore, we focused on PTX3 in our current study as we aimed to determine the effect of radiation on PTX3 expression in a lung injury mouse model. We investigated the time-dependent changes in PTX3 expression levels and examined its correlation with other pathological changes in mouse lung tissue following irradiation. This is the first study to examine tissue changes in radiation-induced lung parenchyma and PTX3 levels in these tissues. We hope that our study can aid the development of new radiation mitigators.

MATERIALS AND METHODS

Animal experiments

A total of 24 healthy, 6–8-week-old, male, adult Swiss Albino mice weighing 25–35 g were obtained from the Ankara University Experimental Animal Laboratory (Ankara, Turkey). The mice were isolated from stress and noise, provided with water and food *ad libitum*, and housed at 25 °C under a 12 h/12 h dark/light cycle before being included in the study. Animals were maintained at the Ankara University Experimental Animal Laboratory and the study was approved by the Animal Tests Local Ethics Committee of Ankara University (approval number 2017-21-166; approval date: 10/18/2017). The mice were divided into four groups of six mice each. Group 1 was the control group, while mice in experimental groups 2–4 were exposed to total body irradiation (TBI) with 6 MV photons using a Varian linear accelerator device (Clinac DHX; Varian Medical Systems, Palo Alto CA) at the Department of Radiation Oncology of Ankara University School of Medicine with a source-to-axis distance of 100 cm, from anterior (250 cGy) and posterior (250 cGy) fields, and a total mid-axis dose of 500 cGy in a single fraction. All mice in the experimental group were sedated during irradiation via injection with 45–50 mg/kg intramuscular ketamine before TBI. The unexposed mice in group 1 were euthanized after ketamine injection, whereas exposed mice of groups 2, 3, and 4 were sedated with 45–50 mg/kg intramuscular ketamine 24, 72, and 168 h after TBI, respectively, and then euthanized. Euthanasia was performed via cardiac perfusion, after which the thoracic region was dissected and the right lung middle lobe completely removed. Lung tissue samples were then obtained and embedded in paraffin at 60 °C following routine protocols. First, all lung tissue samples were washed in a solution containing 10% formol and then placed in screw-cap sampling containers containing 10% formol, with separate boxes for each animal. Two sets of serial sections (5-µm thick) were cut and prepared; the first set was stained with

[Downloaded from ijrr.com on 2026-11-24]

[DOI: 10.18869/acadpub.ijrr.18.1.109]

hematoxylin and eosin (H&E) for histochemical examination while the second set was used for immunohistochemical staining as described below.

Immunohistochemistry

Formalin-fixed, paraffin-embedded lung sections were used for immunohistochemical staining. Tissue samples were stored at 60 °C overnight and then de-waxed with xylene for 30 min. After dehydration in ethanol, the sections were washed with distilled water. Subsequently, the samples were treated with 2% trypsin (ab970; Abcam, Cambridge, UK) at 37 °C for 15 min and incubated in 3% H_2O_2 solution for 15 min to inhibit endogenous peroxidase activity. Next, the sections were incubated with anti-PTX3 polyclonal antibody (1:100; sc-373951; Santa Cruz Biotechnology, Dallas, TX) for 18 h at 4 °C. The samples were then washed three times (5 min each) in PBS, followed by incubation with biotinylated IgG and administration of streptavidin peroxidase (Histostain Plus Kit; 87-9999; Zymed Laboratories, Waltham. MA). After washing away the excess secondary antibody with PBS (three times, 5 min each), the sections were stained with 3,3'-diaminobenzidine (DAB) Liquid Substrate System (ACK125; ScyTek Laboratories, West Logan, UT) to detect immunoreactivity and with Mayer's hematoxylin ((HMM999; ScyTek Laboratories) for counterstaining. Normal IgG in place of primary antibody was used as negative control. All samples were then covered with mounting medium (107961.0500; Merck Millipore, Burlington, MA) and observed under a light microscope (BX-40; Olympus, Tokyo, Japan).

Immunostaining of PTX3 in the lung samples was evaluated semi-quantitatively using H-SCORE analysis [18]. Immunostaining intensities were scored as follows, 0 (no staining), 1 (weak but detectable staining), 2 (moderate staining), and 3 (intense staining). An H-SCORE value was obtained for each specimen by calculating the sum of the percentage of lung cells stained at each intensity category multiplied by its respective score, using the formula $H\text{-}SCORE = \sum Pi\ (i+1)$, where i is the intensity score (with a value of 1, 2, or 3 corresponding to weak, moderate, or strong staining, respectively) and Pi is the percentage of stained cells for each intensity (varying from 0 to 100%). For each sample, five different fields were evaluated at a magnification of 200×. H-SCORE evaluation was performed independently by at least two investigators (KO, SG) blinded to the sample source and to each other's results; the average score obtained by both was then used.

Statistical analysis

All statistical analyses were performed using IBM SPSS version 20.0 for Windows (IBM Corp., Armonk, NY). Kolmogorov-Smirnov tests were used to test the normality of data distribution. Continuous variables are expressed as the mean ± standard deviation and median (25–75th percentiles), while categorical variables are expressed as counts (percentages). Comparisons of non-normally distributed continuous variables between the groups were performed using the Kruskal Wallis one-way analysis of variance and Dunn's post-hoc test. A two-sided p value < 0.05 was considered statistically significant.

RESULTS

Examination of the H&E-stained preparations of lung samples revealed that the lung lumen in group 1 (control) was covered with folded and transitional epithelium and that epithelial thickness consisted of five or six layers. The lamina propria under the epithelium consisted of irregularly distributed collagen fibers. Various blood vessels and additional fibroblasts, which are connective tissue cells, were observed within the lamina propria. Under the lamina propria, longitudinal muscle fibers were observed at the inner and outer layers, while circular fibers were seen in the middle. Lung tissue samples of the experimental groups (groups 2–4) also revealed transitional epithelium coverage and underlining lamina propria. However, in contrast to group 1, a slight edema was observed, which was more apparent in groups 2

[Downloaded from ijrr.com on 2026-11-24]

[DOI: 10.18869/acadpub.ijrr.18.1.109]

and 3 (figure 1).

Furthermore, we investigated acute changes in the lung tissue samples after radiation exposure. Histochemical H&E staining of the lung indicated that the alveolar epithelium was composed of two cell types, type I alveolar cells that were markedly squamous and type II alveolar secretory cells that were cuboidal in shape. We also observed that the lung interstitium between the capillaries and alveolar space was composed of minimal connective tissue matrix, fibroblasts, and inflammatory cells such as macrophages. The control group showed no obvious inflammatory changes. On the other hand, slight infiltration of inflammatory cells in the alveolae and alveolar septal edema were observed in the irradiated groups. Histologic scoring indicated that irradiation with a single fraction of 5 Gy resulted in radiation-induced injury on day 2 and 3.

Immunohistochemistry of the lung tissue samples for PTX3 showed different staining intensities in the lung parenchyma across the four groups. For each sample, an H-SCORE value was obtained by calculating the percentage of lung cells stained in each intensity category multiplied by their respective intensity score (figure 2). We observed very weak staining for group 1 (232.50±9.501; figure 1A and figure 2), whereas group 2 (301.50±7.472) and group 3 (283.50 ± 7.090) showed strong immunoreactivity when stained with the PTX3 antibody (figure 1B, C). Meanwhile, moderate PTX3 immunostaining was observed for group 4 (271,50±10,013; figure 1D). Moreover, H-SCORE values of the PTX3-positive cells between control and early radiation groups were statistically significant (group 1 vs. group 2, p¬4.445; group 5 vs. group 7, p>4.446), indicating that PTX3 expression in the lung is significantly correlated with early radiation exposure. In contrast, PTX3 immunostaining intensity was similar between control and group 4 (168 h after exposure; group 1 vs. group 4, p=0.159). Additionally, no significant differences were observed between the 24 h and 48 h groups (group 2 vs. group 3, p=0.256) or the 48 h and 168 h groups (group 3 vs. group 4, p=0.931). However, the staining intensity of PTX3-positive cells between the very early and late radiation groups was statistically significant (group 2 vs. group 4, p=0.003).

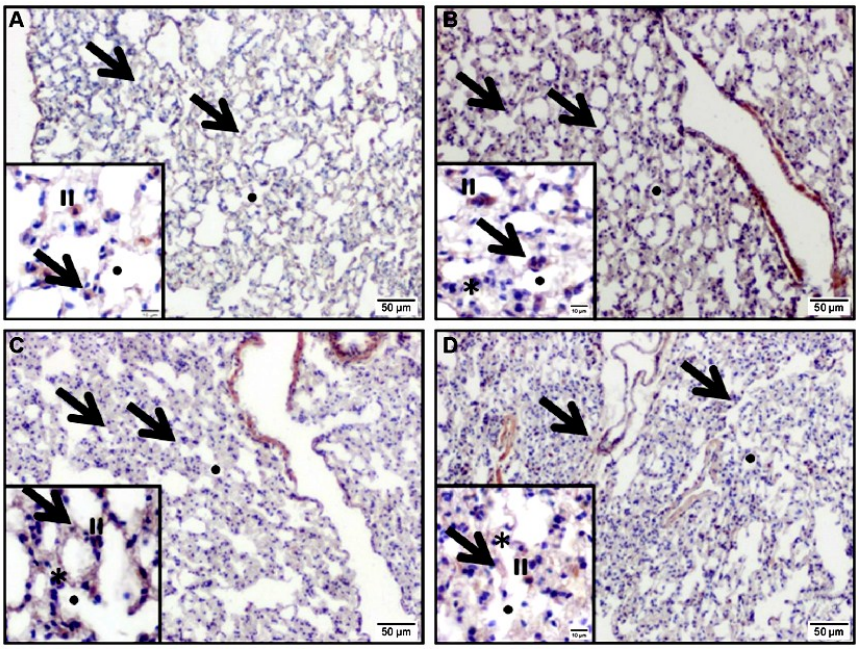

Figure 1. PTX3 expression in mouse lung tissue. **(A)** Weak PTX3 expression (indicated by arrows) in normal lung (control, group 1). **(B, C)** Increased PTX3 immunoreactivity in group **(B)** 2 and **(C)** 3 lungs compared with that of control. **(D)** Moderate PTX3 immunoreactivity was observed in group 4. **Insets:** alveolar space (•); II, type II alveolar epithelial cells; *, alveolar septum.

[Downloaded from ijrr.com on 2026-11-24]

[DOI: 10.18869/acadpub.ijrr.18.1.109]

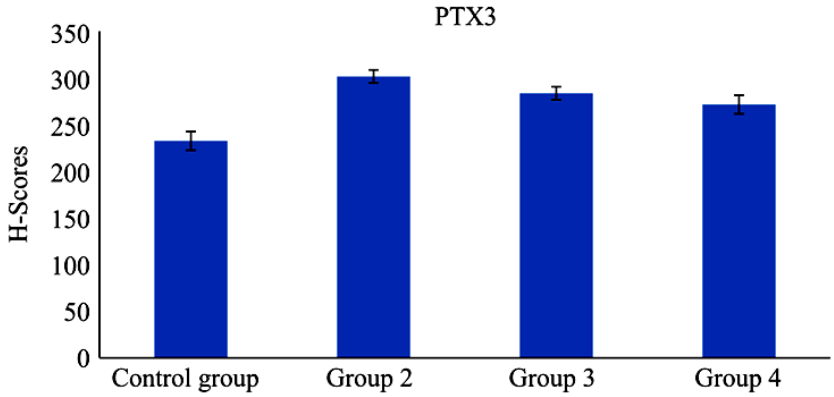

Figure 2. H-SCOREs of PTX3 staining intensity in lung tissue samples. Error bars represent the mean ± standard deviation.

DISCUSSION

PTX3 is important in the innate immune response as a soluble pattern-recognition receptor and in the acute inflammatory response as a potential mediator [12,16]. In the present study, we observed that PTX3 levels increase in mouse lung tissues during early radiation exposure with associated histological changes.

Previously, Chen *et al.* [19] reported that thorax irradiation of mice with 12 Gy resulted in massive infiltration of inflammatory cells in the alveoli and alveolar septal edema compared with that of control mice. Histologic scoring demonstrated that lungs irradiated with a single fraction of 12 Gy exhibited significant changes due to radiation-induced injury on day 2 and day 17. In our study, we observed slight edema on day 1 and day 2 and only mild inflammatory changes in the irradiated groups—this is likely because our applied radiation dose was much lower than that reported in the above study [19].

Moreover, He *et al.* [17] found that PTX3 protein levels in the bronchioalveolar lavage fluid increased in parallel with the severity of lung injury and were correlated with tissue factor (TF) activity. The expression and distribution of PTX3 and TF were further documented in detail 6 h after lipopolysaccharide (LPS; 5 mg/kg) administration. Treatment with anti-human TF monoclonal antibody dramatically attenuated LPS-induced lung injury, alveolar fibrin deposition, and inflammatory cell infiltration in "humanized" hTF-KI mice 6 h after LPS challenge. PTX3 expression significantly decreased after anti-coagulant therapy and the authors theorized that PTX3 may be utilized as a biomarker that reflects lung injury severity. Furthermore, the interplay between PTX3 and TF may potentially mediate lung injury.

Pauwels *et al.* [20] reported that cigarette smoking increases pulmonary PTX3 expression in an interleukin (IL)-1-dependent manner; however, they suggested that either PTX3 is not critical in cigarette smoking-induced pulmonary inflammation, emphysema, and body weight changes, or that its role can be fulfilled by other mediators with overlapping activities. Furthermore, Sproull *et al.* [7] reported elevated PTX3 levels in the plasma of TBI mice at 24 h post-irradiation at 1, 2, 4, and 8 Gy doses; this elevation was significant compared with that of control at every dose examined. Moreover, significantly elevated PTX3 levels were observed 48 h post-irradiation at 2, 4, and 8 Gy doses and at 1 week post-irradiation at 4 and 8 Gy doses. At 72 h post-irradiation, there was a significant decrease in PTX3 levels after the 1 Gy dose and a significant elevation in PTX3 levels at 2, 4, and 8 Gy doses. These observations indicate that PTX3 may be a suitable dose-dependent early marker for radiation-induced damage. In agreement, our study findings support the notion that serum PTX3 levels after irradiation may be a suitable marker for the determination of radiation damage.

In the present study, PTX3 expression was examined in mouse lung tissue samples at

[Downloaded from ijrr.com on 2026-11-24]

[DOI: 10.18869/acadpub.ijrr.18.1.109]

different time points after 500 cGy TBI. Similar to the study by Sproull *et al.* [7], we observed varying levels of PTX3 expression in the lung parenchyma across the different groups; day 1 and 2 post-irradiation expression levels of PTX3 in the airway walls were significantly elevated compared with those of the non-irradiated group (p<0.05). PTX3 levels were also found decreased on day 7 compared with those on day 1 (p¬4.49). Furthermore, we observed very weak staining for the control group, while groups 2 and 3 showed strong immunoreactivity when stained with the PTX3 antibody; moderate PTX3 immunoreactivity was observed for group 4. H-SCORE values of the PTX3-positive cells between the control and early radiation groups were also statistically significant. Importantly, we found that PTX3 expression correlated significantly with early radiation in the lung, further suggesting that PTX3 can act as an early marker for radiation-induced damage.

In studies conducted over the last decade, PTX3 has been shown to play roles in angiogenesis, metastatic spread, and cancer immunomodulation during cancer onset. PTX3 also exhibits protective roles against microvascular damage, which can be very serious in *PTX9*$^{-/-}$ mice; notably, microvascular damage was found to improve when these animals were administered PTX3 [21]. Han B *et al.* [22] suggested that endogenously expressed PTX3 has a protective role in the pathogenesis of acute lung injury and that a lack of PTX3 may enhance neutrophil recruitment, cell death, activation of coagulation cascades, and inflammatory responses in the lung. Furthermore, high levels of serum PTX3 in lung cancer have been reported to be associated with apoptosis as well as increased inflammation and cancer cells in the tumor microenvironment. Moreover, PTX3 was found to correlate with both tumor grade and serum levels in lung, hepatocellular, and colorectal cancers [23-26]. In some cancers, such as liposarcoma and prostate cancer, PTX3 is overexpressed [27-28].

In the present study, PTX3 levels in the lung parenchyma were evaluated and found to correlate with histochemical changes in lung tissue. We believe this supports the correlation between PTX3 levels and radiation-induced lung tissue changes. However, as this was an invasive method, our observations require further study. We measured PTX3 levels in lung tissue samples instead of serum, as serum PTX3 levels after TBI are thought to increase not only after lung damage but also after damage to all other organs. Another limitation to our study is that PTX3 levels were not examined in plasma. The relationship between changes in PTX3 plasma levels and changes in histological and parenchymal tissue is important in terms of predicting lung injury in people exposed to radiation due to radiation accidents or attacks. Furthermore, measuring plasma PTX3 levels may be a good non-invasive method for the early detection of radiation-induced damage.

CONCLUSION

In this study, an increase in PTX3 expression on day 1 after radiotherapy was evaluated as a sign of an acute phase response associated with inflammation. Therefore, PTX3 levels may be utilized as a marker for early radiation exposure and for following the long-term effects of radiation. In addition, a decrease in inflammation-related PTX3 levels, such as the utilization of prostatic-specific antigen (PSA) levels in the diagnosis and follow-up of prostate cancer, may indicate tumor control and increased recurrence and/or metastasis; however, cut-off values need to be defined. Overall, our study provides a basis for future investigation into the pathological processes of pulmonary inflammation and acute radiation injury, which may provide novel therapeutic strategies for controlling pulmonary inflammation without severe radiation injury.

ACKNOWLEDGMENTS

We would like to thank Editage (www.editage.com) for English language editing. No funding was provided for this study.

***Conflicts of interest*:** *Declared none.*

[Downloaded from ijrr.com on 2026-11-24]

[DOI: 10.18869/acadpub.ijrr.18.1.109]

REFERENCES

1. Siegel RL, Miller KD, Jemal A (2019) Cancer statistics, 2019. *CA Cancer J Clin*, ***69(1)****: 7–34.*
2. Sagerup CM, Smastuen M, Johannesen TB, Helland A, Brustugun OT (2011) Sex-specific trends in lung cancer incidence and survival: a population study of 40,118 cases. *Thorax,* ***66(4)****: 301–307.*
3. Ghafoori P, Lawrence BM, Vujaskovic Z, Kelsey CR (2008) Radiation-Induced Lung Injury: Assessment, Management, and Prevention. *Oncology,* ***22(1)****: 37–47.*
4. Goans RE, Holloway EC, Berger ME, Ricks RC (2001) Early dose assessment in criticality accidents. *Health Phys,* ***81 (4)****: 446–449.*
5. Bourgier C, Levy A, Vozenin MC, Deutsch E (2012) Pharmacological strategies to spare normal tissues from radiation damage: useless or overlooked therapeutics? *Cancer Metastasis Rev,* ***31(3-4)****: 699–712.*
6. Rubin P, Johnston CJ, Williams JP, McDonald S, Finkelstein JN (1995) A perpetual cascade of cytokines postirradiation leads to pulmonary fibrosis. *Int J Radiat Oncol Biol Phys,* ***33 (1)****: 99–109.*
7. Sproull M, Kramp T, Tandle A, Shankavaram U, Camphausen K (2017) Multivariate analysis of radiation responsive proteins to predict radiation exposure in total-body irradiation and partial-body irradiation models. *Radiat Res,* ***187 (2)****: 251–258.*
8. Bottazzi B, Doni A, Garlanda C, Mantovani A (2010) An integrated view of humoral innate immunity: pentraxins as a paradigm. *Annu Rev Immunol,* ***28(1)****: 157–183.*
9. Balhara J, Koussih L, Zhang J, Gounni AS (2013) Pentraxin 3: an immuno-regulator in the lungs. *Front Immunol,* ***4****: 127.*
10. Introna M, Alles VV, Castellano M, Picardi G, De Gioia L, Bottazzai B, Peri G, Breviario F, Salmona M, De Gregorio L, Dragani TA, Srinivasan N, Blundell TL, Hamilton TA, Mantovani A (1996) Cloning of mouse ptx3, a new member of the pentraxin gene family expressed at extrahepatic sites. *Blood,* ***87(5)****: 1862–1872*.
11. Garlanda C, Bottazzi B, Bastone A, Mantovani A (2005) Pentraxins at the crossroads between innate immunity, inflammation, matrix deposition, and female fertility. *Annu Rev Immunol,* ***23****: 337–366*.
12. Casula M, Montecucco F, Bonaventura A, Liberale L, Vecchié A, Dallegri F, Carbone F (2017) Update on the role of Pentraxin 3 in atherosclerosis and cardiovascular diseases. *Vascul Pharmacol,* ***99****: 1–12.*
13. Breviario F, d'Aniello EM, Golay J, Peri G, Bottazzi B, Bairoch A, Saccone S, Marzella R, Predazzi V, Rocchi M, Della Valle G, Dejana E, Mantovani A, Introna M (1992) Interleukin-1-inducible genes in endothelial cells. Cloning of a new gene related to C-reactive protein and serum amyloid P component. *J Biol Chem,* ***267(31)****: 22190-22197*.
14. Lee GW, Goodman AR, Lee TH, Vilcek J (1994) Relationship of TSG-14 protein to the pentraxin family of major acute phase proteins. *J Immunol,* ***153(8)****: 3700–3707.*
15. Inforzato A, Peri G, Doni A, Garlanda C, Mantovani A, Bastone A, Carpentieri A, Amoresano A, Pucci P, Roos A, Daha MR, Vincenti S, Gallo G, Carminati P, De Santis R, Salvatori G (2006) Structure and function of the long pentraxin PTX3 glycosidic moiety: fine-tuning of the interaction with C1q and complement activation. *Biochemistry,* ***45(38)****: 11540–11551.*
16. Giacomini A, Ghedini GC, Presta M, Ronca R (2018) Long pentraxin 3: A novel multifaceted player in cancer. *Biochim Biophys Acta Rev Cancer,* ***1869(1)****: 53–63.*
17. He X, Han B, Liu M (2007) Long pentraxin 3 in pulmonary infection and acute lung injury. *Am J Physiol Lung Cell Mol Physiol,* ***292(5)****: L1039–1049.*
18. Slanger M. Calculating H-Score, the ASCO post, April 10, 2015
19. Chen J, Zhang W, Zhang L, Zhang J, Chen X, Yang M, Chen T, Hong J (2017) Glycyrrhetinic acid alleviates radiation-induced lung injury in mice. *J Radiat Res,* ***58(1)****: 41–47.*
20. Pauwels NS, Bracke KR, Maes T, van Pottelberge GR, Garlanda C, Mantovani A, Joos GF, Brusselle GG (2010) Cigarette smoke induces PTX3 expression in pulmonary veins of mice in an IL-1 dependent manner. *Respir Res,* ***11****: 134*.
21. Salio M, Chimenti S, De Angelis N, Molla F, Maina V, Nebuloni M, Pasqualini F, Latini R, Garlanda C, Mantovani A (2008) Cardioprotective function of the long pentraxin PTX3 in acute myocardial infarction. *Circulation,* ***117 (8)****: 1055–1064.*
22. Han B, Haitsma JJ, Zhang Y, Bai X, Rubacha M, Keshavjee S, Zhang H, Liu M (2011) Long pentraxin PTX3 deficiency worsens LPS-induced acute lung injury. *Intensive Care Med,* ***37(2):*** *334–342.*
23. Liu C, Yao Y, Wang W (2014) Pentraxin-3 as a prognostic marker in patients with small-cell lung cancer. *Med Oncol,* ***31(10):*** *207.*
24. Berg J, Halvorsen AR, Bengtson MB, Taskén KA, Mælandsmo GM, Yndestad A, Halvorsen B, Brustugun OT, Aukrust P, Ueland T, Helland Å (2018) Levels and prognostic impact of circulating markers of inflammation, endothelial activation and extracellular matrix remodelling in patients with lung cancer and chronic obstructive pulmonary disease. *BMC Cancer,* ***18(1)****: 739.*
25. Liu B, Zhao Y, Guo L (2018) Increased serum pentraxin-3 level predicts poor prognosis in patients with colorectal cancer after curative surgery, a cohort study. *Medicine (Baltimore),* ***97(40)****: e11780.*
26. Song T, Wang C, Guo C, Liu Q, Zheng X (2018) Pentraxin 3 overexpression accelerated tumor metastasis and indicated poor prognosis in hepatocellular carcinoma via driving epithelial-mesenchymal transition. *J Cancer,* ***9(15):*** *2650–2658.*
27. Willeke F, Assad A, Findeisen P, Schromm E, Grobholz R, von Gerstenbergk B, Mantovani A, Peri S, Friess HH, Post S, von Knebel Doeberitz M, Schwarzbach MH (2005) Overexpression of a member of the pentraxin family (PTX3) in human soft tissue liposarcoma. *Eur J Cancer,* ***42****: 2639–2646.*
28. Sardana G, Jung K, Stepham C, Diamandis EP (2008) Proteomic analysis of conditioned media from PC3, LNCaP and 22Rv1 prostate cancer cell lines: discovery and validation of candidate prostate cancer biomarkers. *J Proteome Res,* ***7****: 3329 –3338.*

[Downloaded from ijrr.com on 2026-11-24]

[DOI: 10.18869/acadpub.ijrr.18.1.109]

[DOI: 10.18869/acadpub.ijrr.18.1.109] [Downloaded from ijrr.com on 2026-11-24]