Volume 18, No 1 | International Journal of Radiation Research, January 2020

Protective effect of vitamin D against rats' mandibular osteoporosis induced by corticosteroids and gamma rays

A.A. Elkady[1*], H.H.Kazem[1], E.A. Elgendy[2]

[1]*Health Radiation Research Department, National Center for Radiation Research and Technology (NCRRT), Egyptian Atomic Energy Authority, 29 Nasr City , Cairo, Egypt*
[2]*Oral Medicine & Periodontology Department, Faculty of Dentistry, Khafrelsheikh University, Egypt*

► ***Original article***

Corresponding authors:
Ahmed Amer Elkady, PhD.,
E-mail:
elkadyah13@gmail.com

Revised: April 2019
Accepted: May 2019

Int. J. Radiat. Res., January 2020; 18(1): 125-131

DOI: 10.18869/acadpub.ijrr.18.1.125

ABSTRACT

Background: Osteoporosis is a progressive systematic skeletal illness characterized by low bone mineral density (BMD), deterioration of microarchitecture of bone tissues and susceptibility to fracture caused by bone resorption. The study investigates the possible role of Alfacalcidol; vitamin D (Vit D) to mitigate osteoporosis induced by corticosteroid and γ-rays in rats. ***Materials and Methods:*** Eighty Sprague-Dawley rats were divided equally into eight groups: Control group (1 ml olive oil orally), Epirelefan group (7mg/kg sc), Vit D group (20,000 IU/kg orally), Vit D plus Epirelefan group, Vit D plus γ-rays (8 Gy) group, Epirelefan plus γ-rays group, Vit D plus Epirelefan plus γ-rays group and γ-rays groups. ***Results*:** In Epirelefan group, mandible bone has small cavities, micro fissures, thinning and decrease in the number of trabecular, which may appear rod-like and concave beside increase marrow cavities. In Epirelefan + γ-rays group, the lesions were more severe with increasing osteoclast and alteration of serum calcium, phosphate and alkaline phosphatase. The administration of Vit D before corticosteroid injection and pre γ-rays-irradiation has significantly reduced mandibular damage. ***Conclusion:*** Vit D could be efficient in mitigating osteoporosis occurred by corticosteroid and γ-rays in rat model.

Keywords*: Osteoporosis, γ-rays, Epirelefan, Vit D, Rats.*

INTRODUCTION

Osteoporosis is a multifactorial skeletal disease, showing a decrease in bone mass and disruption of the microarchitectural structure of bone tissue, leading to weakness and easy fracture of bone [1]. Although osteoporosis usually is reported late in life, and age is a major risk factor, its origins can be tracked back into youth. However, there are many factors that could be directly related to development of osteoporosis and these include dietary calcium levels during periods of rapid bone growth [2], genetic, lifestyle and hormonal elements [3].

Glucocorticoids are essential therapeutic agents that have been used for their strong anti-inflammatory and immunosuppressive properties for over 50 years. Glucocorticoids have a harmful effect on bone formation, turnover and integrity. The main action is on osteoblasts, reducing replication and impairing differentiation and maturation, leading to decreased bone formation [4,5]. Osteocytes are also affected, with decreased cell function and increased apoptosis causing impairment of their ability to identify and repair bone microdamage. Reduced numbers of viable osteocytes are observed in iliac crest biopsies of patients on glucocorticoid treatment [6]. Vitamin D increases calcium absorption in the gastrointestinal tract as well as reabsorption in the distal renal tubules. Thus, patients receiving treatment with active vitamin D compounds should be monitored for hypercalcemia and hypercalcuria

[Downloaded from ijrr.com on 2026-11-24]

[DOI: 10.18869/acadpub.ijrr.18.1.125]

[4]. In a study by Richy *et al.* [7] it was shown that vitamin D equivalents [Alfacalcidol1-alpha (OH) D and calcitriol 1,25(OH)(2)D] may be more active then native vitamin D in glucocorticoid-induced osteoporosis (GIOP). Furthermore, alfacalcidol was found to have a preventive effect on bone loss at the lumbar spine in GIOP patients [8,9].

Ionizing radiations used in cancer treatment may lead to delayed bone abnormalities that raise the hazard of skeletal fractures in women whose malignant disease is treated with irradiation [10]. Reduction in bone mass induce by ionizing radiation is dependent on several factors, including the dose absorbed, the energy of the radiation beam, the fraction size of the radiation dose, and the age and developmental stage of the patient [11]. Six weeks after exposure to high doses (16 Gy delivered in four doses of 4 Gy each to a single limb), causes loss of trabecular bone in a rat [12]. This study aimed to investigate the efficiency of vit D in protecting from osteoporosis caused by corticosteroid or by corticosteroid + γ-rays treatment in rats. To our knowledge, this is the preliminary report of γ-rays that accelerate rat mandibular osteoporosis induced by corticosteroid.

MATERIALS AND METHODS

Animals

Eighty male Sprague-Dawley rats, age (15–16 weeks), weighing (180–190 g), obtained from the NCRRT, Egyptian Atomic Energy Authority, Nasr City, Cairo, Egypt were used in the experiment. Animals were kept under standard conditions and were allowed free access to a standard requirement diet and water ad libitum. Animals were kept under a controlled lighting condition (light: dark, 13–11hours). Animals were acclimatized to the experimental conditions for 3 days prior the start of the study. All experiments were performed in accordance with the ethics committee of the NCRRT.

Radiation processing

It was performed by using gamma cell-40 (Cesium-137) located at NCRRT. Animals were irradiated with a single dose of 8 Gy γ-rays delivered at a dose rate of 0.42 Gy/ minutes at the time of experimentation. Animals were not anesthetized before irradiation.

Reagents

Alfacalcidol (1α-hydroxycholecalciferol) is a synthetic vitamin D_3 compound hydroxylated in position 1, was purchased from LEO Pharmaceutical Products Ballerup-Denmark. The drug was dissolved in olive oil. Epirelefan (triamcinolone acetonide 40mg/ml) is known as a corticosteroid hormone or glucocorticoid. Ampules were purchased from Egyptian International Pharmaceutical Industries Co. – (EIPICO), Egypt. All other chemicals used were of the highest purity grade available.

Experimental design

Eighty male rats were divided into eight equal groups as follows:

Control Group; rats received orally olive oil 1ml for each rat (as vehicle) for 12 weeks. **Epirelefan group;** sterile aqueous suspension was used subcutaneously in a dose of 7 mg/kg once weekly for 12 weeks to induce osteoporosis [13]. **Vit D group;** Alfacalcidol, 20,000 IU/kg of body weight (BW) dissolved in 1 ml olive oil and administrated orally by stomach tube 5 times / week for 12 weeks [14]. **Vit D + Epirelefan group;** this group received Alfacalcidol, as in group III and after one week from the beginning of the experiment, rats were injected with Epirelefan sc (7 mg/kg body weight once weekly for 12 weeks). **Vit D + γ-rays group;** rats received Alfacalcidol as in group III, then after one hour of the last dose, rats whole body was exposed to an acute single dose of 8 Gy γ-rays. **Epirelefan + γ-rays group;** the animals received Epirelefan as in group II then after one week of the last dose, rats whole body was exposed to an acute single dose of 8 Gy γ-rays. **Vit D+ Epirelefan + γ-rays group;** Alfacalcidol and Epirelefan were administrated to rats as the case of group IV then after one hour of the last dose of Alfacalcidol, rats whole body was exposed to an acute single dose of 8 Gy

[Downloaded from ijrr.com on 2026-11-24]

[DOI: 10.18869/acadpub.ijrr.18.1.125]

γ-rays. **γ-rays group;** rats injected olive oil 1ml for each rat (vehicle) for 12 weeks then after one hour of the last dose, rats whole body was exposed to an acute single dose of 8 Gy γ-rays.

Samples collection

At the 5th day post γ-rays exposure, rats were sacrificed. The mandible was removed, followed by removal of any excess of soft tissue, and the bone was fixed in 10% formaldehyde solution. Decalcification was carried out followed by dehydration, cleating and embedding in paraffin. Paraffin sections of 4-micron thickness were prepared and stained routinely with haematoxylin and eosin (H&E) according to Suvarnaet et al. [15].

Biochemical investigation

Blood samples were collected from different rat groups under standard laboratory conditions. Serum Calcium and phosphate were measured with an auto analyzer (Hitachi 7170; Tokyo, Japan). Serum alkaline phosphatase (ALP) was measured by using colorimetric kits (Abcam, UK) following the producer's instructions. The absorbance was read at 405nm.

Statistical analysis

Data were analyzed using SPSS software (version 19.0). One way analysis of variance (ANOVA) followed by LSD as Post Hoc-test were used. The results obtained were expressed by mean ± standard deviation (SD). P-values < 0.05 were considered to be statistically significant [16].

RESULTS

Histopathological finding

Mandible of control rats is formed from haversian system (osteon), interstitial lamella under periosteum and endosteum (figure 1). periosteum is vascular connective tissue membrane which form two layers (outer fibrous layer and inner osteogenic layer). The endosteum that is lines the internal surface of bone, bone marrow cavities and haversian system formed from vascular connective tissue membrane rich in osteogenic, osteoblast and osteoclast cells. Microscopic appearance of mandible in Vit D group and Vit D + γ-rays group showed normally as control rats. In γ-rays group, the histopathological lesions in most cases showed normal structure but in few cases, showed increasing bone matrix tissues replaced by fibrous tissues (figure 2). In Epirelefan group (osteoporosis-group), the major microscopic changes are thinning of the trabecular and widening of haversian canals. The haversian system is poorly organized with rare cement lines. The mandible bone has small cavities, thinning and decrease in the number of trabecular, moreover the trabecular may appear straight or rod-like, concave with present micro fissures beside increase marrow cavities (figure 3. A & B). Moreover, in case Epirelefan + γ-rays group the mandible lesions showed in most cases more severe than Epirelefan group which represented by small cavities and multiple cracks with compact bones beside increasing osteoclast (Fig 4. A & B). While in case of Vit D + Epirelefan group, the mandible showed normally with or without congested blood vessels and increasing osteoclast (figure. 5. A), but in case Vit D+ Epirelefan + γ-rays group, the lesion restrained and the mandible showed normal structure beside dilated blood vessels and marrow cavities (figure 5. B).

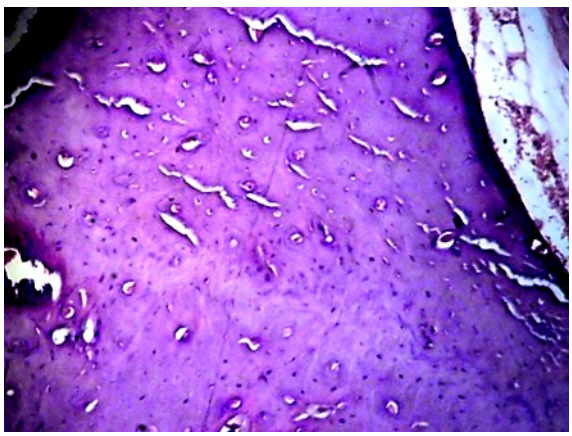

Figure 1. Mandible of control rat, showing normal structure (H& E × 100).

[Downloaded from ijrr.com on 2026-11-24]

[DOI: 10.18869/acadpub.ijrr.18.1.125]

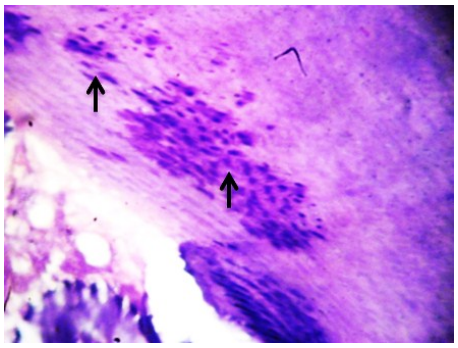

Figure 2. Mandible of γ-rays group, showing increasing bone matrix tissues replaced by fibrous tissues (arrows) (H& E × 400).

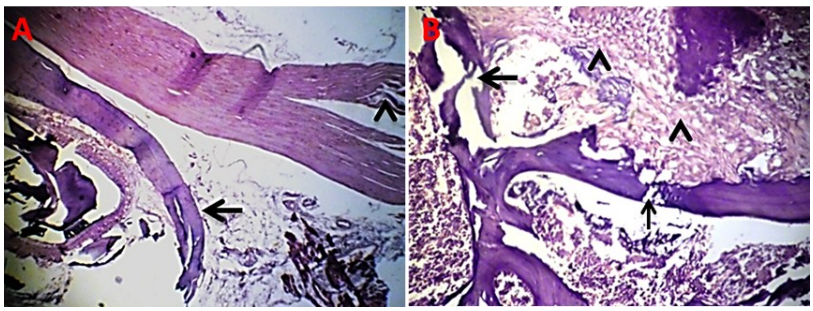

Figure 3. Mandible of Epirelefan group, **A.** showing thin, concave osseous tissues and distorted (arrow browser) with multiple crack on osseous bone (arrow head) (H& E × 400). **B.** showing thin osseous tissues, distorted, rod-like (arrows) and increase marrow cavities (arrows head) (H& E × 100).

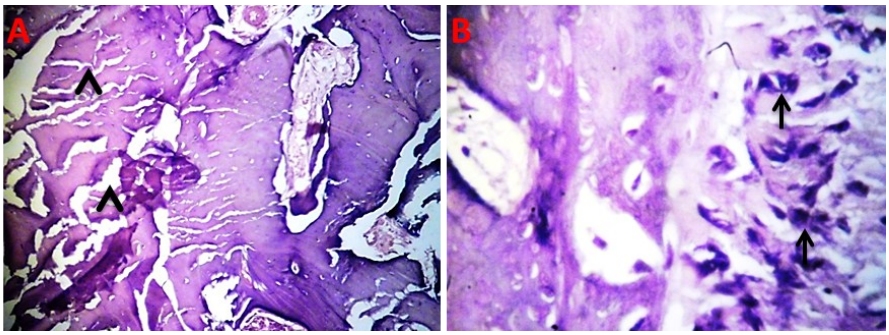

Figure 4. Mandible of Epirelefan + γ-rays group, **A.** showing small cavities and multiple cracks with compact bones (arrows head) (H& E × 100). **B.** Mandible of rat showing increasing osteoclast (arrows) (H& E × 400).

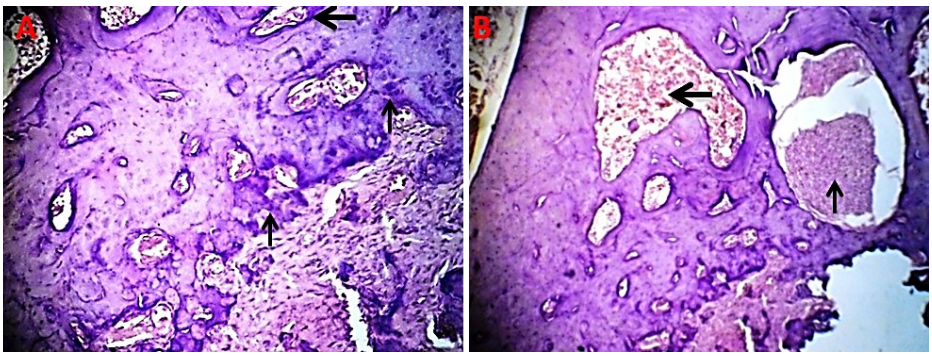

Figure 5. Mandible of rats, (H& E × 100). **A.** Vit D + Epirelefan group, showing congested blood vessels (arrow browser) and increasing osteoclast (arrows). **B.** Vit D+ Epirelefan + γ-rays group, showing normal structure beside dilated blood vessels (arrow browser) and dilated marrow cavities (arrow).

Biochemical results

As shown in table 1 the administration of vitamin D to normal healthy rats had no significant effect on calcium and phosphate levels or alkaline phosphatase activity compared to the control levels. Exposure to γ-rays induces a significant decrease in calcium and phosphate levels and a significant increase of alkaline phosphatase activity compared to the control levels (table 1).

Epirelefan as well as Epirelefan + γ-rays treatment decrease calcium level and increase phosphate level and alkaline phosphatase activity, significantly. The administration of vitamin D to Epirelefan, Epirelefan + γ-rays and γ-rays treated rats has significantly ameliorated these alterations compared to their respective group not receiving vitamin D (table 1).

[Downloaded from ijrr.com on 2026-11-24]

[DOI: 10.18869/acadpub.ijrr.18.1.125]

Table 1. The levels of calcium and phosphate and the activity of alkaline phosphatase in serum of different rat groups.

Groups	**Calcium** (mg/dl)	**Phosphate** (mg/dl)	**alkaline phosphatase** (U/L)
Control	9.80 ± 0.15	8.00 ± 0.08	72.76 ± 1.58
Epirelefan	5.20 ± 0.21[a]	1200 ± 0.09 [a]	85.00 ± 0.90 [a]
Vit D	10.20 ± 0.34	8.20 ± 0.07	75.00 ± 1.80
Vit D + Epirelefan	7.90 ± 0.54[b]	900 ± 0.04[b]	73.00 ± 3.00[b]
Vit D + γ-rays	7.70 ± 0.31[b]	7.00 ± 0.06[b]	105.00 ± 2.90[b]
Epirelefan + γ-rays	4.90 ± 0.32[a]	12.90 ± 0.07[a]	110.00 ± 5.20[a]
Vit D + Epirelefan + γ-rays	7.10 ± 0.11[b]	7.80 ± 0.20[b]	100.00 ± 3.90[b]
γ-rays	6.20 ± 0.12[a]	6.80 ± 0.06[a]	115.04 ± 4.38 [a]

All values are expressed as mean ± SD. aSignificant (P <0.05) when compared with the control group. bSignificant (P <0.05) when compared with the Epirelefan group.

DISCUSSION

The result of extensive studies has demonstrated that the maxillary as well as the mandibular bone may reflect the skeletal bone conditions. It is well documented that the remodeling of bones occurs at the endosteal surfaces where, osteoclasts and osteoblasts are located and that the presence of more surfaces means more cells and remodeling. In this line, Jonasson and Rythén [17] have indicated that the turnover rate of bones in the mandibular alveolar process is the fastest in the body and thus may reveal the first signs of osteoporosis. The three main factors by which osteoporosis advances are an insufficient peak bone mass; the skeleton develops insufficient mass and strength during growth, excessive bone resorption and inadequate formation of new bone during remodeling [18]. Glucocorticoids have damaging results on bone formation, turnover and reliability. The action of cortisone occurred firstly on osteoblasts, decreasing replication and impairing differentiation and maturation, leading to reduced bone formation [4,5]. It also involves a component of increased bone resorption. In the early phase of glucocorticoid treatment, decreased bone formation coupled with increased resorption leads to quick loss of bone integrity and may be lead to significant fracture risk [19]. During the early phase of therapy, high-dose steroids increase osteoclast generation. Osteoblast signaling is affected, causing reduced osteoprotegerin release and increased receptor activator of nuclear factor-Kappa B ligand, resulting in osteoclastogenesis [20]. Moreover glucocorticoids that deleteriously action on bone includes decreased calcium absorption by the gastrointestinal tract and renal calcium loss. Steroid usually cause muscle weakness and therefore increased hazard of falls and fractures [4]. Continuous oral glucocorticoid therapy is associated with rapid bone loss and an increase in fracture risk that is seen within 3-6 months of initiation and is dose-related [21].

Our results agree with the study made by Wimalawansa *et al.* [13] discussing GIOP. The present study reveal that histopathological results occur due to the administration of Epirelefan to rats in Epirelefan group are thinning of the trabecular and widening of haversian canals. The mandible bone has small cavities, thinning and decrease in the number of trabecular, moreover the trabecular may appear straight or rod-like, concave with present micro fissures beside increase marrow cavities. Those lesions more progressive in case Epirelefan + γ-rays group, where the mandible lesions showed in most cases more severe than Epirelefan group with increasing osteoclast. Corticosteroids inhibit replenishment of osteoblasts, reduce the synthesis of bone collagen and osteocalcin by existing osteoblasts, and promote osteoblast and osteocyte apoptosis. Zhang *et al.* [22] suggested that bone loss in directly irradiated bones is not only due to the elevated iron level, but also from increased osteoclast differentiation. Osteoblast inhibition leads to a reduction in the amount of bone replaced in each remodeling cycle. However, the role of osteoclastic bone resorption in fracture risk is less certain as study results have been inconsistent and markers of bone resorption are

[Downloaded from ijrr.com on 2026-11-24]

[DOI: 10.18869/acadpub.ijrr.18.1.125]

often unchanged during short-term corticosteroid treatment[23]. Marcu *et al.* [24] stated that the osteoporosis is represented to the thinned trabeculae of the bone that lost continuity, the better resorption of the horizontal trabeculae, and the reduction of the trabecular connectivity with enlarged areolae and the adipose degeneration of the marrow.

The biochemical results showed decrease serum calcium and increase serum phosphate and alkaline phosphatase activity in Epirelefan group and it was more sever in Epirelefan + γ-rays group. Corticosteroids reduce intestinal calcium absorption by decreasing the expression of calcium channels in the duodenum [25] and increase renal calcium excretion by decreasing calcium reabsorption [26].

In our study, the improvement occurred in biochemical and histopathological findings in both of Vit D + Epirelefan and Vit D+ Epirelefan + γ-rays groups suggested that, administration of Vit D could have potent role for preventing osteoporosis activity [4]. Williamson *et al.* [14] recommend that dietary vitamin D_3 supplementation may increase bone health by improving bone material strength. It is generally established that vitamin D_3 is crucial for bone health through its actions as a regulator of minerals, and in turn, skeletal homeostasis in vertebrates [27]. A number of intervention studies examining the effect of vitamin D_3 supplementation have described significant increases in bone mineral content and bone mineral density [28,29].

In conclusion, the results of the present work revealed that pretreatment with Vitamin D has attenuated the alterations in serum calcium, phosphate, and alkaline phosphatase and histological damage in the mandible of the rats caused by cortisone and γ-rays it could be concluded that vitamin D may be a valued prophylactic agent against mandible osteoporosis.

ACKNOWLEDGEMENTS

We are thankful to our colleagues, Health Radiation Research Department for providing laboratory conveniences, and technicians of the National Centre for Radiation Research and Technology (NCRRT), Egyptian Atomic Energy Authority for providing the fundamental irradiation services. This work was done in the NCRRT, Egypt.

Conflicts of interest*: *Declared none.

REFERENCES

1. Lelovas PP, Xanthos TT, Thoma SE, Lyritis GP, Dontas IA (2008) The laboratory rat as an animal model for osteoporosis research. *Comp Med,* ***58:*** *424-430.*
2. Kanis JA, Borgstrom F, De Laet C, Johansson H, Johnell O, Jonsson P, Oden A, Zethraeus N, Pfleger B, Khaltaev N (2005) Assessment of fracture risk. *Osteoporos Int,* ***16:****581–589.*
3. Dennison E1, Cole Z, Cooper C (2005) Diagnosis and epidemiology of osteoporosis. *Curr Opin Rheumatol,* ***17:*** *456-461.*
4. Canalis E, Massiotti G, Giustina A, Bilezikian JB (2007) Glucocorticoid-induced osteoporosis: Pathophysiology and therapy. *Osteoporos Int,* ***18****: 1319-1328.*
5. Ito S, Suzuki N, Kato S, Takahashi T, Takagi M (2007) Glucocorticoids induce the differentiation of a mesenchymal progenitor cell line, ROB-C26 into adipocytes and osteoblasts, but fail to induce terminal osteoblast differentiation. *Bone,* ***40:*** *84-92.*
6. Sambrook PN, Hughes DR, Nelson AE, Robinson BG, Mason RS (2003) Osteocyte viability with glucocorticoid treatment: Relation to histomorphometry. *Ann Rheum Dis,* ***62:*** *1215–1217.*
7. Richy F, Schacht E, Bruvere O, Ethgen O, Gourlay M, Reginster JY (2005) Vitamin D analogs versus native vitamin D in preventing bone loss and osteoporosis-related fractures: A comparative meta-analysis. *Calcif Tissue Int,* ***76:*** *176-186*.
8. Reginster JY, Kuntz D, Verdickt W, Wouters M, Guillevin L, Menkes CJ et al. (1999) Prophylactic use of Alfacalcidolin corticosteroid-induced osteoporosis. *Osteoporos Int,* ***9:*** *75 -81.*
9. Ringe JD, Coster A, Meng T, Schacht E, Umbach R (1999) Treatment of glucocorticoid-induced osteoporosis with alfacalcidol/calcium versus vitamin D/calcium. *Calcif Tissue Int,* ***65:*** *337-340.*
10. Tai P, Hammond A, Van Dyk J, *et al.* (2000) Pelvic fractures following irradiation of endometrial and vaginal cancers: a case series and review of literature. *Radiother Oncol,* ***56:*** *23–28.*
11. Williams HJ and Davies AM (2006) The effect of X-rays on bone: a pictorial review. *Eur Radiol,* ***16:*** *619-633.*
12. Wernle JD, Damron TA, Allen MJ, Mann KA (2010) Local irradiation alters bone morphology and increases bone

[Downloaded from ijrr.com on 2026-11-24]

[DOI: 10.18869/acadpub.ijrr.18.1.125]

fragility in a mouse model. *J Biomech,* ***43:*** *2738-46.*
13. Wimalawansa SJ, Chapa MT, Yallampalli C, Zhang R, Simmons DJ (1997) Prevention of corticosteroid-induced bone loss with nitric oxide donor nitroglycerin in male rats. *Bone,* ***21:*** *275-80.*
14. Williamson L, Hayes A, Hanson E D, Pivonka P, Sims A N, Jonathan H. Gooi J H, (2017) High dose dietary vitamin D3 increases bone mass and strength in mice. *Bone Rep,* ***6:*** *44 -50.*
15. Suvarna SK, Layton C, Bancroft JD (2013) Bancroft's Theory and Practice of Histological Techniques (7th ed.), Churchill Livingstone Elsevier, Oxford.
16. Snecdecor GW and Cochran WG (1989) Statistical Methods, 8th Edition, Iowa State University Press, USA, P. 503.
17. Jonasson G and Rythén M (2016) Alveolar bone loss in osteoporosis: a loaded and cellular affair? *Clinical, Cosmetic and Investigational Dentistry,* ***8:*** *95-103.*
18. Raisz LG (2005) Pathogenesis of osteoporosis: concepts, conflicts, and prospects. *J Clin Invest,* ***115:*** *3318-3325.*
19. Canalis E, Bilezikian JP, Angeli A, Giustina A (2004) Perspectives on glucocorticoid-induced osteoporosis. *Bone,* ***34:*** *593-598.*
20. Sivagurunathan S, Muir MM, Brennan TC, Seale JP, Mason RS (2005) Influence of glucocorticoids on human osteoclast generation and activity. *J Bone Miner Res,* ***20:*** *390-398.*
21. Compston J (2018) Glucocorticoid-induced osteoporosis: an update. *Endocrine,* ***61:*** *1588-1592.*
22. Zhang J, Zheng L, Wang Z, Pei H, Hu W, Nie J (2018) Lowering iron level protects against bone loss in focally irradiated and contralateral femurs through distinct mechanisms. *Bone,* ***7 (120):*** *50-60.*
23. Romas E (2008) Corticosteroid-induced osteoporosis and fractures. *Aust Prescr,* ***31:*** *45-91*
24. Marcu F, Bogdan F, Muţiu G, Lazăr L (2011) The histopathological study of osteoporosis. *Rom J Morphol Embryol,* ***52:*** *321-325.*
25. Huybers S, Naber TH, Bindels RJ, Hoenderop JG (2007) Prednisolone-induced Ca2+ malabsorption is caused by diminished expression of the epithelial Ca2+ channel TRPV6. *Am J Physiol Gastrointest Liver Physiol,* ***292:*** *92.*
26. Nielsen HK, Thomsen K, Eriksen EF, *et al.* (1988) The effects of high-dose glucocorticoid administration on serum bone gamma carboxyglutamic acid-containing protein, serum alkaline phosphatase and vitamin D metabolites in normal subjects. *Bone Miner,* ***4:*** *105.*
27. Anderson PH, Atkins GJ, Turner AG, Kogawa M, Findlay DM, Morris HA, (2011) Vitamin D metabolism within bone cells: effects on bone structure and strength Mol. Cell. *Endocrinol,* ***347 (1–2):*** *42-47.*
28. El-Hajj G, Tamim H, Maalouf J, Salamoun M, Khalife H, Choucair M, Arabi A, Vieth R (2006) Effect of vitamin D replacement on musculoskeletal parameters in school children: a randomized controlled trial. *J Clin Endocrinol Metab,* ***91:*** *405-412.*
29. Du X, Zhu K, Trube A, Zhang Q, Ma G, Hu X, Fraser DR, Greenfield H (2004) School-milk intervention trial enhances growth and bone mineral accretion in Chinese girls aged 10–12 years in Beijing. *Br J Nutr,* ***92:*** *159-168.*

[Downloaded from ijrr.com on 2026-11-24]

[DOI: 10.18869/acadpub.ijrr.18.1.125]

[DOI: 10.18869/acadpub.ijrr.18.1.125] [Downloaded from ijrr.com on 2026-11-24]