

The protective effect of melatonin on liver damage induced by mobile phone radiation in mice model

R. Moradpour¹, M. Shokri², S. Abedian³, F. Talebpour Amiri^{2*}

¹Department of Biomedical Engineering, Rouzbahan Institute of Higher Education, Sari, Iran

²Department of Anatomy, Faculty of Medicine, Molecular and Cell Biology Research Center, Mazandaran University of Medical Sciences, Sari, Iran

³Department of Immunology, Faculty of Medicine, Immunogenetic Research Center, Mazandaran University of Medical Sciences, Sari, Iran

ABSTRACT

ABSTRACT: Radiofrequency electromagnetic radiation (RF-EMR) of mobile phone has adverse effects on human health, such as the liver tissue. Melatonin, as a neurohormone has antioxidant property. The aim of present study was to evaluate the protective effects of melatonin on liver damage induced by mobile phone-radiofrequency radiation. **Materials and Methods:** In this experimental study, 32 adult male BALB/c mice were divided randomly into four groups: control group (received only normal saline), melatonin group (2 mg/kg, for 30 consecutive days, intraperitoneally), Electromagnetic radiofrequency radiations (RF-EMR) group (4 hours per day for 30 consecutive days, whole body), and melatonin + RF-EMR) group (melatonin was prescribed one hour before exposure to RF-EMR. One day after treatment period were evaluated oxidative stress parameters, serum biochemical, and histopathological assays of liver. **Results:** The results exhibited that RF-EMR significantly increased oxidative stress (increased Malondialdehyde and decreased Glutathione level) compared with control and melatonin group ($P < 0.001$). Histopathological findings in the RF-EMR group showed periportal leucocyte infiltration, dilation of sinusoids, necrosis, vacuolation, and granulomatous formation. Also, alanine transaminase and aspartate transaminase, *alkaline phosphatase* in serum increased significantly compared with control and melatonin groups ($P < 0.001$). Melatonin administration significantly reduced oxidative stress ($P < 0.01$) in the radiated mice and ameliorated histopathological compared with control group. **Conclusion:** The data indicate that RF-EMR induces oxidative damage and changes histopathological structure in the liver. Melatonin decreased oxidative stress and improved the liver damage induced by RF-EMR.

Keywords: Radiofrequency electromagnetic radiation, hepatotoxicity, oxidative stress, antioxidant, melatonin.

► Original article

*Corresponding authors:

F. Talebpour Amiri, PhD,

Fax: + 98 1133543248

E-mail:

Ftaleb2001@yahoo.co.uk

Revised: April 2019

Accepted: May 2019

Int. J. Radiat. Res., January 2020;
18(1): 133-141

DOI: 10.18869/acadpub.ijrr.18.1.133

INTRODUCTION

Radiofrequency electromagnetic radiation (RF-EMR) at a low radiofrequency has a deleterious effect on human health. Prior studies showed that RF-EMR has harmful effects on the organs of the body (1). RF-EMR of mobile phone with production of free radicals and increasing

oxidative stress induced damage in vital organs such as liver (2). Alanine transaminase (ALT) and aspartate transaminase (AST), alkaline phosphatase (ALP) as liver enzymes increase in liver injury and previous studies have shown that mobile phone exposure causes increase liver enzymes (2). The mobile phone with oxidant / peroxide imbalance causes tissue

damage (2,3). Therefore, the use of antioxidants can play a significant role in reducing the damage caused by cell phones.

Melatonin, as a neurohormone, is synthesized and released in human from the pineal gland during the night (1). Synthesis and secretion is inhibited by electromagnetic radiation in the frequency range of visible light (4). Melatonin acts as an antioxidant, antiapoptotic agent and immune stimulant, and adjusts the amount of mRNA for specific proteins. So, It is effective in preventing some diseases (5,6). This hormone is able to reduce the damage induced by oxidative stress with free radical scavenging (7). In previous studies were seen protective effects of melatonin on wireless devices (8). The protective effect of melatonin has been proven by reducing oxidative stress against kidney (9), retina(10), brain (11) and testicular (12) injury due to radiofrequency radiation. The researchers have also shown the protective effect of melatonin in hepatotoxicity due to radiotherapy in cancer patients (13) and microwave radiation (14). But until now, there has been no study on the protective effect of melatonin on liver damage caused by mobile phone radiation.

Based on the above, it is hypothesized that melatonin, due to its antioxidant and anti-inflammatory properties, can have a protective effect on hepatotoxicity induced by RF-EMR from mobile phones. The aim of this study was to investigate the hepatoprotective effect of melatonin on liver injury induced electromagnetic waves by mobile phone with histochemical (MDA, GSH), biochemical (ALT, AST, ALP) and histopathological assessment.

MATERIALS AND METHODS

Experimental design

In this experimental study, 32 BALB/c male mice weighing approximately 25-30 g were prepared from the Mazandaran University of Medical Sciences Research Center. For adaptation to the experiment environment, one week before the start of the study, the animals were maintained on a darkness / brightness 12:

12, 55 ± 5% humidity and 22-24 °C. All the experimental methods were planned in accordance with the Institutional Animal Ethics Committee of the Mazandaran University of Medical Sciences, Sari, I.R. Iran. During the experiment, the mice had free access to water and food. After acclimatization to the environment, the mice were randomly divided into four groups (8 animals/group):

Group I: Normal saline (C): Mice received normal saline as the same volume of other groups by intraperitoneally.

Group II: Melatonin (M): mice received intraperitoneally of melatonin at a dose of 2 mg/kg for 30 consecutive days.

Group III: RF-EMR (R): Mice were continuously exposed to radiofrequency radiation (900 MHz, 100 to 300 MT, 54 to 160 W/m) for 30 consecutive days, 4 continuous hours per day (15).

Group IV: RF-EMR and Melatonin (R + M): mice were received daily 2mg / Kg of melatonin, one hour before exposure to the Mobile Radiation System (16).

Animals were continuously exposed to RF-EMR for 30 days (4 hours a day).

The irradiation system consists of a plastic cage (animal compartment of 40 × 40 × 30 cm) and a Nokia X mobile device (having a SAR value of 1.3 watts/kg for the head area and SAR equivalent to 1.43 kb / kg for the whole body). A continuous wave signal of MHZ 900 was emitted from the radiation system around the electromagnetic radiofrequency waves (carrier frequency of the GSM band). The cell phone was placed on animal cages in all experiments time. Therefore, the mice were able to move freely in their cages during the radiation period. During the encounter, the cell phone was in conversation mode and a voice was recorded with similar text played for animals. The phone was fully charged before it was started. It should be noted that during experiment, the control group was placed in the vicinity of the mobile phone in flight mode.

Sample collection

At the end of the treatment period (day 31),

the mice were anesthetized with ketamine (55 mg / kg) and zylazin (5 mg / kg). Blood was collected from the heart. Blood samples were transferred in tubes containing heparin solution as anticoagulant and then centrifuged at 3000 rpm for 10 minutes. Then mice were killed by displacement of the neck and the liver was removed from the abdomen. A part of the liver was fixed in 10% formalin for histological assessment and part of the liver after washing with PBS and drying with filter paper for was frozen in -70 C freezer histochemical assay.

Analysis of oxidative stress biomarkers

To analyze the oxidative stress, two markers of MDA and GSH were measured in the liver. The concentration of lipid peroxidation in liver was measured by spectrophotometry using thiobarbituric acid (TBA). To begin, 0.25 ml of phosphoric acid (0.05 mol) was mixed with 0.2 ml sample and then 0.3 ml of 0.2% thiobarbituric acid (TBA) was added. Samples were placed in a boiling water bath for 30 minutes. Then the sample tubes were immediately transferred to the ice bath and then 0.4 ml of n-butanol was added to each sample. The resulting mixture was centrifuged (3500 rpm for 10 minutes) and the MDA was measured on the basis of reaction with thiobarbituric acid. The created MDA was calculated in each sample in supernatant (490 nm) using a ELISA reader (Tecan, Rainbow Thermo, Austria). The content of MDA was expressed as nmol / mg protein. tetrameox Propane (TEP) was used as standard in this test ⁽¹⁷⁾.

To measure glutathione (GSH) in liver tissue, glutathione content in the samples was measured using a spectrophotometer (UV-1601 PC, Shimadzu, Japan) and 5, 5 'di-tibis-2-nitrobenzoic acid (DTNB) as an index at 412 nm, and was expressed as (μ M) 20 ⁽¹⁷⁾.

Serum biochemical analysis

The level of activity of ALT, AST and ALP enzymes as serum liver injury diagnostic enzyme markers was determined by kit (Pars Test -1050016) and diagnostic Kit (LDH FSDGKG 2201) (Cat. No. 3000 BT), respectively. A quantitative diagnosis was performed in a serum

using photometric method according to the company's instructions.

Liver histopathology analysis

For histological analysis, 24 hours after samples fixation, processing, embedding, sections with 5 micron thickness were stained with Hematoxylin and Eosin. Then, the histological structure of the liver was analyzed blindly by a histologist with an optical microscope. For semi-quantitative analysis, tissue micrographs were analyzed using a scoring system. Based on the severity of liver sinusoid dilatation, inflammatory cell infiltration, congestion, degeneration, presence of vacuole in the cytoplasm and granulomatous formation were scored. 0 score; (normal), 1 score; (mild), 2 score; (medium) and 3 score; (severe) ⁽¹⁸⁾.

Statistical analysis

Data was presented as means \pm standard deviation (S.D.). SPSS 19 version (Chicago, USA) was used for statistical analysis. Differences between groups were analyzed by means one-way ANOVA and Tukey tests and p-values <0.05 were considered to be statistically significant.

RESULTS

The effect of melatonin on oxidative stress markers of hepatotoxicity induced RF-EMR

The levels of oxidative stress parameters are shown in Figure1 RF-EMR induced oxidative stress in the liver tissue. MDA as the final product of lipid peroxidation was significantly higher in the group exposed to electromagnetic waves compared to the control and melatonin groups ($P < 0.001$). Melatonin could significantly reduced MDA levels in mice exposed to electromagnetic waves ($P < 0.01$). GSH, as an endogenous antioxidant, had a significant decrease in the electromagnetic radiation group compared to the control and melatonin groups ($P < 0.01$). Treatment with melatonin, one hour before electromagnetic radiation could significantly increased GSH levels ($P < 0.05$).

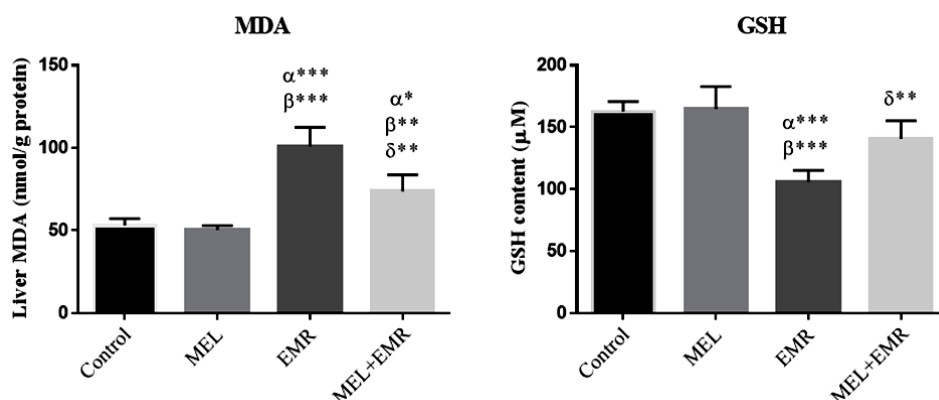


Figure 1. Effect of melatonin on MDA and GSH levels in liver damage induced by electromagnetic radiation in mice. All values were expressed as mean ± standard deviation. α is significant against the control group, β is significant against the melatonin group and γ is significant against the group exposed to electromagnetic radiation (*, P<0.05; **, P<0.01; ***, P<0.001). MEL: Melatonin; RF-EMR: Radiofrequency Electromagnetic radiation; MDA, Malondialdehyde and GSH, Glutathione.

The effect of melatonin on enzymatic markers of hepatotoxicity induced RF-EMR

The activity of enzyme markers in liver serum damage (ALT, AST, ALP) was shown in table 1. Electromagnetic radiation increased the levels of ALT, AST, ALP in RF-EMR group compared with the control and melatonin groups (P<0.001). This increase was effectively and significantly lowered by melatonin (P<0.01).

The effect of melatonin on histopathological changes of hepatotoxicity induced RF-EMR

Figure 2 shows photomicrography of the liver tissue structure in all groups. The histomorphologic findings of the liver with normal structure (sinusoids, hepatocytes and Kupffer cells) were observed in the control group. In the melatonin treated mice, the liver

morphology was similar to the control group. Mice exposed to RF-EMR showed hepatic injury more such as, dilatation of sinusoids, Kupffer cell proliferation, congestion, and proliferation of inflammatory cells around the portal region, eosinophilic cytoplasm and granulomatous formation. However, administration of melatonin in animals exposed to RF-EMR was seen to be a relatively good improvement in the structure of the liver tissue.

The mean of liver tissue damage score in all groups is shown in figure 3. RF-EMR increased the rate of liver damage in mice exposed to RF-EMR compared to control group (P<0.001). While mice administered with melatonin, the rate of liver damage was lower than those exposed only to RF-EMR (P<0.01). The liver tissue structure score was close in control and melatonin groups.

Table 1. Effect of melatonin on ALT, AST, and ALP levels in liver damage induced by electromagnetic waves in mice.

Groups	ALT	AST	ALP
Control	128.5 ± 10.61	147.3 ± 17.92	190.8 ± 13.55
MEL	124.6 ± 17.39	169.3 ± 21.89	189.9 ± 12.46
RF-EMR	190.1 ± 13.14 a *** b ***	227.5 ± 22.29 a *** b ***	262.8 ± 37.57 a *** b ***
RF - EMR + MEL	149 ± 31.38 c **	192.5 ± 18.09 c **	216.6 ± 21.76 c **

All values were expressed as mean ± standard deviation. a is significant compared to the control group, b is significant against the melatonin group and c is significant against the electromagnetic waves group. (**, P <0.01 ***; P <0.001). MEL: Melatonin, RF-EMR: Radiofrequency Electromagnetic radiation. ALT; alanine aminotransferase, AST; aspartate aminotransferase and ALP; alkaline phosphatase.

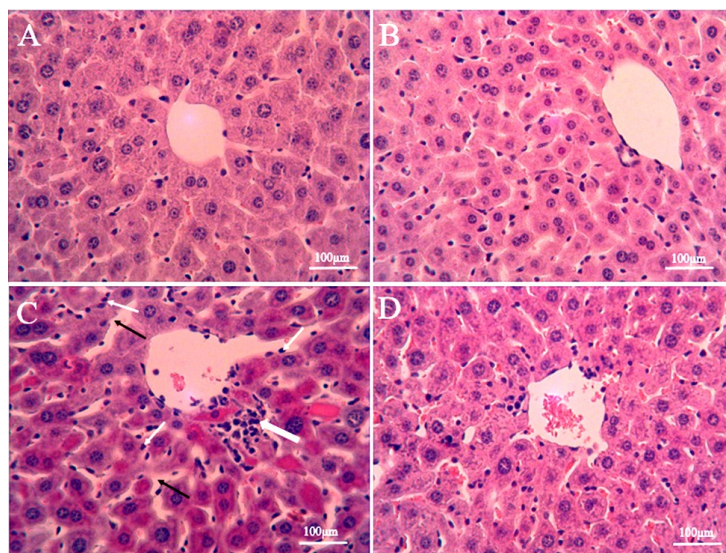


Figure 2. Photomicrographs show the effect of Melatonin and RF-EMR treatment on the histological architecture of liver in the groups. Control (A), melatonin (B), RF-EMR (C) and melatonin + RF-EMR (D). Normal structure can be seen in control and melatonin groups. Liver tissue in the RF-EMR group showed Kupffer cells proliferation (white narrow arrow), the sinusoidal dilation (Thin white arrow), and the inflammatory cell infiltration (Thick white arrow) were seen in liver tissue of mice exposed to RF-EMR. Mice that received RF-EMR with melatonin, liver structure was preserved to a large amount. H & E staining with a magnification of 40 ×, scale bar = 100µm. RF-EMR: Radiofrequency Electromagnetic radiation

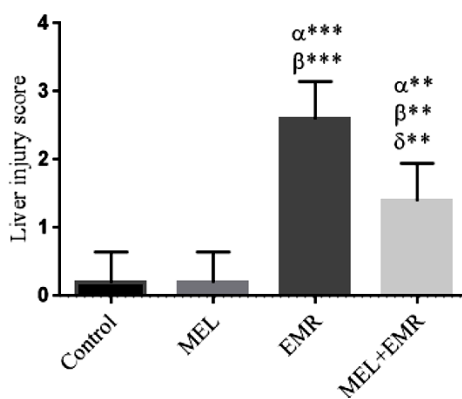


Figure 3. Histogram shows liver injury score. All values were expressed as mean ± SD. α significant vs the control, β significant vs the melatonin and γ significant vs the RF-EMR groups. **, P < 0.01, ***, P < 0.001). MEL: Melatonin, RF-EMR: Radiofrequency Electromagnetic Radiation.

DISCUSSION

The liver is one of the most important and vital organs. In the current study, RF-EMR induced oxidative stress and increased lipid peroxidation. Increasing the oxidative stress parameters leads to severe damage to the liver tissue structure. This damage was confirmed by increasing liver enzymes (ALT, AST, and ALP). The level of oxidative stress markers, liver enzymes, and liver tissue structure has been greatly improved by the administration of

melatonin as an antioxidant.

The results of our study showed that a GSM mobile phone device with 900-1800 MHz wavelength could induced oxidative stress by increasing MDA and reducing GSH. Many studies have shown that the biological effects of RF-EMR on tissues are induced by oxidative stress. The release of free radicals plays a role in the mechanism of the adverse effects of radiation. RF-EMR through free radicals and with their effect on the cell membrane, increase lipid peroxidation and reduce the level of

antioxidants, thus cause oxidative stress in the biological systems of the body ⁽¹⁹⁾. MDA is a marker of oxidative stress and lipid peroxidation is as a marker of free radical damage to the cell membrane, since free radicals cause peroxidation of unsaturated fatty acids ⁽²⁰⁾. Dasdag and colleagues have shown in their study that MDA level increased in rats exposed to radiofrequency radiation with a wavelength of 900 MHz, but no significant changes were observed in catalase, myeloperoxidase, and total antioxidant capacity. Also, they revealed electromagnetic waves led to liver damage by increasing NO as the main source of oxidative stress marker ⁽²¹⁾. Çiğ and colleagues, in *in vitro* study, have shown that RF-EMR from mobile phones and WI-FI waves can induce high levels of oxidative stress and apoptosis. They have shown that these waves through an effect on calcium signaling and transient receptor potential vanilloid 1 channel (TRPV1) involved in the induction of heat, ROS production, and accumulation of intracellular calcium ions ⁽²²⁾. Esmekaya and colleagues also have shown that radiofrequency radiations with 900 MHz wavelength for 3 weeks and 20 minutes per day could increase MDA level and reduce the amount of GSH in the liver, lung, testis and heart tissue ⁽¹⁹⁾. Irmak and colleagues in his study showed that the RF-EMR from 900MHz mobile phones in rabbit model increases oxidative stress markers and reduces endogenous antioxidants ⁽²³⁾. In the present study, we showed that the exposure to 900 MHz RF-EMR could increase MDA levels. The high levels of MDA confirm the peroxidation of the lipid membrane of the liver cells. On the other hand, in this study, the levels of GSH in the liver tissue were reduced in mice exposed to RF-EMR. GSH is an endogenous antioxidant in tissues that is able to scavenge free radicals by having hydroxyl groups ⁽²⁴⁾.

Francisco and co-worker in their study reported that the use of antioxidants could protect individuals from oxidative and inflammatory damage caused by RF-EMR ⁽²⁵⁾. Koyu and colleagues 2005 revealed that rats exposed to waves of 1800 MHz leading to liver tissue damage along with oxidative stress. They have shown that Caffeic acid phenethyl ester

(CAPE) with antioxidant properties improves oxidative stress markers ⁽²⁶⁾. The protective effect of melatonin was seen on the brain ⁽¹¹⁾ and heart ⁽²⁷⁾ damage induce by RF-EMR. It has also been shown in several studies that melatonin protects liver damage induced by oxidative stress ⁽²⁸⁻³⁰⁾. Mariam Chahbouni and colleagues in their study showed that melatonin has a beneficial effect on the level of aminotransferases (ALT, AST, and LDH) in patients with muscular dystrophy By inhibiting lipid peroxidation and inflammation (interleukins, TNF- α and interleukin-gamma) ⁽³¹⁾. Also, Gülüna Erdem Koç and co-workers reported that melatonin was significantly improved number of pyramidal cells in the hippocampus in newborns rats that exposed to RF-EMR during pregnancy ⁽³²⁾. Ozguner and colleagues showed that mobile RF-EMR for half an hour for 60 days increase oxidative stress markers and reduce endogenous antioxidants. In their study, they also showed that melatonin at a dose of 100 $\mu\text{g}/\text{kg}$ could reduce oxidative damage to retinal tissue ⁽³³⁾. Our study also found that an RF-EMR with a wavelength of 900MHz was associated with severe damage of liver tissue, and this damage was directly related to oxidative stress. Reiter showed that animals that receive radiations due to reduced oxidative stress, melatonin is more absorbed into the tissues ⁽³⁴⁾. Also, in another study, administration of melatonin before and after exposure to radiation could reduce the harmful effects of RF-EMR with the effect on the lifetime of free radicals ⁽³⁵⁾.

The most common wavelength of the modulated GSM signals on the phone is a wavelength of 900-1800 MHz and WI-FI with a wavelength of 2450 MHz, and the severity of the damage caused by RF-EMR waves depends on the time and frequency of use ⁽³⁶⁾. RF-EMR cause changes in the concentration of polyunsaturated fatty acid and DNA damage, resulting in damage to the tissue structure of the liver. Rats exposed to microwave with 2.45 GHz wavelengths (power density, 0.2 mW / cm²) for 35 days (two hours in per day) showed increase in lipid peroxidation with histopathologic damage in the liver tissue ⁽³⁷⁾. Histopathological findings in this

study showed proliferation of kupffer cell and proliferation inflammatory cells around the portal region, eosinophilic cytoplasm and granulomatous formation. Melatonin neutralizes the toxic effects of ROS by producing N1-acetyl-N2-formyl-5-methoxykynuramine (AFMK) (38). Also, melatonin with embedding in the superficial part of the lipid cell membrane protects them from the damage induced by free radicals (39). Furthermore, melatonin due to its antioxidant properties is able to protect the DNA of nucleotide and mitochondria, lipids of the membrane, and cytosolic proteins against oxidative damage (40). In this study, we showed that melatonin could greatly improve the damage caused by radiations.

The loss of balance between peroxidants and antioxidants and oxidative stress has a major role in inducing histopathologic damage (41). RF-EMR with varying concentrations of polyunsaturated fatty acids and DNA damage causes damage to the liver tissue structure (42). Ragy and co-worker in their study showed that animals that were exposed with RF-EMR for two months (an hour a day) increased ALT and AST levels. One month after discontinuation of radiation, they showed that these changes were modified again (43). Also, Fatma and colleagues showed that rats exposed to radiation (for 2 months, 3 days in per week) increase liver enzymes activity and levels of MDA and H₂O₂ and decrease their anti-oxidants levels such as GSH and CAT in the liver tissue (44). Unlike our results and the above researchers, Achudume and colleagues stated rats that were continuously exposed to RF-EMR at 900MHz for two months decrease the level of liver enzymes. They stated that this reduction is due to liver dysfunction (45). Chauhan and colleagues have shown that rats exposed to 2.45 GHz microwave wavelengths and (power density, 0.2 mW / cm²) for 35 days per day 2 hours, induced lipid peroxidation and subsequently histopathological damage in the liver tissue (37).

Finally, we showed in this study that the use of a mobile device significantly interrupts oxidative and inflammatory conditions in healthy mice. Our results also showed that the use of melatonin could protect the liver injury

induced by RF-EMR through antioxidant properties. However, this is a preliminary study and considering that people are usually exposed to RF-EMR for a long time in their lives, it is better to be reviewed further studies with longer durations and at different distances relative to the body surface.

ACKNOWLEDGMENTS

This research was supported by the Student Research Committee and Molecular and Cell Biology Research Center, Faculty of Medicine, Mazandaran University of Medical Sciences, Sari, Iran (IR.MAZUMS.REC.1398.081).

Conflicts of interest: Declared none.

REFERENCES

1. Ragy M (2015) Effect of exposure and withdrawal of 900-MHz-electromagnetic waves on brain, kidney and liver oxidative stress and some biochemical parameters in male rats. *Electromagn Biol Med*, **34(4)**:279-84.
2. Fatma AA, M El-Gendy Samir, A Zahkouk Nomaan, A El-Tahway, Sawsan, A El-Shamy (2015) Ameliorative Effect of Two Antioxidants on The Liver of Male Albino Rats Exposed to Electromagnetic Field. *The Egyptian Journal of Hospital Medicine*, **58**:74-93.
3. Karolina Sieroń-Stożny JP, Grzegorz Cieślak, Aleksander Sieroń (2017) Influence of Electromagnetic Fields on Prooxidant/Antioxidant Balance in Rat Liver. *Pol J Environ Stud*, **26(1)**:279-85.
4. MNaYM YW (1997) Enhancement Mice Exposed of Lipid Peroxidation to Magnetic Fields in the Liver of mice exposed to magnetic field. *Industrial Health*, **35**: 285-90.
5. Song JK, Lee SM, KM Lee JE (2015) The protective effect of melatonin on neural stem cell against LPS-induced inflammation. *Biomed Res Int*, **85**: 43-59.
6. Djordjevic BK, Veljkovic G, Despotovic A, Basic M, Jevtovic-Stoimenov JT, et al. (2015) The effect of melatonin on the liver of rats exposed to microwave radiation. *Bratisl Lek Listy*, **116(2)**: 96-100.
7. Russel JR, Dun-Xian Tan, and Annia Galano (2014) Melatonin reduces lipid peroxidation and membrane viscosity. *Andrologia*, **46(1)**: 65-72.
8. Oksay TN, M. Doğan, S. Güzel, A. Gümral, N. Koşar, PA (2005) Protective effects of melatonin against oxidative injury in rat testis induced by wireless (2.45 GHz) devices. *Arch Med Res*, **36(4)**: 350-5.

9. Oktem FO, Mollaoglu F, Koyu H A (2015) Oxidative damage in the kidney induced by 900-MHz-emitted mobile phone: protection by melatonin. *Curr Med Chem*, **22(22)**: 2690-711.
10. Ozguner FB and Y Comlekci S (2006) Protective effects of melatonin and caffeic acid phenethyl ester against retinal oxidative stress in long-term use of mobile phone: a comparative study. *Mol Cell Biochem*, **282(1-2)**:83-8.
11. Nazıroğlu M, Çelik Ö, Özgül C, Çiğ B, Doğan S, Bal R, et al. (2012) Melatonin modulates wireless (2.45 GHz)-induced oxidative injury through TRPM2 and voltage gated Ca²⁺ channels in brain and dorsal root ganglion in rat. *Physiology & behavior*, **105(3)**: 683-92.
12. Dusan Sokolovic BD GK, Tatjana J. Stoimenov, Zoran Stanojkovic, Danka M, et al. (2015) The Effects of melatonin on oxidative stress parameters and DNA fragmentation in testicular tissue of rats exposed to microwave radiation. *Adv Clin Exp Med*, **24(3)**:429-36.
13. Taysi S, Koc M, Büyükokuroğlu ME, Altınkaynak K, Şahin YN (2003) Melatonin reduces lipid peroxidation and nitric oxide during irradiation-induced oxidative injury in the rat liver. *Journal of pineal research*, **34(3)**: 173-7.
14. Djordjevic B, Sokolovic D, Kocic G, Veljkovic A, Despotovic M, Basic J, et al. (2015) The effect of melatonin on the liver of rats exposed to microwave radiation. *Bratislavske lekarske listy*, **116(2)**: 96-100.
15. Djordjevic B SD, Kocic G, Veljkovic A, Despotovic M, Basic J, Jevtovic-Stoimenov T, Sokolovic DM (2015) The effect of melatonin on the liver of rats exposed to microwave radiation. *Bratisl Lek Listy* **116(2)**: 96 – 100.
16. Dusan Sokolovic BD, Gordana K, Tatjana J Stoimenov, Zoran S, Danka M Sokolovic, Andrej V, Goran R, Milena D, Dusan MBF, Radmilo J, Ivana B (2015) The effects of melatonin on oxidative stress parameters and DNA fragmentation in testicular tissue of rats exposed to microwave radiation. *Adv Clin Exp Med*, **24(3)**: 429–36.
17. Karimi S, Hosseinimehr SJ, Mohammadi HR, Khalatbary AR, Talebpour Amiri F(2018) Zataria multiflora ameliorates cisplatin-induced testicular damage via suppression of oxidative stress and apoptosis in a mice model. *Iranian Journal of Basic Medical Sciences*, **21(6)**: 607-14.
18. Hamzeh M, Hosseinimehr SJ, Khalatbary AR, Mohammadi HR, Dashti A, Talebpour Amiri F (2018) Atorvastatin mitigates cyclophosphamide-induced hepatotoxicity via suppression of oxidative stress and apoptosis in rat model. *Research in Pharmaceutical Sciences*, **13(5)**: 440-9.
19. Esmekaya MA, Ozer C, Seyhan N (2011) 900 MHz pulse-modulated radiofrequency radiation induces oxidative stress on heart, lung, testis and liver tissues. *Gen Physiol Biophys*, **30(1)**: 84-9.
20. Ayala A, Muñoz MF, Argüelles S (2014) Lipid peroxidation: production, metabolism, and signaling mechanisms of malondialdehyde and 4-hydroxy-2-nonenal. *Oxidative Medicine and Cellular Longevity*, Volume 2014, Article ID 360438, 31 pages. <http://dx.doi.org/10.1155/2014/360438>
21. Dasdag S, Bilgin H, Akdag M, Celik H, Aksen F (2008) Effect of long term mobile phone exposure on oxidative-antioxidative processes and nitric oxide in rats. *Biotechnology & Biotechnological Equipment*, **22(4)**: 992-7.
22. Çiğ B and Nazıroğlu M (2015) Investigation of the effects of distance from sources on apoptosis, oxidative stress and cytosolic calcium accumulation via TRPV1 channels induced by mobile phones and Wi-Fi in breast cancer cells. *Biochimica et Biophysica Acta (BBA)-Biomembranes*, **1848(10)**: 2756-65.
23. Irmak MK, Fadılloğlu E, Güleç M, Erdoğan H, Yağmurca M, Akyol Ö (2002) Effects of electromagnetic radiation from a cellular telephone on the oxidant and antioxidant levels in rabbits. *Cell Biochemistry and Function*, **20(4)**: 279-83.
24. Zhang M, Zhang H, Li H, Lai F, Li X, Tang Y, et al. (2016) Antioxidant mechanism of betaine without free radical scavenging ability. *Journal of Agricultural and Food Chemistry*, **64(42)**: 7921-30.
25. Ortiz F, Fernández-Gil BI, Guerra-Librero A, López LC, Acuña-Castroviejo D, Escames G (2016) Preliminary evidence suggesting that nonmetallic and metallic nanoparticle devices protect against the effects of environmental electromagnetic radiation by reducing oxidative stress and inflammatory status. *European Journal of Integrative Medicine*, **8(5)**: 835-40.
26. Koyu A, Nazıroglu M, Ozguner F, Ramazan Yilmaz H, Uz E, Cesur G (2005) Caffeic acid phenethyl ester modulates 1800 MHz microwave-induced oxidative stress in rat liver. *Electromagnetic Biology and Medicine*, **24(2)**:135-42.
27. Gumral N, Saygin M, Asci H, Uguz A, Celik O, Doguc D, et al. (2016) The effects of electromagnetic radiation (2450 MHz wireless devices) on the heart and blood tissue: role of melatonin. *Bratislavske lekarske listy*, **117(11)**: 665-71.
28. Hermoso DAM, Shimada LBC, Gilgioni EH, Constantin J, Mito MS, Hermoso APM, et al. (2016) Melatonin protects female rats against steatosis and liver oxidative stress induced by oestrogen deficiency. *Life sciences*, **157**: 178-86.
29. Chen Y, Qing W, Sun M, Lv L, Guo D, Jiang Y (2015) Melatonin protects hepatocytes against bile acid-induced mitochondrial oxidative stress via the AMPK-SIRT3-SOD2 pathway. *Free Radical Research*, **49(10)**:1275-84.
30. Wang D, Wei Y, Wang T, Wan X, Yang CS, Reiter RJ, et al. (2015) Melatonin attenuates (-)-epigallocatechin-3-gallate-triggered hepatotoxicity without compromising its down-regulation of hepatic gluconeogenic and lipogenic genes in mice. *Journal of Pineal Research*, **59(4)**: 497-507.
31. Chahbouni M, Escames G, Venegas C, Sevilla B, García JA, López LC, et al. (2010) Melatonin treatment normalizes plasma pro-inflammatory cytokines and nitrosative/oxidative stress in patients suffering from Duchenne muscular dystrophy. *Journal of Pineal Research*, **48(3)**: 282-9.
32. Erdem Koç G, Kaplan S, Altun G, Gümüş H, Gülsüm Deniz Ö, Aydın I, et al. (2016) Neuroprotective effects of melatonin and omega-3 on hippocampal cells prenatally exposed to 900 MHz electromagnetic fields. *International Journal of Radiation Biology*, **92(10)**: 590-5.
33. Ozguner F, Bardak Y, Comlekci S (2006) Protective effects of melatonin and caffeic acid phenethyl ester against retinal oxidative stress in long-term use of mobile phone: a

- comparative study. *Molecular and Cellular Biochemistry*, **282(1-2)**: 83-8.
34. Reiter RJ, Tan DX, Poeggeler B, Kavet R (1998) Inconsistent suppression of nocturnal pineal melatonin synthesis and serum melatonin levels in rats exposed to pulsed DC magnetic fields. *Bioelectromagnetics: Journal of the Bioelectromagnetics Society, The Society for Physical Regulation in Biology and Medicine, The European Bioelectromagnetics Association*, **19(5)**: 318-29.
 35. Lai H and Singh NP (1997) Melatonin and a spin-trap compound block radiofrequency electromagnetic radiation-induced DNA strand breaks in rat brain cells. *Bioelectromagnetics*, **18(6)**: 446-54.
 36. Nazıroğlu M, Çiğ B, Doğan S, Uğuz AC, Dilek S, Faouzi D (2012) 2.45-Gz wireless devices induce oxidative stress and proliferation through cytosolic Ca²⁺ influx in human leukemia cancer cells. *International Journal of Radiation Biology*, **88(6)**: 449-56.
 37. Chauhan P, Verma H, Sisodia R, Kesari KK (2017) Microwave radiation (2.45 GHz)-induced oxidative stress: Whole-body exposure effect on histopathology of Wistar rats. *Electromagnetic Biology and Medicine*, **36(1)**: 20-30.
 38. Arnao M (2013) Growth conditions determine different melatonin levels in *Lupinus albus* L. *J Pineal Res*, **55(2)**:149-55.
 39. Reiter RT and DX Galano A (2014) Melatonin reduces lipid peroxidation and membrane viscosity. *Front Physiol*, **6(5)**: 337.
 40. Baydas GCT A. (2002) Comparative analysis of the protective effects of melatonin and vitamin E on streptozocin-induced diabetes mellitus. *J Pineal Res*, **32(4)**: 225-30.
 41. Cichoż-Lach H and Michalak A (2014) Oxidative stress as a crucial factor in liver diseases. *World Journal of Gastroenterology: WJG*, **20(25)**: 8082.
 42. Furtado-Filho OV, Borba JB, Dallegrave A, Pizzolato TM, Henriques JA, Moreira JC, et al. (2014) Effect of 950 MHz UHF electromagnetic radiation on biomarkers of oxidative damage, metabolism of UFA and antioxidants in the livers of young rats of different ages. *International Journal of Radiation Biology*, **90(2)**:159-68.
 43. Ragy MM (2015) Effect of exposure and withdrawal of 900-MHz-electromagnetic waves on brain, kidney and liver oxidative stress and some biochemical parameters in male rats. *Electromagnetic Biology and Medicine*, **34(4)**: 279-84.
 44. Fatma AE, Ahkam M, Samir AZ, Nomaan A, Sawsan A (2015) Ameliorative effect of two antioxidants on the liver of male albino rats exposed to electromagnetic field. *Egyptian Journal of Hospital Medicine*, **58**: 74-93.
 45. Achudume A, Onibere B, Nwoha P, Alatise O, Aina F (2012) Effects of radiation emitted from base stations on bilirubin, transaminases and lipid peroxidation in exposed rats. *Energy and Environment Research*, **2(1)**: 115.

