Volume 18, No 3 | International Journal of Radiation Research, July 2020

Effects of adrenomeduline and ramp2 on the lung of mice exposed to total body radiation

M.K. Ozbilgin[1*], G.Z. Karaman[1], S. Gencur[1], E. Gumustepe[2], C. Kurtman[2]

[1]*Department of Histology and Embryology, Celal Bayar University School of Medicine, Manisa, Turkey*
[2]*Department of Radiation Oncology, Ankara University School of Medicine, Ankara, Turkey*

► ***Original article***

Corresponding authors:
Mahmut Kemal Ozbilgin, MD,
E-mail:
kemalozbilgin@yahoo.com

Revised: June 2019
Accepted: August 2019

Int. J. Radiat. Res., July 2020; 18(3): 571-578

DOI: 10.18869/acadpub.ijrr.18.3.571

ABSTRACT

Background: Adrenomedullin (AM) and its receptor, receptor activity-modifying protein (RAMP) 2 have pleiotropic regulatory functions in normal tissue and cancer tissue. AM is produced and secreted both numerous stromal cells and tumor cells. This study aims to investigate a possible role of AM and RAMP2 in the radiation exposure in the normal lung tissue. ***Materials and Methods:*** Four groups with 6 male adult Swiss Albino mice per group were investigated. The mice were subjected to a 500 cGy single-dose radiation exposure in the total body radiation device and lung tissues were collected. 1, 2, and 7 days after radiation exposure, with 1 reference group which was not exposed to radiation. ***Results:*** The general histology and the immunohistochemistry of the tissue samples prepared with anti- AM, anti–RAMP2, and monoclonal antibodies were investigated, yielding a statistically significant increase for AM on day 3 and for RAMP2 on day 1 after radiation exposure. ***Conclusion:*** The observed increase of AM and RAMP2 concentrations in the normal tissue matrix after radiation exposure may play a role in the side effects of radiotherapy.

Keywords: *AM, RAMP2, radiation, lung, carcinogens.*

INTRODUCTION

Radiotherapy is widely used for cancer treatment in order to eliminate malignant cells. however, it also causes major health hazards in the normal tissues, so it calls as a double-edged sword [1]. Although the irradiation may lead to the cancer cells die, the complete effects of the radiotherapy on the nearby normal tissue, especially in the microenvironment of the cancer tissue, are not yet fully understood. The tumor microenvironment enables and supports neoplastic cells to acquire adaptive benefits from the surrounding environment, including the infiltrating tumor-associated immune cells, vasculature and fibroblasts.

There are many molecules within the tumor microenvironment such as AM which has been shown to be involved in tumor survival and progression by promoting cellular proliferation and angiogenesis. Adrenomedullin (AM) is a member of the calcitonin peptide superfamily, such as the calcitonin gene-related peptide, and first isolated from human pheochromocytoma [2]. It is a circulating hormone and functions also as a local paracrine and autocrine mediator with multiple biological activities such as natriuretic [3], diuretic [4] bronchodilator effect [5], regulation of brain functions[6] and anti-inflammatory, anti-oxidative, anti-fibrotic properties [7]. AM is also involved in many human pathologies and also cancer. AM levels in many cancer patients such as a bronchial neuroendocrine tumor were increased compared with healthy patients [8].

Receptor activity-modifying protein 2 (RAMP2) is a single-pass transmembrane protein that heterodimerizes with several family B G-protein coupled receptors to alter their function. RAMP2 has been primarily characterized in association with calcitonin

[Downloaded from ijrr.com on 2026-11-23]

[DOI: 10.18869/acadpub.ijrr.18.3.571]

receptor-like receptor (Calcrl, CLR), forming the canonical receptor complex for the endocrine peptide AM [9]. RAMP2 has been identified as an essential mediator of cardiovascular homeostasis. Conversely, the overexpression of RAMP2 suppresses tumor cell adhesion to endothelial cells, tumor metastasis, and improved survival [10]. RAMP2 causes vascular abnormalities and is embryonically lethal. Early after the induction, pronounced edema with enhanced vascular leakage occurred. AM-RAMP2 system causes the disruption of actin formation, leading to vascular and organ damage at the chronic stage after the gene deletion [11]. In adult RAMP2+/- mice, reduced RAMP2 expression led to vascular hyperpermeability and impaired neovascularization. Conversely, endothelial cells overexpressing RAMP2 had enhanced capillary formation, firmer tight junctions, and reduced vascular permeability [12]. The vascular endothelial adrenomedullin-RAMP2 system is essential for the vascular integrity and organ homeostasis[11]. Deletion of RAMP2 in mice results in massive cutaneous edema and mid-gestational death[13] and hemorrhage in animals [12].

In this study, we investigated the changes of AM and RAMP2 expression in the lung tissue on day 1,3 and 7 days after 500 cGy single-dose radiation exposure.

MATERIALS AND METHODS

The study was approved by the Animal Ethical Committee of the faculty of Medical Medicine affiliated to Ankara University and was conducted in accordance with the recommendations outlined in Guidelines for Care and Use of Experimental Animals. A total of 24 healthy male adult Swiss Albino mice, weighing 30–40 g each, were obtained from Ankara University Experimental Animal Laboratory and used as subjects. The subjects were isolated from stress and noise and fed with water and food ad libitum at 25°C in a cycle of 12 hours of dark and 12 hours of light before being included in the study. The animals were divided into 4 groups as control group (no radiotherapy), group 1 (24 hours later, after radiotherapy), group 2 (72 hours later, after radiotherapy) and group 3 (7 days later, after radiotherapy). Except for the 6 subjects in the control group, mice were exposed to whole body ionizing radiation at the same day with the device present in the Department of Radiation Oncology of Ankara University School of Medicine, whole body irradiation applied with a source-to-axis distance of 100 cm and anterior 250 cGy and posterior 250 cGy; total 500 cGy dose in a single fraction. This radiation treatment dose could make lung injury[14]. For obtaining sedation before the procedure, intramuscular ketamine injection at a dose of 45 –50 mg/kg was performed. The animals were sacrificed, which are control group and on day 1, 3 and 7 after radiotherapy and thorax region was dissected and lungs were completely removed. All lung samples were first washed in a solution containing 10% formol and then placed in screw-cap sampling containers containing 10% formol, with separate boxes used for every animal. The tissue samples taken after the procedure were embedded into paraffin following the routine light microscopy paraffin tissue method at the Department of Histology and Embryology of Celal Bayar University School of Medicine. Slides of 5 µm were evaluated with the indirect immunohistochemistry method.

Immunohistochemistry

Formalin-fixed, paraffin-embedded sections were used for immunohistochemical staining. Tissue samples were stored at 60°C overnight and then dewaxed with xylene for 30 minutes. After dehydration of the sections with ethanol, they were washed with distilled water. Subsequently, the samples were treated with 2% trypsin (ab970; Abcam, Cambridge, UK) at 37°C for 15 minutes and incubated in 3% H2O2 solution for 15 minutes to inhibit endogenous peroxidase activity. Then the sections were incubated with anti–adrenomedulline primary antibody (sc-1414; Santa Cruz, California) in a 1/100 dilution and anti-RAMP2 Polyclonal (Catalogue No. AR5423; Boster Biological Technology Ltd., China) for 18 hours at +4°C. They were then given an additional 3 times for 5

[Downloaded from ijrr.com on 2026-11-23]

[DOI: 10.18869/acadpub.ijrr.18.3.571]

-minute washes in phosphate-buffered saline (PBS), followed by incubation with biotinylated IgG and administration of streptavidin peroxidase (Histostain Plus kit, Zymed 87-9999; Zymed, San Francisco, California, USA). After washing the secondary antibody with PBS 3 times for 5 minutes, the sections were stained with diaminobenzidine (DAB) (DAB, K007; DBS, Pleasanton, California, USA) to detect the immunoreactivity, and then stained with Mayer's hematoxylin (72804E; Microm, Walldorf, Germany) for counterstaining. They were covered with a mounting medium (01730; Surgipath, Cambridge, UK) and observed with light microscopy (Olympus BX-40, Tokyo, Japan).

Immunostaining for AM and RAMP2 were evaluated semi-quantitatively using H-score analysis. The immunostaining intensity was categorized by the following scores: 0 (no staining), 1 (weak, but detectable, staining), 2 (moderate staining), and 3 (intense staining). H-score value was derived for each specimen by calculating the sum of the percentage of cells for lung cells that stained at each intensity category multiplied by its respective score, using the formula H-score = Σ Pi (i+ 1), where *i* is the intensity of staining with a value of 1, 2, or 3 corresponding to weak, moderate, or strong staining, respectively, and Pi is the percentage of stained cells for each intensity, varying from 0 to 100%. For each slide, 5 different fields were evaluated microscopically at 200× magnification. H-score evaluation was performed independently by at least 2 investigators blinded to the source of the samples as well as to each other's results; the average score of both was then used.

Statistical analysis

For the statistical analysis, we used the software SPSS 19.0 (IBM SPSS Statistics). The numerical variables are given with mean, standard deviation, median, minimum, and maximum values. The Shapiro-Wilk test was used for the normality tests. One-way ANOVA tests were used for comparisons between the 4 groups for parametric variables, and the Tukey test was used for post-hoc tests. Additionally, we used the Kruskal-Wallis test for comparisons between the 4 groups for non- parametric variables and the Mann-Whitney U test with Bonferroni correction for post-hoc tests. Statistical comparisons with a p value < 0.05 are assumed as statistically sign ificant. This research was approved by the local institutional review board.

RESULTS

Histochemical Hematoxylin-eosin (HE) staining of the lung showed that alveolar epithelium composed of two type cells. Type I alveolar cells are extremely very squamous cells, and Type II alveolar cells are secretory cells which are cuboidal in shape. We observed the interstitium of the lung was found between the capillaries and the alveolar space and composed of minimal connective tissue matrix, fibroblasts, and inflammatory cells such as macrophages. There aren't any significant differences between these groups (figure 1).

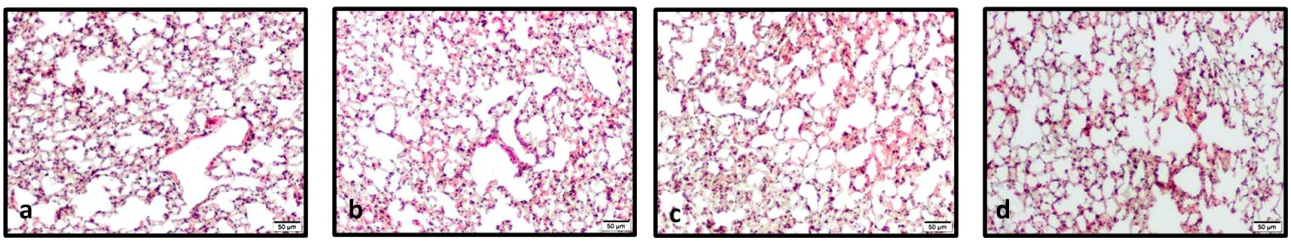

Figure 1. H&E staining on the lung of mice exposed to radiation. There isn't any histological difference among the groups. Control **(a)**, at the 24 hours **(b)**, at the 72 hours **(c)**, and on the 7th day **(d)**.

[Downloaded from ijrr.com on 2026-11-23]

[DOI: 10.18869/acadpub.ijrr.18.3.571]

In the observing of lung tissues by immunohistochemically, anti-AM antibody positivity was seen in the stroma and endothelial cells of vessels. The concentration of AM immunoreactivity peaked in the 3rd (278,8 ± 11,06) day, however, AM expression was very high on day 1 (119,2 ± 11,54) compared to the control group (59,92 ± 5,094). Moreover, immunoreactivity has decreased on the 7th day (31,67 ± 7,368) (table 1, figures 2 and 3).

We observed RAMP2 immunoreactivity in the lung parenchyma of the control group (40,08 ± 5,478) (table 1). In the radiation group, the value for RAMP2 immunoreactivity was significantly higher in the radiation groups (respectively 206,7 ± 10,03), group 2 (137,1 ± 7,869) and group 3 (61,67 ± 6,667) compared with the control group (table 1 and figures 2 and 4). However, the H-score values was similar among the radiation groups (table 1 and figure 2).

Table 1. H-score values of AM and RAMP2 in Lung

	Control group	Group1 (24 hours later)	Group2 (72 hours later)	Group3 (7 days later)
AM	59,92 ± 5,094	119,2 ± 11,54 **	278,8 ± 11,06***	31,67 ± 7,368**
RAMP2	40,08 ± 5,478	206,7 ± 10,03***	137,1 ± 7,869**	61,67 ± 6,667

(** p < 0.01; *** p < 0.001)

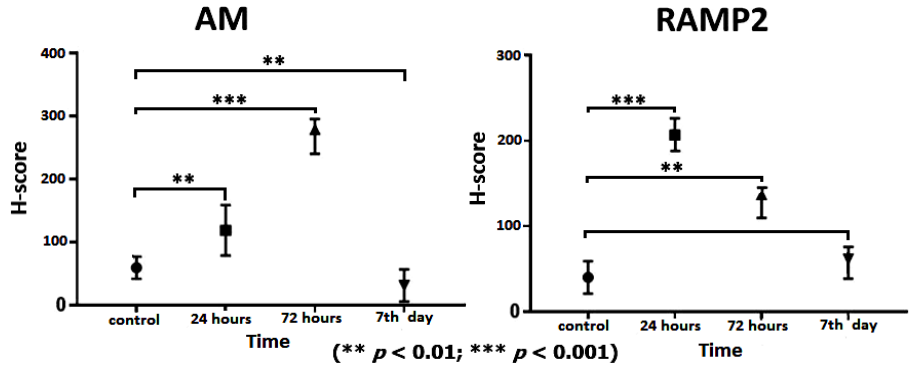

Figure 2. Quantitative assessment of the density in cells that stained positive for AM and RAMP2 was conducted for the lung using H-score. The values shown represent the means ± standard error of the mean.

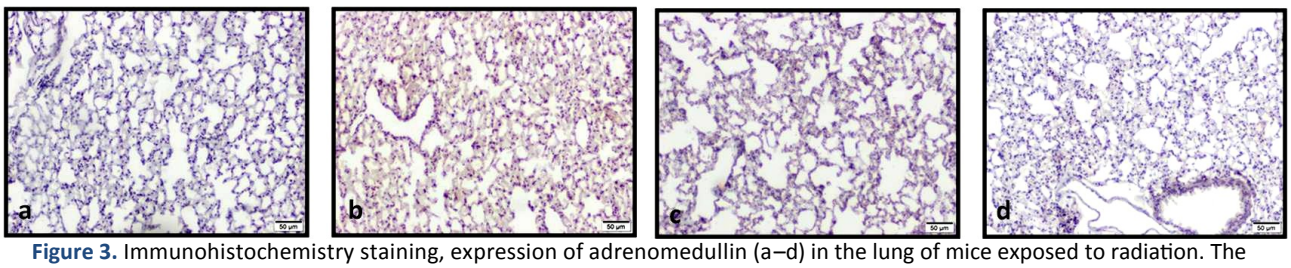

Figure 3. Immunohistochemistry staining, expression of adrenomedullin (a–d) in the lung of mice exposed to radiation. The greatest immunoreactivity of adrenomedullin was observed at the 72 hours (mean ± SE; 278,8 ± 11,06***) **(c)**, as compared to control (mean ± SE; 59,92 ± 5,094) **(a)**, the 24 hours (mean ± SE; 119,2 ± 11,54**) **(b)**, and 7th day (mean ± SE; 31,67 ± 7,368**) **(d)**. (** p < 0.01; *** p < 0.001)

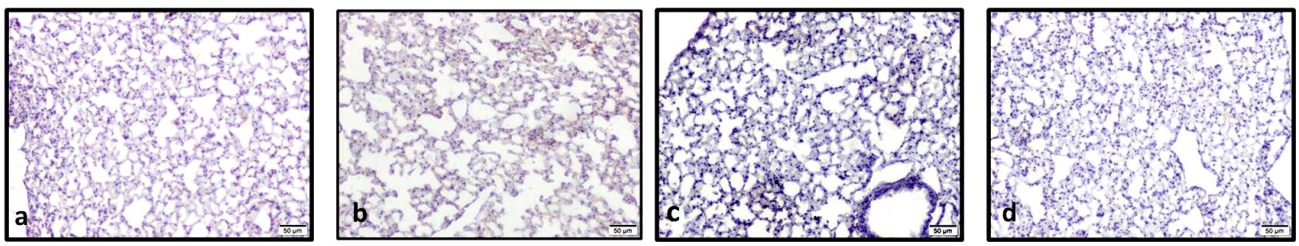

Figure 4. Immunohistochemistry staining, expression of RAMP2 (a–d) in the lung of mice exposed to radiation. The greatest immunoreactivity of RAMP2 was observed at the 24 hours (mean ± SE; 206,7 ± 10,03***) **(b)**, as compared to control (mean ± SE; 40,08 ± 5,478) **(a)**, the 72 hours (mean ± SE; 137,1 ± 7,869**) **(c)**, and 7th day (mean ± SE; 61,67 ± 6,667) **(d)**. (** p < 0.01; *** p < 0.001)

[Downloaded from ijrr.com on 2026-11-23]

[DOI: 10.18869/acadpub.ijrr.18.3.571]

DISCUSSION

Radiotherapy is often used worldwide as an essential modality for cancer therapy. Radiation also affects not only the cancer cells but also both tumor surrounding normal tissue and tumor microenvironment where various pathologic pathways carried out in there, such as hypoxia, extracellular matrix (ECM) remodeling, angiogenesis/vasculogenesis and immune suppression/evasion. In our previous studies, we reported that radiation exposure may initiate angiogenesis, inflammation and changing ECM component in different tissues [15–17]. Here we discuss the expression of AM and RAMP2 in the irradiated lung tissue, to clarified the effects on radiotherapy in tumor surrounding normal tissue and tumor microenvironment.

AM is a ubiquitous regulatory peptide with several biologic functions, such as angiogenesis, growth-stimulating effects, and immune-modulating activity. AM has been shown to be expressed in both a variety of human tumors (such as small cell lung cancer, adenocarcinoma, bronchoalveolar carcinoma, squamous cell carcinoma, lung carcinoids, ganglioblastoma and neuroblastoma) [18,19] and the tumor microenvironment [20]. It is known that AM is a proangiogenic factors and is a HIF1-dependent vasoactive target gene that modifies tissue perfusion by increasing vascular endothelial growth factor (VEGF) expression [21] and promote proliferation and migration of endothelial cells [22]. Overexpression of AM enhances vascular density and directed growth of blood vessels in pancreatic and breast cancer xenografts and also adrenomedullin antagonist suppresses *in-vivo* growth of human pancreatic cancer cells in SCID mice by suppressing angiogenesis [23].

In this study, it has been found that AM increased in the acute period (24 and 72 hours later) at irradiated lung tissues compared to the control group. This results probably in response to the inflammatory effect of the radiation in the acute phase. It's known that, AM production is mostly regulated by oxidative stress and inflammation-related substances such as lipopolysaccharide and inflammatory cytokines (tumor necrosis factor alpha (TNF-α) and interleukin-1 (IL-1)) and also AM contains nuclear factor-Kβ (NF-Kβ) sites for promotion [24]. Radiation causes the inflammation activation of mitogen activated protein kinase (MAPK) family members, which are JNK, p38, and extracellular signal related kinase (ERK1/2). Depending on cell type, inflammatory cytokines may regulate ERK1/2 signaling to protect irradiated tumor cells by activating pro-survival DNA-repair pathways such as ERCC1, XRCC1, and XPC and interacting with the ataxia telangiectasia mutated (ATM) pathway[25]. AM activates three main signaling pathways which are cAMP, Akt and MAPK-ERK. The signaling pathways also has important role to carries out the radiation effects.

AM is stimulated the cell migration and tube formation in angiogenesis in vitro models and supply necessary nutrients and oxygen to the tumor cells to grow[26]. Hence, we observed the increase of AM expression in lung tissue due to radiation exposure and claimed that radiotherapy may be related with to promote the angiogenesis in the stroma. However, the role of the AM in the cancer angiogenesis is not clear completely. It was reported that the overexpressing AM cause the increase in blood vessel density in the human endometrial, breast, lung or pancreatic tumor cell lines, in contrast to this, there are few studies claimed that, AM resulted in blood vessel density reduction in the colorectal, prostate, and renal carcinoma cells[20]. In addition of these, it was known that, radiation has been reported to increase tumor microvessel density and tumor satellite formation in animal models, thereby enhancing the risk of tumor recurrence and metastasis[27].

AM is able to reduce apoptosis of tumor cells and is also called a potent apoptotic inhibitor. Antiapoptotic effects of the AM were reported for many cancer types (endometrial tumor cells, prostate cancer cells, or breast carcinoma cells)[20]. The antiapoptotic effects related with reduced levels of proapoptotic proteins such as fragmented PARP, Bax, and activated caspases[28]. We observed that AM was overexpressed in the lung in the response of radiation on day 1 and 3. However, the up-regulation of AM in the lung tissue after radiation may protect against apoptosis and could be detrimental to the treatment of cancer patients. Similar results were reported for human keratinocytes that low-dose irradiation causes co-activation of ATM, MEK/ERK, and NF-κB pathways to promote survival through influx/activation of immune cells and anti-inflammatory cytokines in the tumor microenvironment[29] and also lymph node carcinoma of the prostate (LNCaP) cancer cells, NF-κB is activated after the irradiation and give rise to overexpression of procaspases molecules via the TNF -α/FAS pathway[30]. Low-dose irradiated tissues cause to release VEGF via mast cells that mediate angiogenesis/vasculogenesis by altering the microenvironment via MMP-9[31].

[Downloaded from ijrr.com on 2026-11-23]

[DOI: 10.18869/acadpub.ijrr.18.3.571]

We also detected the high AM expression of lung tissue in the radiation group until the 3rd day after the one application. Since AM is involved in tumor initiation and progression by promoting cell proliferation, angiogenesis, change of phenotype, and the inhibition of apoptosis [10], one moderate dose radiation application lead to increase the AM expression until 3 days. It may be dangerous for the patient because radiation therapy generally uses for 21 days. It was reported that AM plays a role in influencing the tumor microenvironment to promote tumorigenesis in bone [32]. Ouafik *et al* demonstrate that inhibition of the action of AM using a polyclonal antibody specific to AM may suppress tumor growth and the density of vessels in human glioblastomas[33].

RAMP2 is one of the AM receptors supply to specificity for AM signalling and AM–RAMP2 system is essential for angiogenesis and vascular homeostasis [34]. In the control group, RAMP2 immunoreactivity was seen in minimal level in the lung tissue. It was reported that RAMP2 and RAMP2 mRNA are found in the adult lung tissue, even in the embryonic development, and the expressions of the proteins in the lung may be related to the function of AM in lung angiogenesis and alveolar development [35].

We observed that the RAMP2 immunoreactivity increased in the acute period especially at 24 hours after rat irradiated lung tissues compared to the control group. This result probably in response to the inflammatory effect of the radiation in the acute phase. RAMP2 upregulation shown as a response to pro-inflammatory cytokines vascular permeability and EndMT-like change within primary lesions and formation of pre-metastatic niches in distant organs by destabilizing the vascular structure and inducing inflammation[10]. We observed that the RAMP2 expression is decreased on day 3 compared to day 1 in the irradiated lung tissues. The marked reduction of RAMP2 expression should be contributed to the elevation of AM immunoreactivity reported that RAMP2 mRNA (0.8 kb) were predominantly expressed in the lung, but RAMPs transcription levels in the lungs suppressed at 12 h later in the LPS-induced sepsis model [36]. It's considered the RAMP2 system regulates vascular integrity, RAMP2 deletion leads to systemic edema and also may promote exacerbation of metastasis [36]. The deletion of RAMP2 from endothelial cells suppressing the growth of locally transplanted tumors by reducing tumor angiogenesis was reported [10].

RAMP2 is expressed in various human cancer cells and can stimulate autocrine mechanisms likely to cause neoplastic proliferation [18]. We have detected that the level of RAMP2 is still high on the 7th day. It is thought that RAMP2 is effective in the acute and chronic phase. In human cells and in mice demonstrate that RAMP2 is a key determinant of the effects of AM on the vasculature and is essential for angiogenesis and vascular integrity [11]. The AM-RAMP2 system is a key determinant of vascular integrity and homeostasis from prenatal stages through adulthood [12].

The increase of AM-RAMP2 which are induce angiogenesis and suppress the apoptosis may be initiation tumor formation and progression so, the reduction of the AM-RAMP2 system is necessary to diminish the radiation effects in the microenvironment of normal tissue and cancer tissue. All these data taken together support the idea that, the AM-RAMP2 system has an important role in the radiation area or tumor microenvironment and the AM-RAMP2 system could be followed to prevent from radiation detrimental side effects and can use the therapeutic target for suppressing tumor metastasis.

***Conflicts of interest*:** *Declared none.*

REFERENCES

1. Hei TK, Zhou H, Ivanov VN, Hong M, Lieberman HB, Brenner DJ, Amundson SA, Geard CR (2008) Mechanism of radiation-induced bystander effects: a unifying model. *J Pharm Pharmacol*, ***60****: 943–950*.
2. Kitamura K, Kangawa K, Kawamoto M, Ichiki Y, Nakamura S, Matsuo H, Eto T (1993) Adrenomedullin: A Novel Hypotensive Peptide Isolated from Human Pheochromocytoma. *Biochem Biophys Res Commun, **192**: 553–560*.
3. Jougasaki M, Wei CM, Aarhus LL, Heublein DM, Sandberg SM, Burnett JC (1995) Renal localization and actions of adrenomedullin: a natriuretic peptide. *Am J Physiol Physiol*, ***268****: F657–F663*.
4. Ebara T, Miura K, Okumura M, Matsuura T, Kim S, Yukimura T, Iwao H (1994) Effect of adrnomedullin on renal hemodynamics and functions in dogs. *Eur J Pharmacol, **263****: 69–73*.
5. Kanazawa H, Kurihara N, Hirata K, Kudoh S, Kawaguchi T, Takeda T (1994) Adrenomedullin, a Newly Discovered Hypotensive Peptide, Is a Potent Bronchodilator. *Biochem Biophys Res Commun, **205****: 251–254*.
6. Takahashi H, Watanabe TX, Nishimura M, Nakanishi T, Sakamoto M, Yoshimura M, Komiyama Y, Masuda M, Murakami T (1994) Centrally Induced Vasopressor and Sympathetic Responses to a Novel Endogenous Peptide, Adrenomedullin, in Anesthetized Rats. *Am J Hypertens, **7****:*

[Downloaded from ijrr.com on 2026-11-23]

[DOI: 10.18869/acadpub.ijrr.18.3.571]

478–482.
7. Brain SD and Grant AD (2004) Vascular actions of calcitonin gene-related peptide and adrenomedullin. *Physiol Rev,* ***84****: 903–934*.
8. Pavel M and Georg HE (2006) Adrenomedullin is a novel marker of tumor progression in neuroendocrine carcinomas. *Horm Metab Res,* ***38****: 112–118*.
9. Kadmiel M, Matson BC, Espenschied ST, Lenhart PM, Caron KM (2017) Loss of receptor activity-modifying protein 2 in mice causes placental dysfunction and alters PTH1R regulation. *PLoS One*, ***12****: e0181597*.
10. Tanaka M, Koyama T, Sakurai T, Kamiyoshi A, Ichikawa-Shindo Y, Kawate H, Liu T, Xian X, Imai A, Zhai L, *et al.* (2016) The endothelial adrenomedullin-RAMP2 system regulates vascular integrity and suppresses tumour metastasis. *Cardiovasc Res,* ***111****: 398–409*.
11. Koyama T, Ochoa-Callejero L, Sakurai ; Takayuki, Kamiyoshi A, Yuka Ichikawa-Shindo, Iinuma N, Arai T, Yoshizawa T, Iesato Y, Lei Y, *et al.* (2013) Vascular Endothelial Adrenomedullin-RAMP2 System is Essential for Vascular Integrity and Organ Homeostasis. *Circulation,* ***127****: 842–853*.
12. Ichikawa-Shindo Y, Sakurai T, Kamiyoshi A, Kawate H, Iinuma N, Yoshizawa T, Koyama T, Fukuchi J, Iimuro S, Moriyama N, *et al.* (2008) The GPCR modulator protein RAMP2 is essential for angiogenesis and vascular integrity. *J Clin Invest,* ***118****: 29–39*.
13. Fritz-Six KL, Dunworth WP, Li M, Caron KM (2008) Adrenomedullin signaling is necessary for murine lymphatic vascular development. *J Clin Invest,* ***118****: 40–50*.
14. Soni S, Basu M, Agrawal P, Kumar N, Bhatnagar A, Chhillar N (2016) Multiple parametric approaches to assess acute radiation lung injury of rats. *Ukr Biochem J,* ***88****: 22–30*.
15. Ozbilgin MK, Onal T, Ozcan C, Temel M, Aktas C, Gareveran MS, Uluer ET, Inan S, Kurtman C (2016) Effects of Cyclooxygenase on the Urothelium of the Urinary Bladder of Mice Exposed to Pelvic Radiation. *Anal Quant Cytopathol Histopathol,* ***38****: 103–110*.
16. Aktaş C, Kurtman C, Ozbilgin MK, Tek I, Toprak SK (2013) An experimental study of radiation effect on normal tissue: analysis of HIF-1α, VEGF, eIF2, TIA-1, and TSP-1 expression. *Turkish J Haematol Off J Turkish Soc Haematol,* ***30****: 371–378*.
17. Ozbilgin MK, Aktas C, Uluer ET, Buyukuysal MC, Gareveran MS, Kurtman C (2016) Influence of radiation exposure during radiotherapy. Evidence for the Increase of Versican and Heparin-Binding EGF-like Growth Factor Concentrations. *Anal Quant Cytopathol Histopathol,* ***38****: 126–132*.
18. Martinez A, Miller MJ, Unsworth EJ, Siegfried JM, Cuttitta F (1995) Expression of adrenomedullin in normal human lung and in pulmonary tumors. *Endocrinology,* ***136****: 4099–4105*.
19. Satoh F, Takahashi K, Murakami O, Totsune K, Sone M, Ohneda M, Abe K, Miura Y, Hayashi Y, Sasano H (1995) Adrenomedullin in human brain, adrenal glands and tumor tissues of pheochromocytoma, ganglioneuroblastoma and neuroblastoma. *J Clin Endocrinol Metab,* ***80****: 1750–1752*.
20. Larráyoz IM, Martínez-Herrero S, García-Sanmartín J, Ochoa-Callejero L, Martínez A (2014) Adrenomedullin and tumour microenvironment. *J Transl Med,* ***12****: 339*.
21. Iimuro S, Shindo T, Moriyama N, Amaki T, Niu P, Takeda N, Iwata H, Zhang Y, Ebihara A, Nagai R (2004) Angiogenic effects of adrenomedullin in ıschemia and tumor growth. *Circ Res,* ***95****: 415–423*.
22. Miyashita K, Itoh H, Sawada N, Fukunaga Y, Sone M, Yamahara K, Yurugi T, Nakao K (2003) Adrenomedullin promotes proliferation and migration of cultured endothelial cells. *Hypertens Res*, ***26****: S93–S98*.
23. Ishikawa T, Chen J, Wang J, Okada F, Sugiyama T, Kobayashi T, Shindo M, Higashino F, Katoh H, Asaka M, *et al.* (2003) Adrenomedullin antagonist suppresses *in-vivo* growth of human pancreatic cancer cells in SCID mice by suppressing angiogenesis. *Oncogene*, ***22****: 1238–1242*.
24. Hinson JP, Kapas S, Smith DM (2000) Adrenomedullin, a Multifunctional Regulatory Peptide. *Endocr Rev,* ***21****: 138–167*.
25. Golding SE, Rosenberg E, Neill S, Dent P, Povirk LF, Valerie K (2007) Extracellular signal-related kinase positively regulates ataxia telangiectasia mutated, homologous recombination Repair, and the DNA damage response. *Cancer Res,* ***67****: 1046–1053*.
26. Smith RS, Gao L, Bledsoe G, Chao L, Chao J (2009) Intermedin is a new angiogenic growth factor. *Am J Physiol Circ Physiol,* ***297****: H1040–H1047*.
27. Gandhi S and Chandna S (2017) Radiation-induced inflammatory cascade and its reverberating crosstalks as potential cause of post-radiotherapy second malignancies. *Cancer Metastasis Rev,* ***36****: 375–393*.
28. Zhou P-H, Hu W, Zhang X-B, Wang W, Zhang LJ (2016) Protective effect of adrenomedullin on rat leydig cells from lipopolysaccharide-ınduced ınflammation and apoptosis via the PI3K/Akt Signaling Pathway ADM on Rat Leydig Cells from Inflammation and Apoptosis. *Mediators Inflamm,* ***2016****: 1–16*.
29. Ahmed KM, Nantajit D, Fan M, Murley JS, Grdina DJ, Li JJ (2009) Coactivation of ATM/ERK/NF-κB in the low-dose radiation-induced radioadaptive response in human skin keratinocytes. *Free Radic Biol Med,* ***46****: 1543–1550*.
30. Kimura K and Gelmann EP (2002) Propapoptotic effects of NF-κB in LNCaP prostate cancer cells lead to serine protease activation. *Cell Death Differ,* ***9****: 972–980*.
31. Heissig B, Rafii S, Akiyama H, Ohki Y, Sato Y, Rafael T, Zhu Z, Hicklin DJ, Okumura K, Ogawa H, *et al.* (2005) Low-dose irradiation promotes tissue revascularization through VEGF release from mast cells and MMP-9-mediated progenitor cell mobilization. *J Exp Med*, ***202****: 739–750*.
32. Martínez A (2002) Biology of adrenomedullin. *Microsc Res Tech,* ***57****: 1–2*.
33. Ouafik L, Sauze S, Boudouresque F, Chinot O, Delfino C, Fina F, Vuaroqueaux V, Dussert C, Palmari J, Dufour H, *et al.* (2002) Neutralization of adrenomedullin ınhibits the growth of human glioblastoma cell lines *in- vitro* and suppresses tumor xenograft growth *in-vivo*. *Am J Pathol,* ***160****: 1279–1292*.
34. Yamauchi A, Sakurai T, Kamiyoshi A, Ichikawa-Shindo Y,

[Downloaded from ijrr.com on 2026-11-23]

[DOI: 10.18869/acadpub.ijrr.18.3.571]

Kawate H, Igarashi K, Toriyama Y, Tanaka M, Liu T, Xian X, *et al.* (2014) Functional differentiation of RAMP2 and RAMP3 in their regulation of the vascular system. *J Mol Cell Cardiol* **77**: 73–85.

35. Vadivel A, Abozaid S, van Haaften T, Sawicka M, Eaton F, Chen M, Thébaud B (2010) Adrenomedullin promotes lung angiogenesis, alveolar development, and repair. *Am J Respir Cell Mol Biol,* ***43****: 152–160*.
36. Ono Y, Okano I, Kojima M, Okada K, Kangawa K (2000) Decreased gene expression of adrenomedullin receptor in mouse lungs during sepsis. *Biochem Biophys Res Commun,* ***271****: 197–202*.

[Downloaded from ijrr.com on 2026-11-23]

[DOI: 10.18869/acadpub.ijrr.18.3.571]