

Rectification of radiation-induced damage in swiss albino mice by *aloe vera* leaf extracts (AVE)

P. Gehlot and P.K. Goyal*

Radiation and Cancer Biology Laboratory, Department of Zoology, Rajasthan University, Jaipur 302 004, India

Background: From the time immemorial man has been exposed to ionizing radiation from the environment in which he lives. Radiation protection concepts and philosophy have been evolving over the past several decades. **Materials and Methods:** The radioprotective effect of *Aloe vera* leaf extract (1000 mg/kg b.wt. orally for 15 consecutive days) has been studied against 6 Gy of gamma radiation in the intestine of Swiss albino mice at various post-irradiation intervals viz. 12 hrs, 24 hrs. and 3, 5, 10, 20 and 30 days. **Results:** Crypt survival, villus length, apoptic cells, mitotic figures and goblet cells in jejunum were studied after irradiation. Irradiation produced a significant decrease in crypt survival, mitotic figures and villus length; whereas goblet and apoptic cells showed a significant increase from sham irradiated animals. The major changes were observed on day 3 after irradiation. AVE pre-treated irradiated animals resulted in a significant increase in the number of crypt cells, mitotic figures and villus length; whereas the counts of apoptic and goblet cells showed a significant decrease from respective control group at all the autopsy intervals. Irradiated animals resulted in the elevation in lipid peroxidation and a reduction in glutathione activity. On contrary, AVE treatment before irradiation caused a significant depletion in lipid peroxidation and elevation in glutathione activity. **Conclusion:** The present study suggests the possible radioprotective ability of *Aloe vera* leaf extract. Iran. J. Radiat. Res., 2007; 5 (2): 71-78

Keywords: *Aloe vera*, Swiss albino mice, LPO, GSH, gamma irradiation.

INTRODUCTION

The twentieth century has experienced an increasing use of nuclear energy in medical, engineering, industrial and scientific research and for generation of electricity. Such uses have raised the problem of radiation hazards to living beings. The deleterious effects of radiation can now be strategically counterpoised by the use of many drugs and chemicals. Similar type of chemical protection against radiation-induced changes have been also observed

with AET, herbal preparation like Liv.52, WR-2721, Mentha, Panax Ginseng and melatonin⁽¹⁻⁶⁾. The use of plants and natural products may be beneficial in protecting against the radiation-induced damage, as they are less toxic or practically non-toxic than the synthetic compounds at their optimum protective doses.

Herbal medicine is still the mainstay of about 75-80% of the world population, mainly in the developing countries, for primary health care because of better cultural acceptability, better compatibility with the human body and lesser side effects

One such popularly known and used plant is *Aloe vera barbadensis* belonging to family Liliaceae and consists of about more than 250 species. It is commonly called "Guar-patha" or Ghee-Kuar. It is rich in vitamin A, E, C and Zinc and Selenium⁽⁷⁻⁹⁾. It is reported to have antioxidant, anti-tumor and anti-inflammatory activities. The intestine is one of the most rapidly renewing tissues in the body and hence it responds rapidly to injury. The damage to the gut is of particular primary concern in cytotoxic therapies involving radiation exposure or chemical agents and in accidental cases of radiation release (e.g. Chernobyl). The small intestine represents one of the major dose normal limiting tissues in radiotherapy because of its high sensitivity to radiation.

The present investigation has been made to assess the radioprotective efficacy of *Aloe vera* leaf extract in the intestine of Swiss albino mice.

*Corresponding author:

Dr. P.K. Goyal, Radiation and Cancer Biology Laboratory, Department of Zoology, Rajasthan University, Jaipur 302 004, India.

Fax: +97 141 2742309

E-mail: pkgoyal2002@rediffmail.com

MATERIALS AND METHODS

Animal care and handling

The animal care and handling was done according to the guidelines set by World Health Organization, Geneva, Switzerland and INSA (Indian National Science Academy, New Delhi, India). The departmental animal ethical committee approved this study. Swiss albino mice (*Mus musculus*), 6-8 weeks old with body weight of 24 ± 2 gm, from an inbred colony were used for the present study. These animals were maintained under controlled conditions of temperature and light (light: dark, 10hrs:14 hrs.). Four animals were housed in a polypropylene cage containing sterile paddy husk (procured locally) as bedding throughout the experiment. They were provided standard mice feed (procured from Hindustan Levers Ltd., India) and water ad libitum. Tetracycline water once a fortnight was given as preventive measures against infections.

Irradiation: mice were irradiated by ^{60}Co source in the cobalt teletherapy unit (ATC-C9) at radiation oncology department, Sawai Man Singh Medical College and Hospital, Jaipur, India. The mice were kept in ventilated box with a distance of 77.5 cm from the source to deliver a dose rate of 0.99 Gy min^{-1} .

Plant material: Aloe leaves were collected locally during the whole year. The Aloe vera plant was identified by the curator at the Herbarium of Botany, University of Rajasthan, and Jaipur, India. (RUBL Number19886)

AV Extract: To prepare aqueous extract, fresh shade dried leaves of *Aloe vera* powdered and refluxed with double distilled water (DDW) for 36 hours at 40°C and vacuum evaporated so as to get in powder form. The powder of extract was redissolved in DDW just before oral administration.

Experimental design: Mice were randomly divided into following groups (five per Group per interval):

Group I: Normal / sham-irradiated mice were given distilled water (DDW) through oral gavage once in a day for 15 consecutive

days.

Group II: Mice were treated with 1000 mg/kg body weight of AV dried extract dissolved in distilled water through oral gavage for 15 consecutive days.

Group III: Mice were given distilled water for 15 days and then exposed to 6 Gy dose of gamma radiation. This group served as positive control.

Group IV: Extract of *Aloe vera* was given 1000 mg/kg body weight of mouse orally for 15 days and after 30 min. of last dose; they were exposed to 6 Gy dose of gamma radiation. Following various treatments, mice were autopsied by cervical dislocation on days 12 hrs, 24 hrs, 3, 5, 10, 20 and 30 days. Intestine were surgically removed and fixed in Bouin's fluid. The tissue was embedded in paraffin block after dehydrating with increasing concentrations of 70, 90 and 100% ethanol. Five micrometer sections were cut using hand microtome, were placed on glass slide and were stained with Harris hematoxyline and Eosin. Stained tissue sections were observed under light microscope to determine histopathological changes.

Biochemical parameters

Glutathione (GSH) Assay: GSH in tissue and blood was measured using the method described by Moron *et al.* ⁽¹⁰⁾.

Lipid peroxidation (LPO) Assay: LPO levels in tissue and blood were estimated by the method of Ohkawa *et al.* as thiobarbituric acid (TBA) reactive substances ⁽¹¹⁾.

RESULTS

General

Animals of 6 Gy irradiation resulted in radiation sickness within 10 days after exposure. The symptoms included reduction in food and water intake, diarrhea, lethargy, emaciation, epilation and ruffling of hairs. Daily administration of the AVE for 15 consecutive days did not cause any radiation-induced mortality. AVE administration delayed the appearance and radiation

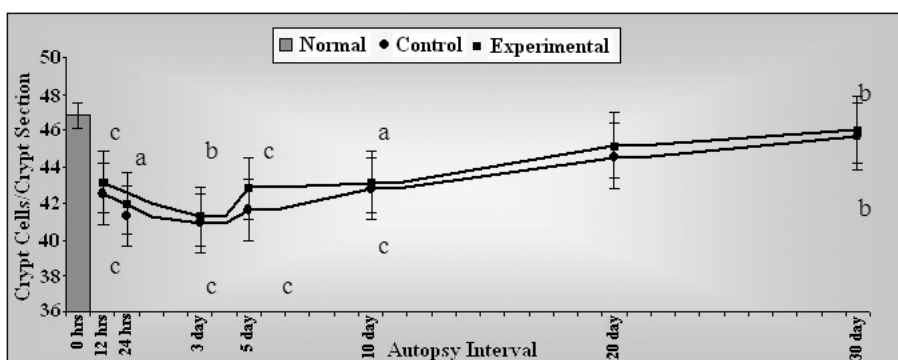


Figure 1. Variations in number of crypt cells/crypt in Swiss albino mice after exposure to 6 Gy gamma radiation with (Experimental) or without (Control) *Aloe vera* leaf extract (AVE). Significance level; Normal vs. Control, Control vs. Experimental
 $a_p \leq 0.05$, $b_p \leq 0.005$, $c_p \leq 0.001$

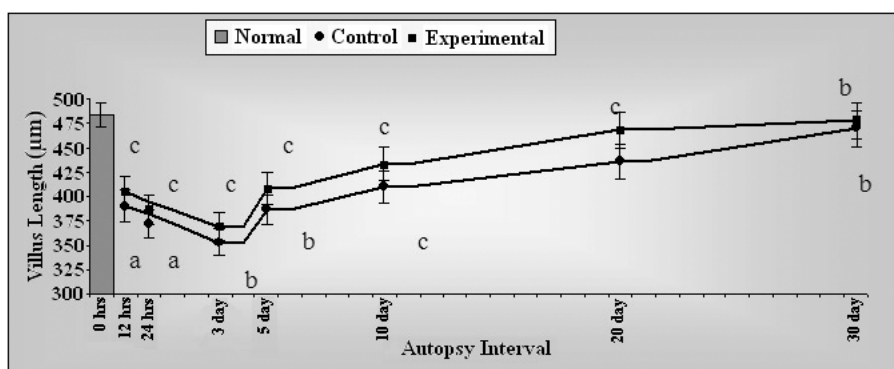


Figure 2. Variations in villus length (μm) in Swiss albino mice after exposure to 6 Gy gamma radiation with (Experimental) or without (Control) *Aloe vera* leaf extract (AVE). Significance level; Normal vs. Control, Control vs. Experimental
 $a_p \leq 0.05$, $b_p \leq 0.005$, $c_p \leq 0.001$

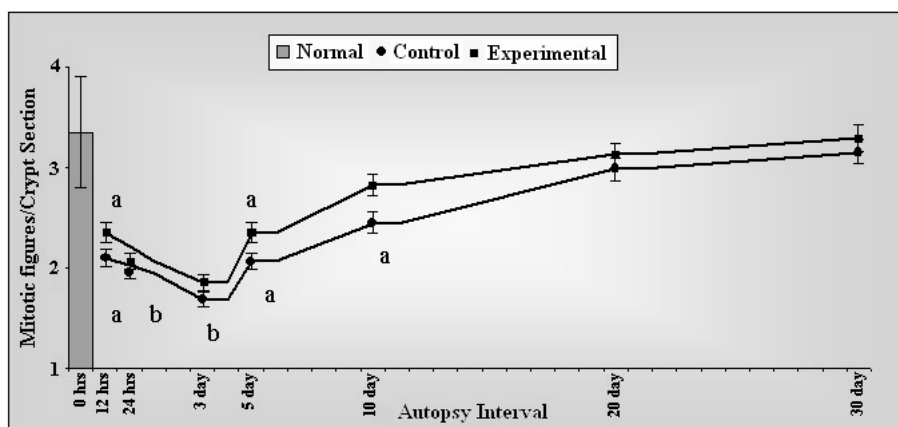


Figure 3. Variations in mitotic figures/crypt in Swiss albino mice after exposure to 6 Gy gamma radiation with (Experimental) or without (Control) *Aloe vera* leaf extract (AVE). Significance level; Normal vs. Control, Control vs. Experimental
 $a_p \leq 0.05$, $b_p \leq 0.005$, $c_p \leq 0.001$

sickness like reduction in diarrhoea, irritability, lethargy and food and water intake.

Intestinal parameters

Crypt cells/ crypt section

On 3rd day maximum decrease was observed in the number of crypt cells in both control and experimental groups. Day 5th onwards, there was an increase in the number of cells in the animals of both the groups. In control, these cells could not attain the normal value even till the last autopsy interval; whereas in experimental, the number of crypt cells were found within normal range (figure 1).

Villus length

The maximum reduction in the villus height was recorded on day 3rd in both control and experimental groups. At later intervals, mucosa exhibited the sign of recovery that was observed in the form of an increase in height of villi in these groups. In experimental group, recovery from lesions was faster and almost a normal length was measured on day 20th with a significant difference to control (figure 2).

Mitotic figures/ Crypt section

The frequency of such figure was reduced to nearly half in comparison to normal on 24 hrs. Post-irradiation. The maximum decrease was evident on day 3 post-treatment in both control and experimental groups. It was followed by an increase in number on day 5th

with a continuous elevation till the end of the experimental, but in control it could not reach the normal level; whereas in experimental, these figures were counted almost normal (figure 3).

Apoptotic cells/ crypt section

The maximum number of dead cells was noticed on day 3rd after irradiation in both control and experimental groups, but afterwards the number of these cells decreased progressively with the advent of post-irradiation time (figure 4).

Goblet cells / villus section

A significant increase in the number of goblet cells was observed in both the groups on day 1. From day 3rd, these cells started to decrease till the last autopsy interval. the number of goblet cells was found to be still higher and did not reach normal level even on 20th day in control animals; whereas in the experimental, these cells were scored almost normal (figure 5).

Biochemical determinants

Lipid peroxidation (LPx) and Glutathione (GSH) Estimations: No significant alteration in the intestinal, hepatic and blood GSH contents were observed between normal and AVE treated animals. However, a statistically significant ($p < 0.001$) decrease in GSH was evident in control animals. Experimental animals showed a significant increase in GSH content (blood, liver & intestine) with

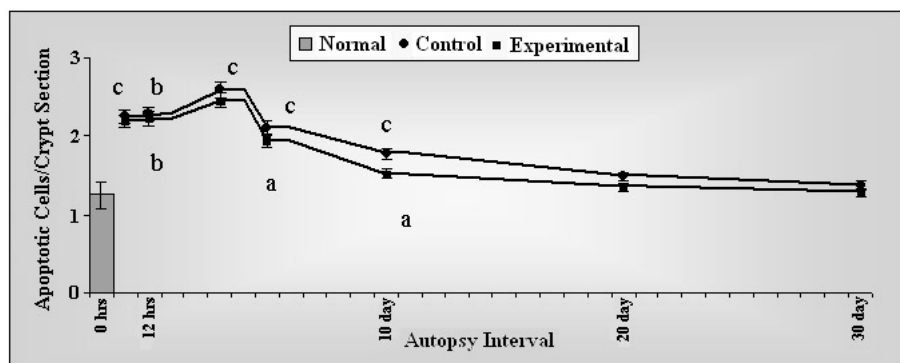


Figure 4. Variations in apoptotic cells/crypt in Swiss albino mice after exposure to 6 Gy gamma radiation with (Experimental) or without (Control) Aloe vera leaf extract (AVE). Significance level; Normal vs. Control, Control vs. Experimental

^a $p \leq 0.05$, ^b $p \leq 0.005$, ^c $p \leq 0.001$

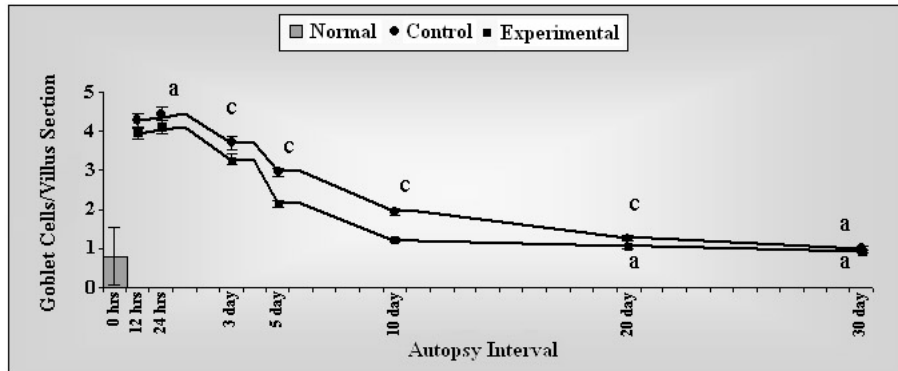


Figure 5. Variations in number of goblet cells / villus in Swiss albino mice after exposure to 6 Gy gamma radiation with (Experimental) or without (Control) *Aloe vera* leaf extract (AVE). Significance level; Normal vs. Control, Control vs. Experimental
^a $p \leq 0.05$, ^b $p \leq 0.005$, ^c $p \leq 0.001$

respect to control but the values remained below normal (figure 6). Administration of AVE alone before irradiation did not alter the lipid peroxidation. Exposure of animals to

gamma radiation increased LPx in group III while the same was significantly reduced in the AVE + irradiation group (figure 7).

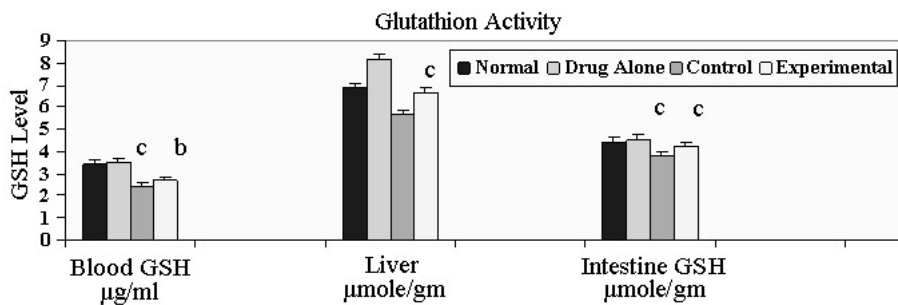


Figure 6. Glutathione (GSH) level in Swiss albino mice after exposure to 6 Gy gamma radiation in the presence (Experimental) or absence (Control) of *Aloe vera* leaf extract (AVE). Significance level; Normal vs. Control, Control vs. Experimental
^a $p \leq 0.05$, ^b $p \leq 0.005$, ^c $p \leq 0.001$

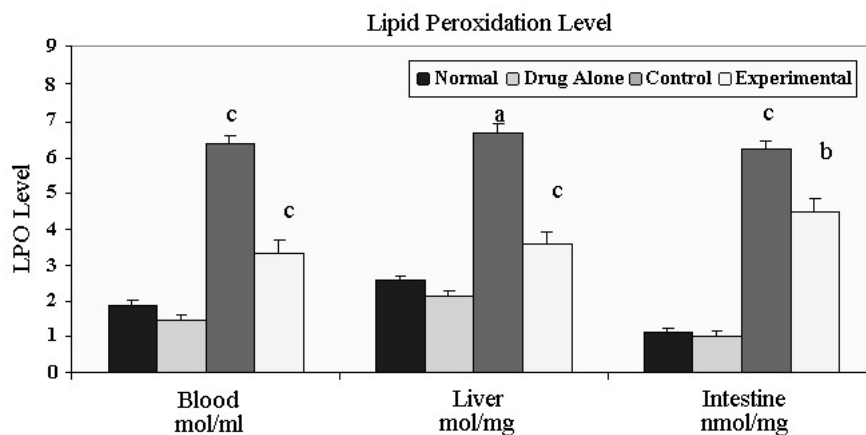


Figure 7. Lipid peroxidation (LPO) level in Swiss albino mice after exposure to 6 Gy gamma radiation in the presence (Experimental) or absence (Control) of *Aloe vera* leaf extract (AVE). Significance level; Normal vs. Control, Control vs. Experimental
^a $p \leq 0.05$, ^b $p \leq 0.005$, ^c $p \leq 0.001$

DISCUSSION

In the present study, after exposure to 6 Gy gamma radiations to animals resulted in radiation sickness within 3-5 days after exposure. The symptoms included reduction in the food and water intake, weight loss, diarrhoea, ruffling of hairs and irritability. The similar symptoms have been observed in mice after gamma irradiation by others also ^(12, 13).

The gastro-intestinal tract is a cell renewal system and consisting of cells with different radiosensitivity. According to Withers and Elkind, crypt cells are more sensitive than villus epithelial cells as indicated by the presence of more severe radiopathological lesions in crypts than those of villi at early intervals and this difference can be explained with the help of the law of Bergonie and Tribondeau ^(14, 15). Reduction in villus height and crypt cell population, suppression of mitosis and increase in number of goblet and dead cells were the major pathological changes after exposure to 6 Gy of gamma rays in the intestinal mucosa in this study.

In the present study, the maximum decrease in the number of crypt cells was noticed on day 3 in the animals of control group after exposure to 6 Gy of gamma radiation. This is good accordance with the earlier studies with the same animal model, where observed the decreased number of these cells in crypt region after irradiation ^(16, 17). This is in concur with earlier studies that reduction in the total cell population of the crypt is due to an early and marked decline in DNA synthesis in the crypt cells, cell death and movement of cells upto villus in the absence of replacement by cellular proliferation ⁽¹⁸⁾. The decline in the number of crypt cells was due to a sharp diminution of mitotic activity in the crypts. After exposure to ionizing radiation, rapidly replicating crypt transit cells either undergo apoptosis or cease replication ⁽¹⁹⁾.

A decrease in number of mitotic figures and minimum number of such dividing cells were recorded on day 3 after irradiation when a cell is exposed to small dose of radiation between late or very early prophase and

mitosis stops or cell reverts to an early prophase ⁽²⁰⁾.

Ionizing radiation affects the cells in all the phases but degree to which these are affected is dependent on the phases (G_1 , S_1 , G_2 or M) in which they were at the time of irradiation ⁽²¹⁻²²⁾. Decline in the number of mitotic cells at early intervals may be attributing to a block of cells in G_2 phase of cell cycle and to prolongation of mitotic process ⁽²³⁾. The number of apoptotic cells /crypt section was found to be increased at the early intervals after irradiation. These cells appeared on 24 hours and their number reached to maximum on day 3rd. After this, there was a gradual decrease but it could not restore to normal level until the last autopsy interval.

The high radiosensitivity of dividing and undifferentiated cells might have attributed the death of cells in crypt region. These findings are in close agreement of Davik who suggested that most of the early mitosis contain cytological injury due to high dose and might give rise to nonviable degenerative cell ⁽²⁴⁾.

In the present study, the number of goblet cells has increased on 24 hours but there after their number declined continuously up to last autopsy interval. The elevation in glycogen content after irradiation may result in an increase in the number of goblet cells.

Villus height was found to be reduced from 24 hours and maximum reduction was noted on day 3 after exposure to gamma rays. Loss of epithelial cells from the villi is the basic reason of reduction in height. Earlier reports with same animal model also proved that *Aloe vera* is a good radioprotector against mouse intestinal mucosa after low level (0.5 Gy) exposure to gamma radiation ⁽²⁵⁾.

Administration of AVE, prior exposure to 6 Gy of gamma ray, reduced the severity of radiation induced various quantitative changes in the intestinal mucosa. Though, there was a reduction in crypt cell population, mitotic figures, villus height and increase in number of goblet and dead cells in the AVE treated irradiated animals but changes in these parameters were less pronounced as compared to that of the control

animals. Both the height and structure of the villus were less affected in AVE protected irradiated animals. This could be possible due to the less mitotic death as well as early and least migration of cells from protected crypts to villi before they become denuded.

The number of crypt cells/ crypt section in experimental animals remained at a higher level because of low cell death and increased rate of mitosis as compared to the animals of their respective control group. The results are concurs with observations of earlier studies of Prasanna and Uma Devi ⁽²⁶⁾. The higher number of mitotic figures in experimental animals than the control was in accordance with the studies of Samarth *et al.* ⁽²⁷⁾.

Glutathione is widely distributed tripeptide and found mainly in the cell cytosol ⁽²⁸⁾, which plays a crucial role in the detoxification process ⁽²⁹⁾. There exists an inverse relationship between GSH content and lipid peroxidation levels. The present study demonstrates a significant reduction in liver, blood and intestine GSH following exposure. This could be due to the enhanced utilization of the antioxidant system as an attempt to detoxify the free radicals generated by radiation. Oral administration of AVE did not significantly influence the endogenous GSH level either in liver, blood or intestine but its presence during radiation exposure protects the endogenous GSH depletion due to irradiation. The lower depletion of liver, blood and intestine GSH in *Aloe vera* pre-treated irradiated animals could be due to the high availability of GSH, which increases the ability to cope up with the free radicals produced by irradiation. The increased GSH level suggests that protection by *Aloe vera* may be mediated through the modulation of cellular antioxidants levels.

The elevated levels of lipid peroxidation in the present investigation are indicative of the oxidative damage caused by gamma radiation in intestine. Inhibition of lipid peroxidation in biomembranes can be caused by antioxidants ^(30, 31). In the present study, it was observed that *Aloe vera* pre-treated

irradiated animals exhibited a significant increase.

CONCLUSION

In previous studies, the miracle *Aloe vera* extract was found quietly healing radiation wounds in intestine effectively as antioxidant because it is rich in vitamin A (B-carotene), C and E, glutathione peroxidase (GSHPx), minerals like Zinc and Selenium. Presence of B-carotene, vitamin C and E ⁽³²⁻³⁴⁾ which goes to serve as effective antioxidants because it scavenges free radicals. The phytochemicals that is responsible for the observed effects of *Aloe vera* is far from clear although the extract contains several amino acids and vitamins like A, C and E.

There is a need to test these individual responsible substances distinctly for their ability to protect radiation -induced accumulation of free radicals, membrane damage. Our future goal is to characterize the relative role of the growth substances and vitamins in radioprotection.

ACKNOWLEDGEMENT

Authors are heartily thankful to Prof D.P. Agarwal (Head) and Dr. A.K. Chougule (RSO), Department of Radiotherapy, SMS Medical College and Hospital, Jaipur, for providing radiation facility and dosimetry respectively.

REFERENCES

1. Maisin JR (1968) Influence of a mixture of chemical protectors on the lymphopoietic and hematopoietic system of mice irradiated with a dose of 2000 R of X-rays. *Experientia*, **24**: 230-1.
2. Daga SS, Jain VK, Goyal PK (1995) Radioprotection effect of Liv.52 (a herbal preparation) against radiation induced hematological changes in mice. *Proc Nat Acad Sci India*, **65(b)**.
3. Bisht KS, Prabhu S, Uma Devi P (2000) Modification of radiation induced damage in mouse intestine by WR-2721. *Indian J Exp Biol*, **38**: 669-674.
4. Pande S, Kumar M, Kumar A (1998) Evaluation of radiomodifying effects of root extract of *Panax ginseng*.

- Phytother Res*, **12**: 13-17.
5. Samarth RM, Panwar M, Kumar M, Kumar A (2006) Radioprotective influence of *Mentha piperita* (Linn) against gamma irradiation in mice: Antioxidant and radical scavenging activity. *Int J Radiat Biol*, **82**: 331-337.
6. Monobe M, Hino M, Sumi M, Uzawa A, Hirayama R, Ando K, Kojima S (2005) Protective effects of melatonin of -ray induced intestinal damage. *Int J Radiat Biol*, **81**: 855-860.
7. Atherton P (1998) Aloe vera: magic or medicine? *Nurs stand*, **12**: 49-54.
8. Klein A and Penneys N (1988).Aloe vera. *J Amer Acad Dermatol*, **18**: 714- 719.
9. Shelton RM (1991) Aloe vera: Its chemical and therapeutic properties. *Int Dermatol*, **30**: 679-683.
10. Moron MS, Depierre JW, Mannervick B (1979) Levels of glutathione, glutathione reductase and glutathione S-transferase activities in rat lung and liver. *Biochem Biophys Acta*, **582**: 67-78.
11. Ohkhawa H, Ohishi N, Yogi K (1979) Assay for lipid peroxidation in animal tissue by thiobarbituric acid reaction. *Analyt Biochem*, **95**: 351.
12. Uma Devi P, Ganasoundari A, Rao BSS, Srinivasan KK (1999) In vivo radioprotection by *Ocimum sanctum* flavonoids : Survival of mice. *Radiat Res*, **151**: 74-78.
13. Jagetia GS and Baliga MS (2005) The effect of seasonal variation on the antineoplastic activity of *Alstonia scholaris* R. Br. In *Hela Cells. J Ethanopharmacol*, **96**: 37-42.
14. Withers HR and Elkind M (1969) Radiosensitivity and fractionation response of crypt cells of mouse jejunum. *Radiat Res*, **38**: 598-613.
15. Bergonie J and Tribondeau L (1906) Interpretation de quelques resultats de la radiotherapie et esal de fixation d'ine technique rationelle. *Compt Rend Acad. Sci*, **143**: 983.
16. Uma Devi P, Saini MR, Saharan BR, Bhartiya HC (1979) Radioprotective effect of 2-MPG on the intestinal crypt of the Swiss albino mice after Co60 irradiation. *Radiat Res*, **80**: 214-220.
17. Goel HC, Salin CA, Prakash H (2003) Protection of jejunal crypts by RH-3(a preparation of *Hippophae rhamnoides*) against lethal whole body gamma irradiation. *Phytother Res*, **17**: 222-226.
18. Baker DG and Hopper AF (1968) Crypt cell population changes in rat intestine during injury and repair after first neutron irradiation. *Radiat Res*, **34**: 555.
19. Vidrich A, Buzan JM, Barnes S, Reuter B, Skaar K, Iio C, Caminelli F, Pizarro T, Chon SM (2005) Altered epithelial cell lineage allocation and global expansion of the crypt epithelial stem cell population are associated with ileitis in SAMP1 YitFc mice. *American J Pathol*, **166**: 1055-1067.
20. Nandchahal K (1990) Crypt cell population in the murine jejunum during injury and repair after whole-body gamma-irradiation. *Radiobiology Radiother*, **31**: 337.
21. Elkind MM and Whetmore GF (1967) The radiobiology of cultured mammalian cells. Gordon and Breach Science Publishers. Inc. New York.
22. Gillette EL, Withers HR, Jannock IF (1970) The age sensitivity of epithelial cells of mouse small intestine. *Radiobiol*, **96**: 639.
23. Leshner S (1967) Compensatory reactions in intestinal crypt cells after 300 Roentgens of Cobalt-60 gamma irradiation. *Radiat Res*, **32**: 501.
24. Davik F (1968) Quantitative cellular aspects of the epithelium in the small intestine of mouse following total body irradiation: Cell death, mitosis and chromosome aberrations. In: "Effect of radiation on cellular proliferation and differentiation". IAEA, Vienna, 531.
25. Gehlot P and Goyal PK (2006) Evaluation of radioprotective efficacy of *Aloe vera* leaf extract in mouse intestinal mucosa after low level exposure to gamma radiation. *J Environ & Sociobiol*, **3**: 93-100.
26. Prasanna PGS and Uma Devi P (1971) Modification of WR-2721 radiation protection from gastrointestinal injury and death in mice by 2-mercaptopyrionylglycine. *Radiat Res*, **133**: 111.
27. Samarth RM, Saini MR, Maharwal J, Dhaka A, Kumar A (2002) *Mentha piperita* (Linn.) Leaf extract provides protection against radiation induced alterations in intestinal mucosa of Swiss albino mice. *Indian J Exp Biol*, **40**: 1245-1249.
28. Kosower NS and Kosower EM (1978) The glutathione status of the cell. *Int Rev Cytol*, **54**: 109-160.
29. Mitchell JR, Hinson JA, Nelson SD (1976) Glutathione and drug induced tissue lesions. In: *Glutathione: metabolism and Function* (Arias IM, and Jakoby WB eds.), Raven Press, New York; pp: 357-366.
30. Konnings AWT and drijver EB (1979) Radiation effect on membranes. I. Vitamin E deficiency and lipid peroxidation. *Radiat Res*, **80**: 494.
31. Konnings AWT and Osterloo SK (1979) Radiation effect on membranes. II. A comparison of the effect of X-irradiation and ozone exposure with respect to the relation of antioxidant concentration and the capacity for lipid peroxidation. *Radiat Res*, **81**: 200.
32. Sabeh I, Wright T, Norton SJ (1993) Purification and characterization of a glutathione peroxidase from the *Aloe vera* plant. *Enzyme protein*, **47**: 92-98.
33. Nikki, E (1991) Vitamin C as an antioxidant. *World reviews of nutrition and Dielectrics*, **64**: 1-30.
34. Burton GM and Ingold KV (1989) Vitamin E as *in vitro* and *in vivo* antioxidant. *Annals of the New York Academy of Sciences*. **570**: 7-22.