Volume 18, No 3 | International Journal of Radiation Research, July 2020

Volumetric-modulated arc stereotactic radiotherapy for intramedullary cervical spinal cord metastases: Report of two cases

Y. Mori*, T. Mori, K. Adachi, S. Abe, Y. Oshima, A. Takeuchi, M. Ito

Department of Radiology and Radiation Oncology, Aichi Medical University, Nagakute, Aichi, Japan

► ***Case report***

Corresponding authors:
Yoshimasa Mori, MD,
E-mail:
yoshim@aichi-med-u.ac.jp

Revised: July 2019
Accepted: August 2019

Int. J. Radiat. Res., July 2020; 18(3): 599-604

DOI: 10.18869/acadpub.ijrr.18.3.599

ABSTRACT

The treatment results of intensity-modulated stereotactic radiotherapy (IM-SRT) by volumetric-modulated arc therapy (VMAT) for intramedullary cervical spinal cord metastases (IMCSCM) in two cases were presented. ***Case 1:*** A 76-year-old woman showed left-sided motor weakness and left arm pain and dysesthesia due to IMCSCM at C [cervical] 6-7 (located a little to the left laterally) with multiple small brain metastases from thyroid carcinoma. Multiple brain metastases were successfully treated by stereotactic radiosurgery (SRS). In addition, IMCSCM was treated by IM-SRT. ***Case 2:*** A 48-year-old man presented with asymptomatic IMCSCM at C2 (located a little to the right laterally) after conventional whole brain radiotherapy (WBRT) and multiple sessions of SRS/SRT for multiple brain metastases from lung adenocarcinoma. IMCSCM was treated by IM-SRT. In both cases 39 Gy in 13 fractions (without PTV [planning target volume] margin, D95%=95% dose) was delivered to the IMCSCM (0.3 ml and 0.5 ml in volume respectively) by coplanar 2-full circular arc VMAT. The maximum dose to the tumor was 46.3 Gy in **case 1** and 47.1 Gy in **case 2**. IMCSCM in both cases shrank markedly without adverse effects during the follow-up period of 32 months and 8 months respectively. The symptoms of the extremities in **case 1** were subsided completely until the patient's death at 34 months after SRT from lung metastasis. In **case 1** IMCSCM had been thought to be a relatively radioresistant thyroid carcinoma metastasis. In **case 2** IMCSCM was near the field of the prior WBRT. However, both tumors were successfully treated without adverse effects by VMAT IM-SRT.

Keywords: *Metastasis, spinal cord, intramedullary, cervical, volumetric-modulated arc therapy.*

INTRODUCTION

Many reports have described the effectiveness of stereotactic radiotherapy/ stereotactic radiosurgery (SRT/SRS) for small brain parenchymal metastases [1]. In contrast, few reports are available on SRT/SRS for spinal intramedullary metastases [2-6]. The low tolerance of the spinal cord to radiation often limits the treatment dose in conventional external beam radiotherapy (cEBRT) to a level below the optimal tumor treatment dose, because radiation myelopathy can result in severe functional deficits [7]. SRT with intensity modulated radiation therapy (IM-SRT) can concentrate a large dose on the target sparing the surrounding normal tissue [2]. In this report, IM-SRT with volume modulated arc radiotherapy (VMAT) was performed for the intramedullary cervical spinal cord metastases (IMCSCM) in two cases. A single spinal lesion was successfully treated in each case without adverse effects. Our strategy with fractionated VMAT-SRT may be safe and effective for IMCSCM.

[Downloaded from ijrr.com on 2026-11-23]

[DOI: 10.18869/acadpub.ijrr.18.3.599]

Patients and Methods:

This study was approved by the research ethics board of Aichi Medical University Hospital (2018-H128). The need for patient consent was waived.

Case 1. (figure 1.2) A 76-year-old woman suffered from left-sided motor weakness and left arm pain and dysesthesia due to IMCSCM at C [cervical] 6-7 (located a little to the left laterally) with multiple small brain metastases from thyroid carcinoma. IMCSCM was treated by VMAT-SRT. In addition, the multiple brain metastases were successfully treated by SRS.

Case 2. (figure 3.4) A 48-year-old man presented with asymptomatic IMCSCM at C2 (located a little to the right laterally) after conventional whole brain radiotherapy (WBRT) and multiple sessions of SRT/SRS for multiple brain metastases from lung adenocarcinoma. IMCSCM was treated by VMAT-SRT.

In both cases 39 Gy in 13 fractions (without PTV [planning target volume] margin, D95% =95% dose) was delivered to the IMCSCM (0.3 ml and 0.5 ml in volume respectively) by coplanar 2-full circular arc VMAT using TrueBeam STx (Varian Medical Systems, Tokyo) equipped with ExacTrac (BrainLAB, Tokyo).

A head, neck, and shoulder thermoplastic shell was used for patient fixation during the treatment. The maximum dose to the tumor was 46.3 Gy in case 1 (figure 1) and 47.1 Gy in case 2 (figure 3). VMAT was planned on an Eclipse (equipped with AcurosXB version 11.0.31, Varian Medical Systems, Tokyo) workstation.

The IMCSCM was diagnosed from the magnetic resonance image (MRI) findings in both cases, and was observed as a well-demarcated, well-Gd [gadolinium]-enhanced mass lesion simultaneously developing with multiple brain parenchymal metastases. Oral administration of steroid continued from just before SRT until several weeks after it.

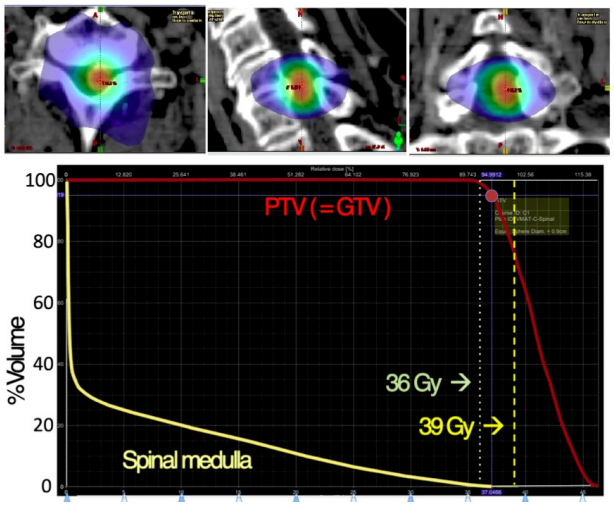

Figure 1. Dose planning for Case 1. Axial (upper left), sagittal (upper middle), and coronal (upper right) images of iodine enhancement computed tomography (CT) on Eclipse (Varian Medical Systems, Tokyo) radiotherapy planning system (RTPS) workstation showed excellent conformity for a C6-7 tumor by volumetric modulated arc therapy (VMAT), simultaneously with sparing of the surrounding normal spinal medulla. A boost up to 46.3 Gy was concentrated at the inside of the tumor around 6-7 as shown by the dose-volume histogram (DVH, lower). 100% dose=39 Gy in 13 fractions, D95%=95% dose.

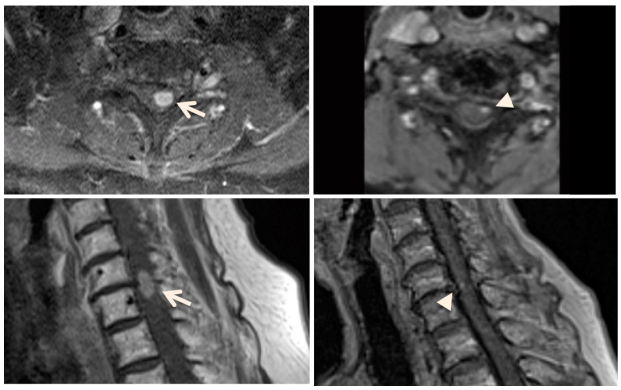

Figure 2. Pre- and post-SRT of cervical spinal lesion in Case 1. Pre-SRT and post-SRT MRIs of cervical spinal lesion. Axial (left upper) and sagittal (left upper) view of gadolinium (Gd) enhanced magnetic resonance images (MRIs) before stereotactic radiotherapy (SRT). Axial (right upper) and sagittal (right upper) view 32 months after SRT. A spinal intramedullary lesion (arrows) at the level C6-7 vertebra shrank within two months after VMAT SRT. The tumor remained shrunken (arrowheads) until the last imaging follow-up on axial (right upper) and sagittal (right upper) view 32 months after SRT before the patient's death at 34 months after SRT from lung metastasis.

[Downloaded from ijrr.com on 2026-11-23]

[DOI: 10.18869/acadpub.ijrr.18.3.599]

RESULTS

IMCSCM in both cases shrank markedly without any adverse effects during the follow-up period of 32 months in case 1 (figure 2) and 8 months in case 2 (figure 4). The symptoms of the bilateral legs and the left upper extremity in case 1 were fully relieved until the patient's death at 34 months after SRT from lung metastasis. No symptoms due to IMCSCM developed during the follow-up period of 8 months in case 2, though back pain due to bone metastasis was present.

Case 1 developed small brain metastases repeatedly during her remaining lifetime. Totally 33 brain lesions were treated in five sessions of SRS (9, 10, 1, 6, and 7 lesions respectively; D95=100%dose=22 Gy) and all were controlled until the patient's death. Case 2 also developed multiple brain metastases repeatedly. Totally 31 small brain metastases were treated by SRS (D95=95%dose of 22 Gy or D100=100% dose=15-18 Gy) in 7 times (1, 2, 2, 3, 1, 3, and 19 tumors respectively) and WBRT (30 Gy in 10 fx.) before the cervical VMAT-SRT. In addition, after the cervical VMAT-SRT, surgical resection of the left frontal brain lesions, which were causing epilepsy, was performed and later 7 small brain metastases were treated by SRS (D100=100% dose=18 Gy). Subsequently all of these brain lesions remained stable until the end of the follow-up period.

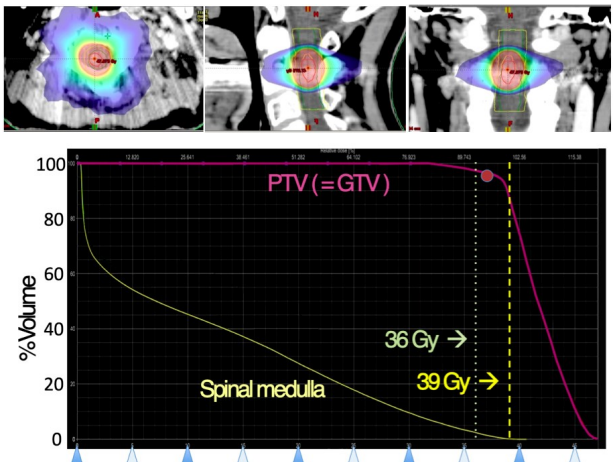

Figure 3. Dose planning for Case 2. Axial (upper left), sagittal (upper middle), and coronal (upper right) images of iodine enhancement CT on Eclipse RTPS workstation showed excellent conformity for a C2 tumor by VMAT, simultaneously with sparing of the surrounding normal spinal medulla. A boost up to 47.1 Gy was concentrated at the inside of the tumor as shown by the dose-volume histogram (DVH, lower). 100% dose=39 Gy in 13 fractions, D95%=95% dose.

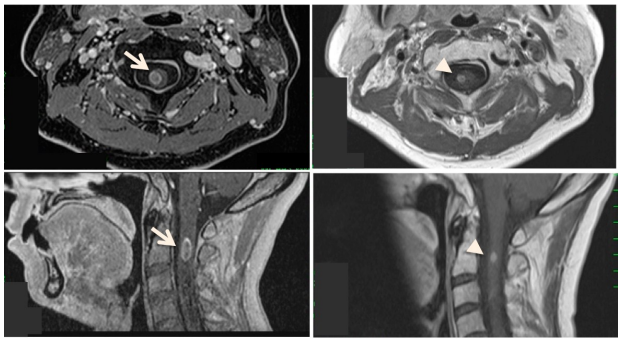

Figure 4. Pre- and post- SRT of cervical spinal lesion in Case 2. Pre-SRT and post-SRT MRIs of cervical spinal lesion Left: sagittal and axial view of Gd enhanced MRI before SRT. Right: sagittal and axial view two months after SRT. A spinal intramedullary lesion (arrows) at the level of C2 vertebra shrank within two months after VMAT-SRT. The tumor remained shrunken (arrowheads) until the last imaging follow-up on axial (right upper) and sagittal (right upper) view 4 months after SRT

DISCUSSION

Intramedullary spinal cord metastasis is a rare entity lacking well-defined treatment guidelines in spite of its rising incidence [8]. The majority of patients newly developing it have a brain metastasis and a known primary elsewhere [9]. Pain and weakness are the usual symptoms at presentation [8]. It should be considered in patients with a known malignancy developing a new sensory or motor deficit, especially if the symptoms are unilateral.

SRT/SRS needs an accurate technique to safely concentrate radiation on the target. TrueBeam equipped with ExacTrac system uses X-ray image analysis to correct patient position before each treatment session. A spinal lesion is accurately targeted after localization of the spinal bone structures. Some reports have noted successful results of SRT/SRS for spinal

[Downloaded from ijrr.com on 2026-11-23]

[DOI: 10.18869/acadpub.ijrr.18.3.599]

metastases, but most describe only spinal bone metastases [10-13]. Only a few reports have focused on the results of SRT/SRS for spinal intramedullary metastases [2-6].

SRT/SRS is an effective treatment option in the management of selected patients with spinal bone metastases. Prospective and retrospective clinical data have demonstrated excellent long-term local control, pain relief, and reduced severity of symptoms [10-13]. When the spinal bone tumor extends into the epidural space, underdosing of the epidural tumor to respect the dose constraint of the adjacent spinal cord may be responsible for an increased risk of local failure within the epidural space [14]. Recent reports discuss slightly higher doses than those previously recommended in consideration of the thecal sac/ cord constraints. Previously, for example, Garg *et al.* [15] reported that a spinal dose of 0.01 cu cm of 10 Gy was safe. Recently, a maximal spinal cord dose constraint of 14 Gy was associated with an acceptably low rate (0.4%) of myelopathy [16]. They delineate the spinal cord by intrathecal contrast medium-enhanced CT myelography. More recently, Ghia *et al.* [10] reported that the spinal cord D[max] as a 0.01 cu cm volume of MRI-defined spinal cord might be a cord constraint. Regarding intramedullary spinal cord metastases, individual circumstances differ greatly, because normal medulla parenchyma surrounds the target tumor totally. However, the tumor is often found before reaching a large size, because it causes neurological symptoms very early in the course involving the spinal medulla or nerves. This may provide a chance to treat it in a pinpoint fashion. In our cases the tumors were very small.

There have been few reports on SRS/SRT in intramedullary spinal cord metastases. Endo *et al.* [17] reviewed reports of conventional EBRT for intramedullary metastases, and found that a total dose of 25 to 40 Gy improved patient symptoms in 84.2% (116 of 191). Shin *et al.* [2] reported treatment results of spinal SRS for intramedullary metastases in six patients (six tumors). The treatment dose was 10-16 Gy. They noted that all but one of the tumors without imaging follow-up were controlled without any adverse effects. Parikh *et al.* [3] reported a case of C5 intramedullary spinal cord metastasis. The tumor was resistant to cEBRT of 30 Gy in 10 fractions. As a retreatment, CyberKnife SRT with a total dose of 15 Gy in three fractions (margin dose at 80% isodose line) successfully shrank the tumor and improved the patient's symptoms until the end of the follow-up period of 26 months after SRT. Veeravagu *et al.* [4] reviewed their experience with CyberKnife SRS/SRT for 11 tumors in nine patients. They delivered 14 Gy to 27 Gy (median 21 Gy) in one to five (median 3) fractions. They noted no recurrence or worsened neurological deficits during the follow-up period of one month and two days to 14 months. Mori *et al.* [5] reported a case of IMCSCMs in C1 and C2. The C1 lesion was inside the field of the previous WBRT of 40 Gy in 20 fractions for multiple brain metastases while the C2 lesion was just outside the field. A total dose of 24 Gy (at 100% isodose) in eight fractions was delivered for C1 lesion and 36 Gy in 12 fractions (at 100% isodose) to the C2 lesion using a multi-circular cone collimator method. They described that both tumors were controlled until the patient's death from primary lung carcinoma 10 months after SRT. The patient's neurological symptom of mild ataxia was stable until his death. We previously published a preliminary report of Case 1 with a shorter follow-up period [6].

We employed a conservative dose and more numerous fraction schedule, to spare the spinal cord from injury. In the present cases, VMAT-SRT was performed for a spinal lesion entirely surrounded by normal spinal medulla. Arc radiation delivery of VMAT is thought to be better than static multi-beam, because of the lower likelihood of an increased dose area beside the target. A total dose of 39 Gy in 13 fractions is almost equivalent to 50 Gy in 25 fractions for spinal tolerance. A 3-Gy fraction schedule was adopted because fractionation with a reasonable treatment period would help enhance tolerance of the surrounding spinal medulla without exceeding the dose to the medulla just beside the tumor caused by tumor shrinkage in the case of a longer treatment period. Around the tumor border and surrounding spinal medulla a total

[Downloaded from ijrr.com on 2026-11-23]

[DOI: 10.18869/acadpub.ijrr.18.3.599]

dose of 95% of 39 Gy in 13 fractions was delivered. Simultaneously a greater boost dose up to 46.3 Gy (case 1) and 47.1 Gy (case 2) in 13 fractions was given to the interior of the tumor. Boost dose inside the tumor might contribute to quick shrinkage of the tumor. This strategy with a 'reasonable margin dose and more central dose' by VMAT is comparable to that using CyberKnife SRT by groups such as Parikh *et al.* [3]. Though this is a report of only two cases, both tumors were successfully treated.

The tolerance dose (TD) to the spinal cord is usually quoted as 45 to 50 Gy in 2-Gy fractions, which is known to be TD 5/5, with 5% severe complication probability in five years [18]. However, more recent studies that included large numbers of patients have shown that a more realistic TD 5/5 could be up to 60 Gy [19]. Sahgal *et al.* [7] found that a dose of approximately 70 Gy or less, in a total maximum point dose normalized to a 2-Gy equivalent dose, was safe. Recently Park *et al.* [20] reviewed SRT/SRS for intramedullary spinal lesions. They summarized relatively low doses for the safe dose to a point within the thecal sac. They also mentioned that the decision to use higher doses must weigh the benefit of tumor control against the potential for radiation toxicity.

CONCLUSIONS

Despite the insufficient follow-up period is not long in case 2, VMAT-SRT was effective in controlling an IMCSCM in both cases. In case 1 IMCSCM had been thought to be a relatively radioresistant thyroid carcinoma metastasis. In case 2, IMCSCM was near the field of prior WBRT. However, both tumors were successfully treated without adverse effects by IM-SRT, and in case 1, it improved the patient's symptoms during her remaining lifetime.

***Conflicts of interest*:** *Declared none.*

REFERENCES

1. Yamamoto M, Serizawa T, Shuto T, Akabane A, Higuchi Y, Kawagishi J, Yamanaka K, Sato Y, Jokura H, Yomo S, Nagano O, Kenai H, Moriki A, Suzuki S, Kida Y, Iwai Y, Hayashi M, Onishi H, Gondo M, Sato M, Akimitsu T, Kubo K, Kikuchi Y, Shibasaki T, Goto T, Takanashi M, Mori Y, Takakura K, Saeki N, Kunieda E, Aoyama H, Momoshima S, Tsuchiya K (2014) Stereotactic radiosurgery for patients with multiple brain metastases (JLGK0901): a multi-institutional prospective observational study. *Lancet Oncol,* ***15****: 387-395*.
2. Shin DA, Huh R, Chung SS, Rock J, Ryu S (2009) Stereotactic spine radiosurgery for intradural and intramedullary metastasis. *Neurosurg Focus,* ***27****: E10*.
3. Parikh S, Heron DE (2009) Fractionated radiosurgical management of intramedullary spinal cord metastasis: a case report and review of the literature. *Clin Neurol Neurosurg,* ***111****: 858-861*.
4. Veeravagu A, Lieberson RE, Mener A, ChenY-R, Soltys SG, Gibbs IC, Adler JR, Tian AG, Chang SD (2012) CyberKnife stereotactic radiosurgery for the treatment of intramedullary spinal cord metastases. *J Clin Sci, 19: 1273-1277*.
5. Mori Y, Hashizume C, Shibamoto Y, Kobayashi T, Nakazawa H, Hagiwara M, Tsugawa T (2013) Stereotactic radiotherapy for spinal intradural metastases developing within or adjacent to the previous irradiation field. Report of three cases. *Nagoya J Med Sci,* ***75****: 263-271*.
6. Mori Y, Kawamura T, Ohshima Y, Takeuchi A, Mori T, Ishiguchi T (2016) Stereotactic radiotherapy for cervical spinal intramedullary metastasis and multiple brain metastases: A case report. *Cureus,* ***8****: e590*.
7. Sagal A, Ma L, Weinberg V, Gibbs IC, Chao S, Chang U-K, Werner-Wasik M, Angelov L, Chang EL, Sohn M-J, Soltys SG, Letourneau D, Ryu S, Gerszten PC, Fowler J, Wong CS, Larson DA (2012) Reirradiation human spinal cord tolerance for stereotactic body radiotherapy. *Int J Radiat Oncol Biol Phys,* ***82****: 107-116*.
8. Majmundar N, Shao B, Assina R (2018) Lung adenocarcinoma presenting as a intramedullary spinal cord metastasis: Case report and review of literature. *J Clin Neurosci,* ***52****: 124-131*.
9. Chason JL and Landers JW (1963) Metastatic carcinoma in the central nervous system and dorsal root ganglia. A prospective autopsy study. *Cancer,* ***16****:781-787*.
10. Ghia AJ, Guha-Thakurta N, Hess K, Yang JN, Settle SH, Sharpe HJ, Li J, MaAleer MF, Chang EL, Tatsui CE, Brown PD, Rhines LD (2018) Phase 1 study of spinal cord constraint relaxation with single session spine stereotactic radiosurgery in the primary management of patients with inoperable, previously unirradiated metastatic epidural spinal cord compression. *Int J Radiat Oncol Biol Phys,* ***102****: 1481-1488*.

[Downloaded from ijrr.com on 2026-11-23]

[DOI: 10.18869/acadpub.ijrr.18.3.599]

11. Bishop AJ, Guadagnolo BA, Allen PK, Rebueno NC, Wang XA, Amini B, Tatsui CE, Rhines LD, Li J, Chang EL, Brown PD, Ghia AJ (2017) Spine stereotactic radiosurgery for metastatic sarcoma: patterns of failure and radiation treatment volume considerations. *J Neurosurg Spine, **27**: 303-311*.
12. Ho JC, Tang C, Deegan BJ, Allen PK, Jonasch E, Amini B, Wang XA, Li J, Tatsui CE, Rhines LD, Brown PD, Ghia AJ (2016) The use of spine stereotactic radiosurgery for oligometastatic disease. *J Neurosurg Spine, **25**: 239-247*.
13. Ryu S, Jin RY, Chen Q, Rock J, Anderson J, Movsas B (2008) Pain control by image-guided radiosurgery for solitary spinal metastasis. *J Pain Symptom Manag, **35**: 292-298*.
14. Chang EL, Shiu AS, Mendel E, Mathews LA, Mahajan A, Allen PK, Weinberg JS, Brown BW, Wang XS, Woo SY, Cleeland C, Maor MH, Rhines LD (2007) Phase I/II study of stereotactic body radiotherapy for spinal metastasis and its pattern of failure. *J Neurosurg Spine, **7**: 151-160*.
15. Garg AK, Shiu AS, Yang J, Wang XS, Allen P, Brown BW, Grossman P, Frija EK, McAleer MF, Azeem S, Brown PD, Rhines LD, Chang EL (2012) Phase 1/2 trial of single-session stereotactic body radiotherapy for previously unirradiated spinal metastases. *Cancer, **118**: 5069-5077*.
16. Yamada Y, Katsoulakis E, Laufer I, Lovelock M, Barzilai O, McLaughlin LA, Zhang Z, Schmitt AM, Higginson DS, Lis E, Zelefsky MJ, Mechalakos J, Bilsky MH (2017) The impact of histology and delivered dose on local control of spinal metastases treated with stereotactic radiosurgery. *Neurosurg Focus, **42**: E6*.
17. Endo S, Hida K, Yano S, Ito M, Yamaguchi S, Kashiwazaki D, Kinoshita R, Shirato H, Iwasaki Y (2008) Intramedullary spinal cord metastasis treated with radiation therapy: report of 3 cases. *No Shinkei Geka, **36**: 345-349*.
18. Ryu S, Gorty S, Kazee AM, Bogart J, Hahn SS, Dalal PS, Chung CT, Sagermann RH (2000) 'Full dose' reirradiation of human cervical spinal cord. *Am J Clin Oncol, **23**: 29-31*.
19. Schultheiss TE (1990) Spinal cord radiation "tolerance": doctrine versus data. *In t J Radiat Oncol Biol Phys, **19**: 219-221*.
20. Park HK and Chang JC (2013) Review of stereotactic radiosurgery for intramedullary spinal lesions. *Korean J Spine, **10**: 1-6*.

[Downloaded from ijrr.com on 2026-11-23]

[DOI: 10.18869/acadpub.ijrr.18.3.599]