

Amelioration of Myogenin, Bcl-2 expression and DNA damages in myocytes of *Trichinella spiralis*-infected mice after immunization with gamma radiation-attenuated larvae

E.N. Hafez^{1*}, W.A.M.S. El-Kholy², M.A.E.M. El-Kholy³

¹Health Radiation Research, National Center for Radiation Research and Technology (NCRRT), Atomic Energy Authority, Cairo, Egypt

²Al Azhar University, Faculty of Medicine, Parasitology Department, Cairo, Egypt

³Al Azhar University, Faculty of Medicine, pathology Department, Cairo, Egypt

ABSTRACT

Background: In trichinosis, the presence of muscle larvae inside skeletal striated muscle causes loss of identity and function of myotube through the releasing of myogenin and myosin. Considering the dominant role of vaccination, research on gamma radiation-attenuated vaccine has very promising value. The goal of this study was to determine the efficacy of vaccination with radiation-attenuated *Trichinella spiralis* larvae on the subsequent infectivity. This goal was to be achieved by expression of myogenin, Bcl-2 and DNA damages of myocytes in experimental animals. **Materials and methods:** Mice were randomly assigned to serve as normal control, infected control, vaccinated unchallenged and vaccinated challenged groups. Histopathological and immunohistochemical assessments of skeletal muscle tissues of diaphragm were conducted using different stains. Also, DNA damages of myocytes by comet assay were evaluated. **Results:** An improvement of histopathological changes and DNA damages of myocytes with significant decreased expression of myogenin and Bcl-2 in vaccinated challenged group was detected. **Conclusion:** Vaccination with gamma radiation-attenuated larvae exerted protective effect against challenged infection. This may pave the way to new protective modality in trichinosis control.

Keywords: *Trichinella spiralis*, gamma radiation, vaccine, myogenin, bcl-2, comet assay.

► Original article

*Corresponding authors:

Eman Naser Hafez Ph.D.,

E-mail:

eman_naser612@hotmail.Com

Revised: November 2019

Accepted: January 2020

Int. J. Radiat. Res., October 2020;
18(4): 699-706

DOI: 10.18869/acadpub.ijrr.18.4.699

INTRODUCTION

Trichinosis is a parasitic disease that can be categorized into three stages: the adult worm in small intestine; the new born larvae in lymphatic vessels and muscle larvae that occupy intracellular niches in skeletal muscle cells. However, the skeletal muscle cells are the only cell type that can support growth and survival of the larvae by dealing with host immune response through effect of excretory / secretory proteins ^(1,2).

Creation of so called Nurse Cell (NC) capsule which is composed of collagenous wall and cellular components is responsible for parasite protection from the host's defense mechanisms and meeting parasite's metabolic nutritional demands ⁽³⁻⁵⁾.

Gene expression analysis revealed that myogenic regulatory factors, MyoD and myogenin (important for the myogenesis and regeneration of muscles), are over expressed in infected muscle tissues during *T. spiralis* infections, and the MyoD factor is highly

expressed in the satellite cells of infected muscles ⁽⁶⁾.

At the end of encapsulation of *Trichinella*, expression of all apoptotic factors ceased and only positivity of an important gatekeeper to apoptotic response B cell lymphoma-2 (Bcl-2) persists in the nurse cell. Anti-apoptotic and pro-apoptotic proteins are two major subgroups of Bcl-2. The interaction between them in mitochondria disrupts the normal function of anti-apoptotic Bcl-2 proteins and can lead to the formation of pores in the mitochondria. This leads to the release of cytochrome C and other pro-apoptotic molecules from the inter membrane space ⁽⁷⁻⁹⁾.

Evaluation of DNA damage induced in *Trichinella spiralis* infected muscle can be applied by single cell gel (comet assay). It is used as a guideline for assessing viability of cell (dead or living), cell death type (apoptosis or necrosis) and repair screening in different cell models in animals ⁽¹⁰⁾. The resulting images measured to determine the extent of DNA damage was classified from type 1-5 based on morphological basis. Viable cells showed large head with minute or no tail while apoptotic one represented as comet-like with small head (the nuclear region) and large tail of nuclear remnants ⁽¹¹⁻¹³⁾.

So far, useful and stable anti-*Trichinella* vaccines that can be used in animal husbandry have not been developed yet. Therefore, it is necessary to develop a vaccine against *Trichinella* infection in domestic animals and humans. Vaccination using live-attenuated pathogen has an advantage of its potent immunogenicity because organisms keep to behave and can be recognized by immune system as a natural infection. This supports the hypothesis that activating multiple innate receptors is better than activating only one receptor ⁽¹⁴⁻¹⁶⁾.

The purpose of this study is to determine the ability of gamma radiation-attenuated *Trichinella spiralis* larvae to induce immune protection against challenged infection. Expression of myogenin and apoptotic factor Bcl-2 were immunohistochemically evaluated as well as DNA damages of myocytes by comet

assay was performed.

MATERIALS AND METHODS

Irradiation of parasite

Trichinella spiralis larvae were obtained by collecting from infected donor mice as described by Crum et al. ⁽¹⁷⁾. Mice were euthanized by cervical dislocation following anesthesia, skinned and eviscerated tissues were minced in a meat grinder. They were digested in 10 ml/g distilled water, 1% (w/v) pepsin (Sigma Chemical Co., St. Louis, MO, U.S.A.) and 1% (v/v) hydrochloric acid. The digested fluid was poured through mesh, washed several times with 0.85% NaCl and larvae were collected. They were exposed to attenuating dose of 300 Gy gamma-radiations—according to Brake et al. ⁽¹⁸⁾. This was performed at the National Center for Radiation Research and Technology (NCRRT), Cairo, Egypt using Indian Cobalt-60 gamma chamber 4000 A Irradiator at 2.5 Krad / h at the time of experimentation.

Experimental animals and design

A total of 40 male Swiss albino mice six week-old and weighing 18-20 g were used in the experiment. They were housed in cages (10 rats in each) and maintained under controlled conditions of lighting and temperature. They were kept under specific pathogen-free conditions, with free access to standard laboratory water and chow according to the ethics committee of the National Center of Radiation Research and Technology, Egyptian Atomic Energy Authority, Cairo, Egypt (REC-NCRRT) (Permissin code 8A/19).

Mice were randomly divided into four groups of 10 mice each: normal control, infected control received orally 250 *Trichinella spiralis* larvae using stomach tube syringes ⁽¹⁹⁾, vaccinated unchallenged group infected orally with the same dose of larvae attenuated with 300 Gy gamma radiation and vaccinated challenged group that infected with radiation-attenuated larvae then challenged two weeks later (to allow stimulation of immune response) by the same infective dose. Thirty

days post infection and challenge; all mice were euthanized under anesthesia. Skeletal muscles tissues of diaphragm were then obtained and divided into three parts for histopathological, immunohistochemical and comet assay study.

Experimental procedures

Histopathological examination

Portions of skeletal muscle tissues of diaphragm of mice in all groups were preserved in 10% buffered formalin, cut into 1 cm. thick slices, dehydrated by alcohol, cleared with xylol and finally embedded in paraffin wax then processed into paraffin blocks. Using Reichert Rotary microtome, serial paraffin sections of 5µm thickness were made then stained with Harries Hematoxylin and Eosin ⁽²⁰⁾.

Immunohistochemical study

Two sections were cut from each case on positively charged slides and subjected to immunohistochemical stain using the streptavidin-biotin alkaline phosphate methods. Myogenin staining was performed using the myf-4 antibody (L026, 1:10, mouse monoclonal, Movacastra Labs, and Burlingame, CA), according to the recommended protocol. In a pressure cooker, antigen retrieval was done for 40 min in 10nM citrate buffer with 0.1% Tween 20 at pH 6.0. Slides were incubated overnight with the primary antibody, followed by detection using standard protocol on an automated immunostainer (Ventana Medical Systems, Tuscon, AZ).

For Bcl-2 staining, the protocol of the DAKO LSAB2 kit Peroxidase (DAKO Kyoto) was followed for each section. The sections were incubated overnight at 4°C with the primary antibody (Bcl-2 mouse monoclonal, DAKO, in a 1:40 dilution with PBS containing 1% bovine serum albumin). Negative controls were prepared by omitting the primary antibody under identical test condition. The sections were placed in an oven at 50°C for 30 min and then they were deparaffinized in PBS, incubated with 0.3% hydrogen peroxide to block endogenous peroxidase activity, washed in PBS again, and boiled in citrate buffer solution (pH 6.0) using a microwave for 10 min at 60°C for antigen

retrieval. After cooling at room temperature, sections were incubated with primary antibody overnight in a humidified chamber and rinsed with PBS. They were then incubated for 30 min at 37°C with biotinylated secondary antibody and streptavidin conjugated to horseradish peroxidase. The sections were counter stained with Mayer's hematoxylin.

Evaluation of immunostaining

Staining for myogenin was graded from 1+ to 4+ as follows, based on the percentage of tumor cell nuclei staining positive: rare positive to 25%; 1+, 25 to 50 % ; 2+, 50 -75% ; 3+ and 75 to 100%; 4+. The percentage of cells immune positive cells for Bcl-2 was calculated by counting the cells in a 200-power field. Two investigators blinded to treatment graded Bcl-2 expression on the following scale: (-), no muscle fibers positive; (+), 1 to 25% of muscle fibers positive; (++) , 26 to 50% of muscle fibers positive; (+++), 51 to 100% of muscle fibers positive ^(21, 22).

Single cell gel (comet Assay)

The remaining of skeletal muscle tissues was subjected to study of DNA damage according to Hartmann *et al.* ⁽²³⁾. Tissues were homogenized in 0.075 NaCl and EDTA buffer, Ph 7.5, at 1 g of tissue to 1 ml of buffer a ratio then cooled to 4°C. 6 µl of tissue homogenate were suspended in 100 µl of 0.5% low-melting agarose (Sigma-Aldrich, StLouis, MA, USA). It was placed onto clean slides coated with 300 µl of 0.6% normal melting agarose. Solidification in ice was done for 10 minutes then slides were covered with 0.55 low melting agarose. After solidification of agarose gel, slides were immersed in lysing solution (100 Na₂ EDTA, 2.5 NaCl, 10 M Tris-HCl and 1% sodium sarcosinate, which was adjusted to pH 10, using 1% Triton X-100 and 10% dimethyl sulfoxide (DMSO). Slides were removed from lysing solution, placed in a horizontal electrophoresis unit (near the anode) that was filled with an alkaline buffer (1mM Na₂ EDTA and 300 mM NaOH) to allow the unwinding of DNA. Electrophoresis was carried out in the freshly prepared alkaline solution for 20 minutes at 25

V (300 mA). Electrophoresis at high pH resulted in structures resembling comets, as observed by fluorescence microscopy. Afterwards, the slides were neutralized by adding Tris buffer (pH 7.5), stained with 30 ml of ethidium bromide (Sigma- Aldrich, St Louis, MA, USA) (20 mg/L), and then covered and stored in sealed boxes at 4°C for further analysis. All of the steps described above were conducted in the dark to prevent additional DNA damage. Images of 100 randomly selected cells were analyzed for each sample by Leitz Orthoplan epifluorescence microscope (magnification $\times 250$) equipped with an excitation filter of 515 to 560 nm and a barrier filter of 590 nm.

Statistical analyses

Results were subjected to Student's t-test using SPSS program version 8 to determine the significance of the data. Data are expressed as mean \pm standard error. Values with $P < 0.05$, $P < 0.01$ and $P < 0.001$ were considered as significant, highly significant and very highly significant respectively.

RESULTS

Histopathological results

Histopathological examination of H&E diaphragm muscle sections of all groups were represented in figure 1. Normal control group showed normal muscle cells with no inflammatory reaction. Infected control group showed severe parasitic infection with many encysted larvae in well-formed capsule. Also, inflammatory tissue reactions infiltrating the cyst walls with cloudy swelling of muscle fibers were detected. Vaccinated unchallenged group showed disintegration and fragmentation of encysted larvae within incomplete cyst wall surrounded by tissue reaction. While vaccinated challenged group showed relative regression of inflammatory reaction with much less cellular infiltrates.

Immunohistochemical examination

Data in table 1, figure 2 showed minimal expression of Bcl-2 in myocytes of normal

control group (1.7 ± 0.3) while infected control group revealed strong positive deposition around encysted larvae and cellular infiltrates (20.7 ± 2.7) with statistically significant increase ($P < 0.001$) compared to normal control group. The expression showed moderate deposition in interstitial spaces of muscle bundles in vaccinated unchallenged group (7.6 ± 0.4). On the other hand, vaccinated challenged group revealed relatively mild expression (3.6 ± 0.3) in muscle bundles with regular architecture showing a high significant decrease were detected compared to infected control group ($P < 0.001$).

Regarding expression of myogenin in normal control group, it showed minimal expression (2.9 ± 0.3) while a strong positive immunostaining of the cellular infiltrates surrounding encysted larvae was recorded in the infected control group (36.8 ± 2.2) with high significant increase compared to normal control group. In vaccinated unchallenged group, there was moderate positive expression (8.2 ± 0.3) with incomplete capsule surrounding disintegrated larvae. Vaccinated challenged group showed a weak deposition (3.5 ± 0.5) with a high significant decrease compared to infected control group ($P < 0.001$) (table 1, figure 3).

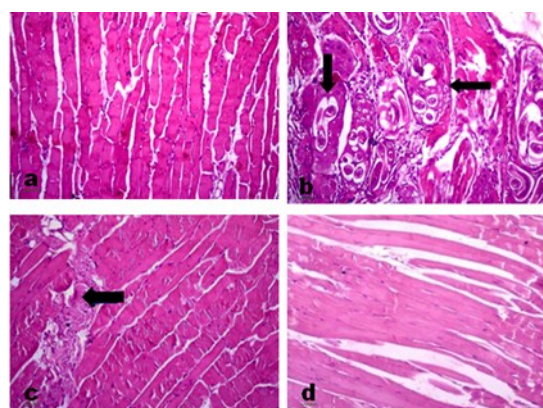


Figure 1. Normal diaphragm muscle fibers of mice showed striations with abundant eosinophilic cytoplasm and peripherally placed nuclei (a). Infected control group showed encysted larvae surrounded by histiocytes, plasma cells and lymphocytes with fibrosis around them (\rightarrow) (b). Vaccinated unchallenged group revealed degeneration and fragmentation of the larvae surrounded with incomplete capsule (arrow) and remains of degenerative changes of muscle fibers (\rightarrow) (c). Vaccinated challenged group showed nearly normal muscle fibers with minimal histopathological changes (d) (H&E X100).

Table 1. Effect of vaccination with attenuated *Trichinella spiralis* larvae on expression of Bcl-2 and myogenin in experimental groups

Parameters	Normal control	Infected control	Vaccinated unchallenged	Vaccinated challenged
Bcl-2	1.7±0.3	20.7±2.7 ⁺⁺⁺	7.6±0.4 ^{++, ***}	3.6±0.3 ^{+, ***}
Myogenin	2.9±0.3	36.8±2.2 ⁺⁺⁺	8.2±0.3 ^{++, ***}	3.5±0.5 ^{n.s., ***}

Data are expressed as mean ± SE. P values + compared to control normal group. P values * compared to control infected group.

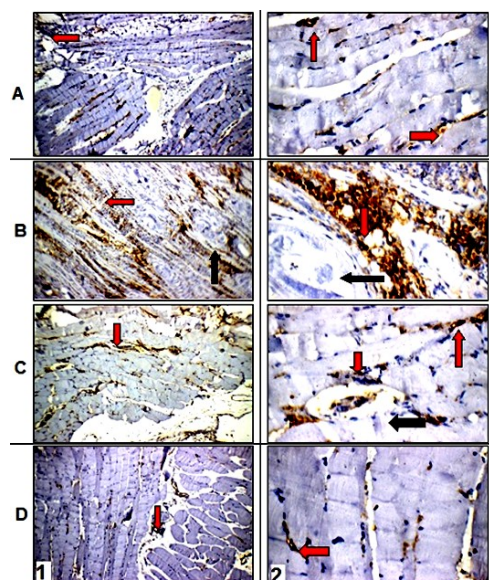


Figure 2. Immunohistochemical staining of Bcl-2 in diaphragm muscles showed weak expression in normal control group (A). Strong positive expression in infected control group (red arrow) around encysted larvae (black arrow) (B). Myocytes of vaccinated unchallenged group revealed moderate expression (red arrow) around degenerated larvae in incomplete capsule (black arrow) (C). Weak expression was detected in vaccinated challenged group (D) (1 Magnification X 200, 2 Magnification X 400).

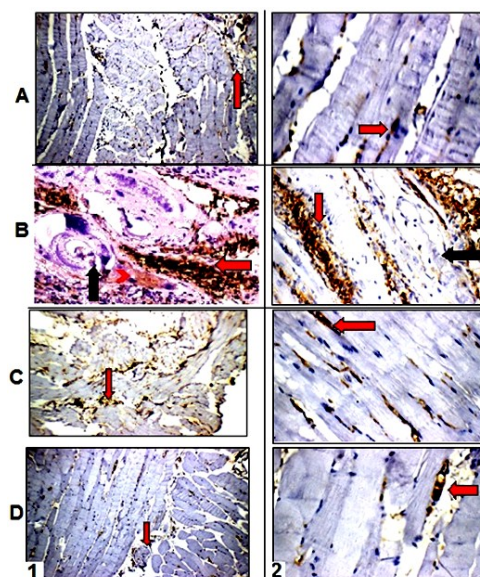


Figure 3. Immunohistochemical staining of myogenin in diaphragm muscles showed weak expression in normal control group (A). Strong positive expression in infected control group (red arrow) around encysted larvae (black arrow) (B). Myocytes of vaccinated unchallenged group revealed moderate expression (red arrow) around degenerated larvae in incomplete capsule (black arrow) (C). Weak expression was detected in vaccinated challenged group (D) (1 Magnification X 200, 2 Magnification X 400).

DNA comet assay

DNA comet assay in myocytes was expressed in table 2 figure 4 showing significant increase in tail moment and tail length in the infected control group compared to the normal control. A significant decrease was

recorded in tail moment and length in vaccinated unchallenged group and vaccinated challenged groups with 91% and 95% untailed respectively compared to the infected control one.

Table 2. Tail moment, length and % of untailed DNA myocytes in comet assay.

	Tailed %	Untailed %	Tail length	Tail DNA%	Tail Moment
Normal control	2	98	1.24±0.005	1.28	1.71±0.14
Infected control	18	82	3.1±0.01 ^a	1.78	5.51±0.16 ^a
Vaccinated unchallenged	9	91	2.80±0.05 ^{a, b}	1.35	3.90±0.13 ^{a, b}
Vaccinated challenged	5	95	1.64±0.06 ^{a, b}	1.21	2.98 ±0.08 ^{a, b}

DNA % = percent of DNA in comet tail

Tail length = Length of tail measured from borders of the head area to tail end (μm)

Tail moment = tail DNA % X tail length

a: Significant difference from normal control

b: Significant difference from infected control




Figure 4. Normal control group shows intact nuclear DNA. In infected control group, DNA damage expressed by tail moment in muscle cells with strongly damaged spot. Vaccinated unchallenged group showed mild DNA damage expressed by tail moment in cells with less damaged spot. Vaccinated challenged group revealed few DNA damage in the cells (a-d magnification X 250)

DISCUSSION

Vaccination efforts have been performed on the protective immunity against *T. spiralis* infection. Immunization of pigs with the soluble fraction prepared by sonication of larvae revealed an ineffective protection⁽²⁴⁾. The crude excretory-secretory (ES) antigens at certain molecular size showed an immune efficacy in reducing parasite burden⁽²⁵⁾. DNA vaccine was demonstrated to be able to promote humoral and cellular immune response and reduce the muscle larval burden⁽¹⁹⁾. However, it was reported that immunization with a single antigen selected from recombinant proteins or ES antigens revealed lower protective effect than inactivated whole worm⁽²⁶⁾.

In the present study, histopathological examination revealed severe parasitic infection with larval encystations surrounded with complete capsule in infected control group. Immunohistochemical staining which was proved to be a subjective, time-consuming process that offers the potential to develop quantitative scoring models⁽²⁷⁾ revealed high expression of myogenin and Bcl-2 in inflammatory cellular infiltrates. This was in accordance with previous studies reported an increase of Myogenin, MyoD and MEF2 in *Trichinella spiralis* infected muscle. Also, weak

expression of Bcl-2 in early infection followed by strong positive staining for mitochondrial related genes as BAX (a pro-apoptotic member of Bcl-2 family) in cellular infiltrates around capsule of encysted larvae. This was explained due to replacement of destructed mitochondria as a result of parasite invasion with new one⁽²⁸⁻³⁰⁾.

Concerning the DNA damage of muscle cells, high intensity of DNA damage with a significant increase in tail moment and tail length in infected control group indicating the adverse effects of parasite on myocytes was recorded. This was in agreement with studies reported DNA fragmentation in the nurse cell during the interval from 18 to 28 days post infection⁽³¹⁾. This may be due to the combination of mitochondrial cytochrome c with apoptotic protease activating factor 1. An intrinsic or mitochondrial Bcl-2-regulated pathway triggers the response of DNA damaged-cells by increasing their production of p53 which is a potent inducer of apoptosis. After *trichinella* invasion, there is an increase the release of Ca²⁺ due to mechanical damage of the sarcoplasmic reticulum that increases the nuclear expression of apoptosis inducing factor (AIF) which could be from the muscle cells or from the parasite organism⁽³²⁾.

Vaccinated unchallenged group showed disintegration of encysted larvae and mild inflammatory reactions within incomplete cyst wall. There was moderate expression of myogenin and Bcl-2 in cellular infiltrates that surround disintegrated larvae. Also mild DNA damage and a significant decrease in tail moment and tail length were detected compared to infected control group. This outcome is compatible with the previous studies reported mild inflammatory and histopathological changes with maintaining normal architecture of different organs resulted from experimental vaccination with radiation-attenuated vaccine without challenged infection. These could be explained by the effect of radiation as a powerful inducer of the intrinsic pathway of apoptosis that leads to DNA fragmentation and mitochondrial

disruption. Thus, it weakened the parasites, systematically inactivate, disassemble and degrade their functional and structural components with loss of their proliferation ability and decreasing pathogenicity^(33,34).

This study revealed marked improvement of histopathological changes in the diaphragm muscle tissues of vaccinated challenged group. These findings were in accordance to previous studies revealed a significant protection against *Trichinella spiralis* with high degree of reinfection resistance using lower dose radiation-attenuated larval vaccine^(35,36). Also, protection against challenged infection was demonstrated in experimental mice immunized with larvae after exposure to the microwave irradiation. This was assessed by a statistically significant decrease in adult and muscle larval count, compared with the non-immunized infected control⁽³⁷⁾.

Immunohistochemical expression of myogenin and Bcl-2 was significantly decreased in vaccinated challenged group. This was in agreement with previous study revealed that vaccination with gamma-radiation attenuated *Schistosoma mansoni* larva resulted in reduction in immunohistochemical changes in liver tissue of challenged group⁽³⁸⁾.

Also, DNA damage showed a significant decrease in tail moment and tail length compared to infected control group. More or less similar results were recorded by previous studies demonstrated a significant decrease in tail moment, tail DNA%, and tail length in brain tissue of group vaccinated with irradiated *T. canis* larvae^(39,40). In another study vaccinated challenged groups either by UV or Gamma radiation attenuated *Toxoplasma gondii*, revealed that the majority of cells appeared normal rounded and few cells with very short tails⁽⁴¹⁾. This is due to potent immunogenicity of attenuated vaccines since the organisms are still able to behave initially in a similar manner to a natural infection. Thereby stimulating the immune system to secrete the immunoregulatory products and induce the cellular activation that would normally occur⁽⁴²⁾.

CONCLUSION

Mice immunized with gamma radiation-attenuated *Trichinella spiralis* larvae showed an enhanced immunogenicity against the challenged infection. This was demonstrated by an improvement of histopathological changes and DNA damages of myocytes that happened as a result of infection. Also, the protection causes reduced expression of myogenin and Bcl-2 in infected muscles of the diaphragm. This would be of a great importance for the future design of a new vaccine for prevention and control of animal trichinosis.

Funding

This research did not receive any specific grant from funding agencies in the public, commercial or not-for-profit sectors.

Conflicts of interest: Declared none.

REFERENCES

1. Farid AS, Fath EM, Mido S, Nonaka N, Horii Y (2019) Hepatoprotective immune response during *Trichinella spiralis* infection in mice. *J Vet Med Sci*, **81**(2): 169–176.
2. Jasmer DP (2001) Genetic reprogramming of mammalian skeletal muscle cells by *Trichinella spiralis*. In "Parasitic Nematodes Molecular Biology, Biochemistry and Immunology" pp. 121-137. CABI publishing, Oxford.
3. Robinson MW, Connolly B (2005) Proteomic analysis of the excretory- secretory proteins of the *Trichinella spiralis* L1 larva, a nematode parasite of skeletal muscle. *Proteomics*, **17**: 4525-32.
4. Sukura A, Nareaho A, Mikkonen T, Niemi M, Oivanen L (2002) *Trichinella native* and *T. spiralis* induce distinguishable histopathologic and humoral responses in the raccoon dog. *Vet Path*, **39**: 257-265.
5. Wu Z, Sofronic-Milosavljevic L, Nagano I, Takahashi Y (2008) *Trichinella spiralis*: nurse cell formation with emphasis on analogy to muscle cell repair. *Parasit & Vect*, **1**: 27.
6. Sofronic-Milosavljevic L, Ilic N, Pinelli E, Gruden-Movsesijan A (2015) Secretory Products of *Trichinella spiralis* Muscle Larvae and Immunomodulation: Implication for Autoimmune Diseases, Allergies, and Malignancies. *J Immunol Res*, 1-14.
7. Haehling EY, Niederkorn G, Stewart GL (1995) *Trichinella spiralis* and *Trichinella pseudospiralis* induce collagen synthesis by host fibroblasts in vitro and in vivo. *Int J Parasitol*, **25**(12):1393- 400.

8. Babal P, Milcheva R, Petkova S, Janega P, Hurnikova Z (2011) Apoptosis as the adaptation mechanism in survival of *Trichinella spiralis* in the host. *Parasitol Res*, **109**: 997–1002.
9. Malik T (2014) Male Infertility: Role of Cellular, Biochemical and Molecular Events. *Theriogenology Insight- Internat J Reprod Anim*, **4**(2):71-84.
10. Muller P (2019) The comet assay: ready for 30 more years. *Mutagenesis*, **33**: 1-7.
11. Marin-Huachaca N, Delincee H, Mancini-Filho J, Villavicencio ALCH (2005) Use of the DNA comet assay to detect beef meat treated by ionizing radiation. *Meat Sci*, **71**: 446-450.
12. Fahim M, Ahmed A, Hussain S (2017) Single Cell Gel Electrophoresis and its Applications in Different Fields. *MOJ Bioequiv Availab* **4**(2): 00066.
13. Archana M, Bastian D, Yogesh TL, Kumaraswamy KL (2012) Various methods available for detection of apoptotic cells- A review. *Ind J Cancer*, **50**: 274-83.
14. Murrell KD and Pozio E (2011) Worldwide occurrence and impact of human trichinellosis, 1986 –2009. *Emerg Infect Dis*, **17**: 2194–2202.
15. Vasou A, Sultanoglu N, Goodbourn S, Randall RE, Kostrikis LG (2017) Targeting Pattern Recognition receptors (PRR) for vaccine adjuvantation: from synthetic PRR agonists to the potential of defective interfering particles of viruses. *Viruses*, **9**(7): 186-198.
16. Viljoen GJ and Luckin AG (2012) The role of nuclear technologies in the diagnosis and control of livestock diseases- a review *Trop Anim Health. Production* **44**: 1341-1366.
17. Crum ED, Despommier DD, McGregor DD (1977) Immunity to *Trichinella spiralis*. I. Transfer of resistance by two classes of lymphocytes. *Immunology*, **33**: 787–795.
18. Brake RJ, Murrell KD, Ray EE, Thomas JD, Muggenburg BA, and Sivinski JS (1985) Destruction of *Trichinella spiralis* by low-dose irradiation of infected pork. *J Food Safety*, **7**: 127–143.
19. Xu J, Bai X, Wang LB, Shi HN, Van Der Giessen WB, Boireau P, Liu MY, Liu XL (2017) Immune responses in mice vaccinated with a DNA vaccine expressing serine protease-like protein from the new-born larval stage of *Trichinella spiralis*. *Parasitol*, **144**(6): 712–719.
20. MacManus JFA and Mowry RW (1964) Staining: Histological and Histochemical. 1st ed. Harper and Row, NewYork, USA, **74**: 126.
21. Hiroyuki Y, Osamu I, Toshiyuki S, Keichi H, Kouzo H, Sachio O (2001) Expression of apoptosis regulatory proteins in skeletal muscle of tumorbearing rabbits. *Jpn J Cancer*, **92**:631-637.
22. Kumar S, Perlman E, Harris CA, Raffield M, Tsokos M (200) Myogenin is a specific marker for rhabdomyosarcoma: An immunohistochemical study in paraffin-embedded tissues. *Mod Pathol*, **13**: 988-993.
23. Hartmann A, Kobayashi H, Miyamae Y, Rojas E, Ryu JC, Sasaki YF (2000) Single cell gel/comet assay: guidelines for in vitro and in vivo genetic toxicology testing. *Environ Mol Mutagen*, **35**:206–221.
24. Marti HP, Murrell KD, Gamble HR (1987) *Trichinella spiralis*: Immunization of pigs with newborn larval antigens. *Exper Parasitol*, **63**: 68–73.
25. Bi K, Yang J, Wang L, Gu Y, Zhan B, Zhu X (2015) Partially Protective immunity induced by a 20 kDa protein secreted by *Trichinella spiralis* Stichocytes. *PLoS ONE*, **10**(8): e0136189.
26. Zhang N, Li W, Fu B (2018) Vaccines against *Trichinella spiralis*: Progress, challenges and future prospects. *Transbound emerg Dis*, **65**(6): 1447-1458.
27. Shavlakadze T, Winn N, Rosenthal N, Grounds MD (2005) Reconciling data from transgenic mice that over express IGF-I specifically in skeletal muscle. *Growth Horm IGF Res*, **15**: 4-18.
28. Matsuo A, Wu Z, Nagano I, Takahashi Y (2000) Five types of nuclei present in the capsule of *Trichinella spiralis*. *Parasitol*, **121**: 203–210.
29. Ibrahim SM, Sarhan MH, Farag TI, Mohamed AH (2019) Apoptotic and vascular changes in *Trichinella spiralis* infected mice after parenteral artemether treatment. *J Egypt Soc Parasitol*, **49**(1): 17 – 27.
30. Boonmars T, Wu Z, Nagano I, Takahashi Y (2004) Expression of apoptosis-related factors in muscles infected with *Trichinella spiralis*. *Parasitol*, **128**: 323-32.
31. Wu Z, Nagano I, Boonmars T, Takahashi Y (2005) Tumor necrosis factor receptor-mediated apoptosis in *Trichinella spiralis*-infected muscle cells. *Parasitol*, **131**:705–712.
32. Norberg E, Orrenius S, Zhivotovsky B (2010) Mitochondrial regulation of cell death: processing of apoptosis-inducing factor (AIF). *Biochem Biophys Res Commun*, **396**:96–100.
33. Amin MM, Hafez EN (2015) Effect of Vaccination with Irradiated Tachyzoites on Histopathological Changes and DNA Damage in Hepatocytes of Experimental Toxoplasmosis. *Arab J Nucl Sci Appl*, **48**(4): 237-245.
34. Flores-Perez I, Fragoso G, de Aluja AS (2003) Apoptosis induced by gamma irradiation of *Taenia solium* metacystode. *Parasitol. Resear*, **90**: 203–208.
35. Gene IH (1988) Vaccines for parasitic diseases. *Ann. Rev. Public Health*, **9**: 483-501.
36. Agyei-Frempong M and Catty D (1983) The measurement of antigens released by radiation-attenuated *Trichinella spiralis* larvae. *Parasite Immunol*, **5**(3): 289-303.
37. Ali SM, El-Zawawy LA, El-Said D, Gaafar MR (2007) Immunization against trichinellosis using microwaved larvae of *Trichinella spiralis*. *J Egypt Soc Parasitol*, **37**(1):121-33.
38. Amin MM, Hafez EN, Marei ES (2015) Immunohistochemical Studies in Mice Liver Immunized by Attenuated *Schistosoma Mansoni* Schistosomules by Gamma Radiation. *Egypt J Hospt med*, **61**: 406-415.
39. Amin MM, Hafez EN, Abd Raboo MA (2016) Assessment of Radiation-Attenuated Vaccine or Thyme Oil Treatment on Controlling DNA Damage and Nitric Oxide Synthesis in Brain of Rat Infected with *Toxocara canis*. *Arab J Nucl Sci Appl*, **94** (2): 199-210.
40. Abd El Maguid A (2010) Studies of toxocariasis in tissues of rats infected with irradiated *Toxocara canis* eggs. *Egypt J Radiat Sci Appl*, **23**(1): 87.
41. Amin MM and Hafez EN (2015) Effect of Vaccination with Irradiated Tachyzoites on Histopathological Changes and DNA Damage in Hepatocytes of Experimental Toxoplasmosis. *Arab J Nucl Sci Appl*, **48**(4): 237-245.
42. Kamiya M, Ooi HK, Nomura T (1987) The effect of radiation on viability and migratory ability of second- stage larvae of *toxocara canis* in mice. *Vet Parasit*, **24** (1-2): 87-92.