Iran. J. Radiat. Res., 2004; 1(4): 229-231

Leiomyosarcoma of prostate; Report of a case

M. Vakilha[1], F.N. Dadgar [2*], T. Tirgari [3]

[1]Radiation-Oncology Dept., Tehran University of Medical Sciences, Tehran, Iran
[2]Novin Medical Radiation Institute, Tehran, Iran
[3] Pathology department, Cancer Institute, Tehran, Iran

ABSTRACT

Leiomyosarcoma is a rare entity in prostate but it is the most common type of prostate sarcomas in adult patients. In most reported series the prognosis is poor and the median survival is about 15-18 months. Hereby we present a 72 years old man who received combined modality treatment including radical surgery followed by adjuvant chemotherapy and radiotherapy. He has been well for 14 months, but now he is suffering from lung metastases and asymptomatic local recurrence. *Iran. J. Radiat. Res., 2004; 1(4): 229-231*

Keywords: *Prostate, leiomyosarcoma, radiotherapy, chemotherapy.*

INTRODUCTION

Leiomyosacoma is the most common sarcoma of prostate gland in adult males but, generally it accounts for less than 0.1% of primary prostate malignancies. The mean age of patients is about 50 years. Neoplasm is a mesenchymal tumor originating from smooth muscles of prostate. The most effective treatment, if feasible, is radical surgery. The role of adjuvant treatments and their effects in terms of increasing overal survival or disease free survival is not clearly defined .

CASE PRESENTATION

Our patient was a 72 years man with chief complaints of urinary symptoms like frequency, dribbling and hesitency with perineal pain. In rectal examination a firm and immobile prostatic mass was touched. This finding was confirmed by transrectal ultrasonography, the preoperative CT-Scan revealed a nonhomogenous prostatic mass without invasion to other organs and without lymph node involvoment (figure 1); thoracic CT-Scan was also normal. Chest radiography was normal and the preoperative PSA value was: 4/2 ng/ml .

Histopathology of transrectal biopsy was suspicious to malignancy therefore radical surgery was plannned. The pathologic examination revealed a high–grade spindle cell sarcoma, suggesting leiomyosarcoma with clear surgical margins.

In immunohistochemical examination the cells were weakly stained by Desmin, but EMA was negative and the result was compatible with leiomyosarcoma.

The patient was referred to our department for adjuvant treatments. He received one course of chemotherapy with three drug regimen: ifosfamide, dacarbazine and farmurobicin. After the first course, because the patient did not accept to continue chemotherapy, he was advised to receive radiotherapy.

The radiotherapy was performed with 4500 cGy as the box technique to whole pelvis and 1500 cGy as the boost dose to the prostatic bed with four oblique fields (figure 2). He was well for 10 months; however he returned with shortness of breath and the lung CT-Scan revealed multiple lung metastases. In rectal examination, a firm nodule was palpated but it

[*] **Corresponding author:**
Dr. F. N. Dadgar, Novin Medical Radiation Institute, Tehran, Iran. Fax: +98 21 8086782.
E-mail: dadgar601@yahoo.com

[Downloaded from ijrr.com on 2026-11-25]

was not symptomatic. Chemotherapy started with the MAID regimen. (Mesna, Adriamycin, Ifosfamide and Dacarbazine). He is still receiving chemotherapy and after 4 courses of cytotoxic therapy a partial response, both in imaging and symptoms, is observed.

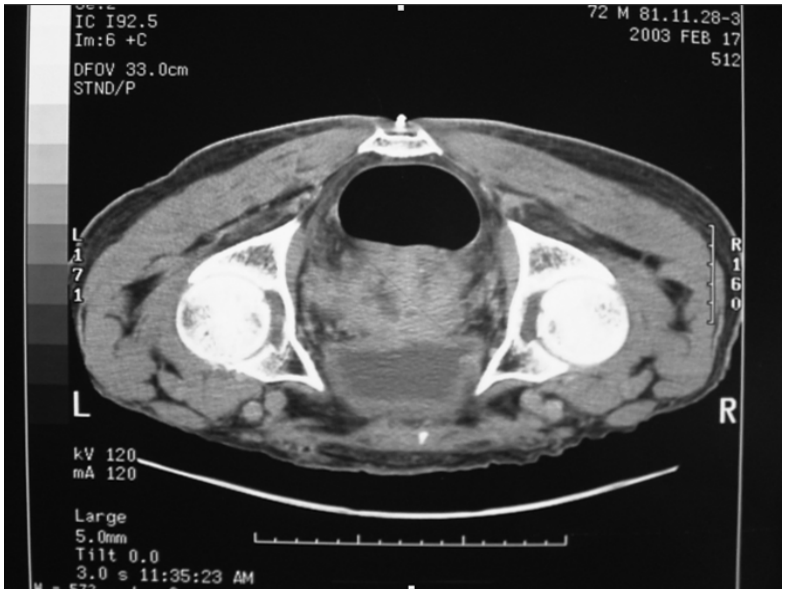

Figure 1. Preoperative CT-Scan.



Figure 2. Planning target volume.

DISCUSSION

Leiomyosarcoma of prostate is the most common type of sarcomas in prostate gland among adult patients.This pathology, in general accounts for less than 0.1% of prostate malignancies.This tumor is a mesenchymal tumor originating from smooth muscles of prostate. The median age of patients is about 50 years, ranging from 17 to 78 years. Most cases

[Downloaded from ijrr.com on 2026-11-25]

are presented with urinary symptoms such as: urinary obstruction, frequency, hesitency, perineal pain and sometimes with problems in defecation. About 25% of cases are presented with metastatic diseases at the time of diagnosis The most common sites of distant metastases are lungs (Sexton *et al.* 2001).

The disease tends to invade lymphatics and blood vessels, causing widespread regional lymphatic and distant metastases (Perez 1998). The most commonly used procedure to obtain histopothologic diagnosis is transrectal ultrasono-graphy guided biopsy. In light microscopic feature, cells usually appear in different spindle shapes due to amount of pleomorphism, necrosis and mitosis; however, the pathologic findings does not seem to affect prognosis. Most cells are stained with vimentin and actin and a few react to desmin in immunohistochemical staining. Serum PSA value is mostly within normal range. Long term survival is generally poor and median survival is about 15-18 months (Range: 5-95 months). Complete surgical excision and presence of distant metastasis seem to be the only significant independent prognostic factors.

The best treatment program has not been defined yet, but combined modality treatment seems to yield the best result (Kuroda *et al.* 1994). Surgical procedure is usually performed as radical cystoprostatectomy (Garcia *et al.* 1993). Neoadjuvant treatments including chemotherapy or chemo-radiation should be considered if preoperative staging shows locally advanced disease. In such cases situation protocols like preoperative chemo-radiation followed by surgery and intraoperative radiotherapy have been advised.

Chemotherapy regimens should consist of agents with activity against sarcomas like anthracyclins, ifosfamide, cyclophosphamide, dacarbazine. Anecdotal reports exist, using combinations like cisplatin, methotrexate and etoposide with acceptable efficacy (Sakano *et al.* 1995).

There is no optimal field arrangement and dose prescription in radiotherapy for leiomyosarcoma, but it seems at least 60 Gy tumor dose is needed for tumor control. Treatment failure is common and occurs both locoregionally via lymphatics and distantly via hematogenous metastasis. Close follow up after definitive therapy using careful physical examination and imaging of thorax, abdomen and pelvis should be performed.

ACKNOWLEDGMENT

Our special thanks to Dr. S. Shariat associate professor of pathology dept. of Tehran university of medical sciences.

REFERENCES

Kuroda H., Yasunaga Y., Takatera H., Fujioka H., Tsujimoto M. (1994). Leiomyosarcoma of the prostate accompanied by multiple hepatocellular carcinoma. *Hinyokika Kiyo.* ***40*****:** *147-9*

Oscar Garcia J. M., Alfaro Ferredo L., Ruiz J. L., Cunat A. E., Martinez J. J., Jimenez C. (1993). Leiomyosarcoma of the prostate, *Arch. Esp. Urol.,* ***46****: 831-833*

Perez C. (1998). Principles and practice of radiation oncology. ***1*****:** *1605-6*

Sakano Y., Yonese J., Okubo Y., Yoshimura K., Maeda H., Yamauchi T., Fukui S. (1995). Leiomyosarcoma of the prostate: a case report of remission for 9 years by radiotherapy. *Hinyokika Kiyo,* ***41*****:** *629-32*

Sexton W. J., Lance R. E., Reye A.O., Pisters P.W., Pisters L. L. (2001). Adult prostate sarcoma, the M.D Anderson center's experience. *J. Urol.,* ***166*****:** *521-525.*

[Downloaded from ijrr.com on 2026-11-25]