

Feasibility of stereotactic ablative reirradiation in breast cancer patient undergoing palbociclib: a case report

V. Nardone^{1*}, A. Reginelli², C. Vitale², M.G. Calvanese¹, P. Correale³, R. Grassi², S. Falivene¹, A. Sangiovanni², S. Cappabianca², C. Guida¹

¹Unit of Radiation Oncology, Ospedale del Mare, Naples, Italy

²Department of Precision Medicine, University of Campania "L. Vanvitelli", Naples, Italy

³Unit of Medical Oncology, Grand Metropolitan Hospital "Bianchi Melacrino Morelli", Reggio Calabria, Italy

ABSTRACT

► Case report

*Corresponding authors:

Valerio Nardone, MD,

E-mail: v.nardone@hotmail.it

Revised: February 2020

Accepted: June 2020

Int. J. Radiat. Res., April 2021;
19(2): 479-482

DOI: 10.29252/ijrr.19.2.479

Background: We report a case of a metastatic breast cancer woman undergoing therapy with fulvestrant and palbociclib that was successfully treated with thoracic stereotactic ablative radiation therapy (SABR) for a hilar lymph node metastasis. **Case Description:** The patient began the radiation treatment in the week off of the palbociclib and reported no acute toxicity. The CT scan showed acute pneumonia 60 days after RT although the patient reported no symptomatology. In addition, the subsequent PET/TC scan performed six months after RT exhibited a complete response of the irradiated lesion. **Conclusion:** The use of SABR in patients undergoing cyclin inhibitors appears to be potentially effective although the association must be further studied to investigate the toxicities.

Keywords: Cyclin inhibitors, breast cancer, SABR, stereotactic radiation therapy, reirradiation.

INTRODUCTION

Metastatic breast cancer (MBC) has been synonymous with a lethal outcome and is generally considered incurable, although an improvement in the overall survival (OS) has emerged during the last decades. However, survival rates remain to be low with 5-year and 10-year survival rates of 27% and 13%, respectively (1,2).

Defining the subgroups of patients suffering from this heterogeneous disease who might benefit from different treatment strategies is of great interest. One special subgroup comprises patients with limited tumor spread lying between localized early breast cancers and disseminated metastatic cancers, termed oligometastatic diseases. Particularly, oligometastatic tumors are characterized by low volume metastatic diseases with a limited number and a limited size of metastatic lesions

(up to five and not necessarily in the same organ), which are potentially amenable to local treatments that aim at achieving long-term remission (3,4).

In this regard, radiation therapy, especially for oligometastatic breast cancer patients, has shown its ability to achieve long-term progression free survival without significant treatment-related toxicities as in other pathologies (5-8). Its investigation with novel molecules will be necessary in the future for the optimal management of breast cancer patients, including the elderly.

The inhibitor of cyclin-dependent kinases (CDKs) 4 and 6 appears to be one of the most promising drugs in this setting. Normal cell replication progress is regulated by several proteins, including cycle dependent kinases. CDK 4/6 inhibitors target the formation of the CDK 4/6-cyclin D1 complex and block the phosphorylation of Rb to affect cell cycle arrest (9).

The association between palbociclib and RT is currently under investigation in clinical trials, as it is considered a potential weapon in patients with metastatic breast cancer, especially in an oligometastatic setting. Early studies have shown the radio-sensitizing effect of palbociclib on the breast cancer cells depending on the presence of a p53 wild type, independent of the inhibitory effect exerted on CDK4/6⁽¹⁰⁾. Only three small series have been published in the scientific literature in a palliative setting⁽¹¹⁻¹³⁾. The largest one was published by Ippolito *et al.*⁽¹²⁾, which demonstrated the feasibility of the concomitant treatment of CDK4/6 and radiotherapy; high-grade hematological toxicity was common, but it did not change the treatment course in most of the patients.

However, additional data on the safety of this association are necessary. In this regard, Messer *et al.*⁽¹⁴⁾ reported an early radiation toxicity onset in a patient receiving supraclavicular lymph node irradiation and palbociclib. The patient developed severe esophagitis and dermatitis that progressed to a severe left neck skin breakdown in the radiation field, resulting in the need for hospitalization. Similarly, Kawamoto *et al.*⁽¹⁵⁾ reported about a patient who developed severe enterocolitis after palliative radiation to pelvic bones.

This report aims to describe an MBC patient who underwent palbociclib and was successfully treated with stereotactic radiation therapy.

Case description

The reported patient was a 48-year-old female who was treated with lumpectomy and axillary dissection in January 2012 and then with radical mastectomy for a carcinomatous mastitis in October 2013.

Moreover, the patient underwent adjuvant therapies (chemotherapy and radiotherapy) from December 2013 to May 2014.

The subsequent follow up examinations were negative for recurrence till January 2017, when a PET/TC showed a subcutaneous nodule, in the intermammary sulcus, anterior to the left section of the body of the sternum (SUV max 4.7), that was surgically excised on February 2017 and whose histopathological examination

confirmed the recurrence of the disease.

A reevaluation PET after the surgical procedure (April 2017) reported the pathological consumption of FDG on the left paramedian section of the sternum body (SUV max 3.1) on the margins of surgical resection at the level of the intermammary sulcus. Therefore, adjuvant RT was performed in the left paramedian region of the sternum body (from April 2017 to May 2017, a total dose of 50 Gy in 25 fractions).

The patient was treated with fulvestrant and subsequently followed up with PET/CT scans.

In October 2018, PET/TC showed an adenopathy in the left retrolateral area characterized by an increase in FDG consumption (SUV max 5.5, figure 1). A thorax CT scan showed in the left hilum, posterior to the bronchus, a roundish formation, with regular margins, of about 18 mm of diameter, with contrast enhancement. The finding was ascribable according to the site and to densitometric strengthening with a lymph node recurrence. The patient started cyclin inhibitors (palbociclib) and was referred to our hospital to evaluate the feasibility of a radiotherapy approach.

After the revision of the previous radiotherapy plans (performed in 2014 and 2017), we decided to treat the nodal recurrence with stereotactic radiotherapy with a curative intent.

The patient underwent a 4D simulation CT scan, and we performed an elastic fusion between simulation CT and diagnostic CT and PET/TC scans. The gross target volume (GTV) was delineated on diagnostic scans and transferred to simulation CT. In addition, the GTV was deformably propagated across phases to obtain the internal target volume (ITV) using the MIM Maestro software, a commercially deformable image registration tool (MIM Software Inc., Cleveland, OH, US). The quality of contour propagation was inspected visually by a clinician with 25 years of experience in lung radiotherapy, and the modifications were made where required. The ITV was then expanded to 5 mm to obtain the planned target volume (PTV). The radiation dose was chosen considering the

dose constraints of the closer OARs (esophagus, trachea, aorta, and heart), as well the previous thoracic irradiations of the patient.

The patient underwent stereotactic RT on the target lymph node with 44 Gy in eight fractions (5.5 Gy/day, daily), which was prescribed at an

isodose of 80% of the PTV (figure 1).

The treatment started in the week off of palbociclib treatment, and the subsequent palbociclib cycle was deferred for three days, which began the day after the end of RT.

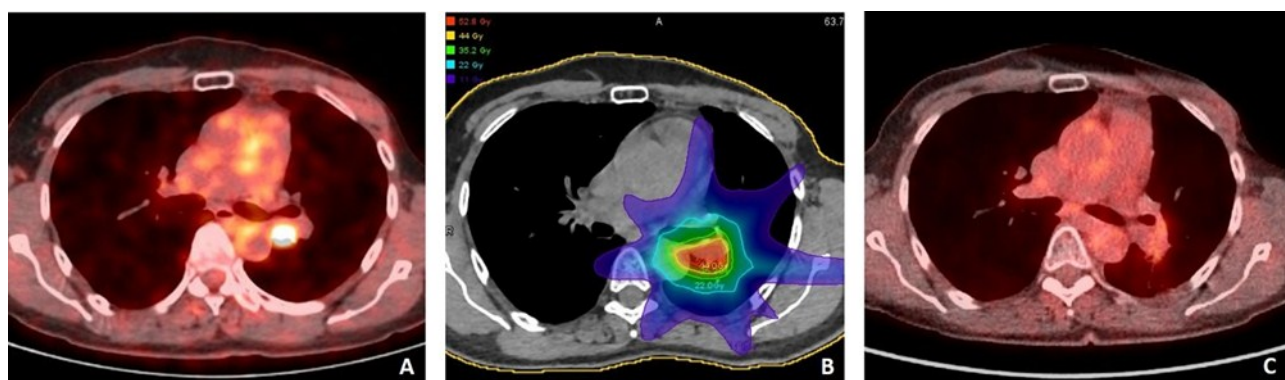


Figure 1. Pre-Radiotherapy PET/CT showed a SUV of 5.5 (Plate A). Stereotactic radiotherapy was performed with 44 Gy delivered in eight fractions (5.5 Gy/day, daily), prescribed at an isodose of 80% of the PTV (Plate B). Restaging PET/CT showed a complete response (Plate C).

CONCLUSION

The patient reported no acute or sub-acute toxicity during the radiation treatment and in the following weeks. However, the CT scan 60 days after the RT showed acute pneumonia, although the patient reported no symptomatology, which was successfully treated with steroids and antibiotics drugs. At the same time, the CT scan showed a good response to the irradiated lesion.

The PET/TC scan performed six months after the end of the RT showed a complete metabolic response of the irradiated lesion, with no signs of the disease recurrence in other districts (figure 1).

The association between CDKs inhibitors and radiation appears to be useful in terms of outcomes, although we need additional data on the safety of this combined approach at the present time.

Funding: Our study received University's grants by the University of Campania "Luigi Vanvitelli".

Conflicts of interest: Declared none.

Int. J. Radiat. Res., Vol. 19 No. 2, April 2021

REFERENCES

1. Eng LG, Dawood S, Sopik V, Haaland B, Tan PS, Bhoo-Pathy N, et al. (2016) Ten-year survival in women with primary stage IV breast cancer. *Breast Cancer Res Treat*, **160(1)**: 145-52.
2. Renzulli M, Zanotti S, Clemente A, Mineo G, Tovoli F, Reginelli A, et al. (2019) Hereditary breast cancer: screening and risk reducing surgery. *Gland Surg*, **8(3)**: S142-S9.
3. Cardoso F, Senkus E, Costa A, Papadopoulos E, Aapro M, Andre F, et al. (2018) 4th ESO-ESMO International Consensus Guidelines for Advanced Breast Cancer (ABC 4) dagger. *Ann Oncol*, **29(8)**: 1634-57.
4. Indolfi C, Cappabianca S, Rossi F, Perrotta S, Procaccini E, Pota E, et al. (2019) Abbreviated breast magnetic resonance imaging (FAST-MRI): A novel approach to breast cancer screening in patients with previous Hodgkin lymphoma. *Pediatr Blood Cancer*, **66(6)**: e27666.
5. Trovo M, Furlan C, Polesel J, Fiorica F, Arcangeli S, Gaj-Levra N, et al. (2018) Radical radiation therapy for oligometastatic breast cancer: Results of a prospective phase II trial. *Radiother Oncol*, **126(1)**: 177-80.
6. Reginelli A, Silvestro G, Fontanella G, Sangiovanni A, Conte M, Nuzzo I, et al. (2016) Validation of DWI in assessment of radiotreated bone metastases in elderly patients. *Int J Surg*, **33(1)**: S148-53.
7. Reginelli A, Calvanese M, Ravo V, Di Franco R, Silvestro G, Gatta G, et al. (2014) Management of breast cancer in elderly patients. *Int J Surg*, **12(2)**: S187-S92.
8. Ciaglia GF, Martino A, Sayad K, Scoglio C, Pezulla D, Cappabianca S (2016) Management of bone metastases

- from breast cancer in upper and lower body at the same time: A Case Report. *World J Oncol*, **7(2-3)**: 57-8.
9. Spring L, Bardia A, Modi S (2016) Targeting the cyclin D-cyclin-dependent kinase (CDK) 4/6-retinoblastoma pathway with selective CDK 4/6 inhibitors in hormone receptor-positive breast cancer: rationale, current status, and future directions. *Discov Med*, **21(113)**: 65-74.
 10. Nardone V, Falivene S, Giugliano FM, Gaetano M, Giordano P, Muto M, *et al.* (2019) The role of radiation therapy and systemic therapies in elderly with breast cancer. *Transl Cancer Res*, 2019.
 11. Hans S, Cottu P, Kirova YM (2018) Preliminary results of the association of Palbociclib and radiotherapy in metastatic breast cancer patients. *Radiotherapy and Oncology*, **126(1)**: 181.
 12. Ippolito E, Greco C, Silipigni S, Dell'Aquila E, Petrianni GM, Tonini G, *et al.* (2019) Concurrent radiotherapy with palbociclib or ribociclib for metastatic breast cancer patients: Preliminary assessment of toxicity. *Breast*, **46**: 70-4.
 13. Meattini I, Desideri I, Scotti V, Simontacchi G, Livi L (2018) Ribociclib plus letrozole and concomitant palliative radiotherapy for metastatic breast cancer. *Breast*, **42**: 1-2.
 14. Messer JA, Ekinci E, Patel TA, Teh BS (2019) Enhanced dermatologic toxicity following concurrent treatment with palbociclib and radiation therapy: A case report. *Rep Pract Oncol Radiother*, **24(3)**: 276-80.
 15. Kawamoto T, Shikama N, Sasai K (2019) Severe acute radiation-induced enterocolitis after combined palbociclib and palliative radiotherapy treatment. *Radiother Oncol*, **131**: 240-1.