

Eventual study of ultraviolet B radiation and their peril on thyroid gland of female Wistar rat

G. Rai and P. Mahobiya*

Department of Zoology, Dr Harisingh Gour (A Central University) Vishwavidyalaya, Sagar (M.P.), India

► Short report

***Corresponding author:**

Payal Mahobiya, Ph.D.,

E-mail:

1607payal@gmail.com

Received: May 2021

Final revised: September 2021

Accepted: September 2021

Int. J. Radiat. Res., April 2022;
20(2): 507-510

DOI: 10.52547/ijrr.20.2.36

Keywords: UVB radiation, hormones, hyperthyroidism, curcumin, female Wistar rat.

ABSTRACT

Background: The present study was carried out to estimate the effect of Ultraviolet B (UVB) radiation on the thyroid gland of female Wistar rats. **Materials and Methods:** Female rat (n=24) of 12-16 weeks with body weight of 130-150gm were housed in standard cages, fed sterilized food and water ad libitum. Animals were divided into four groups. Ist group was control, IInd group was exposed to 280 nm of UVB radiation for 2 h/day. IIIrd group was exposed to 280 nm of UVB radiation for 2 h/day and 25 mg/kg body weight curcumin orally. IVth group was given 25 mg/kg body weight curcumin orally. All treatments last for 15 days. **Results:** The results showed that UVB radiation decreased body and thyroid gland weight. However at the same time increased T3, T4, FT3, and FT4 levels ($p<0.01$; $p<0.001$; $p<0.05$) and decreased the level of TSH ($p<0.001$) significantly. Histologically, UVB radiation-damaged follicular cells and disappeared colloid fluid, and decreased follicle diameter significantly ($p<0.01$). **Conclusion:** It is concluded that UVB radiation generates imbalance in thyroid hormones and induced hyperthyroidism on female Wistar rat and curcumin play protective role in hyperthyroidism against UVB radiation.

INTRODUCTION

UV radiations carry both positive and negative effects and affect the health of animals with humans. UV radiations are non-ionizing, electromagnetic and categorized into three kinds, UVB and UVC. UVC is ranging 200-280 nm and detrimental than UVB (280-320nm) and UVA (320-400nm) (1-3). The exposure of animals to radiation is the worldwide and lifelong event with numerous beneficial and adverse effects on the individual (1). UVB radiations generate free radicals, cause oxidative stress, damage the cells, and affect the endocrine system and their physiological process like the action of thyroid hormones and ovarian cycle, etc(2). Although classically considered resistant to acute effects of radiation(3), thyroid gland has proved to be particularly sensitive to long-term effects of radiation exposure as demonstrated in studies of human subjects exposed to sub lethal radiation doses(4). It is believed that hormones and their receptor are the first line of health to be adversely affected in electromagnetics radiations (5). Both hypothyroidism and hyperthyroidism are associated with oxidative stress, moreover thyroid hormone-induced oxidative damage is believed to be factor responsible for progression of heart failure, as suggested by benefit of T3 administration on antioxidant systems in heart after pharmacological-induced hypothyroidism (6, 7).

Many forms of non-ionizing radiation caused the morphological and physiological changes in thyroid gland (8).

The present study was designed to estimate the effect of UVB radiation on histopathological changes in thyroid follicles and thyroid hormones concentration in female rats.

MATERIALS AND METHODS

Chemicals

Curcumin, Hematoxylin, Eosin obtaining from Himedia, and rest used chemicals were bought from Central Drug House Private Limited, New Delhi.

Experimental setup

Animals were irradiated in UVB chamber measuring 120×56×56 cm. UVB source was high pressure mercury developed by Philips, generating radiations range from 280-320nm, and distance between UV generator lamp and animals were 10cm. Animals were irradiated being 2 h/day for 15 days.

Experimental design and treatment

12-16 weeks with body weight of 130-150gm were obtained from Veterinary Sciences and Animal Husbandry College, Mhow M.P, India. The present study was approved by animal ethical committee,

Department of Pharmaceutical Sciences Dr. Harisingh Gour Vishwavidyalaya, Sagar (M.P.), India (379/Go/ReBi/S/01/CPCSEA) and followed the international guidelines of laboratory animals. Female rats were divided into four groups as follows:

1st Group: (Control) standard diet and water ad libitum.

2nd Group: (UVB exposed) exposed to 280 nm of UVB radiation for 2 h/day for 15 days.

3rd Group: (UVB exposed + Curcumin) exposed to 280 nm of UVB and curcumin (25 mg/kg BW) orally for 15 days.

4th Group: (Curcumin) 25 mg/kg BW curcumin orally for 15 days.

Body and thyroid weight

Initially weight of body weight was recorded at 5 days interval using an electronic balance (Sartorius, BP210 S). After dissection thyroid weight was measured.

Collection of blood samples

At the end of experiment, each group of animals were anesthetized with chloroform, and blood samples were collected by cardiac puncture. The blood was taken for hormonal estimation.

Thyroid Hormone Measurements

Thyroid hormones were measured using Enzyme-Linked Immunosorbent Assay (ELISA) kit provided by The Calbiotech Inc. (California, USA) as per the method applied for hormone concentration in serum and OD taken at 450nm from ELISA reader (Thermo Scientific, Multiskan GO, 1510-04-154C)⁽⁹⁾.

Histology

Animal body perfusion was done through the heart using Zamboni fixative⁽¹⁰⁾. Thyroid gland was removed and kept in fixative for 48 hours. Fixed tissues were dehydrated in ascending grades of alcohol, cleared with xylene, and embedded into paraffin. Then 5µm sections were cut and stained with hematoxylin and eosin. Analyse thyroid follicles under microscope on 10x and 40x magnifications.

Statistical analysis

The Results expressed as mean±SE. Statistical

analysis was performed by using ANOVA Dunnet test was applied for between control and each treated groups individually. The difference was considered as statistically significant when $P < 0.05$. #significant difference curcumin as compare to UVB treated group.

RESULTS

Body and thyroid weight

The IInd UVB exposed group showed a significant reduction in the body and thyroid weight as compared to 1st control group and 3rd group observed that curcumin treatment increased body and thyroid weight significantly ($p < 0.01$) as compared to UVB and no significant changes of 4th positive curcumin group shown in figure 1.

Thyroid hormones

Thyroid hormones showed hyperthyroidism. IInd group UVB exposed Wistar rats showed significant increases in T3 ($p < 0.01$), T4 ($p < 0.05$), FT3 and FT4 level ($p < 0.01$) as compared to 1st control group. 3rd group, administration of curcumin significantly decreased ($p < 0.001$) level of T3 ($p < 0.001$), T4, FT3 and FT4 levels ($p < 0.001$). TSH level showed significant decrease ($p < 0.001$) was observed on IInd UVB exposed group while a significant increase ($p < 0.001$) was observed in IIIrd UVB+Cur group and no changes of 4th positive curcumin group shown in figure 2.

Histological statement

Histological statement had revealed modifications of thyroid structure after UVB exposure and curcumin treatment in Wistar rat. In UVB exposed group, thyroid follicles were damaged and significantly ($p < 0.01$) decrease in diameter of follicles was observed, however administration of curcumin repaired follicles and significantly ($p < 0.01$) increased follicle diameter and no changes of positive curcumin group shown in figure 3.

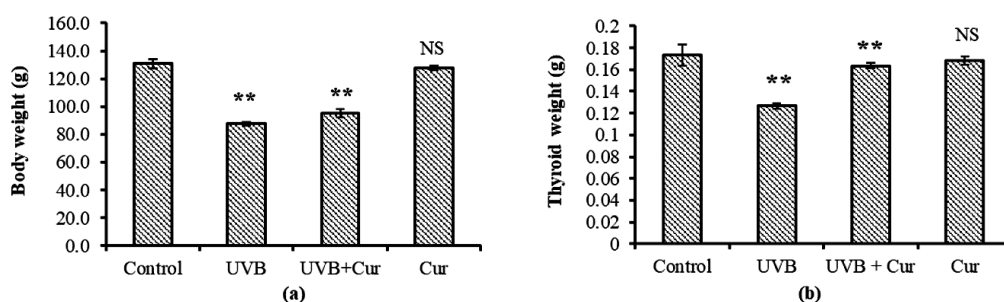


Figure 1. Effect of UVB Radiation and role of curcumin on (a) body and (b) thyroid weight.

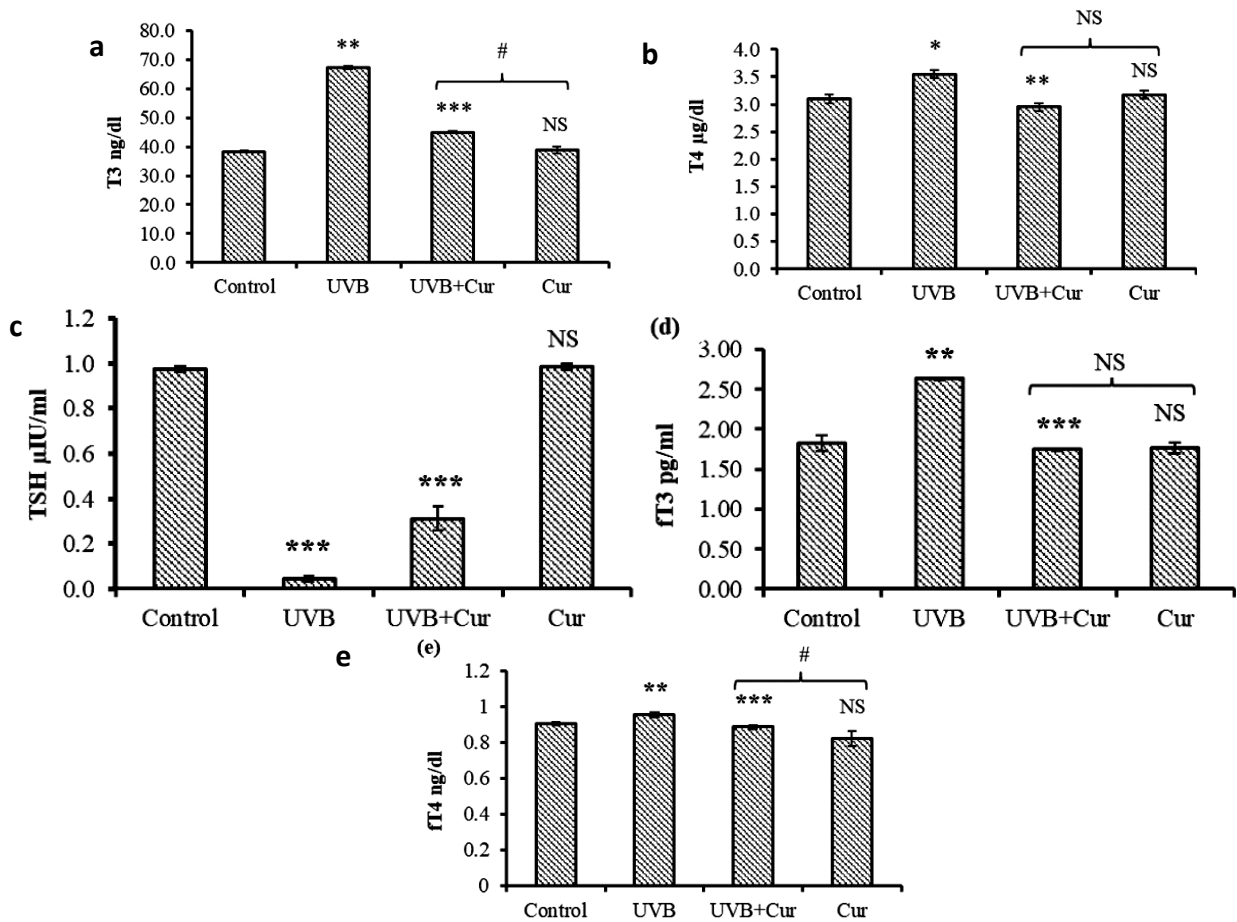


Figure 2. Effect of UVB exposure and curcumin on Thyroid hormones levels (a) T3, (b) T4, (c) TSH, (d) FT3, and (e) FT4.

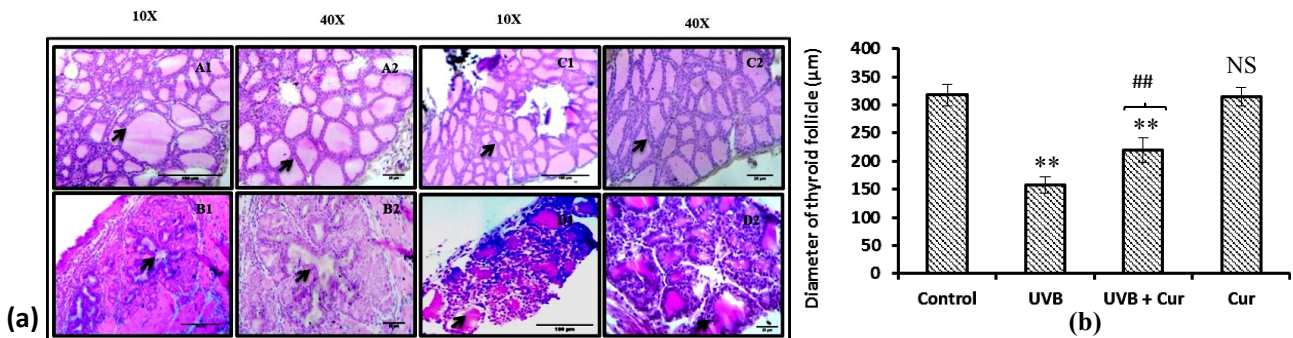


Figure 3. Effect of UVB Radiation and curcumin on (a) Thyroid histology (b) follicles diameter. A1&A2 indicate the control group, B1&B2 indicate UVB exposed group, C1&C2 indicate the UVB+Cur group and D1&D2 indicate Curcumin group. Magnification 10X and 40X)

DISCUSSION

The present study described the effect of UVB exposure on female Wistar rat and their risk on thyroid gland. The results of this study UVB irradiation caused oxidative damage in Wistar rat thyroid as exhibited by increased T3 and T4 levels and decreased TSH levels. UVB irradiation lead to significant loss of body and thyroid weight, our results were in line to those of (11,12). We found that UVB radiation caused oxidative stress and generate free radicals and stimulate hyperthyroidism condition. In hyperthyroidism T3, T4 were significantly increased whereas TSH was significantly decreased. In our study, we used curcumin as an

antioxidant (13). Administration of curcumin lead to decreased in T3, T4, FT3 and FT4 levels as compare to UVB exposed group. Antioxidant accuracy positively transformed thyroid levels. As a known fact that thyroid hormone plays a very important role in metabolism, growth and development of body (14). In other studies, stimulus of 50 Hz electromagnetic frequencies for 2–6 months on male rats exposed from 1-day old and the effect of electromagnetic frequencies on thyroid follicular epithelium, follicular colloid content, interfollicular connective tissue and mast cells. The observed changes pointed to a lowered thyroid activity after 3, 5 and 6 months of exposure and enhanced thyroid activity after 2 months (8, 15, 16). Other studies, Electromagnetic

frequencies sensitive for thyroid gland and stimulated morphological modifications with drop off in serum T4 and T3. These modifications remained to the end of experiment signifying that a longer period of time is required for return of normal thyroid activity after electromagnetic frequencies exposure (17).

CONCLUSION

UVB radiation caused hyperthyroidism. UVB exposure significantly increased T3 and T4 level and decreased TSH level. UVB exposure decreased body and thyroid weight significantly. Curcumin supplementation in hyperthyroidism could apply beneficial effects in favour of imbalance of thyroid hormone and maintain body and thyroid weights induced by UVB exposure and also maintain thyroid diameter and repair damaged follicles cells.

ACKNOWLEDGEMENT

Authors wish to thanks Department of Zoology, School of Biological Sciences, Dr. Harisingh Gour Vishwavidyalaya, Sagar, M.P., India, for providing infrastructure facilities.

Conflicts of interest: Declared none.

Ethical considerations: This study was approved by animal ethical committee, Department of Pharmaceutical Sciences Dr. Harisingh Gour Vishwavidyalaya, Sagar (M.P.), India (379/CPCSEA/IAEC-2018/2017) and followed the international guidelines of laboratory animals.

Author contributions: GR and PM conceived and designed the study. GR carried out the experiment and analyzed the data. Both authors drafted revised and approved the final manuscript.

Financial support: This research work was financially assisted by RGNF with award no. F1-17.1/2017-18/RGNF-2017-18-SC-MAD-42745/ (SA-III/Website) for carrying out this research.

REFERENCES

- Vandersee S, Beyer M, Lademann J, Darvin ME (2015) Blue-violet light irradiation dose dependently decreases carotenoids in human skin, which indicates the generation of free radicals. *Oxid Med Cell Longev*, **2015**: 1-7.
- Rai G, Namdev N, Mahobiya P (2020) Ascorbic acid and curcumin alleviate abnormal estrous cycle and morphological changes in cells induced by repeated ultraviolet B radiations in female Wistar rats. *Asi Paci J Reprod*, **9**(3):142-147.
- Rubin P and Casarett GW (1968) Clinical radiation pathology as applied to curative radiotherapy. *Cancer*, **22**(4): 767-778.
- Todorovic-Dilas L, Bajkin I, Icin T, Novakovic-Paro J, Kovacev-Zavicic B (2012) Iodine and thyroid gland with or without nuclear catastrophe. *Med Pregl*, **65**(11-12): 489-495.
- Hajjoun B, Jowhari H, Mokhtari M (2014) Effects of cell phone radiation on the levels of T3, T4 and TSH, and histological changes in thyroid gland in rats treated with Allium sativum extract. *African J Biotechnol*, **13**(1): 163-169.
- Chattopadhyay S, Zaidi G, Das K, Chainy GB (2003) Effects of hypothyroidism induced by 6-n-propylthiouracil and its reversal by T3 on rat heart superoxide dismutase, catalase and lipid peroxidation. *Indi J Exp Biol*, **41**: 846-849.
- Mahobiya P (2020) Protection against ultraviolet B radiation-induced oxidative damage by antioxidants on liver of female Wistar rat. *Int J Sci Stud*, **7**(12): 95-98.
- Rajkovic V, Matavulj M, Johansson O (2006) Light and electron microscopic study of the thyroid gland in rats exposed to power-frequency electromagnetic fields. *J Exp Biol*, **209**(17): 3322-3328.
- Sachidhanandam M, Singh SN, Salhan AK, Ray US (2010) Evaluation of plasma hormone concentrations using Enzyme-immunoassay/ Enzyme-linked Immunosorbent assay in healthy Indian men: Effect of ethnicity. *Ind J of ClBiochem*, **25**(2): 153-7.
- Niranjan MK, Koiri RK, Srivastava R (2021) Expression of estrogen receptor alpha in response to stress and estrogen antagonist tamoxifen in the shell gland of Gallus gallus domesticus: involvement of anti-oxidant system and estrogen. *Stress*, **24**(3): 261-272.
- Venditti P and Di Meo S (2006) Thyroid hormone-induced oxidative stress. *Cell Mol Life Sci*, **63**(4): 414-434.
- Petrulea M, Muresan A, Duncea I (2012) Oxidative stress and antioxidant status in hypo- and hyperthyroidism. *Antioxid Enzym*, **8**: 197-236.
- Rathore S, Mukim M, Sharma P, Devi S, Chandra Nagar J, Khalid M (2020) Curcumin: A Review for Health Benefits Kingdom of Saudi Arabia. *Int J Res Rev*, **7**(1): 273-290.
- Peepre K, Deshpandey U, Choudhary PS (2014) Role of antioxidants on thyroid hormones in Wistar rats. *Int J Sci Res*, **3**(1): 34-38.
- Rajkovic V, Matavulj M, Lukac T, Gledic D, Babic L, Lazetic B (2001) Morphophysiological status of rat thyroid gland after subchronic exposure to low frequency electromagnetic field. *Med Pregl*, **54**(3-4): 119-127.
- Matavulj M, Rajkovic V, Uscebrka G, Lukac T, Stevanovic D, Lazetic B (2000) Studies on the possible endocrinological effects of 50 Hz electromagnetic field. *Cent Eur J Occup Environ Med*, **6**(2/3):183-188.
- Mohamed DA and Elnegris HM (2015) Histological study of thyroid gland after experimental exposure to low frequency electromagnetic fields in adult male Albino rat and possible protective role of Vitamin E. *J Cytol Histol*, **6**(6):1-8.