

The application of automated volume scanner in bone age assessment

J. Shi¹, Y. Chen², L. Yang¹, Z. Ni³, J. Du^{1*}, Q. Wang^{1*}

¹Department of Imaging Diagnosis Center, Shanghai Children's Medical Center, School of Medicine, Shanghai Jiao Tong University, Shanghai 200127, P.R. China

²Department of Endocrinology and Genetic Diseases, Shanghai Children's Medical Center, School of Medicine, Shanghai Jiao Tong University, Shanghai, 200127, China

³Ultrasound Department, Siemens Healthineers Ltd. China

► Original article

ABSTRACT

*Corresponding authors:

Jun Du, MM.,

Qian Wang, MM, Ph.D.,

E-mail:

duizhi0360603636@163.com,

wfv313@163.com

Received: September 2021

Final revised: March 2022

Accepted: May 2022

Int. J. Radiat. Res., October 2022;
20(4): 767-772

DOI: 10.52547/ijrr.20.4.6

Background: Radiograph of hand and wrist has been widely used in children's bone age assessment (BAA). However, ionizing radiation may be harmful for children in the future. Therefore, alternative methods have been attempted for the evaluation of children's bone age. Here, we reported an automated volume scanner (AVS) in assessing the biological age of children in comparison with X-ray radiograph as the gold standard. **Material and Methods:** Total 22 children (13 male and 9 female) with short stature or precocious puberty were enrolled into this study. Their chronological age ranged from 4 to 14 years old. The children's left hand-wrist was scanned with the AVS by putting them into a water sink containing tape water. Coronal images of the left hand-wrist were reconstructed and compared with X-ray images. **Results:** The number of patients whose hand-wrist bones (except for the first metacarpal sesamoid bone and the secondary ossification center of the first metacarpal bone) identified by AVS image was not significantly different from that by X-ray image. In addition, the total number of observed bones in each patient were not significantly different between the two methods. The concordance rate (percentage of patients whose hand-wrist bone presented in both AVS image and X-ray image) was high and the inter-observer variance of BA was small. **Conclusions:** The AVS method was highly correlated with the standard radiograph for children's bone age assessment with small inter-observer variability. This novel AVS method could be an alternative method in clinical practice for bone age assessment with higher safety and reliability.

Keywords: radioactive automated volume scanner, bone age assessment, chronological age.

INTRODUCTION

Bone age (BA), an interpretation of skeletal maturity, is a vital index to assess the biological age of a child. Bone age assessment (BAA) is mainly applied to determine the physical development status of children with growth disorders and endocrinological abnormalities. Early in the 1990s, skeletal atlases were developed for reference in bone age assessment, for example, the American Atlas developed by Greulich and Pyle (GP) and the British Atlas developed by Tanner and Whitehouse (TW), the two most common atlases ^(1, 2). Since then, several other atlases were developed because of the variation of era, ethnicity, and country, such as Tanner-Whitehouse second edition (TW2) and Tanner-Whitehouse third edition (TW3) ^(3, 4). By comparing the bone appearance in radiograph with the corresponding graph of bone shown in the atlas, the pediatrician could estimate the discrepancy between the biological age and the chronological age that refers to the growth time starts from the birth date.

Although the effective dose of a hand X-ray is

small (0.001 mSv) ⁽⁵⁾, children with growth disorders need repeated BAA to follow the skeletal development at an interval of once or twice per year during the treatment process especially for those treated with growth hormone ⁽⁶⁻⁸⁾. The main problem of repeated hand X-rays is the cumulative ionizing radiation which may put potential health problem for children ^(9, 10). For example, the lifetime risk of cancer attributable to X-ray exposure in childhood is up to about 5-15% per Sv ⁽¹¹⁾. Therefore, X-ray dose reduction in childhood is crucial to avoid detrimental health problem in later life.

Ultrasound-based techniques without ionizing radiation that provide alternative imaging modalities for BAA has been attempted to address the issue of radiation damage ⁽¹²⁻¹⁴⁾. However, the outcomes of bone age assessment by ultrasonography were variable. In this regard, quantitative ultrasound techniques (QUST) were used to assess skeletal age by quantifying the cartilage overlying layers of the femoral head, however, the comparison with the bone age by GP showed poor agreement ⁽¹⁵⁾. Monica Daneff *et al.* proposed a conventional ultrasound technique in

bone age assessment, whereas their ultrasound charts were not compared with the gold-standard radiographs ⁽¹⁶⁾.

Given the drawbacks of ultrasound-based techniques published previously, we herein introduced a new ultrasound scanning method for assessing the bone age, which was an automated volume scanner (AVS) method. A full-field volume of the interested subject (left hand and wrist) as well as complete coronal images of the target bone area were able to acquire by the AVS, which is novel compared to previously report ultrasonic method in BAA application. This study aimed to determine the concordance rate of each bone of hand-wrist shown in AVS images in comparison with the standard X-ray images, and to evaluate the possibility of AVS as an alternative method of X-ray examination in the assessment of the developing status of hand-wrist bones.

MATERIAL AND METHODS

Subjects

Children with clinically suspected growth disorders who were required to undergo X-ray examination in the Shanghai Children's Medical Center from Mar 2018 to Nov 2018 were enrolled into this study. The X-ray radiographs and AVS ultrasound images of the left hand-wrist were taken separately in the Radio-diagnosis Center of Shanghai Children's Medical Center. Patients with the following diseases were excluded: major malformations, congenital infections, metabolic disorders, and diseases associated with the left hand indicated by any radiographs. This study protocol was approved by the ethics committee of Shanghai Children's Medical Center (No. SCMCIRB—K2020008-1). Informed consent was obtained from the parents of each participant.

X-ray examination

Standard anteroposterior radiographs of the left hand and wrist were acquired by experienced technicians using a Digital X-ray diagnostic system (Digital Diagnostic DR, Philips Medical Systems, Cleveland, OH, USA), operating at 46 kV and 2.5 mAs, with an exposure time of 10.1 ms and focus-receptor distance of 1 meter. The procedure was following the instructions of Greulich and Pyle ⁽¹⁾: left-hand palm was faced down and positioned flat on the cassette; the middle finger axis was kept in line with the forearm axis; the upper arm and forearm were at the same horizontal plane; the fingers were separated without touching each other; the thumb rotated naturally with an angle of about 30° apart from the index finger; the X-ray tube was focused on the third metacarpophalangeal joint; X-ray film should cover all the hand fingers, metacarpal bones, carpal bones, and at least 4 centimeters of the distal radius and

ulna. The radiation dose was 0.001 mSv per exposure to get clear hand X-ray images.

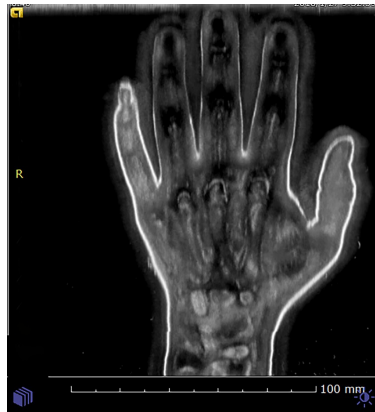AVS ultrasound scanning

AVS ultrasound examination was performed within 2-5 days after X-ray examination by two sonographers using the Siemens ACUSON S2000 ultrasound system (Siemens Medical Solutions, Mountain View, CA, USA) with an integrated Siemens 14L5BV linear transducer for automated and consecutive scanning. Tap water was used as a coupling medium for the AVS examination. The left hand and forearm of a child were plainly put in the water sink. The window of the scanner was immersed into the water and contacted with the child's skin. The touch pressure threshold was set at one pound and the scanner window was fixed for scanning (figure 1). During scanning, the ultrasonic probe was adjusted to be in vertical position to the left hand and left forearm. The settings of AVS examination were as the followings: Dynamic Range was set at a low degree of 55dB to elevate contrast resolution, which would help to improve bone display; Depth was set at a relatively high level of 5-6 cm to show the long-distance field image, which in turn could show the full range of the skeleton; Frequency was reduced to 8MHZ to improve ultrasonic penetration, which would help to display the skeleton of the far-field; Focus was set at below the middle of the image to improve the quality of the far-field ultrasonic image, thus helping to display the skeleton of the far-field; Enhance the dynamic tissue contrast enhancement (DTCE) to the M level in order to reduce the noise and improve the contrast resolution, and to make the bone image clearer; The scanning time was set as either 60 seconds or 90 seconds. After the acquisition, all volume image series were automatically sent from the ultrasonic instrument to a dedicated ultrasound review workstation. The workstation reconstructed the images from acquisition volume to a coronal plane (figure 2), which was similar to the hand-wrist radiograph taken via X-ray.




Figure 1. Schematic diagram of scanning method. Tap water was used as coupling medium. Left hand of the child was plainly put into the water sink. Window part of the scanner was immersed into water and contacted with the child's skin. The touch pressure threshold was set at one pound. The fixed scanner window was fixed for scanning.

Figure 2. An example of automated volume image (AVI) of the whole left hand (a 10-year-old boy) reconstructed by the workstation.



Data analysis

The hand-wrist bones in AVS images were compared with that in X-ray images to confirm consistency, and the concordance rate (percentage of patients whose hand-wrist bone presented in both AVS image and X-ray image) was calculated. Consistency of the bone ages indicated by AVS image and X-ray image was determined by comparing the AVS image with the X-ray image.

Reliability of the AVS examination in bone age assessment was verified by comparing each hand-wrist bone in AVS image with that in matched X-ray image. When analyzing each bone, the number of patients whose hand-wrist bone was found in AVS or X-ray examination was recorded, respectively. For each patient, the total number of hand-wrist bones seen in AVS image or X-ray image were recorded, respectively. Data analysis was performed via Graphpad (version 8.0). Paired *t* test was used for comparison between two groups. Data was expressed as mean \pm standard deviation (SD). $P < 0.05$ was considered significantly different.

Interobserver reliability analysis of AVS method was also performed. Both Observer A and B were sonographers with more than 10 years (A) or 5 years (B) of ultrasonic work experience. Each bone image obtained by AVS examination was evaluated by the two Observers independently. Consistency of the evaluation (each hand-wrist bone was seen or not) by Observer A and B was analyzed using Bland Altman Test.

RESULTS

Demographic characteristics of the children

As shown in table 1, a total of 22 children including 9 girls and 13 boys were finally enrolled into this study. Of them, 2 children were diagnosed as precocious puberty, and the rest 20 children were diagnosed as short stature. Their chronological age ranged from 4 to 14 years old, with an average chronological age of 8.9 ± 3.4 years old.

Comparison of hand-wrist bone display rates between the two methods

A total of 30 hand-wrist bones, which were often

Table 1. Demographic characteristics of the participants.

Characteristics	Value
Chronological Age, years, mean \pm standard deviation	8.9 \pm 3.4
Male, n (%)	13 (59%)
Female, n (%)	9 (41%)
Known indications for the examinations	
Short stature	20 (91%)
Precocious puberty	2 (9%)

used for BAA, were evaluated. As shown in figures 3 and 4, images of left hand (figure 3) and wrist (figure 4) obtained by AVS method were highly qualitative and identical with that of the standard X-ray radiographs. There was no significant difference between AVS and X-ray methods in terms of the number of patients whose hand-wrist bones were identified by AVS sonography or X-ray radiography (figure 5). However, the number of patients whose first metacarpal sesamoid bone observed by AVS method was significantly lower than that by X-ray radiograph ($P < 0.05$, figure 5). Similarly, when assessing the secondary ossification center (SOC) of the first metacarpal bone, the number of patients observed by AVS method was also significantly lower than that by X-ray method ($P < 0.05$, figure 5). In addition, the total number of bones in each patient identified by AVS sonography or traditional X-ray radiography was not significantly different (figure 6).

Interobserver reliability

The consistent rate of the observation results assessed by observer A and observer B was expressed as percentage. The concordance rates of the carpal bones including capitate bone, hamate bone, triangular bone, semilunar bone, trapezium bone, scaphoid bone, trapezoid bone, pisiform bone, radius bone, and ulna bone were 100%, 100%, 95.45%, 100%, 81.82%, 100%, 100%, 95.45%, 100%, and 95.45%, respectively; the concordance rates of the first phalanx including first metacarpal bone, first proximal phalanx, first distal phalanx, and sesamoid bone were 77.27%, 86.36%, 90.91%, and 95.45%, respectively; the concordance rates of the second phalanx including second metacarpal bone, second proximal phalanx, second middle phalanx, and second distal phalanx were 95.45%, 95.45%, 100%, and 90.91%, respectively; the concordance rates of the third phalanx including third metacarpal bone, third proximal phalanx, third middle phalanx, and third distal phalanx were 95.45%, 95.45%, 100%, and 90.91%, respectively; the concordance rates of the fourth phalanx including fourth metacarpal bone, fourth proximal phalanx, fourth middle phalanx, and fourth distal phalanx were 95.45%, 95.45%, 100%, and 95.45%, respectively; and the concordance rates of the fifth phalanx including fifth metacarpal bone, fifth proximal phalanx, fifth middle phalanx, and fifth distal phalanx were all 100%. Furthermore, as shown in figure 7, consistency between the two observers was high.

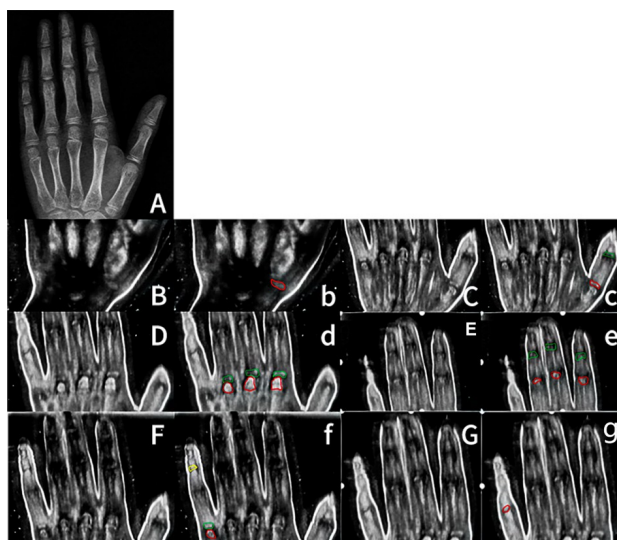


Figure 3. Comparison of left-hand X-ray radiograph and AVIs of a 10.5-year-old girl. Panel A: X-ray image of the metacarpal bone and phalanges. Panel B, C, D, E, F, and G: Different layers of AVIs. Panel b: Red line indicated secondary ossification center of the first metacarpal bone. Panel c: Red and green lines indicated the secondary ossification centers of the first proximal phalanx and the first distal phalanx, respectively. Panel d: Red lines indicated the secondary ossification centers of the second, third and fourth metacarpal bones, and green lines indicated the secondary ossification centers of the second, third, fourth proximal phalanx. Panel e: Red lines indicated the secondary ossification centers of the second, third and fourth middle phalanx, and green lines indicated the secondary ossification centers of the second, third, fourth distal phalanx. Panel f: Red, green, and yellow lines indicated the secondary ossification centers of the fifth metacarpal bone, fifth proximal phalanx, and fifth distal phalanx, respectively. Panel g: Red line indicated the secondary ossification center of the fifth middle phalanx.

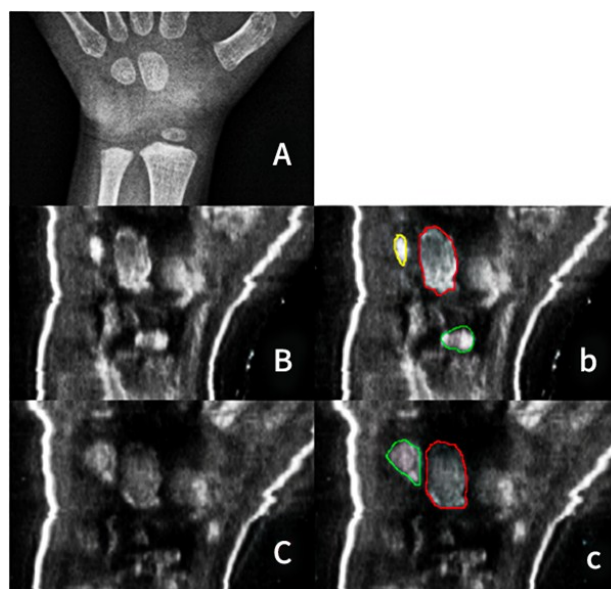


Figure 4. Comparison of left wrist X-ray radiograph and AVIs of a 4-year-old boy. Panel A: X-ray image of the left wrist. Panels B and C: Different layers of AVIs of the left wrist. Panel b: Red, green, and yellow lines indicated capitate bone, the secondary ossification center of radius, and part of the hamate bone, respectively. Panel c: Red and green lines indicated capitate bone and hamate bone, respectively.

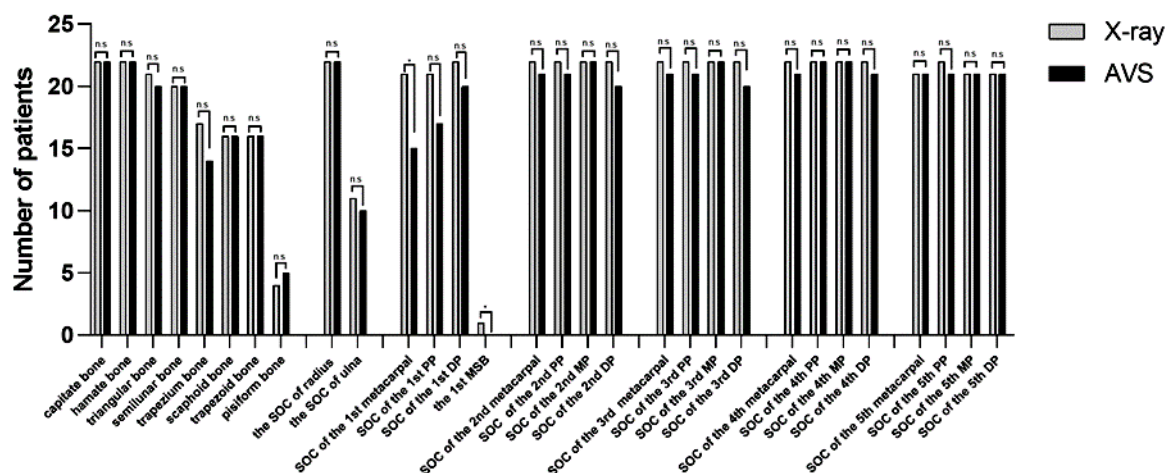


Figure 5. Comparison of the display rates of each bone in AVS image and X-ray image. SOC: secondary ossification center, PP: proximal phalanx, DP: distal phalanx, MP: middle phalanx, MSB: metacarpal sesamoid bone. * $P < 0.05$, n.s: no significance.

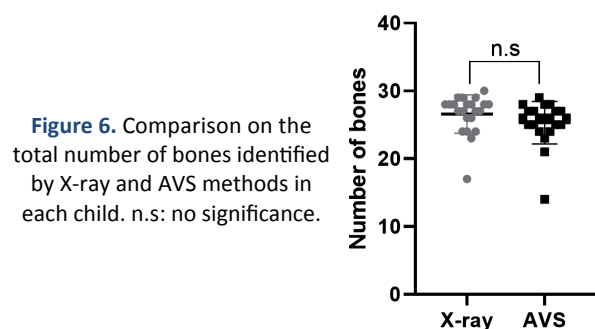


Figure 6. Comparison on the total number of bones identified by X-ray and AVS methods in each child. n.s: no significance.

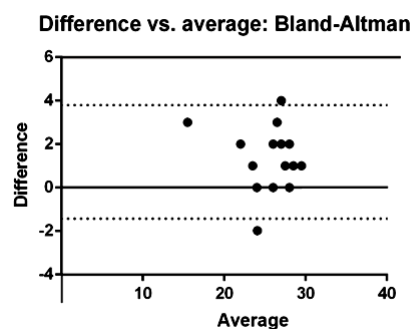


Figure 7. Bland Altman plot for the interobserver difference. Black dashed line: 95% CI.

DISCUSSION

Bone age generally refers to biological age determined by comparing the actual bone development status with atlas of bone at various age stages. BAA is widely applied in clinical medicine, preventive medicine, sports science, and forensic medicine ⁽¹²⁾. In the past several decades, hand and wrist radiograph and its analysis with Greulich-Pyle (GP) or Tanner-Whitehouse (TW) atlases has been widely used as standard method in the BAA. Recently, due to the progress in the area of computer-aided diagnosis and application of artificial intelligence in medicine, several automatic BAA programs have been invented. Here, we reported that the AVS method, which was as sensitive and reliable as the standard X-ray radiograph, could be used as an alternative method for BAA in children with short stature and precious puberty.

Previous studies indicated that the hand-wrist bone radiograph was the most widely used method with the smallest error, followed by feet, knees, elbows, shoulders, and hips ⁽¹⁵⁾. Most people are right-handed and it is more likely to be injured, thus, the left hand has been used in BAA since the 1990s ⁽¹¹⁾. As for the bone age atlases, the TW method depends on scoring the stage of bony development of bones in the hand-wrist position by comparison with a series of scored standards, thus producing a total score from which a skeletal age may be read directly from tables, while GP method utilizes normal radiographs atlases to assess the skeletal age ⁽¹⁶⁾. Recently, in addition to X-ray examination, other methods including ultrasonic technique has also been used for BAA. While the ultrasound method has no advantage in the readability of examination results due to the severe sound attenuation in the bone cortex compared to the X-ray examination, ultrasound experts still devoted to the studies of ultrasonic techniques in bone age evaluation because of the safe, inexpensive, and non-invasive properties of ultrasound. In this regard, Zadik *et al.* invented a novel ultrasound device, named BonAge ⁽¹⁷⁾. This system evaluates the relationship between the velocity of sound passing through the distal radial and ulna epiphysis and growth stage. Mentzel *et al.* suggested that the BonAge system is an easily performed technique for the accurate estimation of skeletal age ⁽¹⁸⁾. Moreover, one-year study of 269 children by Halaba *et al.* showed that, by measuring the relative parameters of ultrasonic propagation in the phalangeal bone, the method of quantitative measurement of sound velocity could provide dynamic changes of bone development, and the results of this ultrasonic measurement were reliable ⁽¹⁹⁾.

In the current study, X-ray radiograph was used as the gold standard for the evaluation whether AVS could equally display every hand-wrist bone required for bone age assessment. We found that images of left

hand and wrist obtained by AVS method were highly qualitative and identical with that of the standard X-ray radiograph. Furthermore, the display rates of the hand-wrist bones (except for the first metacarpal sesamoid bone and the secondary ossification center of the first metacarpal bone) in the AVS method were not significantly different from that in the standard X-ray method, and the variance of the reading outcomes by the two sonographers was very small. These findings suggested that the AVS method was comparable with X-ray radiograph, and it is a reliable method for BAA in children.

The biggest advantage of the AVS method is that the entire hand-wrist could be presented in the reconstructed image, which was derived from the video that contained more information than an X-ray plain image. However, how to obtain stronger evidence for clinical evaluation of bone age by fully using the information will be a big challenge in the future. In this regard, Bilgili and his colleagues created a standard table for ultrasonic BAA in comparison to GP atlas ⁽¹²⁾, which could be used in bone age assessment of children aged 0-6 years. Combined application of the aforementioned standard table of ultrasonic BAA and AVS method reported in the current study could be more reliably assessing bone age in children and adolescents.

Despite the technical innovation, our study still contained limitations. Firstly, this research was a preliminary and exploratory study of AVS with relatively small sample size. Studies on large samples of different races, different regions, and different age groups are needed for establishing the expected ultrasonic GP atlas. Secondly, interobserver reliability analysis of AVS method was performed only in two observers. Results from more observers with different seniority and majors (ultrasound physicians, endocrinologists, or pediatricians) are needed in the future study. Finally, this method requires the subject to be quiet during the examination, a slight shift of body may render the reconstructed image inaccurate. Especially, this is difficult for a younger child to keep still for 60s or 90s, and repeated tests can wear out the child's patience.

CONCLUSION

The current study demonstrated that AVS, a novel ultrasonic technique for bone age assessment, has an acceptable sensitivity and specificity by showing high concordance rate of AVS images with the X-ray radiograph. Although the AVS method cannot yet replace the X-ray examination, it provides an alternative choice for bone age assessment with higher safety, accuracy, and feasibility.

ACKNOWLEDGEMENT

None.

Conflict of interests: All the authors declare that they have no conflict of interest.

Ethics statement: All procedures performed in studies were in accordance with the ethical standards of the institutional and/or national research committee and with the 1964 Helsinki declaration and its later amendments or comparable ethical standards. This study protocol was approved by the ethics committee of Shanghai Children's Medical Center (No. SCMCIRB- K2020008-1). Informed consent was obtained from the parents of each child.

Funding: This study was funded by the Clinical Research Project of Shanghai Municipal Health Commission (201940267), the Shanghai Science and Technology Committee (19411965400), Natural Science Foundation of Shanghai (19ZR1432700) and the Shanghai Health and Family Planning Commission (201740095). The sponsor did not make any substantive contributions to this article.

Author contributions: JS participated in designing of the study, performing AVS ultrasound scanning, and drafting the manuscript. YC and LFY collected the data and performed the statistical analysis. ZLN participated in acquisition, analysis, and interpretation of data. JD and QW designed the study and revised the manuscript. QW performed X-ray examination. All authors read and approved the final manuscript.

Availability of data and material: The datasets used and/or analyzed during the current study are available from the corresponding author on reasonable request.

REFERENCES

- Greulich WW and Pyle SI (1959) Radiographic Atlas of Skeletal Development of the Hand and Wrist. Stanford, CA: Stanford University Press.
- Tanner JM and Whitehouse RH (1975) A note on the bone age at which patients with true isolated growth hormone deficiency enter puberty. *J Clin Endocrinol Metab*, **41**: 788-90.
- Tanner JM, Whitehouse RH, Marshal WA, Healy MJ, Goldstein H (1975) Assessment of Skeletal Maturity and Prediction of Adult's Height (TW2 Method). London: London Academic Press.
- Tanner JM, Healy MJR, Goldstein H, Cameron N (2001) Assessment of skeletal maturity and prediction of adult height (TW3 method). 3rd ed. London: WB Saunders; 2001.
- Mettler FA Jr, Huda W, Yoshizumi TT, Mahesh M (2008) Effective doses in radiology and diagnostic nuclear medicine: a catalog. *Radiology*, **248**: 254-63.
- Kaufman FR and Sy JP (1999) Regular monitoring of bone age is useful in children treated with growth hormone. *Pediatrics*, **104**: 1039-42.
- Fahmy JL, Kaminsky CK, Kaufman F, Nelson MD Jr, Parisi MT (2000) The radiological approach to precocious puberty. *Br J Radiol*, **73**: 560-7.
- Heppe DH, Taal HR, Ernst GD, Van Den Akker EL, Lequin MM, Hokken-Koelega AC, et al. (2012) Bone age assessment by dual-energy X-ray absorptiometry in children: an alternative for X-ray? *Br J Radiol*, **85**: 114-20.
- De González BA and Darby S (2004) Risk of cancer from diagnostic X-rays: estimates for the UK and 14 other countries. *Lancet*, **363**: 345-51.
- Hall EJ and Brenner DJ (2008) Cancer risks from diagnostic radiology. *Br J Radiol*, **81**: 362-78.
- Hall EJ (2009) Radiation biology for pediatric radiologists. *Pediatr Radiol*, **39**(1): S57-64.
- Bilgili Y, Hizel S, Kara SA, Sanli C, Erdal HH, Altinok D (2003) Accuracy of skeletal age assessment in children from birth to 6 years of age with the ultrasonographic version of the Greulich-Pyle atlas. *J Ultrasound Med*, **22**: 683-90.
- Castriota-Scanderbeg A, Sacco MC, Emberti-Gialloreti L, Fraracci L (1998) Skeletal age assessment in children and young adults: comparison between a newly developed sonographic method and conventional methods. *Skeletal Radiol*, **27**: 271-7.
- Daneff M, Casalis C, Bruno CH, Bruno DA (2015) Bone age assessment with conventional ultrasonography in healthy infants from 1 to 24 months of age. *Pediatr Radiol*, **45**: 1007-15.
- Martin DD, Wit JM, Hochberg Z, Säwendahl L, van Rijn RR, Fricke O, et al. (2011) The use of bone age in clinical practice - part 1. *Horm Res Paediatr*, **76**: 1-9.
- Ostojic SM (2013) Prediction of adult height by Tanner-Whitehouse method in young Caucasian male athletes. *QJM*, **106**: 341-5.
- Schmeling A, Reisinger W, Geserick G, Olze A (2006) Age estimation of unaccompanied minors. Part I. General considerations. *Forensic Sci Int*, **159**(1): S61-4.
- Schmidt S, Koch B, Schulz R, Reisinger W, Schmeling A (2008) Studies in use of the Greulich-Pyle skeletal age method to assess criminal liability. *Leg Med (Tokyo)*, **10**: 190-5.
- Malina RM (2011) Skeletal age and age verification in youth sport. *Sports Med*, **41**: 925-47.