

## Pulmonary perfusion scintigraphy in diagnosis and management of fibrosing mediastinitis

R. Wang<sup>1</sup>, Z. LI<sup>2</sup>, Y. Wang<sup>1</sup>, H. Wang<sup>1\*</sup>

<sup>1</sup>Department of Nuclear Medicine, Gansu Provincial Hospital, Lanzhou 730000, China

<sup>2</sup>First Clinical Medical College of Gansu University of Chinese Medicine, Lanzhou 730000, China

### ► Case report

#### \*Corresponding author:

Haijun Wang, Ph.D.,

E-mail: whj1425@126.com

Received: November 2021

Final revised: April 2022

Accepted: June 2022

Int. J. Radiat. Res., October 2022;  
20(4): 893-896

DOI: 10.52547/ijrr.20.4.25

**Keywords:** pulmonary perfusion scintigraphy, fibrosing mediastinitis, pulmonary artery stenosis, pulmonary vein stenosis, interventional therapy, SPECT/CT.

### ABSTRACT

Pulmonary ventilation/perfusion (V/Q) scintigraphy is often used for the diagnosis of pulmonary embolism. However, it should be noted that the perfusion defect shown by pulmonary perfusion imaging is not the only manifestation of pulmonary embolism. Any disease that causes pulmonary vasculature stenosis and occlusion can cause pulmonary blood flow perfusion impaired. We report a case of fibrosing mediastinitis (FM) with pulmonary hypertension as a complication of pulmonary artery and pulmonary vein stenosis. Based on clinical symptoms, laboratory test and multiple radiographic findings, the diagnosis of FM was established. The patient underwent balloon dilation and stent implantation of right upper lobe pulmonary vein, as well as balloon dilatation of right upper lobe pulmonary artery, whose symptoms was immediately improved during the following investigation.

### INTRODUCTION

FM is a rare disease characterized by mediastinal fiber hyperplasia. The onset is insidious, the course is prolonged, and clinicians are not sufficiently alert to FM. Diagnosis of FM is challenging due to the gradual onset of nonspecific symptoms, and most cases are not diagnosed in time. FM should be considered in the differential diagnosis of chest symptoms. There is a report about a case of a 64-year-old woman who presented with only chest tightness and shortness of breath over a 5-year period, with delayed diagnosis. She did not get timely diagnosis and treatment until hemoptysis. The patient underwent a thorough examination and interventional therapy with balloon dilation and stent implantation.

Comprehensive imaging is of great significance in assessing the severity of disease and guiding clinical decision-making. We should emphasize the importance of computed tomography pulmonary angiography (CTPA), along with pulmonary perfusion imaging as a useful adjunct imaging technique.

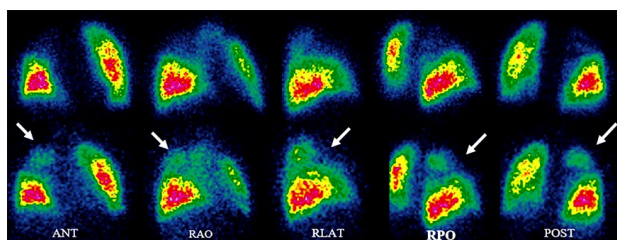
We aim to present a case in which <sup>99m</sup>Tc-MAA single-photon emission computed tomography/computed tomography (SPECT/CT) pulmonary perfusion scintigraphy was used to guide treatment and follow-up. The use of SPECT/CT in patients with FM with such complete clinical data and imaging studies has rarely been reported. This case highlights

the added value of SPECT/CT pulmonary perfusion imaging in screening, guiding targeted invasive therapies, and evaluating efficacy.

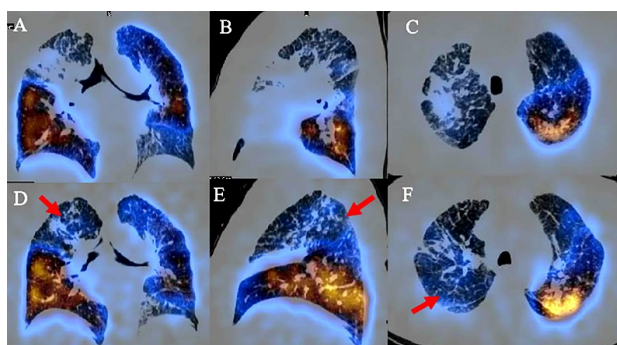
### Case report

A 64-year-old woman presented to our hospital with complaints of chest tightness and shortness of breath for 5 years, and intermittent hemoptysis for 20 hours. She had a history of tuberculosis. Laboratory examination results were as follows: SO<sub>2</sub>:88.2 (>95%), PO<sub>2</sub>:56.4 (83-108 mmHg), PCO<sub>2</sub>: 37.5 (35-45 mmHg), NT-proBNP: 687 (<125 pg/ml), D-dimer: 0.49 (<5.00 ug/ml), WBC: 15.0 (3.5~9.5×10<sup>9</sup>/L), NEUT: 89.1 (50.0-75.0%), RBC: 5.33 (3.50~5.00×10<sup>12</sup>/L), HGB: 163.0 (110.0-150.0g/L). Tuberculosis-specific cellular immunoassay is positive. All autoantibody tests are negative. Emergency CT (GE, LightSpeed VCT) examination: right upper and middle lobe stenosis, bronchopneumonia, atelectasis, multiple enlarged lymph nodes in the mediastinum and right hilum, hard swelling in the upper apex of the right lung, and widened pulmonary trunk. The patient was treated with anti-inflammatory and hemostatic drugs. Echocardiography estimates of pulmonary artery systolic pressure (PASP) was 105mmHg. Bronchoscope: extensive hemorrhage in the bronchi of both lungs, occlusion of the anterior branch of the right upper lobe, and carbon foam pigmentation.

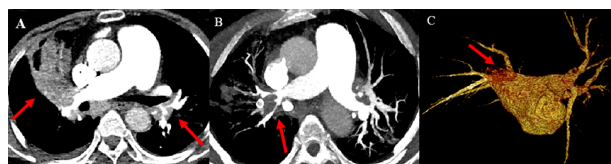
Planar imaging of pulmonary perfusion with  $^{99m}\text{Tc}$ -MAA revealed a radioactive defect in the right upper lobe (figure 1).  $^{99m}\text{Tc}$ -MAA SPECT/CT (GE, Discovery 670, Xeleris) tomographic fusion imaging clearly showed perfusion defects in the right upper lobe, and some subsegmental in left anterior segment, basal segment (figure 2). CTPA (Siemens, Definition flash CT, Siemens Syngo via) was used to identify the cause of impaired lung perfusion and showed significant bilateral pulmonary artery ostium stenosis, surrounding soft tissue density lesions with calcifications, and right upper pulmonary vein occlusion (figure 3).  $^{18}\text{F}$ -FDG positron emission tomography and computed Tomography (PET/CT, GE, Discovery STE, Xeleris) revealed multiple enlargement of mediastinum and bilateral hilum, tending to calcification and calcified lymph nodes, and increased FDG uptake, considering the inflammatory response (figure 4). Right heart catheterization (RHC) was performed to confirm a mean pulmonary arterial pressure (mPAP) was 32 mmHg at rest. Results of invasive pulmonary angiography showed no pulmonary blood flow to the right upper lobe (figure 5). The diagnosis of Fibrosing mediastinitis (FM) was established based on clinical symptoms, laboratory and imaging findings. The patient underwent right upper lobe pulmonary vein balloon dilation and stenting, and right upper lobe pulmonary artery balloon dilatation (figure 5). Symptoms were improved immediately.



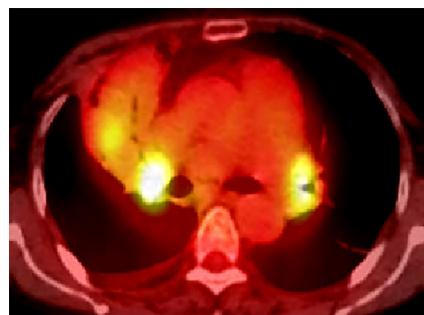
**Figure 1.**  $^{99m}\text{Tc}$ -MAA pulmonary perfusion planar imaging before (up) and after (down) interventional therapy.



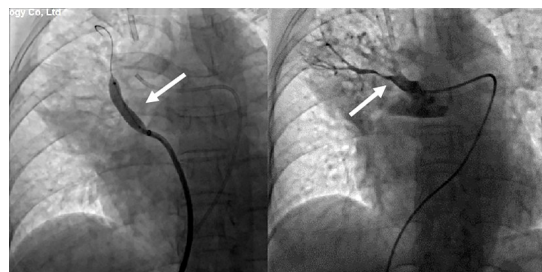
**Figure 2.**  $^{99m}\text{Tc}$ -MAA pulmonary perfusion SPECT/CT fusion imaging before (panel A-C) and after (panel D-F) interventional therapy. Fusion imaging provides a clearer view of the location and extent of the defect and improved perfusion pattern in the right upper lobe.



**Figure 3.** The computed tomography pulmonary angiography (CTPA) showed significant bilateral pulmonary artery ostium stenosis, surrounding soft tissue density lesions with calcifications (panel A-B), and right upper pulmonary vein occlusion (panel C).

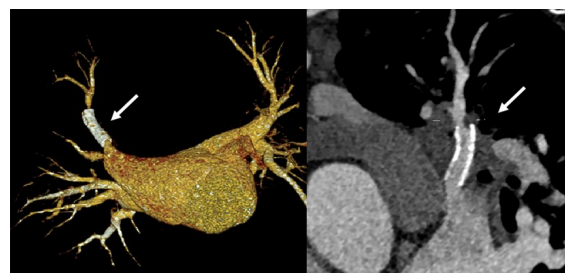


**Figure 4.**  $^{18}\text{F}$ -FDG PET/CT revealed multiple enlargement of mediastinum and bilateral hilum, tending to calcification and calcified lymph nodes, and increased FDG uptake.



**Figure 5.** Invasive pulmonary angiography showed no pulmonary blood flow to the right upper lobe. The patient underwent right upper lobe pulmonary vein balloon dilation and stenting, and right upper lobe pulmonary artery balloon dilatation.

Three months later, she was re-admitted to the hospital for review. NT-proBNP: 232pg/ml, and PASP estimated by echocardiography was 81mmHg. Pulmonary perfusion imaging showed improved perfusion pattern in the right upper lobe (figures 1, 2). Repeat CTPA showed that the right upper pulmonary vein stent was unobstructed, and low-density shadows were seen at the distal end of the stent (figure 6).



**Figure 6.** Repeat CTPA showed that the right upper pulmonary vein stent was unobstructed, and low-density shadows were seen at the distal end of the stent.

## DISCUSSION

FM is a rare disorder in which mediastinal adipose tissue is gradually replaced by infiltrative fibrous tissue. The fibrous tissue gradually proliferates and spreads to infiltrate the mediastinum, possibly encapsulating and compressing important mediastinal structures such as the pulmonary artery, pulmonary veins, trachea and esophagus <sup>(1-2)</sup>. FM is often associated with histoplasmosis and tuberculosis, and other causes include sarcoidosis, mycosis, mediastinal radiotherapy and autoimmune diseases <sup>(3-6)</sup>. In our case, we diagnosed the underlying pathogenetic etiologies as tuberculosis, because the patient had history of pulmonary tuberculosis, a positive tuberculosis-specific cellular immunoassay, and bronchoscope with carbon foam pigmentation.

Diagnosis of FM is challenging due to the gradual onset of nonspecific symptoms, and most cases are not diagnosed in time. The manifestations depends on the degree and scope of the structures involved. Common symptoms are cough, hemoptysis, shortness of breath, and chest pain <sup>(7,8)</sup>. Our patient presented only chest tightness and shortness of breath for 5 years, delaying the diagnosis. Until hemoptysis is diagnosed and treated in time. Hemoptysis can result from bronchial arterial hypertrophy due to pulmonary vein obstruction or pulmonary artery compression <sup>(9-10)</sup>. Pulmonary hypertension (PH) is a serious complication of FM caused by extrinsic compression of the pulmonary vessels. The patient had a longer disease course and had PH at the postobstructive consultation. Pneumonia or atelectasis caused by airway compression. Pulmonary veins obstruction manifests as pleural effusion <sup>(4)</sup>.

Currently, the diagnosis of FM is mainly based on CT imaging findings. Typical clinical and imaging findings are sufficient to confirm the diagnosis, whereas tissue biopsy is usually not necessary for the diagnosis of FM <sup>(1,9-11)</sup>. The presence and severity of FM can be noninvasively assessed with multimodal imaging, including echocardiography, CT, radionuclide perfusion imaging, or magnetic resonance imaging. CTPA plays an important role in the evaluation of patients with suspected FM <sup>(12)</sup>. CT angiography remains the imaging modality of choice due to its high diagnostic power <sup>(1)</sup>. This not only allows assessment of vascular structures, collateral vessel formation, but also best demonstrates calcification, lesions that exhibit soft tissue density, and pulmonary and mediastinal lesions. At the same time, it can accurately characterize the location of the lesion, its relationship with the hilum and mediastinum, and the degree of fibrosis <sup>(5)</sup>. Lesions are usually located in the right paratracheal, subcarinal area, or hilum <sup>(3, 8, 13)</sup>.

Pulmonary ventilation/perfusion (V/Q) scintigraphy is commonly used in the diagnosis of pulmonary embolism <sup>(14-15)</sup>. However, it should be

noted that the perfusion defects shown by pulmonary perfusion imaging are not the only manifestations of pulmonary embolism <sup>(16-17)</sup>. Any disease that causes pulmonary vasculature stenosis and occlusion can lead to impaired pulmonary blood perfusion, including pulmonary artery stenosis or malformation, chronic thromboembolic pulmonary hypertension, arteritis, tumors, etc. Although pulmonary perfusion imaging cannot directly diagnose FM, pulmonary perfusion imaging is a functional imaging, and pulmonary perfusion imaging can directly display the blood flow distribution and damage in both lungs. It is a sensitive method to aid in the diagnosis of pulmonary vascular stenosis and occlusive disease. It has the characteristics of high safety and simple operation. It is mainly used to evaluate the site, scope, extent and efficacy of impaired pulmonary perfusion. SPECT/CT improves accuracy and specificity. The added value of SPECT/ CT provides more anatomical information to better characterize not only the shape, size, and location of defects, but also the pulmonary and mediastinal lesions such as pneumonia, atelectasis, pleural effusion, mediastinal soft tissue lesions, and bilateral hilum enlarged and/or calcified lymph nodes. When these signs are present, extrinsic compression of the pulmonary vessels should be highly considered <sup>(18)</sup>. Further diagnosis should be aided by clinical features, CTPA or pulmonary angiography. PET scans has developed into a widely available and valuable diagnostic tool. It is usually used to rule out malignancies.

Currently, there is no cure for FM <sup>(19-20)</sup>. The purpose of the intervention is to relieve the obstruction and to alleviate the patient's clinical symptoms <sup>(21)</sup>. However, the interventional radiologists believe that endovascular stent placement at stenotic lesions may lead to stenosis recurrence, which is the most common complication <sup>(10, 22)</sup>. Vascular remodeling is considered a cause of restenosis <sup>(13)</sup>. In our patient, the symptoms improved immediately after the balloon dilation and stenting. Repeat pulmonary perfusion imaging 3- months later showed improved perfusion pattern in right upper lobe. However, low-density shadows were seen at the distal end of the stent after 3 months. Interventional radiologists considered recurrent stenosis. The patient underwent balloon dilation again.

## CONCLUSION

Clinicians are not sufficiently alert to FM. FM should be considered in the differential diagnosis of chest symptoms. Comprehensive imaging is important for assessing disease severity of and guiding clinical decision-making. The importance of CTPA examination should be emphasized, and pulmonary perfusion imaging is a useful auxiliary imaging technique, which is of great value in



screening, guiding targeted invasive therapy, and evaluating efficacy.

## ACKNOWLEDGMENT

None.

**Conflict of interest:** Declared none.

**Statement of Ethics:** The ethics committee of Gansu Provincial Hospital approved this study. Informed consent of the patient was obtained.

**Funding:** This article is supported by the Gansu Natural Science Found (No. 21JR1RA025) and the Science Foundation of Gansu Provincial Hospital (No. 20GSSY4-17).

**Author contribution:** Conception and writing, Data analysis and interpretation: (Rong Wang), (Haijun Wang); Materials and data preparation: (Zhoule LI), (Yongle Wang).

## REFERENCES

- Garrana SH, Buckley JR, Rosado ML, Martínez S, Muñoz P, Borsa J (2019) Multimodality Imaging of Focal and Diffuse Fibrosing Mediastinitis. *Radiographics*, **39**(3): 651-667.
- Duan YC, Su HL, Wei R, Jiang KY, Wang AQ, Yang YY, et al. (2022) Short-term efficacy and perioperative safety of catheter-based intervention for pulmonary vein stenosis caused by fibrosing mediastinitis. *Chin J Cardiol*, **50**(1): 55-61.
- Gao W, Zhang X, Fu Z, Hu W, Zhang X, Dai G (2019) Tuberculosis mediastinal fibrosis misdiagnosed as chronic bronchitis for 10 years: a case report. *Quant Imaging Med Surg*, **9**(6): 1179-1183.
- Seferian A, Steriade A, Jaïs X, Planché O, Savale L, Parent F (2015) Pulmonary Hypertension Complicating Fibrosing Mediastinitis. *Medicine (Baltimore)*, **94**(44): e1800.
- Wu Z, Jarvis H, Howard LS, Wright C, Kon OM (2017) Post-tuberculous fibrosing mediastinitis: a review of the literature. *BMJ Open Respir Res*, **4**(1): e000174.
- Xu Y, Xu W, Liu Y, Tian X, Xu K, Shi J, et al. (2018) Pulmonary hypertension associated with combined fibrosing mediastinitis and bronchial anthracofibrosis: A retrospective analysis in a single Chinese hospital. *Clin Respir J*, **12**(3): 1134-1140.
- Yang SQ, Wang JF, Li JF, Huang KW, Yang YH (2021) Refractory pleural effusion as a rare complication of pulmonary vascular stenosis induced by fibrosing mediastinitis: a case report and literature review. *J Int Med Res*, **49**(5): 3000605211010073.
- Garin A, Chassagnon G, Tual A, Revel MP (2021) CT features of fibrosing mediastinitis. *Diagn Interv Imaging*, **102**(12): 759-762.
- Fender EA, Widmer RJ, Knavel KEM, Welby JP, Kern R, Peikert T, et al. (2019) Catheter based treatments for fibrosing mediastinitis. *Catheter Cardiovasc Interv*, **94**(6): 878-885.
- Li Y, Meng X, Wang Y, Yang Y, Lu X (2018) Fibrosing mediastinitis with pulmonary hypertension as a complication of pulmonary vein stenosis: A case report and review of the literature. *Medicine (Baltimore)*, **97**(4): e9694.
- Eshak N, Abdelnaby M, Shehata H, Zizda K (2019) A case of fibrosing mediastinitis complicated by pulmonary hypertension and right-sided heart failure. *Eur Heart J*, **40**(9): 742.
- Garrana SH, Buckley JR, Rosado-de-Christenson ML, Martínez-Jiménez S, Muñoz P, Borsa JJ (2019) Multimodality Imaging of Focal and Diffuse Fibrosing Mediastinitis. *Radiographics*, **39**(3): 651-667.
- Panagopoulos N, Leivaditis V, Kraniotis P, Ravazoula P, Koletsis E, Dougenis D (2019) Sclerosing Mediastinitis Causing Unilateral Pulmonary Edema Due to Left Atrial and Pulmonary Venous Compression. A Case Report and Literature Review. *Braz J Cardiovasc Surg*, **34**(1): 85-92.
- Ma RZ, Han PP, Tao XC, Li H, Wang L, Zhai ZG, et al. (2021) A Feasibility Study on Using Single-Photon Emission Computed Tomography Pulmonary Perfusion/Ventilation Imaging for the Diagnosis of Chronic Thromboembolic Pulmonary Hypertension and Patient Risk Assessment. *Int J Gen Med*, **14**: 8029-8038.
- Bourhis D, Wagner L, Rioult J, Robin P, Pennec RL, Trommur C, et al. (2021) Automatic delineation and quantification of pulmonary vascular obstruction index in patients with pulmonary embolism using Perfusion SPECT-CT: a simulation study. *EJNMMI Phys*, **8**(1): 49.
- Goldbach AR, Pascarella S, Dadpravarar S (2018) Fibrosing Mediastinitis: a Rare Cause of Unilateral Absent Lung Perfusion on a V/Q Scan. *Nucl Med Mol Imaging*, **52**(5): 401-404.
- Sinha D, Kundaragi NG, Kale SK, Sharma S (2020) Fibrosing mediastinitis mimicking as chronic pulmonary thromboembolism. *BJR Case Rep*, **6**(1): 20190049.
- Cao YS, Duan YC, Su HL (2020) Advances in diagnosis and therapy of pulmonary vascular stenosis induced by fibrosing mediastinitis. *Chin J Cardiol*, **48**(10): 823-830.
- Zong DD and Ouyang RY (2021) Pulmonary hypertension complicating mediastinal fibrosis secondary to tuberculosis: A case report and literature review. *Zhong Nan Da Xue Xue Bao Yi Xue Ban*, **46**(7): 774-779.
- Welby JP, Fender EA, Peikert T, Holmes DR, Bjarnason H, Knavel-Koepsel EM (2021) Evaluation of Outcomes Following Pulmonary Artery Stenting in Fibrosing Mediastinitis. *Cardiovasc Intervent Radiol*, **44**(3): 384-391.
- Seckeler MD, Pineda JR, Lotun K (2021) Successful Transcatheter Recanalization of a Chronically Occluded Left Pulmonary Artery Due to Fibrosing Mediastinitis. *JACC Cardiovasc Interv*, **14**(16): e215-e216.
- Duan YC, Zhou X, Su HL, Jiang KY, Wu WY, Pan C, et al. (2021) Balloon angioplasty or stent implantation for pulmonary vein stenosis caused by fibrosing mediastinitis: a systematic review. *Cardiovasc Diagn Ther*, **9**(5): 520-528.