

# Analysis of the effect of centrifugal massage on reducing the incidence of compartment syndrome caused by contrast agent extravasation and reducing tension in patients undergoing enhanced CT examination

F. Wang<sup>1</sup>, W. Liu<sup>2</sup>, S. Zhao<sup>3</sup>, W. Ye<sup>3\*</sup>

<sup>1</sup>Department of the Outpatient, Suzhou Kowloon Hospital, Shanghai Jiaotong University School of Medicine, Suzhou, Jiangsu 215000, China

<sup>2</sup>Department of Emergency, Suzhou Kowloon Hospital, Shanghai Jiaotong University School of Medicine, Suzhou, Jiangsu 215000, China

<sup>3</sup>Department of Medical Imaging, Suzhou Kowloon Hospital, Shanghai Jiaotong University School of Medicine, Suzhou, Jiangsu 215000, China

## ABSTRACT

### ► Original article

#### \*Corresponding author:

Weijie Ye, MD,

E-mail: yeweijie0902@163.com

Received: December 2022

Final revised: February 2023

Accepted: April 2023

Int. J. Radiat. Res., April 2023;  
21(2): 319-324

DOI: 10.52547/ijrr.21.2.20

**Keywords:** Compartment syndrome, massage, computed tomography angiography, contrast agent.

**Background:** The Background: To explore the influence of centrifugal massage on reducing the incidence of compartment syndrome after contrast extravasation (CM) and reducing the tension. **Materials and Methods:** A total of 62 patients with iodine contrast agent extravasation who underwent CT angiography in our hospital from March 2020 to March 2022 were chosen and separated into observation group (OG, n=31) and control group (CG, n=31) following the nursing plan. Patients in the CG adopted external application of drugs, and patients in the OG received centrifugal massage. The occurrence and duration of swelling, the incidence of compartment syndrome after contrast extravasation, nursing satisfaction, patients' symptoms, and psychological status were compared between both groups. **Results:** The swelling degree and duration and incidence of compartment syndrome after contrast extravasation in the OG were declined relative to the CG ( $P<0.05$ ). After 24 and 48 hours of intervention, patients in the OG had elevated self-rating scales compared to the CG ( $P<0.05$ ). The nursing satisfaction of patients in the OG was elevated compared to the CG ( $P<0.05$ ). After intervention, the anxiety and depression scores of the OG was decreased compared to the CG ( $P<0.05$ ). The effective rate of treatment in the OG was elevated compared to the CG ( $P>0.05$ ). **Conclusion:** Centrifugal massage for patients with CT enhanced scanning can prevent the incidence of CM after contrast extravasation, reduce the damage of contrast agent to tissues, and improve nursing satisfaction.

## INTRODUCTION

Computed tomography (CT) angiography is very commonly used in clinical diagnosis, mainly through the difference of contrast agent density to diagnose the patient's lesions, which can significantly improve the accuracy of clinical diagnosis, help doctors to grasp the patient's condition in time, and provide reliable basis for the follow-up treatment arrangement of patients. It is irreplaceable in clinical work <sup>(1, 2)</sup>. However, CT examination needs to inject contrast agent into the patient under high pressure. When the doctor operates improperly or the patient's own body is abnormal, it will lead to a high rate of contrast agent extravasation, causing pain and swelling in local parts of the patient's body. If it is not handled in time, it will even lead to serious limb dysfunction or tissue necrosis. Moreover, allergic reactions of the patient are also very common, which

has a certain risk. It is necessary to explore new intervention methods to reduce the incidence of adverse reactions such as contrast agent extravasation <sup>(3-5)</sup>.

Compartment syndrome (CM) belongs to a rare but severe complication caused by contrast medium extravasation. It is considered to be an elevation in pressure within a closed compartment that leads to a compromise of the microcirculation of the tissue within <sup>(6)</sup>. If not discovered and treated in time, the soft tissue in the compartment can be perpetually injured <sup>(7)</sup>.

Centrifugal massage is a kind of nursing mode for contrast media penetration, which is rising in recent years <sup>(8)</sup>. It is widely used in clinical nursing work based on scientific theory and achieves the most ideal results with optimized means and methods. Centrifugal massage is a nursing mode guided by the overall nursing concept, based on evidence-based

nursing and patient-oriented. It can pay more attention to the details of treatment in the process of treatment, improve the quality and refinement of conventional treatment, and provide comprehensive and professional nursing services for patients <sup>(9)</sup>. As an important part of modern nursing services, centrifugal massage can improve the meticulous degree of intervention and treatment operations, optimize various intervention and treatment services, fine manage resources, improve patients' trust, establish a good nurse patient relationship, improve patients' cooperation in follow-up examination, treatment, and nursing, as well as improve patients' medical experience <sup>(10)</sup>. For patients undergoing enhanced CT examination, centrifugal massage can avoid possible contrast agent extravasation and allergic reactions, reducing the incidence of adverse reactions and improving the safety of CT examination <sup>(11)</sup>. However, there is rare report on the application of centrifugal massage on reducing the incidence of compartment syndrome after contrast extravasation.

Therefore, the purpose of this study was to probe the influence of centrifugal massage on reducing the incidence of compartment syndrome after contrast extravasation and reducing the tension, which might provide a novel sight for prevention of the occurrence of compartment syndrome.

## MATERIALS AND METHODS

### General clinical data

A total of 62 patients with iodine contrast agent (Iopromide injection, 60 mL, Bayer Schering Pharma AG, Germany) extravasation who underwent CT angiography (American GE256-slice spiral CT scanner) in our hospital from March 2020 to March 2022 were included in the study. According to the nursing plan, they were separated into observation group (OG, n=31) and control group (CG, n=31). Selection criteria: (1) Patients with iodine contrast agent extravasation and informed consent to this study; (2) The patient's clinical data was complete; (3) The patient had no contraindications to CT angiography (iodine allergy, pregnancy, etc.). Exclusion criteria: (1) Patients with severe heart valve disease; (2) The patient had related symptoms at the time of treatment; (3) Patients had poor tolerance to CT angiography. The CG contained 16 males and 15 females, with a mean age of (56.79±11.28) years, ranging from 35 to 75 years; Degree of extravasation: mild in 21 cases and moderate in 10 cases. The OG contained 17 males and 14 females, with a mean age of (56.86±11.34) years, ranging from 35 to 77 years; Degree of extravasation: mild in 22 cases and moderate in 9 cases. The difference of clinical data between both groups was balanced ( $P>0.05$ , table 1) and comparable. This study was carried out with the approval of the ethics

committee of Suzhou Kowloon Hospital (KY-2021-006, March, 2020-March, 2022).

CG: External application of medicine was adopted to deal with the symptom of iodine contrast agent extravasation: six layers of medical gauze were completely immersed in 50% magnesium sulfate solution (Hebei Xingtai Metallurgical Magnesium Industry Co. LTD, China), taken out and screwed to half dry (no dripping is appropriate) and applied to the swelling position of the patient, and the outer layer was covered with a film. The magnesium sulfate gauze was replaced every 2 ~ 3 hours, and the swollen limbs was lifted. After 24 hours, the gauze block was removed, and the drug solution at the swollen part was penetrated into the surrounding subcutaneous tissue. The skin tension of the swollen limb was decreased, softened, but the area increased. It disappeared after 48 hours of observation.

OG: Centrifugal massage was used for intervention: after the iodine contrast agent was found to be extravagated, the patient was instructed to lie flat or sit down, the injured limb was put on the bed surface or table top, the eye of the needle was disinfected, and then a sterile small patch was applied. After swelling, anti-swelling gel was applied to reduce swelling and lubricate the skin. The nurse held the patient's affected limb with her left hand, held the proximal end of the swollen part of the affected limb with her right hand, and forcefully pushed the swelling liquid toward the proximal end. During the massage, it could be observed that the subcutaneous contrast liquid of the patient was pushed, the skin showed wrinkle marks, the patient felt pain, the epidermis turned red during the massage, and the original color could be restored after the massage. The massage time should be able to spread the subcutaneous effusion. The massage time should be determined according to the amount of contrast agent extravasation, and it could be 1 to 3 minutes. The number of massages should be determined according to the extent of contrast agent dispersion.

**Table 1.** Clinical characteristics of patients in both groups.

Characteristic	Control group (31 cases)	Observation group (31 cases)	t/ $\chi^2$ value	P value
Gender (male/female)	16/15	17/14	0.06	> 0.05
Average age (years)	56.79±11.28	56.86±11.34	0.02	> 0.05
Degree of extravasation	Mild	21	0.08	> 0.05
	Moderate	10		

Occurrence and duration of swelling: the number of cases of swelling caused by extravasation of contrast medium in the two groups was counted, and the duration of swelling was recorded. The swelling was graded according to the swelling situation. Mild: local swelling range <2.5 cm; Moderate: local swelling range: 2.5 ~ 14.0 cm; Severe: local swelling range

>14.0 cm.

Occurrence of the incidence of compartment syndrome after contrast extravasation: the number of cases of contrast agent extravasation in the two groups was counted and graded according to the degree of extravasation. 0 degree: no clinical symptoms; Grade I: the skin was pale and cold, with or without pain, and the maximum diameter of edema was less than 2.5 cm; Grade II: including all symptoms of grade I, the maximum diameter of edema was 2.5 ~ 15.0 cm; Grade III: including all the symptoms of grade II, with edema skin accompanied by mild and moderate pain, and a certain numbness. The maximum diameter of edema was >15 cm; Grade IV: including all symptoms of grade III, accompanied by skin tightness, exudation, discoloration, blood stasis, deep depression edema, impaired limb circulation, and moderate and severe pain.

Nursing satisfaction: the nursing satisfaction scale was prepared according to relevant standards and distributed to patients after nursing. The scale was a 100 point system, in which  $\geq 95$  points were very satisfied, 90-94 points were satisfied, and < 90 points were dissatisfied. Satisfaction (%) = (very satisfied cases + satisfied cases) / total cases  $\times$  100%.

Psychological status: Self-Rating Anxiety Scale (SAS) as well as the Self-Rating Depression Scale (SDS) were implemented to assess the negative emotions of patients. Higher score represented more serious negative emotions.

Evaluation of patients' conscious symptoms: the curative effect was evaluated and graded according to Likert scale: 5 points meant excellent effect and no adverse reaction; 4 points: satisfactory effect and few adverse reactions; 3 points: general effect and little adverse reaction; 2 points: unsatisfactory effect and small adverse reaction; 1: unsatisfactory effect and large adverse reaction.

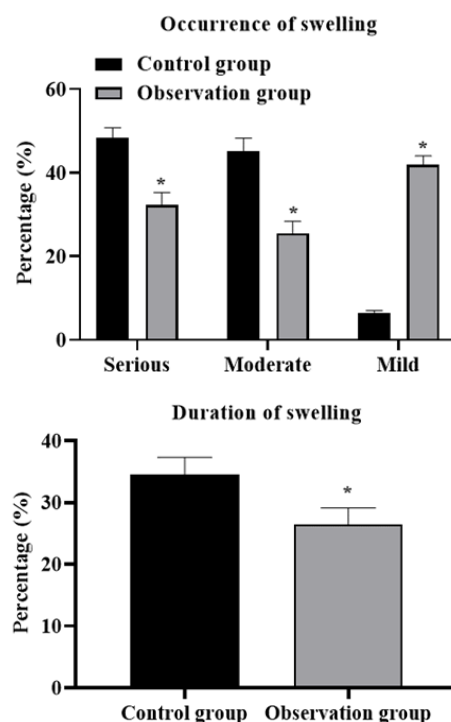
### Statistical analysis

SPSS 22.0 statistical software (International Business Machines Corporation, USA) was implemented, in which normal measurement data were exhibited as mean  $\pm$  standard deviation ( $\bar{x} \pm s$ ), and t-test was performed. Count data were exhibited as percentage (%) and  $\chi^2$  test was performed.  $P < 0.05$  indicated significant.

## RESULTS

### Occurrence and duration of swelling in two groups

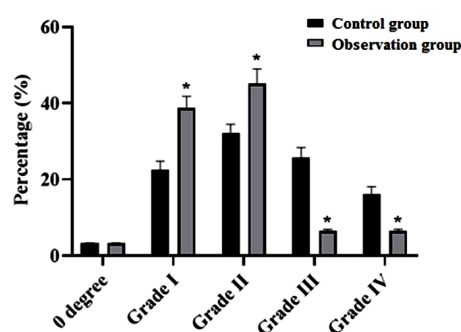
Compared with the CG, the occurrence of serious and moderate swelling in the OG was declined, and the occurrence of mild swelling in the OG was elevated ( $P < 0.05$ ). In addition, the duration of swelling in the OG was also significantly reduced relative to the CG ( $P < 0.05$ , figure 1).



**Figure 1.** Occurrence and duration of swelling in two groups. Note: \*  $P < 0.05$  compared with the control group, and P values were obtained by t test.

### Comparison of the incidence of compartment syndrome after contrast extravasation

Compared to the CG, the number of patients in grade I and grade II contrast agent extravasation was higher in the OG, while the number of patients in grade III and grade IV contrast agent extravasation was lower, which implied that the incidence of compartment syndrome after contrast extravasation in the OG was declined compared to the CG ( $P < 0.05$ , figure 2).

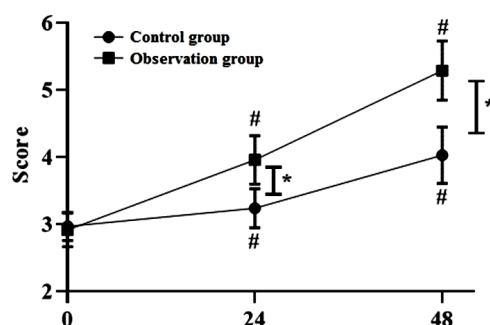


**Figure 2.** Comparison of the incidence of compartment syndrome after contrast extravasation between the two groups. Y axis is showing the number of patients. Note: \*  $P < 0.05$  compared with the control group, and P values were obtained by t test.

### Comparison of self-evaluation results between two groups

After 24 and 48 hours of intervention, patients both groups had elevated self-rating scale scores, and patients in the OG had higher self-rating scale scores

compared to the CG ( $P < 0.05$ , figure 3).



**Figure 3.** Comparison of self-evaluation results between two groups. Note: \*  $P < 0.05$  compared with the control group, #  $P < 0.05$  compared with before intervention, and  $P$  values were obtained by  $t$  test.

### Comparison of nursing satisfaction between two groups

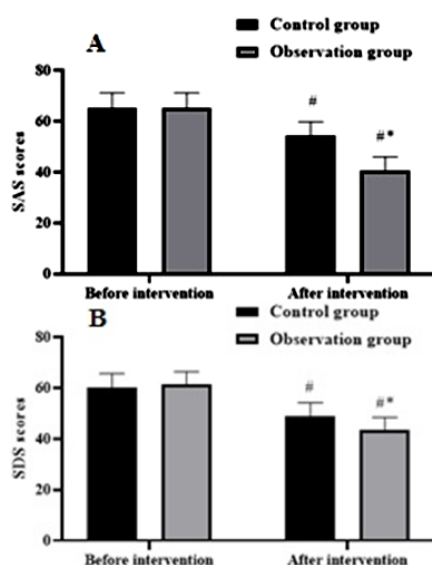
The nursing satisfaction of patients in the OG was 96.77%, which was elevated compared to that of 83.87% in the CG ( $P < 0.05$ , table 2).

**Table 2.** Comparison of nursing satisfaction between two groups (n, %)

Groups	Cases	Very satisfied	Satisfied	Dissatisfied	Satisfied rate (%)
Observation group	31	16 (51.61)	14 (45.16)	1 (3.23)	30 (96.77)*
Control group	31	12 (38.71)	14 (45.16)	5 (16.13)	26 (83.87)

### Anxiety and depression scores of patients in two groups

Previous to intervention, no difference was discovered in SAS and SDS scores between both groups were compared ( $P > 0.05$ ). After intervention, SAS and SDS scores of both groups were lower ( $P < 0.05$ ), and those in the OG were declined compared to the CG ( $P < 0.05$ , figure 4).



**Figure 4.** Comparison of SAS (A) and SDS (B) scores of two groups of patients. Note: \*  $P < 0.05$  compared with the control group, #  $P < 0.05$  compared with before intervention, and  $P$  values were obtained by  $t$  test. SAS: Self-Rating Anxiety Scale. SDS: Self-Rating Depression Scale.

### Intervention effect of patients in both groups

The effective rate of treatment in the OG was 96.77%, which was promoted relative to that of 87.10% in the CG ( $P < 0.05$ ), as displayed in table 3.

**Table 3.** Comparison of intervention effect of patients in both groups.

Groups	Cases	Cure	Improved	Not cured	Effective rate of treatment (%)
Observation group	31	20 (64.51)	10 (32.26)	1 (3.23)	30 (96.77)*
Control group	31	13 (38.71)	14 (45.16)	4 (12.90)	27 (87.10)

Note: \*  $P < 0.05$  compared with the control group, and  $P$  values were obtained by chi-square test.

## DISCUSSION

In CT angiography, if the patient's own blood vessels are poor or the cooperation ability is poor, it is easy to lead to contrast agent extravasation. In addition, the routine use of high-pressure syringes in CT enhancement scanning will enhance the fragility of blood vessels and increase the permeability, which will lead to needle displacement. These factors can all lead to increased risk of contrast agent extravasation (12, 13). Adverse reactions of contrast agent include nausea, vomiting, chills, sweating, dizziness, etc. at this time, doctors need to stop contrast agent injection and deal with it accordingly. Contrast agent extravasation, as a common type of adverse reaction in angiography, increases the pain of patients. Patients can appear local skin redness, swelling, pain, numbness, blisters, etc., severe cases can lead to skin tissue ulceration and necrosis (14). Contrast agent extravasation can lead to vascular damage, proliferation of connective tissue around the blood vessels, thickening and hardening of blood vessels, narrowing of lumen, and redness, pain, numbness, blisters, etc. around the blood vessels, which makes the pain more severe (15, 16). Although most of the contrast agents used in China in recent years are non-ionic contrast agents, which have the characteristics of non-ionic dissociation, high-density hydrophilicity, low chemical toxicity and low permeability, and can reduce the extravasation of contrast agents and allergic reactions to a certain extent, the occurrence of adverse reactions will also be affected by individual factors of patients, and other intervention methods still need to be explored for the adverse reactions caused by CT contrast examination (17, 18). Some scholars have found that reducing the severity of contrast agent extravasation and allergy through improving nursing intervention methods has a significant control effect. Among them, centrifugal massage is a fine and nursing intervention aimed at the patient's disease, and actively prepares for the possible risk factors of the patient. Through a certain degree of effective intervention, the occurrence of contrast agent extravasation and allergy can be reduced, and the severity of adverse reactions can be



reduced, it can control and prevent possible abnormal situations <sup>(19)</sup>.

At present, the treatment effect of 50% magnesium sulfate solution in contrast agent extravasation is relatively satisfactory, but due to the influence of temperature and climate, water is prone to dry and form crystals, and it is also necessary to prevent drugs from wetting other parts, thus limiting the patient's activity. Magnesium sulfate constricts blood vessels through cold compress, alleviates edema, and reduces peripheral nerve pain of patients, but its principle is to eliminate edema by changing the osmotic pressure, which takes a long time to take effect and is cumbersome to operate. Constant replacement of magnesium sulfate gauze blocks also increases nursing workload. Outpatients often can't insist on leaving until the swelling completely subsides, thus prolonging the treatment time and increasing the difficulty of nursing work. After contrast agent extravasation, patients are prone to anxiety and tension. At this time, emotional pacification must be carried out first. When patients have bad emotional status, long-term external application of magnesium sulfate gauze is easy to be obstructed by patients. The massage technique can spread the extravagated contrast agent, so as to relieve the swelling and pain faster. It can also accelerate blood circulation, remove blood stasis, as well as lessen swelling and pain. The skin friction heat generated in the process of massage can help restore the elasticity of skin blood vessels, improve blood vessel permeability and local lymphatic circulation. In addition, massage is also conducive to increasing the absorption area of drugs, so that the accumulated contrast agent can be absorbed by tissues as soon as possible and enters the metabolic process. And the massage technique takes less time than magnesium sulfate wet compress, and the acceptance of patients is higher.

In our study, the results showed that the incidence of non-permeability of contrast medium in CT enhanced scanning was low after the use of centrifugal massage nursing, which was similar to the existing research results <sup>(20)</sup>, which indicated that the implementation of centrifugal massage therapy based on conventional treatment could effectively reduce the incidence of compartment syndrome after contrast extravasation during CT enhanced scanning. Previous studies have found that reasonable and effective centrifugal massage can decline the occurrence of swelling in patients with extravasation and shorten the duration of swelling <sup>(21)</sup>. Consistently, the results of our research demonstrated that, compared with the CG, the occurrence of serious and moderate swelling in the OG was declined, and the occurrence of mild swelling in the OG was elevated. Meanwhile, the duration of swelling in the OG was also significantly reduced compared to the CG. As reported previously, centrifugal massage can find and treat extravasation patients in time, improve the

cooperation between nurses and technicians, and reduce and avoid tissue damage caused by contrast agent extravasation <sup>(1)</sup>. In line with the above literature, the results of our study also found that centrifugal massage could alleviate patients' anxiety and depression, and improve nursing satisfaction, which was also similar to the research results at home and abroad <sup>(22, 23)</sup>, which implied that centrifugal massage could improve the degree of psychological intervention of patients, establish a good nurse patient relationship, and improve the quality of treatment.

To sum up, centrifugal massage can reduce the incidence of compartment syndrome after contrast extravasation for patients undergoing CT enhanced scanning, relieve the negative emotions and promote patient satisfaction, which is worthy for clinical application.

## ACKNOWLEDGMENT

None.

**Funding:** This work was supported by the Suzhou Science and Technology Plan Project (No. SLT201953).

**Conflict of interest:** The authors confirm they have no conflicts of interest to declare.

**Ethical consideration:** This study was carried out with the approval of the ethics committee of Suzhou Kowloon Hospital (KY-2021-006, March, 2020-March, 2022).

**Author contribution:** Fang Wang and Wentong Liu participated in the study design and the literature search. Fang Wang and Wentong Liu collected the data and wrote the manuscript. Fang Wang, Wentong Liu, Shiwei Zhao and Weijie Ye revised the manuscript. All authors read and approved the final manuscript.

## REFERENCES

1. Silva HCS, Bitencourt AGV, Chojniak R. (2018) Extravasation of iodinated contrast medium in cancer patients undergoing computed tomography. *Radiologia Brasileira*, **51**(4): 236-41.
2. Esposito A, Buscarino V, Raciti D, et al. (2020) Characterization of liver nodules in patients with chronic liver disease by MRI: performance of the Liver Imaging Reporting and Data System (LI-RADS v.2018) scale and its comparison with the Likert scale. *La Radiologia Medica*, **125**(1): 15-23.
3. Conner B, Ash R, Allen W, et al. (2017) Preventing Intravenous Contrast Extravasation in CT: A Simple Solution. *Journal of the American College of Radiology*, **14**(10): 1326-32.
4. Sakellariou S, Li W, Paul MC, et al. (2016) Role of contrast media viscosity in altering vessel wall shear stress and relation to the risk of contrast extravasations. *Medical Engineering & Physics*, **38**(12): 1426-33.
5. Barrera CA, White AM, Shepherd AM, et al. (2019) Contrast Extravasation using Power Injectors for Contrast-Enhanced Computed Tomography in Children: Frequency and Injury Severity. *Academic Radiology*, **26**(12): 1668-74.
6. Savage SA, Fox C, Goldie SJ. (2022) Compartment syndrome of the hand following CT contrast extravasation. *ANZ J Surg*, doi.org/10.1111/ans.18155.
7. van Veelen NM, Link BC, Donner G, et al. (2020) Compartment syndrome of the forearm caused by contrast medium extravasa-

- tion: A case report and review of the literature. *Clin Imaging*, **61**: 58-61.
8. Grimes JA, Reed RA, Beale C, *et al.* (2021) Effect of contrast agent viscosity and massage on success of computed tomography lymphangiography with aqueous contrast for sentinel lymph node identification in healthy dogs. *Vet Comp Oncol*, **19**(3): 587-92.
  9. Scott HC, Stockdale C, Robinson A, *et al.* (2022) Is massage an effective intervention in the management of post-operative scarring? A scoping review. *J Hand Ther*, **35**(2): 186-99.
  10. Mitzel-Wilkinson A. (2000) Massage therapy as a nursing practice. *Holist Nurs Pract*, **14**(2): 48-56.
  11. Shaqdan K, Aran S, Thrall J, *et al.* (2014) Incidence of contrast medium extravasation for CT and MRI in a large academic medical centre: A report on 502,391 injections. *Clinical Radiology*, **69**(12): 1264-72.
  12. Sonis JD, Gottumukkala RV, Glover M, *et al.* (2018) Implications of iodinated contrast media extravasation in the emergency department. *The American Journal of Emergency Medicine*, **36**(2): 294-6.
  13. Dykes TM, Bhargavan-Chatfield M, Dyer RB. (2015) Intravenous Contrast Extravasation During CT: A National Data Registry and Practice Quality Improvement Initiative. *Journal of the American College of Radiology*, **12**(2): 183-91.
  14. Belzunegui T, Louis CJ, Torrededia L, *et al.* (2011) Extravasation of radiographic contrast material and compartment syndrome in the hand: a case report. *Scandinavian Journal of Trauma, Resuscitation and Emergency Medicine*, **19**: 9.
  15. Chew FS. (2010) Extravasation of Iodinated Contrast Medium During CT: Self-Assessment Module. *American Journal of Roentgenology*, **195** (6-supplement): S80-S5.
  16. Wang CL, Cohan RH, Ellis JH, *et al.* (2007) Frequency, management, and outcome of extravasation of nonionic iodinated contrast medium in 69,657 intravenous injections. *Radiology*, **243**(1):80-7.
  17. Wang Y, Qian B, Peng J. (2022) The Effect of Enhanced Multislice Spiral Computed Tomography Scan in Nursing. *Journal of Sensors*, 2022: 2950689.
  18. Kappler S, Hannemann T, Kraft E, *et al.* (2012) First results from a hybrid prototype CT scanner for exploring benefits of quantum-counting in clinical CT: SPIE, **8313**: 1-11.
  19. Nebuloni L, Kuhn GA, Müller R. (2013) A comparative analysis of water-soluble and blood-pool contrast agents for in vivo vascular imaging with micro-CT. *Acad Radiol*, **20**(10): 1247-55.
  20. Alami Z, Nasri S, Ahid S, *et al.* (2015) Extravasation of contrast medium during CT examination: an observational case-control study. *The Pan African Medical Journal*, **20**: 89.
  21. Tsai YS, Cheng SM, Ng SP, *et al.* (2007) Squeeze maneuver: an easy way to manage radiological contrast-medium extravasation. *Acta Radiol*, **48**(6): 605-7.
  22. Moon SN, Pyo JS, Kang WS. (2021) Accuracy of Contrast Extravasation on Computed Tomography for Diagnosing Severe Pelvic Hemorrhage in Pelvic Trauma Patients: A Meta-Analysis. *Medicina (Kaunas, Lithuania)*, **57**(1):53.
  23. Chen J, Xie P, Huang J, Sheng E, *et al.* (2021) Subdural contrast extravasation after percutaneous coronary intervention mimicking acute subdural hematoma: A case report. *Medicine*, **100**(17): e25583.