

# Computed tomography guided nerve interventional therapy in ischemic cerebrovascular disease

Y. Quan<sup>1</sup>, Y. Jin<sup>2</sup>, Y. Liu<sup>1</sup>, S. Hu<sup>1</sup>, X. Yin<sup>1</sup>, M. Jin<sup>1</sup>, W. Jiang<sup>1\*</sup>

<sup>1</sup>Department of Vascular Neurosurgery, New Era Stroke Care and Research Institute, The PLA Rocket Force Characteristic Medical Center, Beijing 100088, China

<sup>2</sup>Division of Life Science Metrology, National Institute of Metrology, Beijing 100013, China

## ABSTRACT

### ► Original article

**\*Corresponding author:**

Weijian Jiang, Ph.D.,

**E-mail:**

[jiangweijian2018@163.com](mailto:jiangweijian2018@163.com)

**Received:** February 2023

**Final revised:** May 2023

**Accepted:** June 2023

*Int. J. Radiat. Res.*, October 2023;  
21(4): 707-711

DOI: 10.52547/ijrr.21.4.15

**Keywords:** Cerebrovascular disease, computed tomography, hypoxia-ischemia, nerve interventional therapy, vascular recanalization.

**Background:** To explore the impact of head and neck computed tomography (CT) guided nerve interventional therapy in ischemic cerebrovascular disease (ICVD) patients. **Materials and Methods:** Patients with ICVD (n=100) admitted to our hospital from December 2021 to December 2022 were selected and randomly allocated into control group (CG) and observation group (OG). The CG received drug treatment, and the OG drug treatment before surgery and treated with head and neck CT combined with nerve intervention therapy. Interventional therapy was conducted via endovascular stenting. The National Institute Health of Stroke Scale (NIHSS) score, activities of daily living (ADL) score, vascular recanalization rate, blood flow of the diseased vessels along with occurrence of adverse reactions in both groups were compared. **Results:** After therapy, NIHSS score in both groups was declined, and lower in the OG relative to the CG (P<0.05), while ADL score in both groups was elevated, and higher in the OG relative to the CG (P<0.05). The vascular recirculation rate of the OG was 86.00%, higher relative to 60.00% in the CG (P<0.05). Vs (peak systolic flow velocity) and Vd (end diastolic flow velocity) in both groups was lessened post treatment, and lower in the OG relative to the CG (P<0.05). The occurrence of adverse reactions in two groups showed no significant difference (P>0.05). **Conclusion:** CT guided nerve interventional therapy was effective for the treatment of ICVD patients, which promoted vascular recanalization and nerve function recovery, effectively improve vascular endothelial function and cerebral blood flow of patients, and improve patient life quality.

## INTRODUCTION

Cerebrovascular diseases have emerged as the leading cause of death worldwide <sup>(1)</sup>, and ischemic cerebrovascular disease (ICVD) accounts for 75%-80% of cerebrovascular diseases <sup>(2)</sup>. With the growing aging population in China, the incidence of ICVD shows an obvious rising trend, which poses a huge burden to the patients and society <sup>(3)</sup>. As a disorder of blood supply to brain tissue caused by hemodynamic disorders, ICVD refers to the occurrence of ischemia together with hypoxia of brain tissues in the matched blood supply area, leading to softening and death of brain tissue <sup>(4)</sup>. It mainly includes the transient ischemic attacks and acute cerebral infarction, with atherosclerosis-induced artery stenosis or occlusion as the main cause <sup>(5)</sup>. The traditional treatment of ICVD mainly used surgery and supplemented with drugs, such as anticoagulant, antithrombotic, stable atherosclerotic plaque therapy, but the therapeutic effect is not satisfactory <sup>(6)</sup>. Therefore, effective treatment approach is needed to avoid disability and death.

Interventional therapy refers to a minimally invasive means used for the identification of the

artery stenosis location and the treatment of cerebrovascular diseases via intubation with the aid of computer <sup>(5)</sup>. As a safe, minimally invasive method with low incidence of complications, nerve interventional therapy is widely applied in recent years, which can act on the diseased blood vessels, make them open quickly, effectively reduce the infarct area, and save patients from the pain of craniotomy, with significant effect in clinical practice, offering a novel approach for the administration of cerebrovascular occlusion <sup>(7,8)</sup>. Besides, Studies have demonstrated the clinical effect of interventional therapy with the application of CT machines as auxiliary imaging in patients with ICVD <sup>(9)</sup>.

Imaging is a reliable approach extensively applied in the diagnosis and management of cerebrovascular diseases, and deepens our understanding of cerebrovascular physiology <sup>(10)</sup>. The commonly used imaging facilities in interventional therapy include angiography machine, fluoroscopy machine, and computed tomography (CT) machine <sup>(11,12)</sup>. Imaging techniques with the advantages of clearly showing the stenosis in the intracranial and extracranial artery, provides a reliable reference for clinical assessment and can improve the treatment outcomes

of interventional therapy<sup>(5)</sup>.

In this study, we aimed to elucidate the impact of head and neck CT guided nerve interventional therapy in ICVD patients. The findings of our study might provide novel insight into the effective management of ICVD patients.

## MATERIALS AND METHODS

### Patients

Totally 100 patients with ICVD admitted to our hospital from December 2021 to December 2022 were enrolled in this study and randomly divided into control group (CG) and observation group (OG), with 50 patients in each group. In the OG, there were 28 male patients and 22 female patients, with the age from 62 to 80 and an average age of  $70.82 \pm 4.36$  years. The average onset time was  $3.87 \pm 1.08$  hours (h). There were 18 cases of diabetes mellitus, 24 cases of hypertension, and 8 cases of hyperlipidemia. In the CG, 27 male patients and 23 female patients were included, with the age from 59 to 81 years old, and the average age was  $71.05 \pm 4.37$  years. The average onset time was  $3.90 \pm 1.12$  h. There were 19 cases of diabetes mellitus, 23 cases of hypertension, and 9 cases of hyperlipidemia. There were no significant differences in general data between both groups ( $P > 0.05$ ).

Inclusion criteria: (1) Meeting the diagnostic criteria of ICVD and under head CT or magnetic resonance imaging (MRI) confirmation. (2) No contraindications of interventional surgery in the observation group. (3) The informed consent was signed by all patients as well as their families.

Exclusion criteria: (1) Patients with malignant tumor or serious heart, liver or kidney disease. (2) Patients with coagulation dysfunction or contraindications of anti-platelet agglutination drugs. (3) Patients with severe bleeding tendency. (4) Patients allergic to contrast media. (5) Patients with uncontrolled hypertension. (6) Patients who were allergic to the drugs used in this study.

### Methods

Patients in the CG were given drug treatment, including oral administration of clopidogrel bisulfate tablets (Shiyao Group Euyi Pharmaceutical Co., LTD., China) and aspirin (Hunan Xinhui Pharmaceutical Co., LTD., China). The dose of clopidogrel bisulfate tablets was 75 mg/ time, once a day, and the dose of aspirin was 100 mg/ time, once a day. The course of treatment lasted 6 months.

Patients in the OG were treated with head and neck CT (Philips Brilliance 64-slice spiral CT, Philips Medical Systems, the Netherlands) combined with nerve intervention therapy, and took aspirin and clopidogrel orally for 5 days before surgery, with usage and dosage consistent with the CG. With the

assistance of CT, the 6F and 8F arterial sheaths (Cook incorporated, USA) were placed by femoral artery approach, vertebral artery stents, and carotid artery stents, respectively, and then systemic heparinization and CT were performed to determine the location and extent of arterial stenosis. Then, 6F and 8F guide catheters (Cerenovus, Fremont, CA, USA) were placed in the proximal end of the lesion, microguide wires (Asahi SION, Japan) were inserted into them, and the stent was implanted into the stenosis site with the aid of a balloon (Boston Scientific, USA). The dilation and blood supply of each segment of intracranial blood vessel after the stent release was observed. The operation was completed when there was no abnormal condition. The neurological function and vital signs of the patient should be closely monitored in the first 24 hours after the operation. The arterial sheath was removed within 5 hours after the operation, and then compressed for about 30 minutes to observe the bleeding situation. If there was no bleeding, elastic bandage could be used to immobilize the affected part for 6 hours. Postoperative drug therapy was performed for 6 months.

### Observation indicators

Neurological impairment before treatment and 6 months after therapy was compared using the National Institute Health of Stroke Scale (NIHSS) score<sup>(13)</sup>. The self-care ability of both groups was compared before treatment and 6 months after treatment using the activities of daily living (ADL) score<sup>(14)</sup>. The vascular recanalization condition of patients after treatment was evaluated. Complete recanalization: blood vessels were unblocked and perfusion was completely restored in the ischemic area. Partial recanalization: the blood vessel was partially unblocked and the perfusion area was less than 50%. Non-recanalization: no significant changes after treatment, perfusion did not resume. Comparison of blood flow of the diseased vessels between both groups: Before and after therapy, color Doppler ultrasound machine (Toshiba Medical, Tokyo, Japan) was used to observe the peak systolic flow velocity (Vs) as well as end diastolic flow velocity (Vd) of the vessels with craniocerebral lesions in both groups. The occurrence of adverse reactions, including subcutaneous hematoma, cerebral infarction, and transient ischemic attack, were observed in both groups.

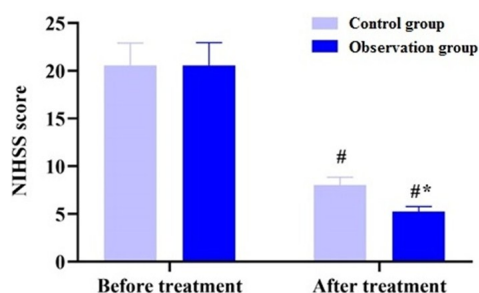
### Statistical analysis

Results were analyzed using SPSS 20.0 statistical software (IBM Corporation, Chicago, IL, USA). Measurement data are presented as the mean  $\pm$  standard deviation and analyzed with t-test. The statistical data were expressed by the rate (%) and subject to  $\chi^2$  test.  $P < 0.05$  was considered to be statistically significant.

## RESULTS

### NIHSS score in both groups

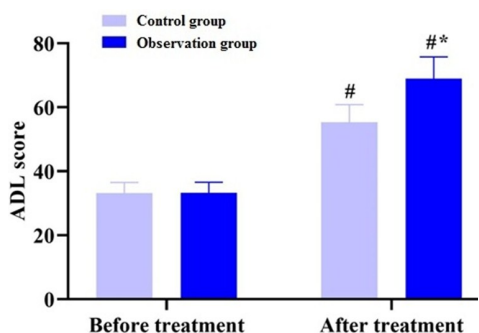
NIHSS score in both groups was declined after therapy, and that in the OG was lower relative to the CG, which indicated that the CT-guided nerve interventional therapy effectively alleviated the neurological impairment and promoted nerve function recovery in ICVD patients relative to drug treatment alone ( $P < 0.05$ , figure 1).



**Figure 1.** NIHSS score for neurological impairment evaluation in patients before and after the therapy in both groups. NIHSS, National Institute Health of Stroke Scale. # $P < 0.05$ , compared with before treatment, \* $P < 0.05$ , compared with the control group.

### ADL score in both groups

ADL score in both groups was elevated after therapy, and was higher in the OG relative to the CG, suggesting that the self-care ability of ICVD patients was more effectively improved after the CT-guided nerve interventional therapy compared with administration with conventional drugs ( $P < 0.05$ , figure 2).



**Figure 2.** ADL score for the evaluation of self-care ability of patients before and after the treatment in both groups. ADL, activities of daily living. # $P < 0.05$ , compared with before treatment, \* $P < 0.05$ , compared with the control group.

### Vascular recanalization in both groups

As displayed in table 1, the vascular recirculation rate of the OG was 86.00%, which was higher than that of 60.00% in the CG, which indicated that the CT-guided nerve interventional therapy showed better treatment efficacy and more effectively promoted vascular recanalization of ICVD patients ( $P < 0.05$ ).

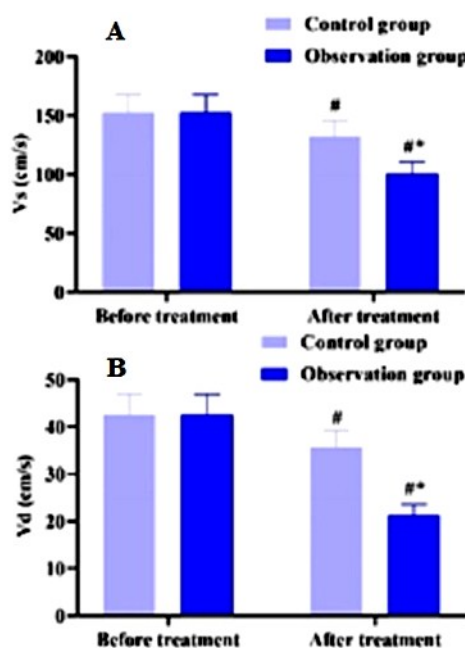
### Vs and Vd of diseased vessels in both groups

As displayed in figure 3, Vs and Vd in both

groups were lessened post therapy, and those in the OG were lower in comparison with the CG, which implied that CT-guided nerve interventional therapy effectively improved vascular endothelial function as well as the cerebral blood flow of diseased vessels in ICVD patients ( $P < 0.05$ , figure 3).

**Table 1.** Vascular recanalization condition of patients after treatment in both groups (n, %).

Groups	Complete recanalization	Partial recanalization	Non-recanalization	Recanalization rate (%)
Control group (n=50)	15	16	19	31 (62.00%)
Observation group (n=50)	28	15	7	43 (86.00%)
$\chi^2$	7.48			
P	<0.05			



**Figure 3.** Vs (A) and Vd (B) for the evaluation of blood flow of diseased vessels in patients before and after the treatment in both groups. Vd, end diastolic flow velocity; Vs, peak systolic flow velocity. # $P < 0.05$ , relative to before treatment, \* $P < 0.05$ , relative to control group.

### Occurrence of adverse reactions in both groups

The total incidence rate of adverse events such as subcutaneous hematoma, cerebral infarction and transient ischemic attack was 14% in the CG and 2% in the OG. The occurrence of adverse reactions was relatively lower in the OG but with no statistical significance ( $P > 0.05$ , table 2).

**Table 2.** Incidence rate of adverse reactions in patients after treatment in both groups (n, %).

Groups	Subcutaneous hematoma	Cerebral infarction	Transient ischemic attack	Total incidence rate (%)
Control group (n=50)	0	3	4	7 (14.00)
Observation group (n=50)	2	0	0	2 (4.00%)
$\chi^2$	3.29			
P	>0.05			

## DISCUSSION

ICVD is relatively common in clinic, which mainly affected the middle-aged and elderly population<sup>(15)</sup>. Recently, the incidence of this disease in our country is increasing year by year and has a development trend among young people<sup>(16)</sup>. Characterized by the rapid onset, rapid progression, relatively high mortality and disability rates, ICVD presents the requirements of timely and effective treatment<sup>(17)</sup>. The main clinical treatment is drug and surgery, but drug therapy usually cannot effectively improve the stenosis of the lumen, with a high recurrence rate of secondary embolism<sup>(18)</sup>. The nerve interventional surgery is developed and has been widely used to treat cerebrovascular diseases, which can improve cerebral blood perfusion, facilitate the opening of occlusive blood vessels, as well as reduce the risk of secondary cerebral hemorrhage<sup>(19)</sup>. In this study, we demonstrated that CT guided nerve interventional therapy was more effective in the treatment of ICVD relative to drug treatment alone, which may provide insight into the therapy of ICVD patients.

The vascular structure of human brain is very complex and the tissue precision is extremely high. CT machine has high sensitivity, which can help doctors provide more information about the brain during the operation of patients<sup>(20)</sup>. In addition, CT can not only observe the small blood vessels in the head and neck from multiple angles, but also visually observe the structural characteristics of the lesions and accurately locate the lesions<sup>(21)</sup>. Therefore, CT is the basis of nerve interventional surgery, with irreplaceable significance. Endovascular therapy based on stented-assisted angioplasty provides a safe approach for patients with intracranial stenosis<sup>(22)</sup>. A retrospective study has revealed that the CT guided endovascular recanalization is a reliable and effective way to treat patients with acute ischemic stroke<sup>(23)</sup>. The contrast agent was injected into the target blood vessel to obtain the CT image to reflect the collateral circulation and cerebral blood flow, so as to understand the details of the lesions, which was conducive to the development of interventional surgery and has guiding significance for the prediction of surgical risk and the judgment of surgical efficacy<sup>(24)</sup>. Assisted by CT, the stent was sent to the lesion site for interventional therapy, which could effectively reduce the stenosis of blood vessels, reduce the ischemic symptoms of patients, and facilitate the flow perfusion of reversible injured neurons as well as neurological function recovery. In our study, CT was used to guide the endovascular stenting in nerve interventional therapy of ICVD patients. After treatment, the OG showed lower NIHSS score in comparison with the CG (figure 1), and the ADL score of the OG was higher compared to the CG (figure 2). The vascular recirculation rate of the OG was 86.00%, higher than that of 60.00% in the CG (table 1). The previous literature indicates that

the treatment efficacy of CT perfusion imaging guided neurointerventional thrombolysis reached 95.12%, which is significantly higher than in those treated with intravenous thrombolysis using the rt-PA alone, and the results of our study are basically consistent with the previous findings<sup>(25)</sup>. It is suggested that CT guided nerve interventional treatment of ICVD had good curative effect, which could dredge blocked blood vessels in patients, improve their nerve function, as well as promote the quality of life of patients. Besides, the OG showed significantly lower Vs and Vd in comparison with the CG after treatment, indicating that CT guided nerve interventional therapy could effectively improve the cerebral blood flow in patients with ICVD (figure 3). The reasons may be that interventional therapy guided by CT could effectively restore normal blood flow in ischemic brain tissue to improve the condition of ischemia and hypoxia in patients, relieve the clinical symptoms of patients, and restore the normal function of ischemic penumbra brain tissue. At the same time, stent implantation is conducive to re-repairing the rough intima of the stenosis site, which effectively prevents plaque shedding and thrombosis.

In addition, due to the high potential danger of ICVD, whether the treatment program has good safety is also the core index to evaluate its clinical value. In this study, adverse events such as subcutaneous hematoma, cerebral infarction, and transient ischemic attack were observed in both groups of patients, while the incidence rate of adverse events was not significantly different between the CG and OG groups, implying that head and neck CT combined with neuronal intervention could avoid neuronal damage to patients to the maximum extent, and the treatment accuracy was higher than drug regimen, with relatively high safety (table 2), which was somewhat different from relevant literature report showing that only intracranial hemorrhage is observed in patients after treatment<sup>(26)</sup>.

In conclusion, CT guided nerve interventional therapy showed good curative effect for ICVD patients, which can effectively attenuate neurological impairment, promote vascular recanalization and nerve function recovery, improve cerebral blood flow, and thus improve the quality of life of patients.

## ACKNOWLEDGMENT

*None.*

**Funding:** This study was supported by the grants from National Key Basic Research Program of China (973 program) (No. 2013CB733805), and the National Natural Science Foundation of China (No. 81871464).

**Conflicts of interests:** The authors declare no conflicts of interest in this study.

**Ethical consideration:** This study was approved by the institutional ethics committee at the PLA Rocket

Force Characteristic Medical Center approval (X2017008).

**Author contribution:** Y.Q. and W.J., conceived and designed the study. Y.J., Y.L., collected the clinical data. S.H., X.Y. and M.J., conducted the data analysis. Y.Q., wrote the draft manuscript and the other authors reviewed and revised the manuscript. All authors read and approved the final version of manuscript.

## REFERENCES

- Peng LP, Cao Y, Zhao SL, et al. (2019) Memory T cells delay the progression of atherosclerosis via AMPK signaling pathway. *Annals of Translational Medicine*, **7**(23): 782.
- Liu W, Wong A, Law AC, et al. (2015) Cerebrovascular disease, amyloid plaques, and dementia. *Stroke*, **46**(5): 1402-7.
- Caprio FZ and Sorond FA (2019) Cerebrovascular Disease: Primary and Secondary Stroke Prevention. *Med Clin North Am*, **103**(2): 295-308.
- Al-Kawaz M, Cho SM, Gottesman RF, et al. (2022) Impact of Cerebral Autoregulation Monitoring in Cerebrovascular Disease: A Systematic Review. *Neurocrit Care*, **36**(3): 1053-70.
- Wang X, Zhang X, Guan Q, et al. (2022) Clinical effect of digital subtraction angiography combined with neurointerventional thrombolysis for acute ischemic cerebrovascular disease and its influence on vascular endothelial function and oxidative stress. *Oxidative Medicine and Cellular Longevity*, **2022**: 2777865.
- Zhao QQ, Li X, Luo LP, et al. (2019) Repurposing of approved cardiovascular drugs against ischemic cerebrovascular disease by disease-disease associated network-assisted prediction. *Chem Pharm Bull (Tokyo)*, **67**(1): 32-40.
- Hao Y, Qi Z, Ding Y, et al. (2019) Effect of interventional therapy on IL-1 $\beta$ , IL-6, and neutrophil-lymphocyte ratio (NLR) levels and outcomes in patients with ischemic cerebrovascular disease. *Med Sci Monit*, **25**: 610-7.
- Feng S, Yang Q, Liu M, et al. (2011) Edaravone for acute ischaemic stroke. *The Cochrane Database of Systematic Reviews*, **12**: Cd007230.
- Mukherjee A, Muthusami P, Mohimen A, et al. (2017) Noncontrast Computed Tomography versus Computed Tomography Angiography Source Images for Predicting Final Infarct Size in Anterior Circulation Acute Ischemic Stroke: a Prospective Cohort Study. *J Stroke Cerebrovasc Dis*, **26**(2): 339-46.
- Dehkharghani S and Andre J (2017) Imaging approaches to stroke and neurovascular disease. *Neurosurgery*, **80**(5): 681-700.
- Gruberg L (2022) Robotic-assisted percutaneous coronary intervention: Rise of the Machines. *Cardiovasc Revasc Med*, **43**: 120-2.
- Narang A, Guerrero M, Feldman T, et al. (2016) Computed tomography assessment for transcatheter mitral valve interventions. *J Cardiovasc Surg (Torino)*, **57**(3): 360-71.
- Chalos V, van der Ende NAM, Lingsma HF, et al. (2020) National Institutes of Health Stroke Scale: An Alternative Primary Outcome Measure for Trials of Acute Treatment for Ischemic Stroke. *Stroke*, **51**(1): 282-90.
- Lau BC, Scribani M, Lassiter T, et al. (2019) Correlation of single assessment numerical evaluation score for sport and activities of daily living to modified harris hip score and hip outcome score in patients undergoing arthroscopic hip surgery. *Am J Sports Med*, **47**(11): 2646-50.
- Diener HC, Katsarava Z, Weimar C (2008) Headache associated with ischemic cerebrovascular disease. *Rev Neurol (Paris)*, **164**(10): 819-24.
- Lanzino G and Brown Jr. RD (2014) Introduction: management of ischemic cerebrovascular disease. *Neurosurg Focus*, **36**(1): 1-2.
- Alatli T, Kocaoglu S, Akay E (2022) The relationship of LDH and hematological parameters with ischemic volume and prognosis in cerebrovascular disease. *J Coll Physicians Surg Pak*, **32**(1): 42-5.
- Shaban S, Huasen B, Haridas A, et al. (2022) Digital subtraction angiography in cerebrovascular disease: current practice and perspectives on diagnosis, acute treatment and prognosis. *Acta Neurol Belg*, **122**(3): 763-80.
- Pantoni L (2010) Cerebral small vessel disease: from pathogenesis and clinical characteristics to therapeutic challenges. *Lancet Neurol*, **9**(7): 689-701.
- Xiang SF, Li JT, Yang SJ, et al. (2022) Whole-brain volume CT angiography can effectively detect early ischemic cerebrovascular diseases. *Curr Med Imaging*, **18**(7): 731-8.
- Wang PQ, Wang AP, Cao ZH, et al. (2015) The study of the distribution character of cerebral arterial stenosis in patients with ischemic cerebrovascular disease by means of 64 slices CT. *Eur Rev Med Pharmacol Sci*, **19**(12): 2287-92.
- Lu J and Wang DM (2021) [Update in endovascular therapy of ischemic cerebrovascular disease]. *Zhonghua wai ke za zhi [Chinese journal of surgery]*, **59**(3): 192-5.
- Turk AS, Magarick JA, Frei D, et al. (2013) CT perfusion-guided patient selection for endovascular recanalization in acute ischemic stroke: a multicenter study. *J Neurointerv Surg*, **5**(6): 523-7.
- Wang PQ, Wang Y, Zhang GB, et al. (2015) Study on the carotid atherosclerotic plaque of patients suffering from ischemic cerebrovascular disease by 64 slices CT. *Eur Rev Med Pharmacol Sci*, **19**(18): 3480-5.
- Fu HW LG (2019) Clinical efficacy observation of DSA combined with neurointerventional thrombolysis in the treatment of ischemic cerebrovascular disease. *Practical Journal of Clinical Medicine*, **16**(6): 178-82.
- Burkart DJ, Day JS, Henderson K, et al. (2013) Efficacy of peripheral interventional radiologists performing endovascular stroke therapy guided by CT perfusion triage of patients. *J Vasc Interv Radiol*, **24**(9): 1267-72.

