

# Preliminary analysis of clinical effect observation and prognostic recurrence factors of ultrasound-guided sclerotherapy of renal and hepatic cysts

L. Li, J. Luo, H. Lu\*

Department of Ultrasound, Wuxi NO.8 People's Hospital Group, Wuxi, Jiangsu, 214000, China

## ABSTRACT

### ► Original article

#### \*Corresponding author:

Hailan Lu, Ph.D.,

E-mail: wuxihailan8@163.com

Received: February 2023

Final revised: May 2023

Accepted: June 2023

Int. J. Radiat. Res., October 2023;  
21(4): 719-725

DOI: 10.52547/ijrr.21.4.17

**Keywords:** Hepatic cysts, cystic kidney disease, endoscopic ultrasound-guided fine needle aspiration, sclerotherapy, polidocanol, ethanol.

**Background:** To investigate the difference in the effect of ultrasound-guided puncture injection of polidocanol (PO) and ethanol (ET) in the treatment of renal and hepatic cysts (RHC), and to analyze the factors related to patients' prognosis of disease recurrence. **Materials and Methods:** A total of 105 patients with RHC admitted to our hospital from August 2020 to August 2021. Among them, 59 patients received ultrasound-guided puncture injection of ET (control group); the rest 46 received ultrasound-guided puncture injection of PO (observation group). The success rate of one-time puncture and adverse reactions of the two groups were counted, and the levels of C-reactive protein (CRP), Cortisol (Cor), liver and kidney function. Patients were then followed up for a one-year prognosis, and the prognosis of RHC recurrence was recorded. Logistic regression analysis was performed to analyze the factors associated with the recurrence of cysts. **Results:** Postoperative CRP and Cor were observed to be lower than those in the control group, and hepatic and renal function was better than that in the control group ( $P < 0.05$ ). In addition, the incidence of adverse reactions was lower in the observation group than in group B ( $P < 0.05$ ). Cyst diameter, incomplete cyst aspiration, and post-sclerotic segregation were high-risk independent factors affecting prognostic cyst recurrence ( $P < 0.05$ ). **Conclusion:** Ultrasound-guided injection of PO puncture sclerosis for RHC has excellent results. At the same time, patients need to be concerned about the diameter of the cyst, incomplete aspiration of the cystic fluid, and whether the cyst is separated after sclerosis.

## INTRODUCTION

Renal and hepatic cyst (RHC) is one of the common benign lesions, and patients mostly show symptoms such as abdominal pain and distension after the onset of the disease. Untimely treatment may easily cause complications such as cyst rupture or bleeding, which may pose a certain threat to patients' life safety<sup>(1)</sup>. Recently, with the aggravation of the aging population and changes in people's lifestyle habits, the incidence of RHC has been increasing, with more than 3 million new cases worldwide by 2018, and about 20-30% of these patients eventually develop malignant disease, which has serious implications for life safety<sup>(2,3)</sup>. Thus, the timely treatment of RHC is of great importance to safeguard the health of patients<sup>(4)</sup>. Although conventional surgical treatment can help patients to completely remove cysts, this method is more damaging and expensive, and is not suitable for clinical promotion<sup>(5)</sup>. The potential threat of difficulty in surgical treatment is further increased by the fact that most patients with RHC are middle-aged and elderly and are often combined with other underlying diseases<sup>(6)</sup>. And with the continuous improvement of

ultrasound interventional technology, puncture sclerotherapy has been more and more widely used in clinical practice<sup>(7)</sup>. As a minimally invasive ultrasound-guided therapy, ultrasound-guided puncture sclerotherapy greatly enhances the safety of the treatment on the premise of safeguarding patients' safety and enables them to obtain more desirable results in postoperative rehabilitation<sup>(8)</sup>. However, the choice of sclerosing agent in puncture sclerotherapy is still controversial in clinical practice, and ethanol (ET) has been reported as the most classical sclerosing agent, and its effectiveness has been verified many times with high clinical applicability<sup>(9)</sup>. polidocanol (PO), a new polymeric compound sclerosing agent that also has analgesic and anti-inflammatory effects, will probably achieve more significant results in puncture sclerotherapy<sup>(10)</sup>.

At present, few studies have reported on the difference in the effectiveness of ET and PO in the application of sclerotherapy for RHC puncture, and there is a lack of reliable reference and guidance in the selection of sclerosing agents in clinical practice. Therefore, in this study, the effects of two sclerosing agents on RHC were observed in RHC patients and

are reported below. And this study can provide reference and guidance for future sclerotherapy of RHC, which can improve the prognosis of RHC patients.

## MATERIALS AND METHODS

### Patient data

A total of 105 patients with RHC admitted to our hospital from August 2020 to August 2021 were selected for prospective analysis. Among them, 59 patients received ultrasound-guided puncture injection of ET (Shaanxi Tianyu Pharmaceutical Co., Ltd, H20080445, China) and were regarded as the control group; the rest 46 received ultrasound-guided puncture injection of PO (Jinan Lanjue Trading Co., China) and were regarded as the observation group. The study was conducted in strict compliance with the Declaration of Helsinki and was approval from the Ethics Committee of Wuxi NO.8 People's Hospital (registration number: 20200653, registration time: June 2020.)

### Inclusion and exclusion criteria

Inclusion criteria: diagnosis of hepatic cyst or renal cyst, size greater than 3 cm, single cyst, confirmed by pathological examination, complete medical history; signed informed consent forms from patients. Exclusion criteria: contraindications to ultrasound interventional sclerotherapy, allergy to ET and PO, combined metabolic diseases, combined coagulation disorders, combined malignancies.

### Treatment methods

After disinfection of the operative area and local anesthesia with 2% lidocaine (Shanxi Jinxin Shuanghe Pharmaceutical Co., Ltd, H11022295, China), the puncture needle (PCT18G, HAKKOU, Japan) was inserted into the cyst under color Doppler ultrasound (Philips IU-22, Netherlands) guidance, and the ultrasound ensured that the puncture needle was always near the central 1 / 2 of the cyst. A three-way pipe was then connected and all the cyst contents were aspirated. Patients in the control group made foam sclerosing agent according to the ratio of ET: air = 1:4, injected in a volume of 1 / 4 of the cyst volume, and injected in several times, with a single injection volume less than or equal to 60 mL, which was kept for 5 min after injection and withdrawn. In the observation group, foam sclerosing agent was made according to the ratio of PO: air = 1:4, and 100 mg was injected for cyst diameter less than or equal to 6 cm, and 200 mg was injected for diameter greater than 6 cm. The puncture site was disinfected, and sterile dressing was applied after the sclerotherapy injection was completed. Postoperatively, patients were instructed to shift position regularly to ensure adequate contact between the sclerosing agent and the capsule wall.

Image images are shown in figures 1-5.

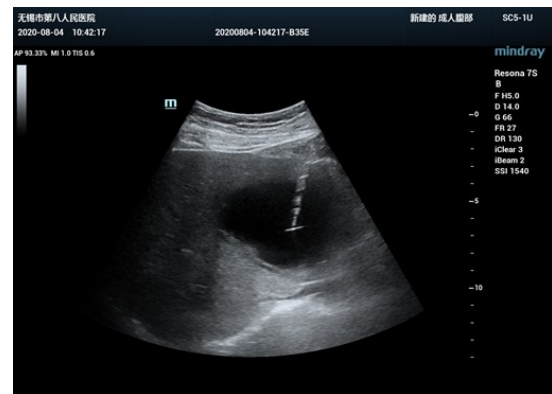


Figure 1. Real-time guided puncture of the needle into the cyst to the mid-posterior 1/3-1/2 of the cyst.

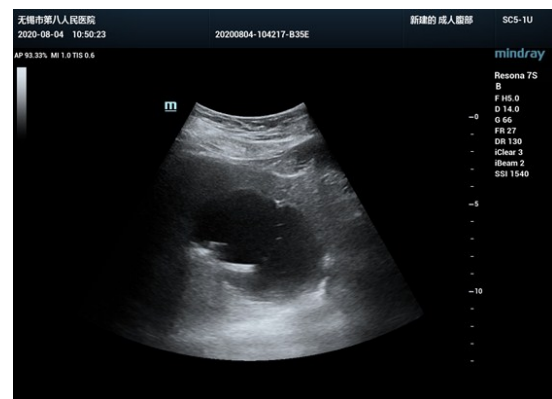


Figure 2. Pull out the needle core and connect the syringe.

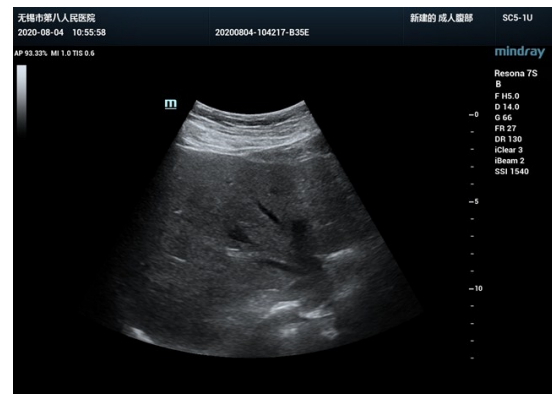


Figure 3. Evacuation of the cyst fluid.

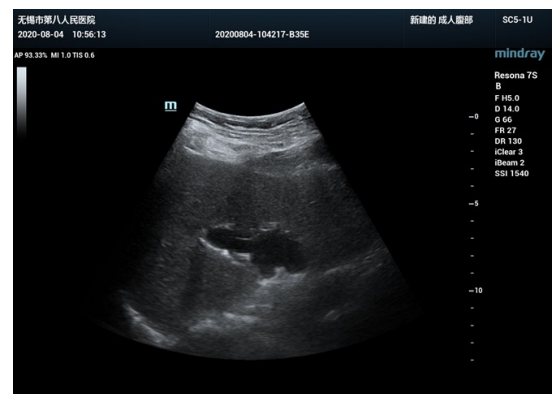


Figure 4. Injection of hardener.

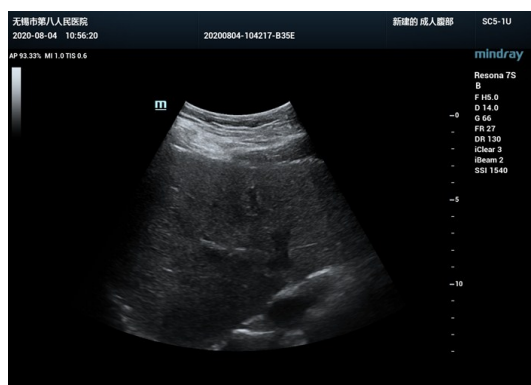


Figure 5. Extraction of hardener.

### Blood sample collection and testing

Fasting venous blood was drawn from patients before surgery (T0), 12 h after surgery (T1) and 24 h after surgery (T2), respectively, and the levels of C-reactive protein (CRP) and Cortisol (Cor) were measured by chemiluminescence (Brocade BK12200 Fully Automatic Chemiluminescent Immunoassay Analyzer, USA) after centrifugation to obtain serum. Blood was also taken before and 1 week after surgery, and alanine transaminase (ALT), aspartate transaminase (AST) and total bilirubin (TBil) were measured by automatic biochemical analyzer (Myriad BS-2800M Automatic Biochemistry Analyzer, China). Serum creatinine (Scr) and blood urea nitrogen (BUN) were detected by immunoturbidimetric method.

### Efficacy evaluation

The clinical outcome of patients was assessed at 6 months postoperatively <sup>(11)</sup>. Cured: complete disappearance of the cyst. Effective: greater than 50% reduction in cyst volume. Markedly effective: cyst volume reduction greater than 30% but less than 50%. Ineffective: cyst volume reduction <30% or enlargement. Effective rate = (cured + effective) / total number of patients × 100%.

### Prognostic follow-up

Patients were followed up for 1 year after discharge from the hospital and were notified by telephone to return for review. Each patient should be reviewed at least 3 times within 1 year, with a controlled interval of 2-4 months between each review. The follow-up end event was patients' RHC recurrence (the presence of a new cyst on ultrasonography was defined as a recurrence).

### Outcome measures

The one-time puncture success rate and procedure time in both groups. (2) Changes in CRP, Cor and hepatic and renal function indices before and after surgery. (3) Clinical efficacy. (4) Adverse reactions during the postoperative period until discharge from the hospital. (5) Factors associated with prognostic recurrence affecting RHC.

### Statistical analysis

Statistical analysis of the data results of this study was performed using SPSS 21.0 software. Data such as operative time and intraoperative bleeding were expressed as ( $\bar{x} \pm s$ ), and t-test was used for comparison between groups, and paired t-test, analysis of variance (ANOVA) and Bonferroni test were used for that within groups. Data on clinical efficacy and adverse reactions were expressed as (%), and the  $\chi^2$  test was used for comparison between groups. Correlation factors were analyzed using logistic regression.  $P < 0.05$  was considered a statistically remarkable difference.

## RESULTS

### Comparison of surgical situations

As shown in table 1, the one-time puncture success rate and operative time were 91.3% and (19.4±5.4) min in the observation group and 89.8% and (20.1±5.1) min in the control group, respectively. The differences in one-time puncture success rate and operative time between groups were not statistically remarkable ( $P > 0.05$ ).

Table 1. Surgical situations.

	n	One-time puncture success	Operative time (min)
Control group	59	53 (89.8)	20.1±5.1
Observation group	46	42 (91.3)	19.4±5.4
$\chi^2$ or t		0.065	0.680
P		0.799	0.498

### Comparison of traumatic stress levels

As shown in figure 6, no difference was seen in the comparison of CRP and Cor levels between both groups of patients at T0 ( $P > 0.05$ ). At T1, CRP and Cor were elevated in both groups, and at this time the observation group was lower than the control group ( $P < 0.05$ ). At T2, the levels of CRP and Cor in the two groups were lower than those at T1, but still higher than those at T0, and the levels of CRP and Cor in the observation group were still lower than those in the control group ( $P < 0.05$ ).

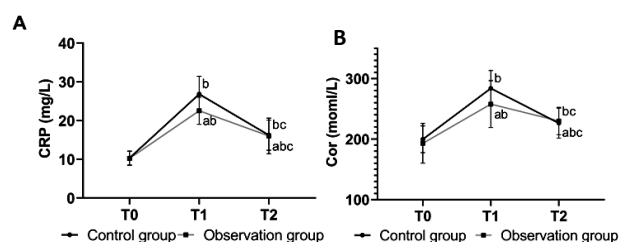
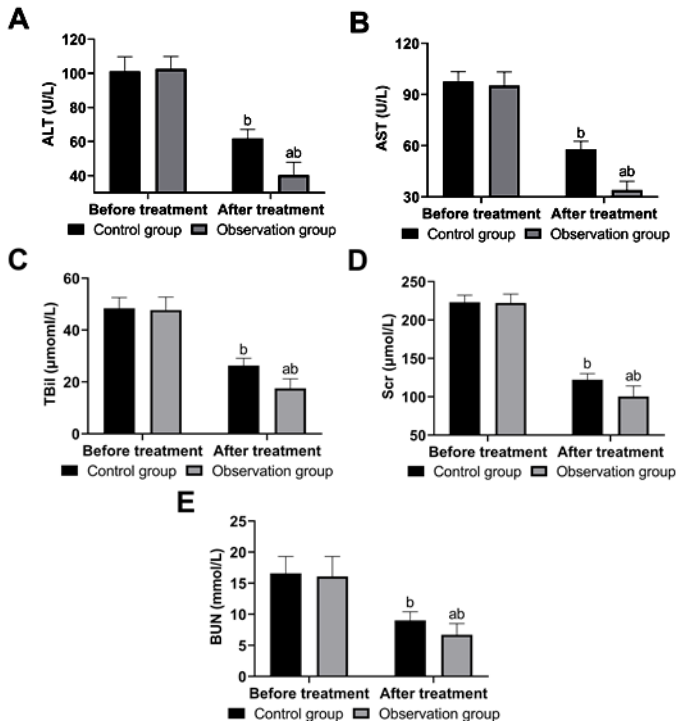


Figure 6. Traumatic stress levels. (A) Comparison of CRP. (B) Comparison of Cor. compared with observation group,  $aP < 0.05$ . compared with T0,  $bP < 0.05$ . compared with T1,  $cP < 0.05$ . CRP and Cor were higher than T0 in both groups at T1 and higher in the control group than in the observation group; CRP and Cor were higher than T0 and lower than T1 in both groups at T2. Note: C-reactive protein (CRP), Cortisol (Cor).

### Comparison of hepatic and renal function

As shown in figure 7, hepatic and renal function between both groups before treatment also manifested no difference ( $P>0.05$ ). After treatment, ALT, AST, TBil, Scr, and BUN were lower in the observation group than in the control group ( $P<0.05$ ). The hepatic and renal function indexes were lower in both groups after treatment compared with those before treatment ( $P<0.05$ ).



**Figure 7.** Hepatic and renal function. (A) Comparison of ALT. (B) Comparison of AST. (C) Comparison of TBil. (D) Comparison of Scr. (E) Comparison of BUN. Compared with observation group, aP < 0.05. Compared with before treatment, bP < 0.05. The ALT, AST, TBil, Scr, and BUN in both groups were lower than those before treatment, and the ALT, AST, TBil, Scr, and BUN in the observation group were lower than those in the control group after treatment. Note: alanine transaminase (ALT), aspartate transaminase (AST), total bilirubin (TBil), serum creatinine (Scr) and blood urea nitrogen (BUN).

### Comparison of clinical efficacy

As shown in table 2, the total effective rate of treatment in the observation group was 76.3%, while the rate in the control group was 80.4%. The difference in their total effective rate of treatment was not statistically marked ( $P<0.05$ ).

**Table 2.** Clinical efficacy.

	n	Cured	Effective	Markedly effective	Ineffective	Effective rate
Control group	59	26 (44.1)	19 (32.2)	10 (16.9)	4 (6.8)	76.3%
Observation group	46	23 (50.0)	14 (30.4)	6 (13.0)	3 (6.5)	80.4%
$\chi^2$						0.262
P						0.609

### Comparison of adverse reactions

As shown in table 3, during the treatment,

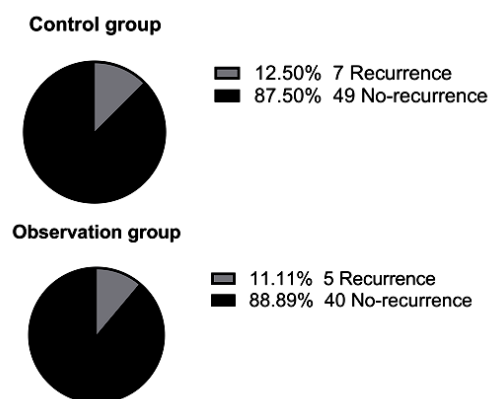
patients in both groups had different degrees of adverse reactions such as fever and intracapsular bleeding, with the incidence of adverse reactions in the observation group being 10.9% and that in the control group being 27.10%. It was seen that the incidence of adverse reactions was lower in the observation group ( $P<0.05$ ).

**Table 3.** Adverse reactions.

	n	Fever	Intracapsular bleeding	Nausea and vomiting	Drunken reaction	Total incidence rate
Control group	59	4 (8.5)	5 (8.5)	3 (5.1)	4 (6.8)	27.1%
Observation group	46	2 (4.3)	1 (2.2)	1 (2.2)	1 (2.2)	10.9%
$\chi^2$						
P						

### Univariate analysis affecting prognosis and recurrence of RHC

Forty-five cases in the observation group and 56 in the control group were successfully followed up in the prognostic follow-up, with a follow-up success rate of 96.19%. As shown in figure 8, five patients in the observation group had disease recurrence, with an overall recurrence rate of 11.1%. In the control group, 7 cases relapsed, with an overall recurrence rate of 12.5%. The difference in recurrence rate between the two groups was not statistically remarkable ( $P>0.05$ ). As shown in table 4, no differences were seen between the data of age and gender of patients with recurrent cysts compared with those without recurrence ( $P>0.05$ ), while the differences between the data of cyst diameter, incomplete aspiration of cyst fluid, and dislodged puncture needle were statistically obvious ( $P<0.05$ ).



**Figure 8.** Prognosis RHC recurrence. The overall recurrence rate was 12.5% in the control group and 11.1% in the observation group, with no difference between the two groups ( $P>0.05$ ).

### Multivariate analysis affecting prognosis and recurrence of RHC

Multiple logistic regression analysis was performed to assign values to the univariate indicators with differences mentioned above (table 5), and they were used as covariates, with the presence or absence of cyst recurrence in patients as

the dependent variable. The output results are shown in Table 6, which shows that puncture needle dislodgement was not an independent factor affecting cyst recurrence ( $P>0.05$ ), while cyst diameter, incomplete cyst aspiration, and post-sclerotic separation were all independent risk factors affecting cyst recurrence ( $P<0.05$ ).

**Table 4.** Univariate analysis affecting prognosis and recurrence of RHC.

	No-recurrence patients (n=89)	Recurrence patients (n=12)	$\chi^2$	P
<b>Age</b>			0.107	0.744
≥60 / <60	34 / 55	4 / 8		
<b>Gender</b>			0.215	0.643
Male / female	58 / 31	7 / 5		
<b>Cyst diameter (cm)</b>			11.090	<0.001
3-10 / >10	65 / 24	3 / 9		
<b>Incomplete aspiration of cyst fluid</b>			13.930	<0.001
Yes / no	12 / 77	7 / 5		
<b>Dislodged puncture needle</b>			8.818	0.003
Yes / no	9 / 80	5 / 7		
<b>Way of flushing</b>			0.331	0.565
Single flushing / repeated flushing	4 / 85	1 / 11		
<b>Smoking</b>			0.024	0.876
Yes / no	35 / 54	5 / 7		
<b>Drink alcohol</b>			2.793	0.095
Yes / no	8 / 81	3 / 9		
<b>Family history of disease</b>			0.298	0.585
Have / none	10 / 79	2 / 10		
<b>Post-sclerotic separation</b>			16.780	<0.001
Yes / no	22 / 67	10 / 2		

**Table 5.** Assignment.

Univariate	Assignment
Cyst diameter	3-10=0, >10=1
Incomplete aspiration of cyst fluid	No=0, Yes=1
Dislodged puncture needle	No=0, Yes=1
Post-sclerotic separation	No=0, Yes=1

**Table 6.** Multivariate analysis affecting prognosis and recurrence of RHC.

	$\beta$	SE	Wald $\chi^2$	P	OR	95%CI
<b>Cyst diameter</b>	0.984	0.235	10.429	0.000	4.263	2.064-8.426
<b>Incomplete aspiration of cyst fluid</b>	1.264	0.341	8.712	0.002	5.162	1.224-7.526
<b>Dislodged puncture needle</b>	1.062	2.642	3.356	0.087	2.067	1.124-5.097
<b>Post-sclerotic separation</b>	0.542	1.264	9.324	0.000	3.812	1.264-5.993

## DISCUSSION

Cysts are most common in congenital hepatic cysts and renal cysts, and surgery is usually the

treatment of choice for this disease<sup>(12)</sup>. However, due to the high invasiveness of traditional surgery, ultrasound interventional sclerosis is now mostly used in clinical practice to treat RHC<sup>(13)</sup>. The mechanism is mainly through a combination of ultrasound and percutaneous puncture placement drainage, which aspirates the contents of the cyst and induces sclerosis of the cyst wall under the inhibition of sclerosing agents<sup>(14)</sup>. Compared with traditional surgery, ultrasound-guided puncture sclerotherapy has higher safety and higher clinical application value<sup>(15)</sup>. Among them, the choice of sclerosing agent is the key to determine the effectiveness of sclerotherapy. And the present study has important reference significance for future clinics in selecting sclerosing agents for RHC by comparing the difference of effect between ET and PO.

In the present study, it was first seen that there was no difference in the one-time puncture success rate and operative time between both groups of patients, thanks to the role of ultrasound guidance for precise localization of the cyst. The clinical outcomes of the two groups were also more consistent, indicating that both ET and PO have excellent therapeutic effects. The stability of ultrasound-guided puncture sclerotherapy for RHC has also been verified several times in previous studies<sup>(16, 17)</sup>, which is also consistent with our findings. In the follow-up comparison, we found that the postoperative CRP and Cor levels were lower in the observation group than in the control group, suggesting that PO caused less traumatic stress injury to patients. ET, a traditional sclerosing agent in sclerotherapy, has been studied and found to induce coagulation of cyst wall epithelial cells after injection into cysts<sup>(18)</sup>. While, ET, as an industrial raw material, is less safe for application in humans and more traumatic for patients<sup>(19)</sup>. PO is one of the foam hardeners, which has higher adhesion, stability and compactness after foam. It can fully extrude the contents of the capsule wall and increase the contact area between the hardener and the capsule wall. It can not only improve the effectiveness of anesthesia, but also help to maintain compression, disrupt the secretory function of the cystic tissue, causing aseptic inflammation of the cystic wall and eventually forming dense fibrous strips, thus avoiding a traumatic stress response due to cyst compression of surrounding organs<sup>(20)</sup>.

We speculate that this is the main reason for the less severe postoperative traumatic stress reaction in the observation group. The amount of PO used is less compared to ET and has less impact on hepatic and renal function during injection. The use of PO also avoids the irritation of the vasculature of the capsule wall by repeated pumping and is therefore less taxing on the hepatic and renal function of patients<sup>(21)</sup>. This can also be illustrated by the fact that the postoperative ALT, AST, TBil, Scr, and BUN levels

were lower in the observation group than in the control group. At the same time, we saw a lower incidence of postoperative adverse effects in the observation group, which again supports that PO has fewer negative effects on patients and is more conducive to their postoperative recovery.

In the prognostic follow-up, there was no obvious difference in the recurrence rate of cysts between the two groups, which indicates that both treatments have stable therapeutic effects and are reliable for the prognosis of patients' health. Logistic regression analysis manifested that cyst diameter, incomplete cyst aspiration, and post-sclerotic segregation were all independent risk factors for cyst recurrence. The presumed reason for this is that the larger the diameter of the cyst and the more cystic fluid within the cyst, the more active it is. When ET is used as a sclerosing agent, its dose needs to be increased, resulting in alcohol toxicity reactions in some patients<sup>(22)</sup>. The dosage of PO sclerosing agent needs to be controlled according to the volume of the bursal fluid, and the active ingredient entering the bursa is limited, resulting in less contact area between the sclerosing agent and the bursal wall; part of the bursal wall collapsed due to bursal fluid withdrawal cannot contact the sclerosing agent, resulting in the continued secretion of its epithelial bursal fluid, leading to recurrence<sup>(23)</sup>.

While incomplete aspiration of the cyst fluid affects dilution by residual cyst fluid after sclerosing agent injection, resulting in incomplete cyst closure<sup>(24)</sup>. And larger cysts have more active internal fibrous tissue, and more fibrous hyperplasia can easily free into separations of different sizes, hindering cystic fluid extraction and leading to partial residual cystic fluid, as well as hindering the freeing of cystic fluid within the cyst and fluid accumulation leading to cyst recurrence<sup>(25)</sup>. In Hahn ST' study, the cyst diameter and incomplete aspiration of cystic fluid were similarly mentioned as factors associated with the recurrence of renal cysts<sup>(26)</sup>, which could corroborate the results of the current trial.

## CONCLUSION

Ultrasound-guided injection of PO and ET sclerotherapy has a better effect on RHC, but PO has less effect on stress response, hepatic and renal function, and has higher safety. So, it is recommended to be used first. Cyst diameter, incomplete aspiration of cystic fluid, and post-sclerotic segregation were independent factors affecting the prognosis and recurrence of RHC. In the future, the clinic needs to pay attention to the above-mentioned conditions for early intervention in the sclerotherapy of RHC patients, so as to provide a more reliable guarantee for their prognosis and recovery.

## ACKNOWLEDGEMENTS

*Not applicable.*

**Consent to Publish:** All authors gave final approval of the version to be published.

**Competing Interests:** The authors report no conflict of interest.

**Author contributions:** Hailan Lu conceived and designed the project, and wrote the paper. Lin Li generated the data and analyzed the data. Jie Luo modified the manuscript. All authors gave final approval of the version to be published, and agree to be accountable for all aspects of the work.

**Availability of data and materials:** The data that support the findings of this study are available from the corresponding author upon reasonable request.

**Funding:** Not applicable.

## REFERENCES

1. Abu-Wasel B, Walsh C, Keough V, Molinari M (2013) Pathophysiology epidemiology classification and treatment options for polycystic liver diseases. *World J Gastroenterol*, **19**(35): 5775-5786.
2. Bag ND, Mohakud S, Naik S, Shri A (2021) Recurrent giant simple hepatic cyst: an unusual cause of dyspnoea in an elderly man. *BMJ Case Rep*, **14**(2).
3. Carrim ZI and Murchison JT (2003) The prevalence of simple renal and hepatic cysts detected by spiral computed tomography. *Clin Radiol*, **58**(8): 626-629.
4. Cecere N, Hakem S, Demoulin N, et al. (2015) Weight loss in a patient with polycystic kidney disease: when liver cysts are no longer innocent bystanders. *Acta Clin Belg*, **70**(5): 369-371.
5. Cheng D, Amin P, Ha TV (2012) Percutaneous sclerotherapy of cystic lesions *Semin Intervent Radiol*, **29**(4): 295-300.
6. Cnossen WR and Drenth JP (2014) Polycystic liver disease: an overview of pathogenesis clinical manifestations and management. *Orphanet J Rare Dis*, **9**, 69.
7. Danza FM, Falcione M, Bordonaro V, et al. (2017) Minocycline hydrochloride as a soft sclerotizing agent for symptomatic simple renal and hepatic cysts *Eur Rev Med Pharmacol Sci*, **21**(2): 408-415.
8. Du C, Chai N, Linghu E, et al. (2022) Long-term outcomes of EUS-guided lauromacrogol ablation for the treatment of pancreatic cystic neoplasms: 5 years of experience. *Endosc Ultrasound*, **11**(1): 44-52.
9. El-Kader OA, Mohyelden K, Metwally AH, et al. (2014) Ethanola mine oleate vs absolute ethanol as sclerosing agents for treating symptomatic simple renal cysts. *Arab J Urol*, **12**(4): 294-298.
10. Fotiadis NI, Sabharwal T, Morales JP, et al. (2007) Combined percutaneous radiofrequency ablation and ethanol injection of renal tumours: midterm results. *Eur Urol*, **52**(3): 777-784.
11. Hahn ST, Han SY, Yun EH, et al. (2008) Recurrence after percutaneous ethanol ablation of simple hepatic renal and splenic cysts: is it true recurrence requiring an additional treatment? *Acta Radiol*, **49**(9): 982-986.
12. Halenka M (2013) Non-surgical management of thyroid abscess with ultrasound-guided fine-needle application of an antibiotic followed by sclerotization with absolute alcohol. *Minerva Endocrinol*, **38**(3): 281-287.
13. Lantinga MA, de Sevaux RGL, Gevers TJG, et al. (2018) Clinical predictors of escalating care in hepatic and renal cyst infection in autosomal dominant polycystic kidney and liver disease. *Neth J Med*, **76**(5): 226-234.
14. Lantinga MA, Drenth JP, Gevers TJ (2015) Diagnostic criteria in renal and hepatic cyst infection. *Nephrol Dial Transplant*, **30**(5): 744-751.
15. Lohela P (2002) Ultrasound-guided drainages and sclerotherapy. *Eur Radiol*, **12**(2): 288-295.
16. Masyuk TV, Masyuk AI, LaRusso NF (2018) Polycystic liver disease: The interplay of genes causative for hepatic and renal cystogenesis *Hepatology*, **67**(6): 2462-2464.

17. Michimoto K, Shimizu K, Kameoka Y, et al. (2016) Transcatheter arterial embolization with a mixture of absolute ethanol and iodized oil for poorly visualized endophytic renal masses prior to ct-guided percutaneous cryoablation. *Cardiovasc Intervent Radiol*, **39**(11): 1589-1594.
18. Neuville MF, Lovinfosse P, Jadoul A, et al. (2021) The use of a visual 4-point scoring scale improves the yield of (18)F-FDG PET-CT imaging in the diagnosis of renal and hepatic cyst infection in patients with autosomal dominant polycystic kidney disease. *Eur J Nucl Med Mol Imaging*, **48**(1): 254-259.
19. Palanivelu C, Rangarajan M, Senthilkumar R, Madankumar MV (2007) Laparoscopic management of symptomatic multiple hepatic cysts: a combination of deroofing and radical excision. *JSLs*, **11**(4): 466-469.
20. Sawada N, Endo T, Mikami K, et al. (2017) Kidney Injury due to ureteral obstruction caused by compression from infected simple hepatic cyst. *Case Rep Gastroenterol*, **11**(2): 312-319.
21. Sun WB, Yang B, Liu H, et al. (2004) Evaluation of absolute alcohol treatment for renal cyst with percutaneous puncture and catheterization under ultrasonographic guidance. *Zhonghua Wai Ke Za Zhi*, **42**(10): 590-592.
22. Suwabe T, Ubara Y, Higa Y, et al. (2009) Infected hepatic and renal cysts: differential impact on outcome in autosomal dominant polycystic kidney disease *Nephron Clin Pract*, **112**(3): c157-163.
23. Takebayashi S, Horikawa A, Arai M, et al. (2009) Transarterial ethanol ablation for sporadic and non-hemorrhaging angiomyolipoma in the kidney *Eur J Radiol*, **72**(1): 139-145.
24. Xu S, Rao M, Pu Y, et al. (2020) The efficacy of laparoscopic lauromacrogol sclerotherapy in the treatment of simple hepatic cysts located in posterior segments: a refined surgical approach *Ann Palliat Med*, **9**(5): 3462-3471.
25. Xue J and Geng X (2015) Curative effect of lauromacrogol and absolute ethyl alcohol injection guided by ultrasound on simplex hepatic cyst *Pak J Pharm Sci*, **28**(2): 697-700.
26. Yamamoto K, Sakaguchi H, Anai H, et al. (2005) Sclerotherapy for simple cysts with use of ethanolamine oleate: preliminary experience *Cardiovasc Intervent Radiol*, **28**(6): 751-755.

