

Application of intravoxel incoherent motion diffusion-weighted magnetic resonance imaging on the diagnosis of breast cancer

S. Chen^{1,2}, D. Wang³, P. Kong², H. Gu², Z. Yu^{1*}

¹Department of breast surgery, The Second Hospital of Shandong University, Jinan, Shandong, 250033, China

²Department of breast surgery, Shandong Provincial Qianfoshan Hospital, Jinan, Shandong, 250014, China

³Department of Medical Imaging, Shandong Provincial Qianfoshan Hospital, Jinan, Shandong, 250033, China

► Original article

*Corresponding author:

Zhigang Yu, M.D.,

E-mail: yuzhigang@sdu.edu.cn

Received: March 2023

Final revised: June 2023

Accepted: July 2023

Int. J. Radiat. Res., October 2023;
21(4): 827-832

DOI: 10.52547/ijrr.21.4.31

Keywords: Breast cancer, magnetic resonance imaging, intravoxel incoherent motion, histological grading, diffusion-weighted imaging.

ABSTRACT

Background: To explore the application of intravoxel incoherent motion (IVIM) parameters based on mono- and bi-exponential models for diagnosing breast cancer (BC). **Materials and Methods:** 43 patients underwent breast magnetic resonance (MR) scanned before operation and the images were transferred to AW Volume Share 5 post-processing workstation. The mono-exponential and bi-exponential model was used to measure the slow diffusion coefficient (DC) (D), fast DC (D*) and fraction of perfusion (f). And the association between different parameter values and BC grading was analyzed via Spearman's rank correlation coefficient. **Results:** The D mono value of 13 patients with benign breast diseases was higher than that of 30 patients with BC (4.04 ± 0.23 vs 2.59 ± 0.64 , $p < 0.05$) while there was no statistical significance on the value of D* mono, f mono, D bi, D* bi and f bi. Additionally, the parameter differences of D mono, D* mono, D bi and D* bi had statistical significance between the different BC grades. And the grades of BC had a negative correlation with D mono and D bi while were positively related to D* mono and D* bi. It was most closely related to D* bi than D bi. D mono value in ER-positive were higher than that in ER-negative group (3.09 ± 0.37 vs 1.03 ± 0.09 , $p = .0095$). **Conclusion:** IVIM could be used to diagnose BC, predict histological grading and ER expression and provide valuable imaging for the clinical treatment and prognosis of BC patients.

INTRODUCTION

Breast cancer (BC) is the most common malignant tumor in women around the world⁽¹⁾. In China, BC is one of the primary malignancies⁽²⁾. According to statistics, the number of China's female's BC, each year is 169000, which is the second most common female malignancy. Each year about 4,5000 women die from BC, which is the most common malignancy of females' sixth cause of death⁽³⁾. BC is one of the important factors which harm female health and the recent incidence of BC is the overall rise, so it is particularly important to evaluate the diagnosis of BC. And the diagnosis is closely related to the histological grade, some scholars found that the 5-year survival rate of the histological grade I, II and III in BC was 84.2%, 70.2% and 51.9%, and there are significant differences between those^(4,5).

With constant innovation and development in magnetic resonance (MR) technology, more and more advanced technology can be applied to the diagnosis and evaluation of BC^(6,7). Intravoxel incoherent motion (IVIM) is one of them, and in recent years, more and more of them was widely used in clinical⁽⁸⁾. A recent study revealed that IVIM imaging played a

critical role in subtyping of BC⁽⁹⁾. Studies have shown that apparent diffusion coefficient (ADCs) in both normal and benign tissues have ADCs higher than malignant lesions^(10,11). In 1986, Le Bihan et al first proposed the IVIM which is based on diffusion-weighted imaging (DWI), in biological tissue^(12,13). IVIM phenomena include two factors which are pure water molecular diffusion movement and blood perfusion⁽¹⁴⁾. IVIM not only can provide quantitative parameters of pure water molecular diffusion movement in organizations, but also can reflect the condition of the tissue's perfusion, which can truly reflect the water molecules diffusion movement, including the following parameters: pure diffusion coefficient (D), the pseudo-diffusion coefficient (D*) and the perfusion fraction (f)^(15,16).

In summary, the study focused on analysis of the relationship between different parameter values of IVIM imaging based on mono-exponential and bi-exponential models and the grading of BC. And we found that the value of D-mono of benign breast diseases was higher than that of BC, and there was statistical significance between the different grades, and between subtyping of ER in BC.

MATERIALS AND METHODS

Patients

Forty-three patients were selected in Qianfoshan Hospital of Shandong Province from October 2014 to January 2016. They were female, the age ranged from 31 to 68 years. All of the patients did the MR examination before operation and all of them did the surgical treatment in a week, and all of them without any treatment before examination. The study was approved by the institutional ethical committee and all the patients signed informed consent.

Data

MR images using 3.0 T superconducting magnetic resonance equipment (Discovery MR750, GE Healthcare, USA), it is a dedicated eight-channel bilateral breast phase control coil, with the patient prone, their bilateral breast naturally hanging in the coil. Each research object is scanned in the axial T1WI, T2WI, and IVIM sequence. Scan parameters of each sequence: the axial fast spin echo T1WI (repetition time (TR) 632 ms, echo time (TE) 8.9 ms, field of view (FOV) 36 × 36 cm, matrix 320 × 192, slice thickness 6 mm, slice gap 1 mm, number of excitation (NEX) 2); the fast spin echo of axial water lipid T2WI (TR 2907 ms, TE 52.8 ms, FOV 36 × 36 cm, matrix 320 × 192, slice thickness 6 mm, slice gap 1 mm, NEX 1); multi b value of DWI using a single shot spin echo sequence (TR 3000 ms, TE 56.3 ms, FOV 36 × 36 cm, matrix 128 × 96, slice thickness 6 mm, slice gap 1 mm, b value respectively 0, 20, 50, 100, 150, 200, 400, 800, 1000, 1200, 1500 s/mm², NEX respectively 1, 2, 2, 2, 2, 1, 2, 4, 4, 6).

Data analysis

The original image obtained by scanning will be sent to AW Volume Share 5 post-processing workstation (GE Healthcare, USA), two physicians have five years of experience in imaging diagnosis to analyze and measure images using Functool 9.4.05 software (GE Healthcare, USA), combining with T1WI, T2WI and IVIM image, selecting the maximum level of lesion, placing the region of interest (ROI) in the lesion site, avoiding the hemorrhage and necrosis, then calculating the slow diffusion coefficient slow ADC mono values, rapid diffusion coefficient fast ADC mono values and filling fraction f mono values using single exponential model; calculating the slow diffusion coefficient slow ADC bi values, fast diffusion coefficient fast ADC bi values, scores of infusion f bi values by using double exponential model. Measuring 3 times and selecting the average, recording the lesion's ADC mono values, fast ADC mono values, f mono values, slow ADC bi values, fast ADC bi values and f bi values.

Grading of BC

Using the classification method improved by

Elston and Ellis, put forward by Bloom and Richardson, according to the following 3 indicators: formation of the gland duct, nuclear pleomorphism, nuclear division phase to score: (1) the formation of the gland tube >75% is 1 score, 10% ~ 75% is 2 scores, and < 10% is 3 scores; (2) nuclear pleomorphism: tumor tissue compared with tumor surrounding normal breast tissue, the tumor cells which are small and rule is 1 score, the tumor cells which are medium size and moderate atypia is 2 scores, the tumor cells which are large and obvious atypia is 3 scores; (3) the nuclear division phase count: in the cell growth active region, count every 10 HPF nuclear division 0 ~ 5 is 1 score, 6 ~ 10 is 2 scores, 11 is 3 scores. Adams 3 items above, total scores 3 ~ 5 is I level, low grade; 6 ~ 7 is II level, moderate grade; 8 ~ 9 is III level, high grade.

Statistical analysis

SPSS17.0 software (IBM, China) was executed. Regarding the grade I, II, III of BC respectively as the group 1, 2, 3, and then the D mono value, D* mono value, f mono value, D bi value, D* bi value and the f bi value respectively calculated by single index model and double exponential model will be processed by One-Way Analysis of variance (ANOVA). Then meaningful parameters will be counted by Spearman rank correlation, analysis of the relationship between the histological grading of BC and the different parameters. $P < 0.05$ indicated significance.

RESULTS

Comparison of IVIM parameters between benign and malignant breast tumors

Among the 46 patients, 33 patients with BC were confirmed by pathology; 6 patients had benign hyperplasia of mammary gland, 4 patients had introduction papilloma, and 3 patients had introduction carcinoma.

Patients with breast hyperplasia and intraductal papillomatosis were assigned to the benign breast disease group. The D mono value of benign breast diseases is higher than that of BC (4.04 ± 0.23 vs 2.59 ± 0.64 , $P < 0.05$), while the D* mono value, f mono, D bi value, D* bi value and f bi value had no statistically significant difference between the benign breast diseases and BC (table 1).

Table 1. Comparison of IVIM parameters between benign and malignant breast tumors.

Parameters	Benign	Malignant	P
D mono ($\times 10^{-3}$ mm ² /s)	4.04±0.23	2.59±0.64	<0.05
D* mono ($\times 10^{-3}$ mm ² /s)	2.63±0.12	11.98±4.15	>0.05
f mono (%)	25.21±2.64	27.33±7.45	>0.05
D bi ($\times 10^{-3}$ mm ² /s)	0.65 ±0.11	0.53±0.17	>0.05
D* bi ($\times 10^{-3}$ mm ² /s)	33.89±5.23	63.49±17.83	>0.05
f bi (%)	36.67±7.78	31.56±8.23	>0.05

Relationship between IVIM parameters and histological grading of BC

The 33 cases of invasive carcinoma were confirmed by surgery pathology, among them, BC I level has 8 cases, II level has 15 cases, III level has 10 cases; Compared between histologic grade of BC I, II, III level, the D mono value, D* mono value, D bi value respectively measured by single index model and double index model have significant difference with bi groups, while there was no statistically significant difference between the f mono value and the f bi group. $P < 0.05$ means the difference has statistical significance. The histological grade of BC has a negative correlation with the D mono value measured by single index model, the correlation coefficient $r = 0.930 > 0.9$, appears significant negative correlation, $P < 0.001$, difference have significance; has negative correlation with the D bi value measured by double index model, correlation coefficient $r = 0.967 > 0.9$, appears significant negative correlation, $P < 0.001$, difference has significance. Histological grade of BC has a positive correlation with the D*mono value measured by single index model, the correlation

coefficient $r = 0.938 > 0.9$, appears significant positive correlation, $P < 0.001$, difference has significance; has a negative correlation with the D* bi value measured by double index model, correlation coefficient $r = 0.978 > 0.9$, appears significant positive correlation; $P < 0.001$, difference has significance (table 2).

Relationship between IVIM parameters and immunohistochemical markers of BC

Thirty-three patients, with single lesion, were pathologically confirmed as invasive ductal carcinoma. Among them, the estrogen receptor (ER) positive, progesterone receptor (PR) positive and human epidermal growth factor receptor 2 (HER-2) positive patients were 26, 18 and 6, respectively. The D-mono value in ER-positive was higher than that in ER-negative group (3.09 ± 0.37 vs 1.03 ± 0.09 , $P = 0.0095$). No difference in D* mono, f mono, D bi, D*bi and f-bi between ER positive and negative patients was found. IVIM parameters had no significant correlation with the expression of PR and HER-2 (table 3).

Table 2. IVIM parameters be processed by using single factor analysis of variance method.

Parameters	Histologic grade of breast cancer			P
	I	II	III	
D mono($\times 10^{-3}$ mm ² /s)	4.27±0.42	2.31±0.3	00.92±0.17	0.000
D* mono($\times 10^{-3}$ mm ² /s)	1.03±0.12	9.24±1.25	23.57±1.01	0.000
f mono(%)	23.96±6.25	29.20±7.09	30.59±8.67	0.160
D bi($\times 10^{-3}$ mm ² /s)	1.22±0.10	0.71±0.14	0.31±0.14	0.000
D* bi($\times 10^{-3}$ mm ² /s)	7.06±0.71	36.93±1.07	139.27±7.95	0.000
f bi(%)	28.54±7.27	34.06±4.96	36.20±8.30	0.061

Abbreviation: f, perfusion fraction; D, pure diffusion coefficient, D*, pure diffusion coefficient. $P < 0.05$ was deemed statistically significant.

Table 3. Relationship between IVIM parameters and immunohistochemical markers of breast cancer.

		n	D-mono	P	D*-mono	P	f-mono	P	D-bi	P	D*-bi	P	f-bi	P
ER	Positive	26	3.09±0.37	0.0095	10.07±3.36	0.467	30.54±3.16	0.261	0.80±0.11	0.542	37.89±14.19	0.067	35.14±2.96	0.250
	Negative	7	1.03±0.09		14.91±5.26		23.00±6.01		0.64±0.29		100.1±32.33		27.81±5.86	
PR	Positive	18	2.54±0.62	0.985	11.67±4.34	0.687	29.87±3.76	0.621	0.79±0.16	0.696	60.95±24.37	0.687	34.73±2.59	0.551
	Negative	15	2.52±0.53		9.36±3.55		26.81±4.75		0.71±0.17		47.54±19.61		31.24±5.39	
Her-2	Positive	6	3.02±0.80	0.376	8.47±5.25	0.338	33.78±6.33	0.279	0.51±0.12	0.185	72.15±36.86	0.424	37.18±1.65	0.392
	Negative	27	2.26±0.43		14.34±3.16		26.50±3.12		0.85±0.13		44.96±13.63		31.63±3.62	

Abbreviation: f, perfusion fraction; D, pure diffusion coefficient, D*, pure diffusion coefficient; ER, estrogen receptor, PR, progesterone receptor; HER-2, Human epidermal growth factor receptor 2. $P < 0.05$ was deemed statistically significant.

DISCUSSION

In recent years, the morbidity of BC has become the highest in all kinds of cancer in our country's women as well as a fledgling trend. So far, the latest figures published by the National Cancer Registry of China reported the number of BC in China has reached 249 thousand, and the number in the urban area is relatively more. BC has been the most common disease among the women who resided in the cities in China, with the disease incidence being about 46.74/100 thousand. According to the figures released by the National Cancer Registry, in a decade, the incidence has been a general uptrend both in the cities and countryside. Especially in the countryside,

the incidence of BC has risen far more than in cities, owing to its low levels in the village⁽¹⁷⁾. As a result, the treatment effects and prognosis of BC would be a significant topic among clinicians. The assessment of BC's therapeutic effects and prognosis before the treatment is an urgent demand of both doctors and patients. In this study, IVIM-DWI combined with single index and double index, to the preoperative grading of BC. And the results revealed that there was a statistical significance of the difference between parameters including D mono, D* mono, D bi and D* bi and BC grades, and D mono value was found to be higher in ER-positive than ER-negative group.

Histopathological classification of BC is considered to be an important factor influencing the

treatment effect and prognosis of BC. If the histological grade is higher, the early treatment is easier to be fair and the overall survival rate is lower and the prognosis is worse. Bloom and Richardson founded the comprehensive classification method in 1959, which adopted three parameters to grade. Classification has a clear relationship with 5, 10 and 15 years of survival rate⁽¹⁸⁾. Several studies have shown that invasive ductal carcinoma with high grade or poor differentiation has obviously higher rate of lymph node metastasis, recurrence and mortality than those with low grade or rich differentiation^(19, 20). Some scholars even believed that without considering the clinical classification, histological grading had a significant impact on the mortality and survival length of the patients^(21, 22). Histological grading can do a biopsy, but the pathological examination is invasion for the invasive carcinoma, the highest incidence group in BC. Hence, noninvasive examination by imaging has always been

the aim of the medical profession. With the improvement of magnetic resonance equipment and the post-processing software, MRI techniques have been developed to the direction of equal emphasis on form and function. The morphological and functional parameters provided by MRI can reflect the biology prognosis of the carcinoma to some extent. At present, breast's MRI examination has been widely used in clinical. The magnetic resonance DWI can technology and irrelevant movement within the voxel imaging (IVIM) technology has attracted more and more attention in recent year^(23, 24). Traditional DWI can detect the diffusion of the water molecules in organization through ADC, and the mathematical model is the single index model:

$$S(b) = S_0 \cdot \exp(-b \times \text{ADC})$$

Where; $S(b)$, diffusion-weighted signal strength; S_0 , not applying diffusion gradient signal strength; b , diffusion sensitive factor. Usually being used for data processing of double b value ($b = 0$ and others).

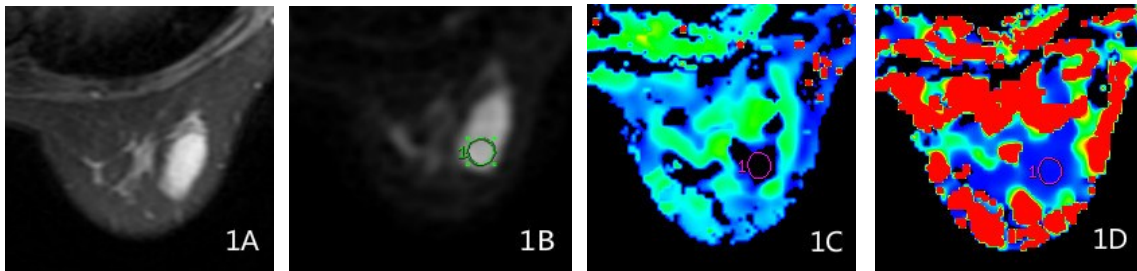


Figure 1. The images of MRI scanning for patients with grade I breast cancer. Thirty-eight years old female patients with right breast invasive cancer at grade I. **(1A)** T2WI sequence of fat suppression. **(1B)** The corresponding gray-scale image when selecting ROI. **(1C, 1D)** The IVIM parameters of this patient: $D\text{-mono} = 0.00423$; $D^*\text{-mono} = 0.00105$; $f\text{-mono} = 0.26335$; $D\text{-bi} = 0.00121$; $D^*\text{-bi} = 0.00711$; $f\text{-bi} = 0.27714$. f , perfusion fraction; D , pure diffusion coefficient, D^* , pure diffusion coefficient.

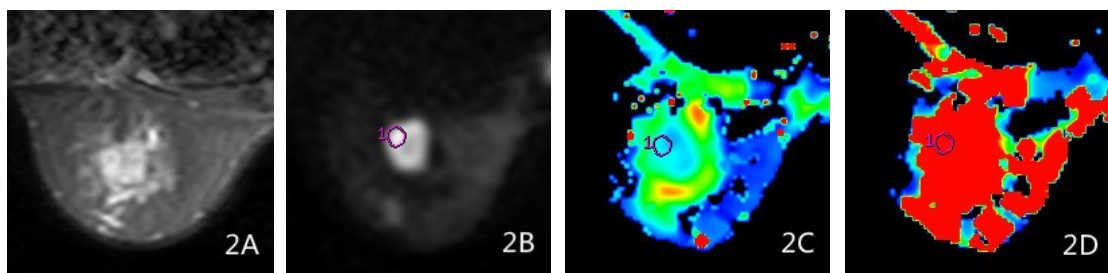


Figure 2. The images of MRI scanning for patients with grade II breast cancer. Fifty-two years old female patients with left breast invasive cancer at grade II. **(2A)** T2WI sequence of fat suppression. **(2B)** The corresponding gray-scale image when selecting ROI. **(2C, 2D)** The IVIM parameters of this patient: $D\text{-mono} = 0.00231$; $D^*\text{-mono} = 0.00921$; $f\text{-mono} = 0.30531$; $D\text{-bi} = 0.00071$; $D^*\text{-bi} = 0.03691$; $f\text{-bi} = 0.33916$.

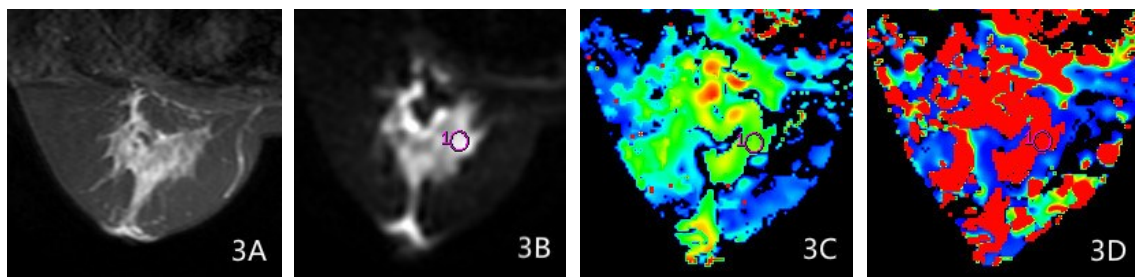


Figure 3. The images of MRI scanning for patients with grade III breast cancer. Forty-two years old female patients with left breast invasive cancer at grade III. **(3A)** T2WI sequence of fat suppression. **(3B)** The corresponding gray-scale image when selecting ROI. **(3C, 3D)** The IVIM parameters of this patient: $D\text{-mono} = 0.00092$; $D^*\text{-mono} = 0.02355$; $f\text{-mono} = 0.30889$; $D\text{-bi} = 0.00028$; $D^*\text{-bi} = 0.13884$; $f\text{-bi} = 0.32264$.

The single index model of traditional DWI is different from the single index model of traditional IVIM in our present study. The single index model in our study is referred to as the single index model which is used for post-processing of IVIM data. In the software of Functool, when using a single exponential model, data which is collected by IVIM are divided into high-value b and low-value b two parts, and the high-value part b ($200 \text{ s/b} > \text{mm squared}$) is used to fit the slow spread of ADC, while the low-value b part is simply used to fit the rapid spread of ADC.

For biological tissue, the movement of water molecules mainly has two aspects: one is the diffusion of water molecule movement, namely the Brownian motion and it is related to the organization's physical characteristics, which can be used to describe the organization's features; the other is microcirculation in the capillary network, namely perfusion. In terms of the voxel level, when applying the diffusion-sensitive gradient, perfusion can also cause voxel proton group phase within the irrelevant due to the capillary network of pseudo-random distribution of organs, which can cause ADC values on the high side ^(25, 26). If there is only the diffusion of water molecules in voxel, the measured ADC values should be the same as the diffusion coefficient D values. However, the measured IVIM/ADC values in the body often tend to be higher, owing to ADC value having both water molecular diffusion and the composition of blood perfusion. IVIM can be used to quantify the two kinds of motion components in DWI imaging.

In 1986, Le Bihan et al defined the concept of the IVIM firstly, which can be used to quantify how b value of DWI imaging to quantitatively analyze the movement of the water molecules diffusion and microcirculation perfusion through analysis multi b value DWI imaging by applying IVIM model ⁽¹²⁾. The mathematical model for the double exponential model:

$$S(b)/S_0 = (1-f) \cdot \exp(-b \cdot D) + f \cdot \exp[-b(D+D^*)].$$

S (b), the diffusion-weighted signal strength; S₀, not applying diffusion gradient signal strength; B, diffusion sensitive factor; F, filling fraction (perfusion fraction), on behalf of the voxel in microcirculation perfusion diffusion effect overall diffusion effect of volume rate; D*, pseudo-diffusion coefficient and it is on behalf of diffusion motion related to microcirculation perfusion in voxel, also called perfusion related diffusion or fast pool diffusion; D, slow diffusion coefficient, which is on behalf of just water molecular diffusion in voxel, also called slow pool diffusion.

IVIM double exponential model can be used to analyze multi b value of DWI, then we can get perfusion parameters and related parameters (f, D*) and diffusion (D), which can quantify the two kinds of motion components in DWI images.

At present, IVIM-DWI sequence, based on this

theory, has obtained good application in mammary gland disease, but the study is rarely reported in the literature for IVIM-DWI combined with single index and double index, to the preoperative grading of invasive BC. We aimed to discuss if the D mono value, D* mono value, f mono value, D bi value, D* bi value and the f bi value respectively measured by IVIM-DWI combined with single and double index models are related to the classification of invasive BC.

If the degree of malignancy of BC is higher, the cell proliferation is more strongly, the cell density is higher, the extracellular volume will be less, the more immature tumor vessels. As a result, MRI image signal has changed and the parameter value of IVIM sequence has been different ^(27, 28). In this study, with the increase of breast malignant degree, D mono value and D bi value have been smaller and smaller and negative correlation, while the D * mono value and D* bi value have been a more and more and positive correlation, which is consistent with the Costantini etc 's conclusion that the ADC is related to the grading of tumor and the cell structure ⁽²⁹⁾. Han Shuai etc. found that D* value and D value are different in the degree of differentiation of rectal cancer, indicating D* value and D values all contribute to preoperatively evaluating the malignant degree of rectal cancer. Further analysis found that D value in IVIM can be more objective and more accurate to assess the water molecular diffusion of tumor tissue and more helpful to assess the malignant degree of rectal cancer before operation, compared with the traditional ADC values; we can preliminary considered that the lower the IVIM parameter D is, the higher the rectal cancer malignant degree is, the worse the patient's prognosis is. The results show that BC also conforms to this law. This study found that D mono value and D bi value respectively measured by IVIM single and double index model were negatively correlated with tumor grade, consistent with the above findings. Its correlation coefficient was $r = -0.930$ and $r = -0.967$ which was analyzed by the Spearman rank correlation. And according to it, the correlation is greatly improved compared with the ADC value measured by the traditional DWI. Therefore, the measured D value, excluding the effect of tissue microcirculation perfusion, can be better than the traditional ADC values to identify the malignant degree of BC, which also provides a more reliable imaging diagnostic method for the classification of BC's malignant degree. Furthermore, this study demonstrated that the D-mono value in the subtype of ER-positive was higher than ER-negative group but there was no difference in other parameters between ER-positive and negative patients, and IVIM parameters had no significant correlation with the expression of PR and HER-2. This finding was similar to the previous reports⁽³⁰⁾. However, this research also has some shortcomings. For example, the sample

size studied is a little small, especially the cases of I and III are relatively small, so the results of this study have some deviation. Hence, we need to continue to enlarge the sample size, and in this way, we can further figure out the correlation between IVIM parameters and BC grading.

In conclusion, this present study revealed that there was statistical significance between different grading or ER subtyping of BC and IVIM parameters based on single index and double index. IVIM-MRI techniques do not need to contrast medium and are easy to operate. Therefore, the IVIM-MRI technology could be more widely used in the field of BC grading and subtyping, providing more reliable image data.

ACKNOWLEDGMENT

The examinations and diagnoses reported in this study were completed by the Department of breast surgery and the Department of Medical Imaging of Shandong Provincial Qianfoshan Hospital. We thank our all colleagues for contributing to this article.

Author contribution: Zhigang Yu and Shouhua Chen conceived and designed the study. Shouhua Chen, Dawei Wang, Peng Kong collected and analyzed the data. He Gu was responsible for data processing and statistical analysis. Shouhua Chen and Dawei Wang wrote the first draft of the manuscript. Shouhua Chen and Zhigang Yu revised the manuscript.

Funding: There is no funding support for this study.

Data Availability: The simulation experiment data used to support the findings of this study are available from the corresponding author upon request.

Conflicts of Interest: The authors declare that there are no conflicts of interest regarding the publication of this paper.

Ethical consideration: The study was obtained from the approval of the ethical committee of Qianfoshan Hospital of Shandong Province.

REFERENCES

1. Trapani D, Ginsburg O, Fadelu T, et al. (2022) Global challenges and policy solutions in breast cancer control. *Cancer Treat Rev*, **104**:102339.
2. Fan L, Strasser-Weippl K, Li JJ, et al. (2014) Breast cancer in China. *Lancet Oncol*, **15**(7):e279-89.
3. Eshaghi M (2020) The effect of pain management on pain reduction in women with breast cancer. *SRPH Journal of Medical Sciences*, **2**(2):1-5.
4. Zhang M, Peng P, Gu K, et al. (2018) Time-varying effects of prognostic factors associated with long-term survival in breast cancer. *Endocr Relat Cancer*, **25**(5): 509-21.
5. Cang B, Zhou W, Cai L (2011) Analysis of survival related factors in 174 breast cancer. *Practical Oncology Journal*, **25**(4): 3.
6. Tagliafico AS, Piana M, Schenone D, et al. (2020) Overview of radiomics in breast cancer diagnosis and prognostication. *Breast*, **49**: 74-80.
7. Fowler AM and Strigel RM (2022) Clinical advances in PET-MRI for breast cancer. *Lancet Oncol*, **23**(1): e32-e43.
8. Liang J, Zeng S, Li Z, et al. (2020) Intravoxel incoherent motion diffusion-weighted imaging for quantitative differentiation of breast tumors: A meta-analysis. *Front Oncol*, **10**: 585486.
9. Uslu H, Onal T, Tosun M, et al. (2021) Intravoxel incoherent motion magnetic resonance imaging for breast cancer: A comparison with molecular subtypes and histological grades. *Magn Reson Imaging*, **78**: 35-41.
10. Guo Y, Cai YQ, Cai ZL, et al. (2002) Differentiation of clinically benign and malignant breast lesions using diffusion-weighted imaging. *J Magn Reson Imaging*, **16**(2): 172-8.
11. Sinha S, Lucas-Quesada FA, Sinha U, et al. (2002) In-vivo diffusion-weighted MRI of the breast: potential for lesion characterization. *J Magn Reson Imaging*, **15**(6): 693-704.
12. Le Bihan D, Breton E, Lallemand D, et al. (1988) Separation of diffusion and perfusion in intravoxel incoherent motion MR imaging. *Radiology*, **168**(2): 497-505.
13. Le Bihan D and Turner R. (1992) The capillary network: a link between IVIM and classical perfusion. *Magn Reson Med*, **27**(1): 171-8.
14. De Robertis R, Tinazzi Martini P, Demozzi E, et al. (2015) Diffusion-weighted imaging of pancreatic cancer. *World J Radiol*, **7**(10): 319-28.
15. Fang S, Yang Y, Chen B, et al. (2022) DWI and IVIM Imaging in a Murine Model of Rhabdomyosarcoma: Correlations with Quantitative Histopathologic Features. *J Magn Reson Imaging*, **55**(1): 225-33.
16. Zhang Y, Luo D, Guo W, et al. (2023) Utility of mono-exponential, bi-exponential, and stretched exponential signal models of intravoxel incoherent motion (IVIM) to predict prognosis and survival risk in laryngeal and hypopharyngeal squamous cell carcinoma (LHSCC) patients after chemoradiotherapy. *Jpn J Radiol*, **41**: 712-722.
17. Chen W and Zheng R (2015) Incidence, mortality and survival analysis of breast cancer in China. *Chinese Journal of Clinical Oncology*, **24**: 668-674.
18. Bloom HJ and Richardson WW (1957) Histological grading and prognosis in breast cancer; a study of 1409 cases of which 359 have been followed for 15 years. *Br J Cancer*, **11**(3): 359-77.
19. Parham DM (1995) Mitotic activity and histological grading of breast cancer. *Pathol Annu*, **30**(Pt 1):189-207.
20. Carter D. Interpretation of Breast Biopsies. 4th Edition, 2002, Lippincott Williams & Wilkins, USA.
21. Le Doussal V, Tubiana-Hulin M, Friedman S, et al. (1989) Prognostic value of histologic grade nuclear components of Scarff-Bloom-Richardson (SBR). An improved score modification based on a multivariate analysis of 1262 invasive ductal breast carcinomas. *Cancer*, **64**(9): 1914-21.
22. Elston CW (1995) Pathology of the breast. *The Breast*, **4**(1): 74-5.
23. Aberle DR, Chiles C, Gatsonis C, et al. (2005) Imaging and cancer: research strategy of the American College of Radiology Imaging Network. *Radiology*, **235**(3): 741-51.
24. Leung JW (2005) Screening mammography reduces morbidity of breast cancer treatment. *AJR Am J Roentgenol*, **184**(5): 1508-9.
25. Hopton DS, Thorogood J, Clayden AD, MacKinnon D (1989) Histological grading of breast cancer; significance of grade on recurrence and mortality. *Eur J Surg Oncol*, **15**(1): 25-31.
26. Freedman LS, Edwards DN, McConnell EM, Downham DY (1979) Histological grade and other prognostic factors in relation to survival of patients with breast cancer. *Br J Cancer*, **40**(1): 44-55.
27. Peters NH, Borel Rinkes IH, Zuithoff NP, et al. (2008) Meta-analysis of MR imaging in the diagnosis of breast lesions. *Radiology*, **246**(1): 116-24.
28. Jones EF, Sinha SP, Newitt DC, et al. (2013) MRI enhancement in stromal tissue surrounding breast tumors: association with recurrence free survival following neoadjuvant chemotherapy. *PLoS One*, **8**(5): e61969.
29. Costantini M, Belli P, Rinaldi P, et al. (2010) Diffusion-weighted imaging in breast cancer: relationship between apparent diffusion coefficient and tumour aggressiveness. *Clin Radiol*, **65**(12): 1005-12.
30. Qin Y, Wu F, Hu Q, et al. (2023) Histogram analysis of multi-model high-resolution diffusion-weighted MRI in breast cancer: correlations with molecular prognostic factors and subtypes. *Front Oncol*, **13**: 1139189.