

High-dose-rate mold brachytherapy for mandibular gingival squamous cell carcinoma in outpatient setting – Initial case report

A. Takeshita¹, H. Shimamoto^{1,2*}, Y. Uchimoto¹, T. Tsujimoto¹, T. Miyamoto³, S. Kreiborg^{4,5}, S.M. Mallya⁶, M. Oda⁷, T. Hirata², K. Ogawa²; H. Shiomi^{1,2}, S. Murakami^{1,2}

¹Department of Oral and Maxillofacial Radiology, Osaka University Graduate School of Dentistry, 1-8 Yamadaoka, Suita, Osaka 565-0871, Japan

²Department of Radiation Oncology, Osaka University Graduate School of Medicine, 2-2 Yamadaoka, Suita, Osaka 565-0871, Japan

³Dental Laboratory, Osaka University Dental Hospital, 1-8 Yamadaoka, Suita, Osaka 565-0871, Japan

⁴Department of Pediatric Dentistry and Clinical Genetics, School of Dentistry, Faculty of Health and Medical Sciences, University of Copenhagen, Nørre Allé 20, DK-2200, Copenhagen, Denmark

⁵3D Craniofacial Image Research Laboratory (School of Dentistry, University of Copenhagen; Centre of Head and Orthopedics, Copenhagen University Hospital Rigshospitalet; and Department of Applied Mathematics and Computer Science, Technical University of Denmark), Nørre Allé 20, DK-2200, Copenhagen, Denmark

⁶Section of Oral and Maxillofacial Radiology, UCLA School of Dentistry, 10833 Le Conte Ave., Los Angeles, CA 90095-1668, USA

⁷Department of Medical Technology, Osaka University Hospital, 2-15 Yamadaoka, Suita, Osaka 565-0871, Japan

► Case report

*Corresponding author:

Hiroaki Shimamoto D.D.S., Ph.D.,

E-mail:

shimamoto.hiroaki.dent@osaka-u.ac.jp

Received: November 2022

Final revised: April 2023

Accepted: May 2023

Int. J. Radiat. Res., October 2023;
21(4): 849-853

DOI: 10.52547/ijrr.21.4.36

Keywords: *Gingival cancer, radiation therapy, mold brachytherapy, outpatient.*

ABSTRACT

Brachytherapy is often used to treat oral cancer, as it generally yields a good outcome with little oral function loss. In particular, mold brachytherapy is ideally suited for superficial oral cases, such as cancers developing on the gingiva, palate, or buccal mucosa, with little to no bone involvement and thin tissue thickness. Mold brachytherapy including that at a high-dose-rate (HDR) is used to treat gingival cancer, though hospitalization is the typical treatment setting. Reported here are details of HDR mold brachytherapy performed in an outpatient setting for a mandibular gingival case of squamous cell carcinoma (SCC). Mandibular gingival SCC in a 71-year-old man was treated as an outpatient using HDR mold brachytherapy (54 Gy in 9 fractions, 5 days). After receiving mold treatment for thirty months, there was no sign of recurrence or metastasis. To our knowledge, this is the first report of HDR mold brachytherapy in an outpatient setting for treating mandibular gingival cancer.

INTRODUCTION

Brachytherapy is often used to treat oral cancer, as it generally yields a good outcome with minimal loss of oral function⁽¹⁻⁶⁾. The methods available are classified as interstitial, intracavity and mold brachytherapy, with the latter's main benefit is that it is a non-invasive process⁽¹⁻⁸⁾. However, the need for personalized molds for individual patients as well as a narrow range of applications limit the use of mold brachytherapy^(2, 4, 5, 9-11). Nevertheless, for cancer arising in the oral cavity, such as in the gingiva, palate, floor of the mouth, lips, or buccal mucosa, this method is well suited because of the thinness of the tissue treated with irradiation⁽¹⁻¹³⁾.

Mold brachytherapy whether high-dose-rate (HDR) or low-dose-rate (LDR) technique, requires use of a shielded room during treatment and it is generally performed in a hospital setting. A few case reports have documented use of mold brachytherapy for treating gingival cancer during hospitalization with a HDR technique^(1, 4, 6, 9, 11, 12). Although HDR mold brachytherapy in an outpatient setting has been suggested as an approach for treating superficial oral cancer^(2, 4, 6, 11), few cases with actual application to the maxillary gingiva have been reported^(8, 10, 13). Moreover, there are no known reports of HDR mold brachytherapy performed on an outpatient basis for mandibular gingival cancer. Presented here is the first known mandibular gingival case of squamous

cell carcinoma (SCC) successfully managed with HDR mold brachytherapy in an outpatient setting period.

Case presentation

A 71-year-old man who complained of pain in the left mandibular gingiva visited our hospital. There were no known comorbidities, though the patient had been diagnosed with serious anxiety disorder, leading to refusal to undergo surgery, chemotherapy, and hospitalization. An ulcerated mobile mass was noted on the lower left gingiva, extending to the retromolar trigone, which was measured at approximately 24×12 mm (figure 1). The surface mucosa had an irregular appearance with some ulceration noted. Computed tomography (CT) (Aquilion ONE; Canon Medical Systems, Japan) findings showed a 3-mm thick mass with no evidence of bone destruction (figure 2). Clinically, there was no evidence of cervical lymphadenopathy, while ultrasound (Aplio XG; Canon Medical Systems, Japan), CT, magnetic resonance imaging (Signa HDxt 1.5T; GE Healthcare, USA), and positron emission tomography-CT (Discovery ST Elite; GE Healthcare, USA) revealed no metastasis in the cervical lymph nodes or distant metastasis. The patient was diagnosed with squamous cell carcinoma (SCC), cT2N0M0, Stage II, based on the findings of the biopsy and imaging results. Since the lesion was localized inside the mucosa, HDR mold brachytherapy was performed in an outpatient setting.

A plaster model (New Plastone LE; GC Co., Japan) of the mandible including the lesion was made using an alginate impression (Aroma Fine Plus; GC Co., Japan) (figure 3). Three flexible catheters (ProGuide Sharp Needle 6F x240 mm; Nucletron B.V., Netherlands) for HDR interstitial brachytherapy were then placed on a 0.5 mm thick polyethylene terephthalate glycol plastic sheet (Erkodur; Erkodent, Germany) and fixed with resin (Unifast III; GC Co., Japan) (figure 4A, B). A 4-mm thick lead mold was formed using a second plaster model made by a silicon impression (Labocone Putty; GC Co., Japan, Sildefit wash; Shofu Inc., Ltd., Japan) of the first plaster model with the plastic mold in place (figure 4A, C, D), with that then placed on top of the plastic mold to make a two-layered mold (figure 4E, F). This was done to reduce radiation exposure in the surrounding area.

To prevent metallic artifacts produced by lead in the second mold, only the first mold was put in the patient's mouth. After that, CT scanning was performed and a three-dimensional treatment plan was designed using an Oncentra Brachy tool (Elekta AB, Sweden). The contour of the clinical target volume (CTV) was identified using CT images and the

planning target volume (PTV) was determined to be the CTV's equivalent. A 6-Gy dosage as D100, i.e., the minimum prescribed dose, was given to 100% of the PTV. Figure 5 depicts the dose-distribution diagram. Since no bone destruction was seen in CT scans, the PTV was made to include the entire tumor volume and irradiate from the mandibular surface to around 1 cm into the mandibular alveolar bone. The design also took into account lowering the dose to healthy tissues surrounding the tumor.

After positioning the two-layered mold inside the mouth, the radiation therapy started (figure 6). MicroSelectron HDR-V2 (Elekta, Sweden) was used as the irradiation device, while 192-Ir was used as the radiation source. The total prescribed dose was 54 Gy divided into nine fractions given at intervals of at least six hours over a period of five days, with the patient treated on an outpatient basis. The patient understood and followed the instructions of the medical staff, with any questions related to the treatment adequately addressed to reduce his anxiety.

Despite the use of lead shielding, radiation-related mucositis developed immediately after irradiation in areas other than the primary tumor, including the left lateral border of the tongue, floor of the mouth, and cheek. The mucositis severity was consistent with the delivered radiation dose. At two months after the radiation treatment, mucosal inflammation had mostly subsided and at 12 months post-irradiation the mucosa showed complete healing (figures 7, 8, 9).

There were no signs of xerostomia or dysgeusia. Additionally, imaging examinations conducted six and 18 months following therapy revealed no abnormalities at the primary site of the lesion. At 30 months following treatment, no metastasis in a cervical lymph node or distant metastasis was detected.

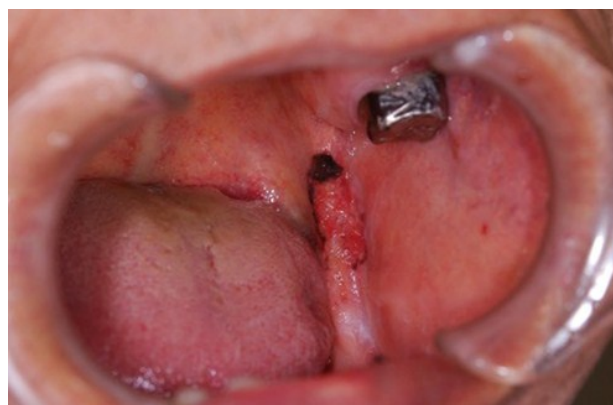

Figure 1. Pretreatment clinical photograph showing large lesion on the left mandibular gingiva and retromolar trigone, measured to be approximately $24 \times 12 \times 3$ mm in size, cT2N0M0, Stage II.

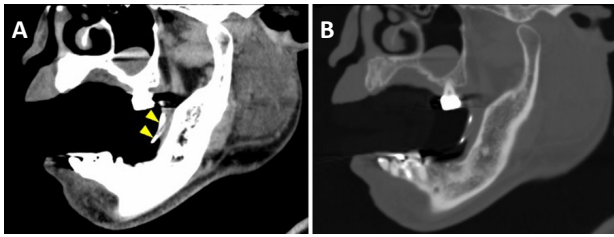


Figure 2. Pretreatment CT images. Representative sagittal section through left mandibular posterior body. **(A)** Soft tissue kernel reconstruction. Arrowheads show one of three flexible catheters used for HDR mold brachytherapy. The 3-mm region between the flexible catheter and mandibular ramus corresponds to tumor thickness. **(B)** Bone kernel reconstruction CT section showing intact mandibular cortex in contact with tumor, with no evidence of bone destruction.

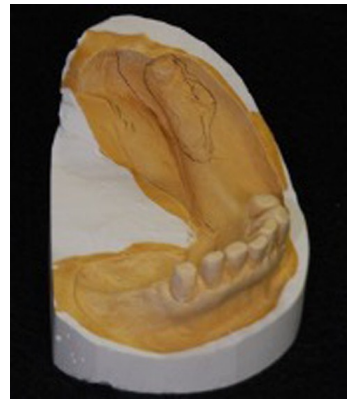

Figure 3. Plaster model. Note the tumor region outlined from the left mandibular gingiva to retromolar trigone.

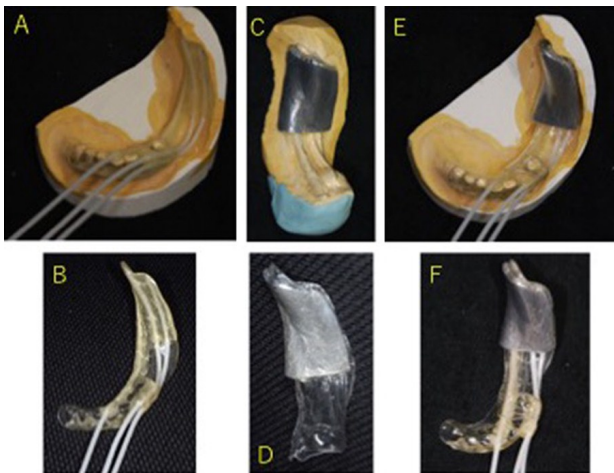


Figure 4. Custom fabrication of mold. **(A, B)** Plastic mold with three flexible catheters attached. **(C, D)** Lead mold used to protect against radiation exposure. **(E, F)** Two-layered mold after assembly.

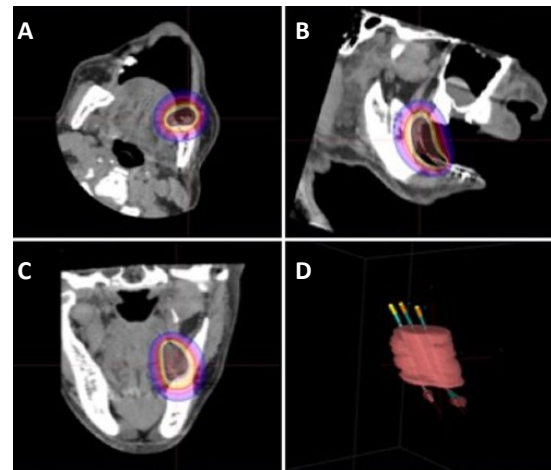


Figure 5. Dose-distribution map for HDR mold brachytherapy. Dose distribution profile shown for **(A)** axial **(B)** sagittal, and **(C)** coronal sections. **(D)** Three-dimensional surface rendered image showing position of three flexible catheters in relation to planned target volume in segment colored red.

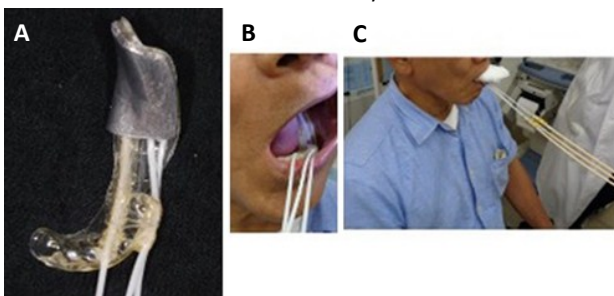


Figure 6. Treatment setup. **(A)** Two-layered mold. **(B)** Mold placed in mouth of patient and connected to irradiator. **(C)** Patient shown biting on piece of gauze to stabilize jaw position during irradiation.

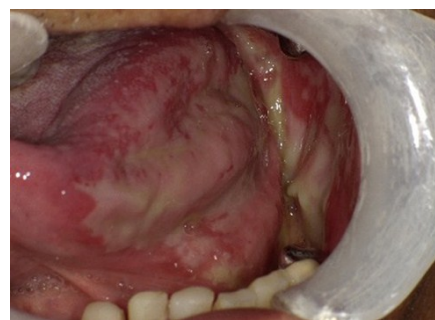

Figure 7. Clinical photograph at one week after treatment. Note mucositis on the left lateral border of the tongue, floor of the mouth, and cheek, adjacent to the region of the mold.

Figure 8. Clinical photograph at two months after treatment. Mucositis can be seen on the left lateral border of the tongue and adjacent to the region of the mold, though size was reduced as compared to one week after treatment (see Figure 7).

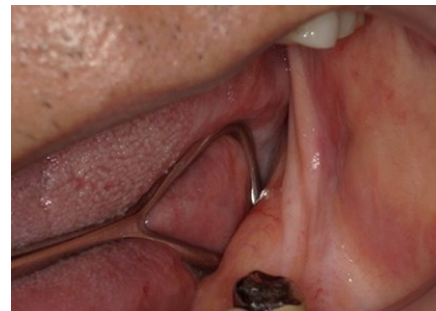
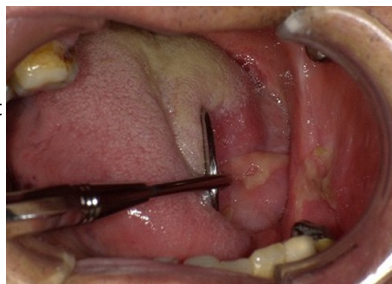
Figure 9. Clinical photograph at 12 months after treatment. Healed oral mucosa with no evidence of mucositis.

DISCUSSION

The usual course of treatment for gingival cancer is surgical resection^(13,14). Alternatively, for cases of superficial gingival cancer with little or no bone invasion, external-beam or internal radiation therapy can be used. The present patient was initially offered external-beam radiation therapy, though he declined due to worries about side effects such as extensive mucositis and/or skin damage. As a result, mold brachytherapy was selected as a potentially viable option^(1,2,12).

The principal benefit of mold brachytherapy is that it eliminates the necessity for invasive operations^(1-3, 5-8). Tissue morbidity is decreased because no catheter is inserted into the tissue. In addition, a catheter only needs to be set at the time of treatment, and the mold is also detachable. There have been reports of using this approach to treat superficial gingival cancer while hospitalized, with local control and good prognosis^(1, 4, 6, 9, 11, 12). However, to our knowledge, this is the first report of use of mold therapy for mandibular gingival cancer performed in an outpatient setting.

Decay of ¹⁹²Ir occurs principally by emission of beta particles and gamma radiation. The half-value layer of lead used for these radiation energies is 2.5 mm, thus the lead thickness of 4 mm used in the present fabricated mold used was expected to result in transmission of 31% of the incident radiation⁽¹⁵⁾, thereby reducing exposure in the surrounding anatomy. There were no unanticipated adverse events found to be associated with the outpatient treatment protocol utilized. Based on the present results, we believe that mold brachytherapy in cases with superficial gingival cancer can be successfully administered in an outpatient treatment setting. A previous report suggested two points: (1) Due to its inadequate coverage, the mold technique is not recommended for tumors located in the retromolar trigone; (2) Tumors that are more than 5 mm thick before radiation therapy may not be acceptable for the mold technique⁽⁶⁾. However, our experience in the present case showed that the tumor could be covered and mold brachytherapy was successful.

Since there were no teeth in the vicinity of the tumor in the present case, it was simple to create and put the mold in the relevant area (figure 10). It was assumed that there was no bone invasion since the tumor moved during palpation and because a bone invasion was not shown on CT imaging. The PTV was extended from the tumor surface to about 1 cm into the mandible since it was very hard to irradiate only the tumor. All layers of the cortical bone but only a portion of the bone marrow was irradiated due to the possibility of the tumor invading the bone at a microscopic-sized. Importantly, the findings of the panoramic radiograph did not reveal any teeth in the irradiation area with odontogenic inflammation,

which would need to be extracted before mold brachytherapy. Thus, it was determined that there was a low possibility of radiation-induced osteonecrosis of the mandible in the present patient.

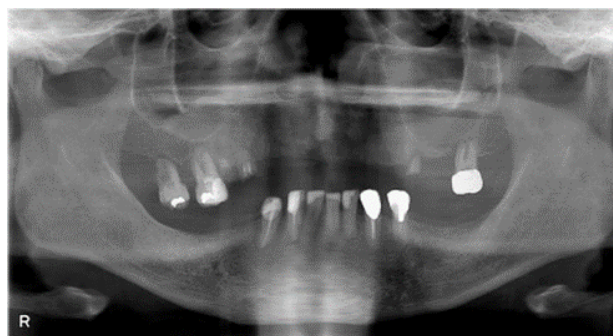


Figure 10. Pretreatment panoramic radiograph (Hyper-X; ASA-HIROENTGEN, Japan).

An outpatient setting provides several advantages. Overall, fewer hospital resources are needed and the related health care costs are markedly reduced as compared to hospitalization. In addition, scheduling of the radiation therapy is not dependent on hospital bed availability, thus allowing the institution to increase bed utilization for cases that require inpatient care. The need for personnel including physicians, nurses, and other health care staff is also markedly reduced, which further lowers costs associated with treatment delivery. In general, treatments delivered in an outpatient setting have increased convenience for both patient and caregivers, and also eliminates the emotional burden of a hospital stay. The absence of any unanticipated adverse events associated specifically with the outpatient treatment protocol in the present case further emphasizes the value of this treatment approach.

There are some limitations to outpatient care. It is more difficult to handle some types of emergencies or urgent situations, which can potentially compromise patient safety and health. Also, such an approach is not suited for patients who are unable to adhere to or comply with instructions from medical staff. During the five-day treatment period for the present case, the patient was proactively interviewed to (a) identify any impact on appetite, weight loss, or general physical well-being, (b) ensure oral hygiene practices and compliance with prescribed medications, (c) confirm his ability to continue outpatient visits, and (d) inquire regarding any questions related to the treatment. We also instructed him to contact us immediately in case of an emergency. The patient understood and followed the instructions of the medical staff. Except for the tumor, he was in good general health and had no history of medical illness requiring management, though was affected by an anxiety disorder. Thus, we considered that this patient was well suited for outpatient treatment.

There was no evidence of a local recurrence, lymph node metastasis, or distant metastasis over the

30-month follow-up period. Furthermore, the absence of any bone changes in the irradiated area as of the time writing is encouraging. More patients are expected to be deemed inoperable due to comorbidities or to decline hospitalization as the general population ages. Although the target group is small, the outcomes of the present case demonstrate that outpatient mold brachytherapy is an appealing alternative that is less invasive and burdensome for suitable oral cancer patients.

In conclusion, to the best of our knowledge, this is the first report of HDR mold brachytherapy treatment of a mandibular gingival SCC in an outpatient setting. We recommend judicious application of this approach to improve the patient treatment experience without compromising safety or therapeutic outcome.

ACKNOWLEDGEMENTS

Not applicable.

Ethical approval: The ethics committee of Osaka University Graduate School of Dentistry approved this study. All procedures performed were conducted in accordance with the ethical standards of the institutional and/or national research committees, as well as the 1964 Helsinki Declaration and its later amendments or comparable ethical standards.

Informed consent: Written informed consent was obtained from the patient for presentation of relevant data in this report.

Funding: None.

Conflicts of interest: The authors have no conflicts of interest to declare.

Authors' contributions: Conception and design: A.T., H.S., Y.U., and S.M. Data collection: A.T., H.S., Y.U., T.T., T.M., and M.O. Data analysis and interpretation: S.K., S.M.M., T.H., K.O., and H.S. Drafting of the article: A.T., H.S., Y.U., T.T., and T.M. Revising the article: S.K., S.M.M., T.H., K.O., and H.S. All of the authors have read

and agreed to the published version of the manuscript.

REFERENCES

- Unetsubo T, Matsuzaki H, Takemoto M, et al. (2015) High-dose-rate brachytherapy using molds for lip and oral cavity tumors. *Radiat Oncol*, **10**: 81.
- Yamazaki H, Yoshida K, Yoshioka Y, et al. (2013) High dose rate brachytherapy for oral cancer. *J Radiat Res*, **54**: 1–17.
- Wong G, Cirino ET, Ladd RO, et al. (2015) Use of customized intraoral mold high-dose-rate brachytherapy in the treatment of oral cavity cancer in an elderly patient. *Pract Radiat Oncol*, **5**: 74–78.
- Ariji E, Hayashi N, Kimura Y, et al. (1999) Customized mold brachytherapy for oral carcinomas through use of high-dose-rate remote after loading apparatus. *Oral Surg Oral Med Oral Pathol Oral Radiol Endod*, **87**: 508–512.
- Matsuzaki H, Takemoto M, Hara M, et al. (2012) Two-piece customized mold technique for high-dose-rate brachytherapy on cancers of the buccal mucosa and lip. *Oral Surg Oral Med Oral Pathol Oral Radiol*, **113**: 118–125.
- Nishimura Y, Yokoe Y, Nagata Y, et al. (1998) High-dose-rate brachytherapy using molds for oral cavity cancer: The technique and its limitations. *Int J Clin Oncol*, **3**: 351–356.
- Prisciandaro JI, Foote RL, Herman MG, et al. (2005) A buccal mucosa carcinoma treated with high dose rate brachytherapy. *J Appl Clin Medical Phys*, **6**: 8–12.
- Jolly DE and Nag S (1992) Technique for construction of dental molds for high-dose-rate remote brachytherapy. *Spec Care Dentist*, **12**: 219–224.
- Chatani M, Tsuboi K, Yagi M, et al. (2012) High dose rate brachytherapy using molds after chemoradiotherapy for oral cavity cancer. *Jpn J Radiol*, **30**:40–44.
- Garrán C, Montesdeoca N, Martínez-Monge R (2008) Treatment of upper gum carcinoma with high-dose-rate customized-mold brachytherapy. *Brachytherapy*, **7**: 267–269.
- Obinata K, Ohmori K, Shirato H, Nakamura M (2007) Experience of high-dose-rate brachytherapy for head and neck cancer treated by a customized intraoral mold technique. *Radiat Med*, **25**: 181–186.
- Kudoh T, Ikushima H, Kudoh K, et al. (2010) High-dose-rate brachytherapy for patients with maxillary gingival carcinoma using a novel customized intraoral mold technique. *Oral Surg Oral Med Oral Pathol Oral Radiol Endod*, **109**: e102–e108.
- Cengiz M, Ozyar E, Ersu B, et al. (1999) High dose rate mold brachytherapy of early gingival carcinoma: a clinical report. *J Prosthet Dent*, **82**: 512–514.
- Head and Neck cancers, Version 2. NCCN Clinical Practice Guidelines in Oncology. (2022). Available online: <https://www.nccn.org>. Accessed 1sth November 2022.
- Khan FM (2010) The physics of radiation therapy. 4th ed. Lippincott Williams & Wilkins, Philadelphia p. 316.

