Volume 22, No 1 | International Journal of Radiation Research, January 2024

Clinical efficacy of CT positioning-guided puncture and drainage of cerebral hemorrhage

Rong Cai*

Department of Operating Center, Affiliated Hospital of North Sichuan Medical College, Nanchong, Sichuan, 637000, China

► ***Original article***

Corresponding author:
Rong Cai, Ph.D.,
E-mail:
13458251545@163.com

Received: April 2023
Final revised: July 2023
Accepted: August 2023

Int. J. Radiat. Res., January 2024; 22(1): 43-48

DOI: 10.52547/ijrr.21.1.7

Keywords: *Computed tomography, puncture and drainage, intracerebral hemorrhage, hypertension.*

ABSTRACT

Background: To probe the effects of computed tomography (CT) positioning-guided puncture and drainage of cerebral hemorrhage. ***Material and Methods:*** Totally 120 patients with hypertensive cerebral hemorrhage (HCH) in our hospital from February 2022 to January 2023 enrolled in this study. Patients were randomized into observation group (OG) and control group (CG), including 60 cases in each group. Patients in the CG were given conservative treatment. Patients in the OG were given CT guided puncture and drainage of intracerebral hemorrhage. The effects of different treatment on clinical efficacy, daily living ability, motor function of limbs, quality of life, incidence of postoperative complications and patient satisfaction were compared. ***Results:*** The total clinical response rate in the OG reached 93.33%, which was significantly higher compared with the 78.33% in CG ($\chi2=5.55$, $P<0.05$). After treatment, daily living ability and motor function scores were elevated in both groups, and were higher after CT positioning-guided puncture than conservative treatment ($P<0.05$). The score of social relations, mental function, mental vitality and physical function were higher while the complication rate was lower in the OG in comparison with the CG ($P<0.05$). Moreover, OG also showed higher patient satisfaction rate than the CG (96.67% VS 78.33%), with statistical significance ($\chi2=9.22$, $P<0.05$). ***Conclusion:*** CT positioning-guided puncture and drainage is a reliable and effective approach to attenuate the hematoma, improve the life quality of patients with intracerebral hemorrhage, with better clinical response and less complications relative to the conservative treatment.

INTRODUCTION

Hypertensive cerebral hemorrhage (HCH) is the most common cerebrovascular disease in our country, with a mortality rate of up to 40% [1]. It is more common in people between 50 and 70 years old, and seriously threatens the life and health of middle-aged and elderly people [2]. Most scholars believe that chronic hypertension can lead to hyaline degeneration of cerebral arteries [3]. First, the stroma under the intima of blood vessels is swollen, and lipid precipitates under the intima, forming unstructured substances between the intima and the inner elastic layer, resulting in reduced elasticity and increased brittleness [4]. Vascular wall tension loss and cellulose necrosis, resulting in local artery spindle or bulbous bulge under the impact of blood pressure, and blood may invade the wall and form a sandwich aneurysm [5]. When blood pressure spikes, the aneurysm ruptures and causes bleeding [6]. Hypertensive cerebral hemorrhage is often in activity, excitement, forced defecation and other moments of onset, sudden onset, often in a few minutes or hours to develop to the peak of the disease [7]. The clinical manifestations vary according to the bleeding site, the amount of bleeding, and systemic conditions. The onset is usually sudden onset of severe headache, nausea, vomiting, and often restlessness, lethargy, or coma [8]. Hemiplegia and pupil changes appear on the opposite side of the hematoma. In the early stage, both sides of the pupil shrink. When the hematoma expands and brain edema worsens, intracranial pressure increases, causing cerebral herniated crisis such as dilated pupil on the side of the hematoma, respiratory disorders, slow pulse, and elevated blood pressure appear [9]. At present, minimally invasive puncture and drainage guided by computed tomography (CT) positioning is widely used in clinical practice due to its characteristics of small trauma and good drainage effect [10]. The timely diagnosis and treatment are of vital significance for the prognosis of patients with hypertensive cerebral hemorrhage. With the advancement of CT technology, the CT imaging has gradually become the important evidence for the design of treatment plan and the prognosis evaluation with high sensitivity for patients with intracerebral hemorrhage [11].

This study proposed to investigate the clinical effects of CT positioning guided puncture and drainage compared with conservative treatment for cerebral hemorrhage. The clinical outcomes, postoperative recovery and satisfaction between

[Downloaded from ijrr.com on 2026-11-24]

[DOI: 10.61186/ijrr.22.1.43]

patients in the two groups were evaluated. The findings of this study are expected to provide reference for the management of cerebral hemorrhage in clinical practice.

MATERIALS AND METHODS

Patients

Totally 120 patients with hypertensive cerebral hemorrhage admitted to our hospital from February 2022 to January 2023 were selected as the study objects. All patients were confirmed with cerebral hemorrhage by head CT examination, with a bleeding volume of 30-120 mL. According to the principle of randomized control, the patients were randomized into observation group (OG) and control group (CG), including 60 cases per group. Patients in the OG were treated with CT positioning-guided puncture and drainage, and those in the CG received conservative treatment. Inclusion criteria: (1) Family members signed the informed consent. (2) Complete medical records and clear medical history. (3) Diagnosed and confirmed with as cerebral hemorrhage by head CT imaging examination. (4) With a history of hypertension. Exclusion criteria: (1) Complicated with other organ lesions. (2) Congenital mental, language and cognitive disorders. (3) Unable to participate in the test for personal reasons.

Methods

Patients in the control group received conservative treatment. The vital signs of patients were continuously monitored and measures were taken to control the blood pressure and maintain the electrolyte balance. The 20% mannitol (Sichuan Kelun Pharmaceutical Co., Ltd., Sichuan, China) was used for dehydration to reduce intracranial pressure. Appropriate antibiotics were given to prevent infection.

For patients in the observation group, the distance between scalp and hematoma center was determined according to CT image, suitable puncture and drainage needle (YL-1, Beijing WanFu Water Co., Ltd., Beijing, China) was selected, and non-functional area close to hematoma without important blood vessels was selected as puncture area. After the preoperative preparation was completed, lidocaine (Shanghai Shyndec Pharmaceutical Co.,Ltd., Shanghai, China) was used for local anaesthesia, and then the needle was injected, and made the puncture into the hematoma based on CT guidance. Next, the drill core was pulled out, and the sealing cover was fixed. The hematoma was first slowly aspirated, and then the mixture of normal saline and heparin was repeatedly rinsed. The drainage solution was stopped after it became weak. Finally, liquefied solution composed of normal saline, heparin, and urokinase (Tianjin Biochemical Pharmaceutical Co., Ltd., Tianjin, China) was injected into the residual cavity and left in place for about 4 h, and the drainage tube was opened for drainage. The treatment was repeated at 8 h until CT examination confirmed the removal of hematoma (figure 1). After all the hematoma was removed, the puncture needle was removed.

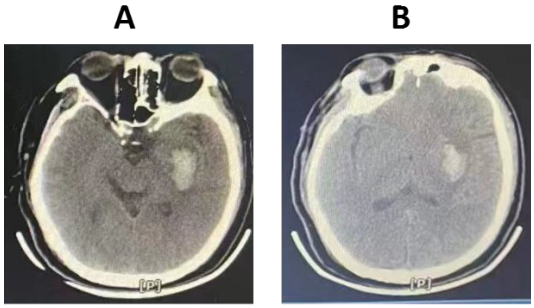

Figure 1. (A) CT images of patients with cerebral hemorrhage prior to the treatment. **(B)** CT images of patients after CT positioning guided puncture and drainage.

Imaging studies

Cranial plain CT scan was conducted with an Aquilion 64-slice CT scanner (Toshiba, Japan). With the orbito-auricular line as the baseline, the top of the head is continuously scanned. The parameters were set as follows: the slice thickness was 8 mm, the slice interval was 8 mm, the tube voltage was 120 KV, and the tube current was 200–238 mAs. Radiologists observed the location of cerebral hemorrhage and volume of hematoma, and arranged the reexamination based on the changed condition of patients.

Post-surgery interventions

Patients received general routine interventions after surgery, including the detection of changes in vital signs, disease observation, and dietary guidance. The oxygen inhalation was given if necessary. Nutritional support and oral care should be strengthened. Patients in coma should be given nasal feeding and inhalation, and easily digestible foods such as low sugar and low fat should be given. Patient blood pressure was controlled strictly. Dehydration was performed according to the results of intracranial pressure monitor. Drainage tube care fixation and proper placement of drainage tube and drainage bag. The ventricular drainage tube was suspended about 20 cm above the head of the bed to maintain normal intracranial pressure. The intraoperative cavity drainage tube was placed parallel and gradually lowered 48 h later. The drainage bag was replaced every day, with the cleaning and disinfection done well and under aseptic operation. The puncture site was kept clean and dry, and the sterile dressing was replaced once a day.

Observation indexes

(1) Clinical efficacy was evaluated as follows: Basic recovery: more than 91% reduction in the degree of National Institutes of Health Stroke Scale (NIHSS) [12]. Obvious effect: the NIHSS score was

[Downloaded from ijrr.com on 2026-11-24]

[DOI: 10.61186/ijrr.22.1.43]

decreased by 46% to 90%. Effective: the NIHSS score was decreased by 18% to 45%. Ineffective: the decline in the neurological deficit score was not reached 18%. Total response rate = (basic recovery + obvious effect + effective)/Total cases ×100%.

(3) Daily living ability was assessed by Barthel index [13], including dressing, eating, grooming, bathing, toilet use, bed chair transfer, flat walking, urination control, stool control, up and down stairs.

(4) The motor function of limbs was evaluated by Fugl-Meyer Motor Function scale [14].

(5) Postoperative quality of life score was accessed based on The 100-item World Health Organization Quality of Life Assessment (WHOQOL-100) [15], including social relations, psychological function, spiritual vitality, and physical function.

(6) Postoperative complications were monitored, mainly including constipation, rebleeding, pneumonia, lower limb venous thrombosis, and intracranial infection.

(7) Patient satisfaction rate for the treatment in both groups was evaluated. The patient satisfaction questionnaire designed by our hospital was used, which was filled in by patients or their families anonymously. It was divided into three options: very satisfied, satisfied and dissatisfied. Satisfaction was calculated by very satisfied rate + satisfaction rate.

Statistical method

The t test and χ^2 test in SPSS19.0 software (SPSS Inc, Chicago, IL, USA) were used to analyze and compare the measurement data and counting data, $P<0.05$ was regarded as statistically significant.

RESULTS

CT diagnosis results

Totally 120 patients with hypertensive cerebral hemorrhage in our hospital from February 2022 to January 2023 were enrolled in this study. The OG had 30 males and 30 females, and their age ranged from 42 to 77 years, with an average age of 53.26±5.36 years. The CT results showed that the bleeding sites were basal ganglia in 45 cases (75%), temporal lobe in 10 cases (16.67%), and parietal lobe in 5 cases (8.33%). In the control group, 32 males and 28 females were included, with the age ranging from 43 to 78 years, and the average age was 53.31±5.46 years. The CT results showed that the bleeding sites were basal ganglia in 46 cases (76.67%), temporal lobe in 8 cases (13.33%) and parietal lobe in 6 cases (10%). No significant differences were found in gender, age, blood loss, bleeding site and other general conditions between the CG and OG ($P>0.05$, Table 1). The results of CT scan showed dense masses with clear boundary and uniform density in the brain, and the CT values were between 54Hu to 79Hu.

Table 1. Clinical characteristics of patients.

	Control group (n=60)	Observation group (n=60)	P
Age (years)	53.31±5.46	53.26±5.36	0.96
Gender (male/female)	32/28	30/30	0.715
bleeding sites			0.85
basal ganglia	46	45	
temporal lobe	8	10	
parietal lobe	6	5	
Bleeding volume (ml)	33±4.5	34±5.2	0.262
Onset time (h)	6.9±2.2	7.1±2.5	0.642
History of hypertension (years)	7.9±2.4	8.5±3.7	0.294

Clinical effects in both groups

After the conservative treatment in the control group, 22 patients had basic recovery, 16 patients showed obvious effect, 9 patients showed effective outcome and 13 patients exhibited ineffective outcome. For patients in the OG, 33 cases had basic recovery, 15 cases had obvious effect, 8 patients showed effective outcome and 4 patients exhibited ineffective outcome. The total clinical response rate of the OG was 93.33%, and was significantly higher compared to the 78.33% in CG ($\chi^2=5.55$, $P<0.05$, figure 2). Consistently, the results of CT scan showed that the hematoma volume was significantly reduced in both groups of patients after treatment, and those in the OG showed better recovery relative to the OG.

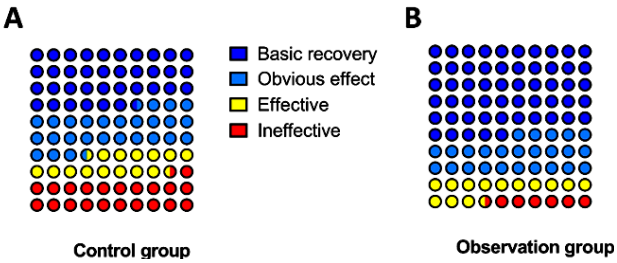

Figure 2. Clinical treatment efficacy evaluation of **(A)** conservative treatment in the control group and **(B)** CT positioning-guided puncture and drainage in the observation group.

Recovery of daily living ability and motor function of limbs in both groups

As displayed in figure 3 that, previous to treatment, no significant differences were seen in daily living ability and motor function scores in both groups ($P>0.05$). Both scores were elevated post treatment, and we also revealed that the two scores in the OG were higher relative to the CG, which indicated that CT positioning-guided puncture and drainage more effectively promoted the recovery of daily living ability and motor function of HCH patients compared with conservative treatment ($P<0.05$).

Patient life quality score in both groups

Patient life quality in the two groups after the treatment was monitored using the WHOQOL-100. As shown in figure 4, the score of social relations, mental

[Downloaded from ijrr.com on 2026-11-24]

[DOI: 10.61186/ijrr.22.1.43]

function, mental vitality and physical function in the OG were higher relative to the CG, suggesting the CT positioning-guided puncture and drainage as a reliable management to improve patient recovery and life quality compared with conservative treatment (P<0.05, figure 4).

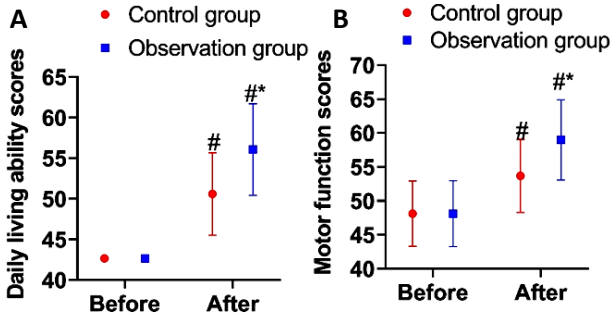

Figure 3. (A) Daily living ability and **(B)** motor function of limbs in both groups before and after the treatment. #P<0.05, relative to before treatment. *P<0.05, relative to the control group.

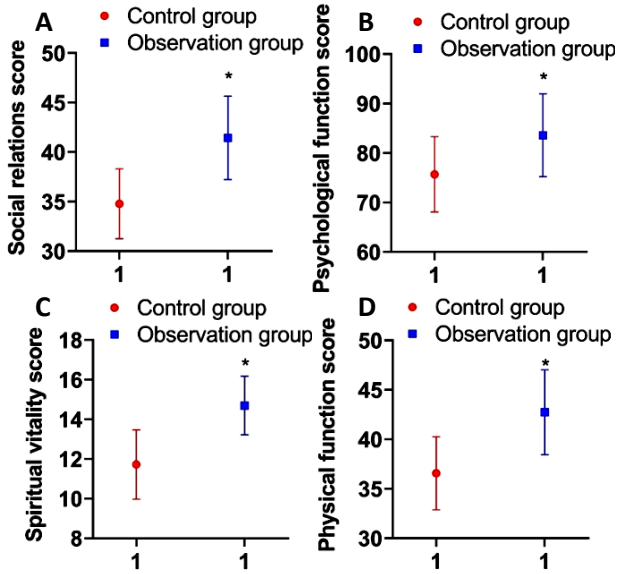

Figure 4. Quality of life score in **(A)** social relations, **(B)** psychological function, **(C)** spiritual vitality, and **(D)** physical function in both groups after the treatment based on WHOQOL-100. *P<0.05.

Incidence of postoperative complications in both groups

After the treatment, the cases of complications in the OG were less than the CG, and the complication incidence rate of the OG was only 6.67%, which was significantly lower relative to the CG (23.33%) (χ^2=6.54, P<0.05, table 2).

Patient satisfaction in both groups

According to the patient satisfaction questionnaire, 13 patients in the CG were unsatisfied, and 2 patients in the OG were unsatisfied. Patient satisfaction in the OG reached 96.67%, which was significantly higher compared to the CG (78.33%), and the difference had statistical significance (χ^2=9.22, P<0.05, figure 5).



Figure 5. Patient satisfaction rate of the treatment **(A)** in the control group and **(B)** observation group.

DISCUSSION

Hypertensive intracerebral hemorrhage is a common and serious disease in the department of neurology, which can lead to hemiplegia, neurological dysfunction, and even death [16]. In China, approximately 48% of cardiovascular and cerebrovascular disease cases were cerebral hemorrhage cases, and the mortality rate of cerebral hemorrhage has reached 55% annually [17, 18]. Timely removal of hematoma, reducing the compression of brain tissue, and restoring the damaged nerve function are the main measures for the treatment of hypertensive cerebral hemorrhage [19]. CT positioning guided puncture drainage is reported with satisfactory results [20]. In our study, we revealed that compared with the conservative treatment, the CT positioning-guided puncture drainage can effectively attenuate the intracerebral hematoma with improved clinical effects and functional recovery relative to the conservative treatment.

Currently, the conservative treatment and CT positioning-guided puncture drainage are both applied for cerebral hemorrhage therapy in clinic, and it is controversial in the selection of optimal treatment approaches [21]. Some believe that the time of hematoma dissipation in the conservative treatment is longer with slow functional recovery, and the prognosis in patients after the conservative treatment is worse than those receiving the minimally invasive puncture drainage [21]. A randomized

Table 2. Incidence of postoperative complications in both groups.

Groups	Constipation	Rebleeding	Pneumonia	Lower limb venous thrombosis	Intracranial infection	Total incidence rate (%)
Control group (n=60)	5	2	3	2	2	14 (23.33%)
Observation group (n=60)	2	0	1	1	0	4 (6.67%)
χ^2	6.54					
P	<0.05					

[Downloaded from ijrr.com on 2026-11-24]

[DOI: 10.61186/ijrr.22.1.43]

controlled trial also indicates that minimally invasive surgery more effectively improves postoperative recovery, reduces postoperative complications, and raises survival rates compared with conventional craniotomy [22]. However, Mendelow *et al.* in their multi-center clinical trials indicate that no significant difference is found between patients in the conservative treatment group and those in the surgery group, while the surgery group has a small survival advantage [23]. The reason may be that the patients with cerebral hemorrhage are usually middle-aged or elderly patients, and their low tolerance of the surgery and the complications may counteract part of the treatment effects. The CT positioning-guided puncture drainage is characterized by the less trauma, quick rehabilitation and less complications [10]. As the hematoma formation is a main factor involved in the pathogenesis of cerebral hemorrhage, its existence with sterile products induces toxic reactions in brain tissue, leading to cell edema and increased intracranial pressure [21]. Therefore, in the process of hemorrhage evacuation, the accurate positioning of the drainage catheter is considered as a critical factor [10]. In our study, under the guidance of CT imaging, all catheter tips reached the center of the hemorrhage. We found that the hematoma volume was significantly reduced in both groups of patients after treatment, and those in the OG showed higher reduction in hematoma volume relative to the OG. The outcomes also demonstrated that the total clinical response rate of the CT positioning-guided puncture and drainage was higher compared to the conservative treatment (figure 2). The daily living ability and motor function scores after the CT positioning-guided puncture and drainage were elevated relative to the conservative treatment (figure 3). The CT positioning-guided puncture and drainage also improved the score of quality of life relative to the conservative treatment (Figure 4). Furthermore, we found that the complication rate after conservative treatment was higher relative to the CT positioning-guided puncture and drainage (table 2), and patient satisfaction in the OG was higher in comparison with the CG (figure 5). These results were also consistent with the previous findings.

CONCLUSION

CT positioning guided puncture drainage is a reliable and effective approach with favorable clinical response and can improve the postoperative recovery and life quality of patients after intracerebral hemorrhage compared with conservative treatment, and is worth for promotion in clinical practice.

***Funding*:** This work was supported by the 2021 research project of Famous Old Traditional Chinese Medicine Case Research Center of Nanchong (No. YAZX21-YB-02).

***Conflicts of interests*:** The authors declare no conflicts of interest to declare.

***Ethical consideration*:** This study was approved by the Ethics Committee of Affiliated Hospital of North Sichuan Medical College (approval number: SC-LL-01) and written informed consent was signed by all patients before the study.

***Author contribution*:** R.C. designed the study, collected and analyzed the data, wrote and revised the manuscript. The author has read and approved the final version of the manuscript.

REFERENCES

1. Ziai WC, Thompson CB, Mayo S*, et al.* (2019) Intracranial hypertension and cerebral perfusion pressure insults in adult hypertensive intraventricular hemorrhage: Occurrence and associations with outcome. *Crit Care Med*, ***47****(8): 1125-34.*
2. Mehndiratta P, Manjila S, Ostergard T*, et al.* (2012) Cerebral amyloid angiopathy-associated intracerebral hemorrhage: pathology and management. *Neurosurg Focus*, ***32****(4): E7.*
3. Delcroix M, Torbicki A, Gopalan D*, et al.* (2021) ERS statement on chronic thromboembolic pulmonary hypertension. *Eur Respir J*, ***57*** *(6).*
4. Ikram MA, Wieberdink RG, Koudstaal PJ (2012) International epidemiology of intracerebral hemorrhage. *Curr Atheroscler Rep*, ***14*** *(4): 300-6.*
5. Dastur CK and Yu W (2017) Current management of spontaneous intracerebral haemorrhage. *Stroke Vasc Neurol*, ***2****(1): 21-9.*
6. Robles LA and Volovici V (2022) Hypertensive primary intraventricular hemorrhage: a systematic review. *Neurosurg Rev*, ***45****(3): 2013-26.*
7. Zhang L, Wang X, Ge Y (2022) Anesthetic effect of sevoflurane in the craniotomy hematoma evacuation treatment of hypertensive cerebral hemorrhage. *Panminerva Med*, ***64****(3): 407-8.*
8. Yang R, Wang Z, Jia Y*, et al.* (2022) Comparison of clinical efficacy of sodium nitroprusside and urapidil in the treatment of acute hypertensive cerebral hemorrhage. *J Healthc Eng*, ***2022****: 2209070.*
9. Sun G, Fu T, Liu Z*, et al.* (2021) The rule of brain hematoma pressure gradient and its influence on hypertensive cerebral hemorrhage operation. *Sci Rep*, ***11****(1): 4599.*
10. Yang Z, Hong B, Jia Z*, et al.* (2014) Treatment of supratentorial spontaneous intracerebral hemorrhage using image-guided minimally invasive surgery: Initial experiences of a flat detector CT-based puncture planning and navigation system in the angiographic suite. *AJNR American Journal of Neuroradiology*, ***35****(11): 2170-5.*
11. Gil-Garcia CA, Flores-Alvarez E, Cebrian-Garcia R*, et al.* (2022) Essential Topics About the Imaging Diagnosis and Treatment of Hemorrhagic Stroke: A Comprehensive Review of the 2022 AHA Guidelines. *Current problems in cardiology*, ***47****(11): 101328.*
12. Eskioglou E, Huchmandzadeh Millotte M, Amiguet M*, et al.* (2018) National Institutes of Health Stroke Scale Zero Strokes. *Stroke*, ***49*** *(12): 3057-9.*
13. Ocagli H, Cella N, Stivanello L*, et al.* (2021) The Barthel index as an indicator of hospital outcomes: A retrospective cross-sectional study with healthcare data from older people. *J Adv Nurs*, ***77****(4): 1751-61.*
14. Gladstone DJ, Danells CJ, Black SE (2002) The fugl-meyer assessment of motor recovery after stroke: a critical review of its measurement properties. *Neurorehabil Neural Repair*, ***16****(3): 232-40.*
15. Cazzorla C, Del Rizzo M, Burgard P*, et al.* (2012) Application of the WHOQOL-100 for the assessment of quality of life of adult patients with inherited metabolic diseases. *Mol Genet Metab*, ***106****(1): 25-30.*
16. de Oliveira Manoel AL (2020) Surgery for spontaneous intracerebral hemorrhage. *Crit Care*, ***24****(1): 45.*
17. Zheng H, Chen C, Zhang J*, et al.* (2016) Mechanism and therapy of brain edema after intracerebral hemorrhage. *Cerebrovascular Diseases (Basel, Switzerland)*, ***42****(3-4): 155-69.*

[Downloaded from ijrr.com on 2026-11-24]

[DOI: 10.61186/ijrr.22.1.43]

18. Yang M, Pan X, Liang Z*, et al.* (2019) Clinical features of nephrotic syndrome with cerebral hemorrhage. *Medical science monitor: Int Med J Experimental and Clinical Res,* ***25****: 2179-85.*
19. Reznik ME, Fakhri N, Moody S*, et al.* (2020) Arrival blood pressure in hypertensive and non-hypertensive spontaneous intracerebral hemorrhage. *J Neurol Sci*, ***416****: 117000.*
20. Fiorella D, Arthur A, Schafer S (2015) Minimally invasive cone beam CT-guided evacuation of parenchymal and ventricular hemorrhage using the Apollo system: proof of concept in a cadaver model. *J Neurointerv Surg*, ***7****(8): 569-73.*
21. Jia Y, Wang Y, Yang K*, et al.* (2021) Effect of Minimally Invasive Puncture Drainage and Conservative Treatment on Prognosis of Patients with Cerebral Hemorrhage. *Journal of healthcare engineering*, ***2021****: 2401256.*
22. Liu J, Cheng J, Zhou H*, et al.* (2021) Efficacy of minimally invasive surgery for the treatment of hypertensive intracerebral hemorrhage: A protocol of randomized controlled trial. *Medicine*, ***100****(3): e24213.*
23. Mendelow AD, Gregson BA, Rowan EN*, et al.* (2013) Early surgery versus initial conservative treatment in patients with spontaneous supratentorial lobar intracerebral haematomas (STICH II): a randomised trial. *Lancet (London, England)*, ***382****(9890): 397-408.*

[Downloaded from ijrr.com on 2026-11-24]

[DOI: 10.61186/ijrr.22.1.43]