Volume 22, No 1 | International Journal of Radiation Research, January 2024

Study on diagnostic value of ultrasound combined with mammography in breast cancer with different clinical and pathological features

Y. Xu[1,2], J. Qian[2], F. Wang[2], Y. Chen[1*]

[1]*Department of Breast Surgery, The Second Affiliated Hospital Zhejiang University School of Medicine, Hangzhou, Zhejiang 310009, China*

[2]*Department of Breast Surgery, The Women's and Children's Hospital of Linping District Hangzhou, Hangzhou, Zhejiang 311199, China*

► ***Original article***

Corresponding author:
Yiding Chen, Ph.D.,
E-mail: *cyd963136@163.com*

Received: June 2023
Final revised: August 2023
Accepted: August 2023

Int. J. Radiat. Res., January 2024; 22(1): 49-54

DOI: 10.52547/ijrr.21.1.8

Keywords: *Breast cancer, ultrasound, mammography, cancer diagnosis.*

ABSTRACT

Background*:** To assess the diagnostic value of ultrasound (US) combined with mammography in breast cancer with different clinical and pathological features. ***Materials and Methods: Totally 340 female patients with breast cancer were enrolled in this study. All patients underwent color ultrasound and mammography examination and the diagnostic efficiency in breast cancer with different clinical and pathological features was assessed. ***Results:*** The diagnostic sensitivity of ultrasound in breast cancer with different Body Mass Index (BMI), initial symptom, histological grade, and hormone receptor (HR) status was similar. The diagnostic sensitivity of mammography in breast cancer with different histological grade, HR status and Ki-67 positive rate was similar. However, the diagnostic sensitivity of ultrasound and mammography was higher in age ≥50 years, human epidermal growth factor receptor 2 (HER2) positive patients. The diagnostic sensitivity of ultrasound in Ki-67 positive rate >20 was higher than that in Ki-67 positive rate ≤20. The diagnostic sensitivity of mammography was higher in BMI >30 and in the initial symptom with calcification. Moreover, in different molecular subtypes, the diagnostic sensitivity of ultrasound and mammography in HR+HER2+ was the highest, followed by HR-HER2+, HR-HER2- and HR+HER2-. The diagnostic efficiency of ultrasound combined with mammography in different age, BMI, initial symptom, histological grade and HR status was similar. In addition, the diagnostic efficiency of ultrasound combined with mammography was higher than single ultrasound and mammography. ***Conclusion:*** Ultrasound combined with mammography showed high diagnostic efficiency in breast cancer with different clinical and pathological features was high, and is worthy for clinical promotion.

INTRODUCTION

Breast cancer (BC) is the leading cause of cancer incidence worldwide and the most prevent malignancy in females [1, 2]. Aberrations in hormone receptor (HR) and human epidermal growth factor receptor 2 (HER2) pathways are frequently observed in breast cancer patients. Based on molecular biomarkers, breast cancer can be classified into at least four different subtypes, with different treatments and prognoses: HR-negative and HER2-enriched, HR-positive and HER2-negative luminal A, HR-positive and HER2-positive luminal B and triple negative/basal-like, which is a subtype that is negative for both HR and HER2 [3]. The HR+/HER2 (−) subtype is likely to remain the most commonly diagnosed type of breast cancer [4]. Women aged 50-55 years old have a high incidence of breast cancer, mainly manifested as abnormal nipple or areola, breast mass, nipple discharge and axillary lymph node enlargement [5]. The cause of breast cancer is not completely clear, and it has seriously affected the life and health of the majority of female groups [6]. With the increase of living pressure and the prevalent screening programs the number of breast cancer patients is also increasing correspondingly, and the age of onset is showing a younger trend, which has attracted great attention from all walks of life [7, 8]. Therefore, early diagnosis and intervention are important to improve the prognosis of breast cancer patients.

Imaging technology is a major technology in breast cancer screening, including mammography, CT examination, ultrasound examination, and MRI examination [9]. Among them, breast ultrasound is convenient, non-invasive, without ionizing radiation and reproducible, and has been widely used in breast cancer screening and monitoring the response to therapy. Breast ultrasound imaging is also revealed to be effective in the detection of dense breasts possibly missed by mammography. However, there are certain shortcomings in showing small lesions and

[Downloaded from ijrr.com on 2026-11-24]

[DOI: 10.61186/ijrr.22.1.49]

calcification [10, 11]. Mammography is the first and basic examination method in breast cancer screening, with high sensitivity and specificity, but it is prone to adverse conditions such as breast image overlap [12]. Previous studies have also demonstrated that mammography screening is associated with the reduced breast cancer-related mortality [13, 14]. However, the long-term mammogram is indicated to increase the risk of radiation exposure [15]. Both the ultrasound examination and mammography have their own advantages and disadvantages. According to relevant studies, the combined application of mammography and ultrasound in breast cancer screening can improve the early diagnosis rate and reduce the occurrence of missed diagnosis and misdiagnosis [16]. The sensitivity of mammography is approximately 85% in specialized radiology practices, and exceeds 90% when combined with breast ultrasound or MRI [17, 18]. However, the association between the diagnosis sensitivity with the clinicopathological features of breast cancer patients remains not fully explored.

Therefore, our study aimed to investigate the diagnostic sensitivity of ultrasound combined with mammography in breast cancer with different clinical and pathological features. The findings of our work might provide clues for breast cancer diagnosis in clinic.

MATERIALS AND METHODS

Patients

A total of 340 female patients with breast cancer were selected from our hospital from January 1, 2018 to December 1, 2021, aged 27-80 years, with an average age of 49.30±11.40 years. All patients underwent color ultrasound and mammography examination. The clinical information of patients was shown in table 1.

Inclusion criteria: (1) Patients with breast skin abnormalities, nipple abnormalities and nipple discharge. (2) With breast lumps that could be touched; (3) Age ≥18 years old. (4) All patients and their families have informed consent and signed informed consent.

Exclusion criteria: (1) Cognitive abnormalities, unable to communicate normally. (2) Pregnant or lactating women. (3) Had a history of breast surgery.

Methods

Mammography

The MAMMOMAT Balance mammogram machine (Siemens, Germany) was used for examination. Oblique and axial radiographs of the inner and outer sides of the breast were taken by automatic exposure mode, and X-ray radiographs were enlarged according to the Breast Imaging Reporting and Data System (BI-RADS) grading standard [19]. The voltage was set as 22-35 kV, and the current was set as 30-300 mA. The digital mammography system generated raw data were analyzed using Volpara Imaging Software (Volpara Health Technologies Ltd., New Zealand). The location, shape, margin, density, and calcification foci of the masses were observed and evaluated. The examination was conducted by two experienced imaging physicians. The positive features were: fine sand or granular calcification foci clustered to 5/cm^2, with high density, unclear edges, and irregular nodules. Local skin depression was observed. The two physicians independently analyzed the examination results by double-blind method. If there was any difference in opinion, the final diagnosis was reached by consensus.

Table 1. General data of patients.

Age (years)	49.30±11.40
BMI	22.5±4.6
histological grade	N=313
Grade I	90 (28.8%)
Grade II	159 (50.8%)
Grade III	64 (20.4%)
calcification	N=340
with without	111 (32.6%) 229 (67.4%)
HR status	N=340
positive	244 (71.8%)
negative	96 (28.2%)
HER2 status	N=340
positive	92 (27.1%)
negative	248 (72.9%)
Ki-67	N=340
>20	135 (39.7%)
≤20	205 (60.3%)

BMI, Body Mass Index.

Ultrasonography of breast

The voluson 730 color ultrasound diagnostic instrument (GE Healthcare, US) was used for examination, and the probe frequency was 5-10 MHz. Before the examination, the patient was instructed to lift both upper limbs and lie flat, holding the head, and the lymphatic tissue of the breast and armpit was fully exposed. For those with larger breasts, a lateral position could be adopted, appropriate amount of coupling agent was applied in the probe, and the nipple was taken as the center to carry out radial scanning examination around, and horizontal and longitudinal scanning was performed. To ensure the integrity of the scan, each scan period overlapped with the last one. When an abnormal echo region was detected, a careful scan was performed. Simultaneously, the echo characteristics of this region were recorded, and the shape, echo intensity value, edge, and surrounding tissue relationship were evaluated. The blood flow parameters in the echo were detected by Doppler spectrum, and the status of lymph nodes in the axillary axilla was examined by scanning. According to the BI-RADS grading criteria, grade IV-V represented breast cancer. Specific positive signs included: lack of regular shape, lack of

[Downloaded from ijrr.com on 2026-11-24]

[DOI: 10.61186/ijrr.22.1.49]

uniformity in the distribution of echoes from center to edge, and fuzzy mass at the edge of the boundary. There were tiny, strong echo spots around the edges of the mass. Attenuation of echo, disorganized duct structure, and aspect ratio of more than 1 could be observed behind the mass.

The above examination was conducted by two experienced imaging physicians. The two physicians independently analyzed the examination results by double-blind method. If there was any difference in opinion, the final diagnosis was reached by consensus. Figure 1 showes the representative MRI and ultrasound images of breast cancer patients.

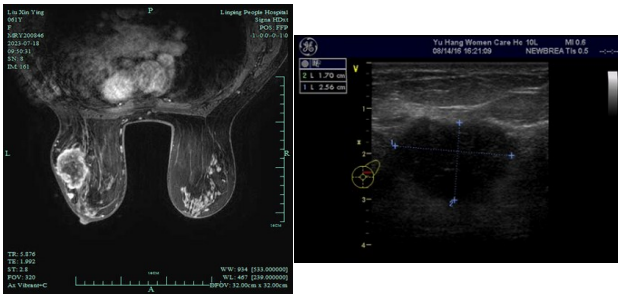

Figure 1. The representative MRI (left panel) and ultrasound images (right panel) of breast cancer patients. MRI images showed 45*4635 mm circular mass in the left breast, with BIRADS: 5. US imaging showed 2.6*1.7cm hypoecho mass in the left breast, with BI-RADS: 5

Observation indicators

The diagnostic efficiency of single and combined ultrasonography and X-ray molybdenum target examination was compared.

Statistical analysis

Statistical software SPSS 20.0 (SPSS Inc., USA) was used to process the data. The statistical data were represented by % and χ^2 test was used. P<0.05 was considered statistically significant.

RESULTS

Diagnostic efficiency of US and mammography with different age and BMI

As displayed in table 2, the diagnostic sensitivity of ultrasound in the age <50 years was 77%, and in age ≥50 years was 87.7% (P=0.007). The diagnostic sensitivity of mammography in the age <50 years was 65.2%, and in the age ≥50 years was 74.7% (P=0.036). Notably, the diagnostic efficiency of ultrasound combined with mammography was similar in the age <50 years and age ≥50 years, with the sensitivity of 89.3% and 94.4%, respectively (P=0.064), and was higher than single ultrasound and mammography.

The diagnostic sensitivity of ultrasound in different BMI was similar (P=0.057). The diagnostic sensitivity of mammography in BMI <25, BMI 25-30 and BMI >30 was 70.9%, 64.3% and 78.9%, respectively (P=0.045). Notably, the diagnostic efficiency of ultrasound combined with mammography in different BMI was similar (P=0.112), with the sensitivity of 90.7%, 92.9% and 100%, respectively, and was higher than single ultrasound and mammography.

Table 2. Diagnostic sensitivity of ultrasound and mammography in breast cancer with different age and BMI.

	N	Ultra-sound (%)	P value	Mammogra-phy (%)	P value	Combined inspection (%)	P value
Age	340		0.007		0.036		0.064
<50 years	178	77		65.2		89.3	
≥50 years	162	87.7		74.7		94.4	
BMI	340		0.057		0.045		0.112
<25	237	79.3		70.9		90.7	
25~30	84	89.3		64.3		92.9	
>30	19	84.2		78.9		100	

BMI, Body Mass Index; N, number of patients.

Diagnostic efficiency of US and mammography in calcification

As displayed in table 3, the diagnostic sensitivity of ultrasound in different initial symptom was similar (P=0.455). The diagnostic sensitivity of mammography in the initial symptom with calcification was 80.2% and without calcification was 64.6% (P=0.004). Notably, the diagnostic efficiency of ultrasound combined with mammography in different initial symptom was similar (P=0.409), with the sensitivity of 93.7% and 90.8% for the presence or absence of calcification, respectively, and was higher than single examination with ultrasound and mammography.

Table 3. Diagnostic efficiency of ultrasound combined with mammography in breast cancer with different initial symptom.

	N	Ultra-sound (%)	P value	Mammog-raphy (%)	P value	Combined inspection (%)	P value
Initial symptom	340		0.455		0.004		0.409
With calcification	111	82.9		80.2		93.7	
Without calcification	229	81.7		64.6		90.8	

N, number of patients.

Diagnostic efficiency of US and mammography in different histological grade

It was displayed in table 4 that, the diagnostic sensitivity of ultrasound and mammography in different histological grade was similar (P=0.304 and P=0.522). Notably, the diagnostic efficiency of ultrasound combined with mammography in different initial symptom was also similar (P=0.051), with the sensitivity of 86.7%, 95.0% and 95.3%, respectively, and was higher than single examination with ultrasound and mammography.

Diagnostic efficiency of US and mammography in different HR and HER2 status

As displayed in Table 5, the diagnostic sensitivity

[Downloaded from ijrr.com on 2026-11-24]

[DOI: 10.61186/ijrr.22.1.49]

of ultrasound and mammography in different HR status was similar (P=0.349 and P=1.000). Notably, the diagnostic efficiency of ultrasound combined with mammography in different initial symptom was also similar (P=0.123), with the sensitivity of 92.0% and 95.8%, respectively, and was higher than single examination with ultrasound and mammography.

The diagnostic sensitivity of ultrasound in HER2 positive patients was 91.3%, and in HER2 negative patients was 78.6% (P=0.007). The diagnostic sensitivity of mammography in HER2 positive patients was 82.6%, and in HER2 negative patients was 64.9% (P=0.001). Of note, the diagnostic efficiency of ultrasound combined with mammography in HER2 positive patients was 98.9%, and in HER2 negative patients was 89.1% (P=0.002), and was higher than single ultrasound and mammography.

Table 4. Diagnostic efficiency of ultrasound combined with mammography in breast cancer with different histological grade

	N	Ultra-sound (%)	P value	Mammog-raphy (%)	P value	Combined inspection (%)	P value
Histological grade	313		0.304		0.522		0.051
Grade I	90	77.8		66.7		86.7	
Grade II	159	83.0		71.7		95.0	
Grade III	64	87.5		75.0		95.3	

N, number of patients.

Table 5. Diagnostic efficiency of ultrasound combined with mammography in breast cancer with different HR and HER2 status.

	N	Ultra-sound (%)	P value	Mammog-raphy (%)	P value	Combined inspection (%)	P value
HR	340		0.349		1.000		0.123
Positive	244	80.7		69.7		92.0	
Negative	96	85.4		69.8		95.8	
HER2	340		0.007		0.001		0.002
Positive	92	91.3		82.6		98.9	
Negative	248	78.6		64.9		89.1	

N, number of patients. HR, hormone receptor; HER2, human epidermal growth factor receptor 2.

Diagnostic efficiency of US and mammography in different Ki-67 positive rate

As displayed in table 6, the diagnostic sensitivity of ultrasound in Ki-67 positive rate >20 was 89.6%, and in Ki-67 positive rate ≤20 was 77.1% (P=0.004). The diagnostic sensitivity of mammography in different Ki-67 positive rate was similar (P=0.278). Notably, the diagnostic efficiency of ultrasound combined with mammography in Ki-67 positive rate >20 was 97.8%, and in Ki-67 positive rate ≤20 was 87.8% (P=0.001), and was higher than single examination with ultrasound and mammography.

Table 6. Diagnostic efficiency of ultrasound combined with mammography in breast cancer with different Ki-67 positive rate

	N	Ultrasound (%)	P value	Mammog-raphy (%)	P value	Combined inspection (%)	P value
Ki67	340		0.004		0.278		0.001
>20	135	89.6		73.3		97.8	
≤20	205	77.1		67.3		87.8	

N, number of patients.

Diagnostic efficiency of US and mammography in different molecular subtyping

As displayed in Table 7, the diagnostic sensitivity of ultrasound in HR+HER2- was 77.2%, in HR+HER2+ was 94.1%, in HR-HER2+ was 87.8% and in HR-HER2 - was 83.6% (P=0.023). The diagnostic sensitivity of mammography in HR+HER2- was 65.8%, in HR+HER2+ was 84.3%, in HR-HER2+ was 80.5% and in HR-HER2- was 61.8% (P=0.013). Notably, the diagnostic efficiency of ultrasound combined with mammography in HR+HER2- was 87.6%, in HR+HER2+ was 100%, in HR-HER2+ was 97.6% and in HR-HER2- was 94.5% (P=0.013), and was higher than single examination with ultrasound and mammography.

Table 7. Diagnostic efficiency of US and mammography in breast cancer with different molecular subtyping.

	N	Ultra-sound (%)	P value	Mammog-raphy (%)	P value	Combined inspection (%)	P value
Molecular subtyping	340		0.023		0.013		0.006
HR+HER2-	193	77.2		65.8		87.6	
HR+HER2+	51	94.1		84.3		100	
HR-HER2+	41	87.8		80.5		97.6	
HR-HER2-	55	83.6		61.8		94.5	

N, number of patients. HR, hormone receptor; HER2, human epidermal growth factor receptor 2.

DISCUSSION

In recent years, the incidence of breast cancer has gradually increased, posing a great threat to the health of females. Breast cancer at the early stage lacks typical clinical symptoms and signs [20]. Therefore, early diagnosis and treatment is essential for the improvement of the survival rate and quality of life of patients.

In the screening of breast cancer, molybdenum is the preferred imaging method, with certain advantages in the development of burr signs and calcification points, especially for the shrunk breast with high fat content, in which molybdenum development is clearer [21]. Molybdenum can also leave a clear image, which is conducive to regular follow-up [22]. However, the missed diagnosis rate of molybdenum target is high, especially in the cases with the presence of benign and malignant lesions. It is often difficult to distinguish malignant lesions, and the nipple, areola region, glandular tail, and deep lesions are easily missed [23].

Color Doppler ultrasound imaging based on the acoustic impedance difference of various tissues, with clear image anatomical level, can clearly display the subcutaneous breast gland, each layer of internal microstructure and mass boundaries, internal echo characteristics [24]. At the same time, it clearly shows

[Downloaded from ijrr.com on 2026-11-24]

[DOI: 10.61186/ijrr.22.1.49]

the blood flow in the breast mass and the condition of the axillary lymph nodes, can observe the elasticity and activity of the lesion, and effectively distinguishes and diagnoses the cystic and solid nature of the mass, and is an important imaging method for early screening of breast cancer [25]. However, in clinical practice, it is found that the diagnosis of micro-calcification foci by color Doppler ultrasound was not characteristic, and it is easy to misdiagnose or miss diagnosis [26].

In this study, the results indicated that the diagnostic sensitivity of ultrasound in breast cancer with different BMI, initial symptom, histological grade, and HR status was similar (tables 2-5). However, the diagnostic sensitivity of ultrasound in age ≥50 years was higher relative to that in age <50 years (table 2). The diagnostic sensitivity of ultrasound in HER2 positive patients was higher compared to that in HER2 negative patients (table 5). The diagnostic sensitivity of ultrasound in Ki-67 positive rate >20 was higher than that in Ki-67 positive rate ≤20 (table 6). Moreover, in different molecular subtypes, the diagnostic sensitivity of ultrasound in HR+HER2+ was the highest, followed by HR-HER2+, HR-HER2- and HR+HER2- (table 7). Consistently, it has been reported that patients with higher HER2 positive and Ki-67 positive expression have higher peak intensity in ultrasound, and more abundant intrafocal enhancement [27, 28]. In addition, it has been demonstrated that ultrasound measurements are more strongly correlated with HR+/HER2+ subtype than HR-HER2+ and HR-HER2- subtypes [29].

Our study also revealed that the diagnostic sensitivity of mammography in breast cancer with different histological grade, HR status and Ki67 positive rate was similar (table 4-6). However, the diagnostic sensitivity of mammography in age ≥50 years was higher compared to that in age <50 years (table 2). The diagnostic sensitivity of mammography in BMI >30 was higher than that in BMI <25 and BMI 25-30 (table 2). The diagnostic sensitivity of mammography in the initial symptom with calcification was higher than that without calcification (table 3). The diagnostic sensitivity of mammography in HER2 positive patients was higher compared to that in HER2 negative patients (table 5). Moreover, in different molecular subtypes, the diagnostic sensitivity of mammography in HR+HER2+ was the highest, followed by HR-HER2+, HR-HER2- and HR+HER2- (table 7). Consistently, it has been reported that mammography has a high diagnostic sensitivity in the calcification symptom of breast cancer patients [30]. Similarly, mammography has been shown to have a high correlation with HR+HER2+ subtype [31].

Compared with the single examination with mammography, ultrasound compared with mammography increases the detection rate of disease and improves the detection sensitivity [32]. Notably, our study also showed that the diagnostic efficiency of ultrasound combined with mammography in different age, BMI, initial symptom, histological grade and HR status was similar (table 2-5). At the same time, the diagnostic efficiency of ultrasound combined with mammography in HER2 positive patients was higher than that in HER2 negative patients (table 5). The diagnostic sensitivity of ultrasound in Ki-67 positive rate >20 was higher than that in Ki-67 positive rate ≤20 (table 6). Moreover, in different molecular subtypes, the diagnostic sensitivity of ultrasound in HR+HER2+ was the highest, followed by HR-HER2+, HR-HER2- and HR+HER2- (table 7). In addition, the diagnostic efficiency of ultrasound combined with mammography was higher than single ultrasound and mammography, which was in line with previous studies [33, 34].

In conclusion, ultrasound combined with mammography showed high diagnostic efficiency in breast cancer with different clinical and pathological features, and is worthy for clinical promotion.

ACKNOWLEDGMENT

Not applicable.

***Funding*:** None.

***Conflicts of interests*:** The authors have no conflicts of interest to declare.

***Ethical consideration*:** This study was approved by The Second Affiliated Hospital Zhejiang University School of Medicine (approval number: LLSC-KYKT-2023-0053-A, 2023).

***Author contribution*:** Y.X. and Y.C.; conceptualized the study. J.Q. and F.W.; collected and analyzed the data. Y.X.; wrote the first version of the manuscript and all authors revised and approved the final version of the manuscript.

REFERENCES

1. Zhang YN, Xia KR, Li CY, *et al.* (2021) Review of breast cancer pathologigcal image processing. *Biomed Res Int*, ***2021****: 1994764.*
2. Eshaghi M (2020) The effect of pain management on pain reduction in women with breast cancer. *SJMSHM, **2**(2) :1-5.*
3. Murali B, Durbin L, Vijaykumar S*, et al.* (2022) Treatment of HR+/HER2- breast cancer in urban mainland China: results from the CancerMPact Survey 2019. *Breast Cancer Res Treat*, ***195****(3): 441-51.*
4. Reid S, Haddad D, Tezak A*, et al.* (2021) Impact of molecular subtype and race on HR+, HER2- breast cancer survival. *Breast Cancer Res Treat*, ***189****(3): 845-52.*
5. Coughlin SS (2019) Epidemiology of breast cancer in women. *Adv Exp Med Biol*, ***1152****: 9-29.*
6. Peairs KS, Choi Y, Stewart RW*, et al.* (2017) Screening for breast cancer. *Semin Oncol*, ***44****(1): 60-72.*
7. Johnson RH, Anders CK, Litton JK*, et al.* (2018) Breast cancer in adolescents and young adults. *Pediatr Blood Cancer*, ***65****(12): e27397.*
8. Harbeck N and Gnant M (2017) Breast cancer. *Lancet (London, England)*, ***389****(10074): 1134-50.*

[Downloaded from ijrr.com on 2026-11-24]

[DOI: 10.61186/ijrr.22.1.49]

9. Chen L, Jiang N, Wu Y (2020) Application and analysis of biomedical imaging technology in early diagnosis of breast cancer. *Methods Mol Biol*, ***2204****: 63-73.*
10. Sood R, Rositch AF, Shakoor D*, et al.* (2019) Ultrasound for breast cancer detection globally: A systematic review and meta-analysis. *J Glob Oncol*, ***5****: 1-17.*
11. Ozmen N, Dapp R, Zapf M*, et al.* (2015) Comparing different ultrasound imaging methods for breast cancer detection. *IEEE Transactions on Ultrasonics, Ferroelectrics, and Frequency Control*, ***62****(4): 637-46.*
12. Fiorica JV (2016) Breast cancer screening, mammography, and other modalities. *Clin Obstet Gynecol*, ***59****(4): 688-709.*
13. Helvie MA and Bevers TB (2018) Screening mammography for average-risk women: The controversy and nccn's position. *Journal of the National Comprehensive Cancer Network : JNCCN*, ***16****(11): 1398-404.*
14. van den Ende C, Oordt-Speets AM, Vroling H*, et al.* (2017) Benefits and harms of breast cancer screening with mammography in women aged 40-49 years: A systematic review. *International Journal of Cancer*, ***141****(7): 1295-306.*
15. Wang Y, Li Y, Song Y*, et al.* (2022) Comparison of ultrasound and mammography for early diagnosis of breast cancer among Chinese women with suspected breast lesions: A prospective trial. *Thoracic cancer*, ***13****(22): 3145-51.*
16. Ohnuki K, Tohno E, Tsunoda H*, et al.* (2021) Overall assessment system of combined mammography and ultrasound for breast cancer screening in Japan. *Breast Cancer*, ***28****(2): 254-62.*
17. Lehman CD, Arao RF, Sprague BL*, et al.* (2017) National performance benchmarks for modern screening digital mammography: Update from the breast cancer surveillance consortium. *Radiology*, ***283****(1): 49-58.*
18. Conant EF, Barlow WE, Herschorn SD*, et al.* (2019) Association of digital breast tomosynthesis vs digital mammography with cancer detection and recall rates by age and breast density. *JAMA Oncology*, ***5****(5): 635-42.*
19. Radiology ACo, D'Orsi CJ, Sickles EA*, et al.* (2013)ACR BI-RADS Atlas: breast imaging reporting and data system; mammography, ultrasound, magnetic resonance imaging, follow-up and outcome monitoring, data dictionary. ACR, American College of Radiology,
20. Barzaman K, Karami J, Zarei Z*, et al.* (2020) Breast cancer: Biology, biomarkers, and treatments. *Int Immunopharmacol*, ***84****: 106535.*
21. He H, Zhang G, Zhou H*, et al.* (2022) Differential efficacy of b-ultrasound combined with molybdenum target detection mode for breast cancer staging and correlation of blood flow parameters with IGF-1 and IGF-2 expression level and prognosis. *Contrast Media Mol Imaging*, ***2022****: 9198626.*
22. Hu Y, Zhang Y, Cheng J (2019) Diagnostic value of molybdenum target combined with DCE-MRI in different types of breast cancer. *Oncol Lett*, ***18****(4): 4056-63.*
23. Sechopoulos I, Teuwen J, Mann R (2021) Artificial intelligence for breast cancer detection in mammography and digital breast tomosynthesis: State of the art. *Semin Cancer Biol*, ***72****: 214-25.*
24. Lee CU, Hesley GK, Uthamaraj S*, et al.* (2021) Using ultrasound color doppler twinkling to identify biopsy markers in the breast and axilla. *Ultrasound Med Biol*, ***47****(11): 3122-34.*
25. Zhou BY, Wang LF, Yin HH*, et al.* (2021) Decoding the molecular subtypes of breast cancer seen on multimodal ultrasound images using an assembled convolutional neural network model: A prospective and multicentre study. *EBioMedicine*, ***74****: 103684.*
26. Yeo SH, Kim GR, Lee SH*, et al.* (2018) Comparison of ultrasound elastography and color doppler ultrasonography for distinguishing small triple-negative breast cancer from fibroadenoma. *J Ultrasound Med*, ***37****(9): 2135-46.*
27. Zhou J, Jin AQ, Zhou SC*, et al.* (2021) Application of preoperative ultrasound features combined with clinical factors in predicting HER2-positive subtype (non-luminal) breast cancer. *BMC Med Imaging*, ***21****(1): 184.*
28. Liu J, Wang X, Hu M*, et al.* (2022) Development of an ultrasound-based radiomics nomogram to preoperatively predict Ki-67 expression level in patients with breast cancer. *Front Oncol*, ***12****: 963925.*
29. Graeser M, Schrading S, Gluz O*, et al.* (2021) Magnetic resonance imaging and ultrasound for prediction of residual tumor size in early breast cancer within the ADAPT subtrials. *Breast Cancer Res*, ***23****(1): 36.*
30. Mackenzie A, Warren LM, Wallis MG*, et al.* (2016) Breast cancer detection rates using four different types of mammography detectors. *Eur Radiol*, ***26****(3): 874-83.*
31. Um E, Kang JW, Lee S*, et al.* (2018) Comparing accuracy of mammography and magnetic resonance imaging for residual calcified lesions in breast cancer patients undergoing neoadjuvant systemic therapy. *Clin Breast Cancer*, ***18****(5): e1087-e91.*
32. Ultrasound as an Adjunct to Mammography for Breast Cancer Screening(2016): A Health Technology Assessment. *Ontario Health Technology Assessment Series*, ***16****(15): 1-71.*
33. Ha SM, Chang JM, Lee SH*, et al.* (2021) Detection of contralateral breast cancer using diffusion-weighted magnetic resonance imaging in women with newly diagnosed breast cancer: Comparison with combined mammography and whole-breast ultrasound. *Korean J Radiol*, ***22****(6): 867-79.*
34. Devkota R, Bhattarai M, Adhikari BB*, et al.* (2021) Evaluation of breast mass by mammography and ultrasonography with histopathological correlation. *J Nepal Health Res Counc*, ***19****(3): 487-93.*

[Downloaded from ijrr.com on 2026-11-24]

[DOI: 10.61186/ijrr.22.1.49]