Volume 22, No 1 | International Journal of Radiation Research, January 2024

Assessment of the effectiveness of neoadjuvant chemotherapy for rectal cancer by MRI and PETCT: a meta-analysis

P. Zhao[1#], Y. Xu[1#], C. Xie[1*], M. Zhan[1,2], Y. Qian[1], Z. Gao[1]

[1]Department of Radiology, Affiliated Xiaoshan Hospital, Hangzhou Normal University, Hanghzou, Zhejiang, 311200, China

[2]Department of Radiology, Hangzhou Ninth People's Hospital, Hangzhou, Zhejiang, 311200, China

► ***Original article***

Corresponding author:
Chunmei Xie, Ph.D.,
E-mail: *XcmandTT@163.com*

Received: June 2023
Final revised: August 2023
Accepted: September 2023

Int. J. Radiat. Res., January 2024; 22(1): 85-90

DOI: 10.52547/ijrr.21.1.12

Keywords: *Magnetic resonance imaging, positron emission tomography computed tomography, rectal neoplasms, meta-analysis, neoadjuvant therapy.*

#these authors have the same contribution

ABSTRACT

Background: A meta-analysis of the effectiveness of Magnetic Resonance Imaging (MRI) and Positron Emission Tomography Computed Tomography (PETCT) in assessing the effects of neoadjuvant chemotherapy (nCRT) for Rectal cancer (RC) was performed to provide a reference for better clinical assessment in the future. ***Materials and Methods***: Relevant literature on the assessment of the effects of MRI and PETCT on RC nCRT was screened through PubMed, Cochrane, EMBAS and other literature databases, and the final literature for analysis was determined after cross-screening by two study team members. Review Manager 5.3 software was used to assess the quality of the literature and extract relevant information such as authors, year of publication, and results, and meta-analysis was performed using Stata 15.1 software. ***Results:*** Through screening, six references were finally included, totaling 396 cases of study subjects, and the results of literature quality evaluation showed that the selected literature was of high quality and had some reference value. Meta-analysis revealed a sensitivity of 0.76 and a specificity of 0.74 for the final combination of MRI; the sensitivity and specificity of the final combined PETCT were 0.78 and 0.71, respectively. Deek's test showed P>0.05 for both MRI and PETCT, with no publication bias. ***Conclusion:*** MRI and PETCT are similarly effective in predicting the effect of RC nCRT.

INTRODUCTION

Rectal cancer (RC) is one of the most common gastrointestinal malignancies worldwide [1]. Most patients are at a locally advanced stage at the time of initial diagnosis. Progressive RC is usually treated with neoadjuvant chemotherapy (nCRT) in combination with total rectal mesenteric resection [2, 3]. After nCRT, approximately 50-60% of patients descend and 15-27% experience pathological complete remission (pCR) [4-7]. In addition, patients who achieve a complete clinical response after nCRT may receive a reserved treatment called a watch-and-wait strategy as an alternative to surgery [8-10]. Therefore, accurate preoperative evaluation of nCRT and correct prognosis can ensure more individualized as well as more effective treatment.

Magnetic Resonance Imaging (MRI) is now widely used for the diagnosis, preoperative staging, and outcome evaluation of RC [11, 12]. Conventional MRI sequences can detect morphological changes, but there are limitations in their ability to differentiate between residual tumor and post-treatment fibrosis in the assessment of treatment response after nCRT. While various other parameters of MRI, such as MRI-based tumor regression grading, tumor perfusion index from dynamic enhancement MRI, and apparent diffusion coefficient (ADC) based on diffusion-weighted images (DWI), have been investigated to assess the response of RC patients after nCRT [13].

Currently, rectal Positron Emission Tomography Computed Tomography (PETCT) imaging is increasingly used in the assessment of treatment response after nCRT for RC [14-16]. Since metabolic changes in tumor cells may precede morphological anatomical changes, PETCT, as a functional metabolic imaging modality, can detect the metabolic changes of tumor cells after nCRT as early as possible.

Currently, there is no accurate protocol for determining the effectiveness of nCRT in the clinic, so there is no way to accurately know the recovery of RC patients in the clinic. Although both CT and MRI have been shown to have significant effects in the assessment of RC, the progress of their application after nCRT is still controversial. Therefore, by analyzing the role of MRI versus PETCT in assessing the efficacy of RC chemotherapy, this study can provide more help for the future treatment of RC.

[Downloaded from ijrr.com on 2026-11-24]

[DOI: 10.61186/ijrr.22.1.85]

MATERIALS AND METHODS

Inclusion and exclusion criteria

Inclusion criteria: (1) patients diagnosed with locally progressive RC; (2) monitoring the imaging response before and after nCRT with MRI and PETCT; (3) using postoperative pathology as the gold standard; (4) study results describing the pCR or tumor regression grade (TRG); (5) the ability to obtain true positive (TP), false positive (FP), false negative (FN) and true negative (TN) data; (6) published in English; (7) the type of publication is a treatise.

Exclusion criteria: (1) case reports, reviews, conference abstracts and correspondence; (2) studies with animal models; (3) documents that cannot be extracted directly or indirectly from the four-compartment table; (4) duplicate publication.

Article search strategy

PubMed, Cochrane, EMBASE, and CNKI literature databases were searched from the earliest searchable date to June 1, 2023. Languages are limited to English and Chinese. A secondary search for references in the literature was conducted by combining subject and free word search methods. English search terms: MRI, PETCT, rectal neoplasms, rectal cancer, rectal carcinoma, neoadjuvant chemotherapy, and preoperative.

Literature screening and data extraction

Literature screening and data extraction were performed independently by two researchers, and any disagreements were resolved through discussion. First, the titles and abstracts of the articles were reviewed to exclude irrelevant articles, and then the full articles were read to determine if they were included in the study. Relevant information needed to be extracted for each study, the first author, region, year of publication, study method, four-grid table data (TP, FP, FN, TN), sample size, patient gender, mean age, age range, examination method and pathological assessment criteria were extracted for this study. If data from the four-cell table were incomplete, the original authors were contacted to obtain as complete data as possible, and if still unavailable, they were excluded from the study.

Literature quality evaluation

To assess the methodological quality and applicability of the included literature, the QUADAS-2 [17] diagnostic test accuracy quality assessment tool and Review Manager 5.3 software were used to generate a literature quality assessment form for quality assessment. Each eligible study was evaluated independently by two investigators and discrepancies were resolved through discussion.

Imaging Methods for MRI and PETCT

MRI: Uses specific magnetic resonance techniques to display vascular and blood flow signals, including T1-weighted images (T1WI), T2-weighted images (T2WI), proton density-weighted images (PDWI), and diffusion-weighted images (DWI), etc. PETCT: Utilizes positron-ribonucleotide labeling of glucose and other metabolites of the human body, and is injected intravenously by an The instrument detects metabolic changes in a localized tissue of the body.

Data statistics and analysis

All original studies were statistically analyzed using Stata 15.1 software, and forest plots of sensitivity and specificity were plotted separately for MRI and PETCT. The Receiver operating characteristic (ROC) curves for MRI and PETCT were then plotted, where sensitivity was the vertical coordinate of the ROC curve and specificity was the horizontal coordinate, with each data point representing a study and the area under the curve (AUC) serving as the final comparator. Heterogeneity was tested for each included original study using a chi-square test. When the final I^2 value is greater than 50%, the random effects model is chosen; when it is less than 50%, the fixed effects model is used. Deek tests were performed on all included original studies using Stata 12.0 software to determine whether publication bias existed in each included original trial, with $P<0.05$ indicating publication bias.

RESULTS

Literature search results

Initially, 2226 relevant literatures were screened, which eventually included 6 literatures [18-23] (figure 1). A total of 396 patients (277 men and 119 women), aged from 28 to 82 years, were included in the study. The basic characteristics of the included literature are shown in Table 1 and 2.

Quality evaluation

The quality of the literature is evaluated in detail in Figure 2, where two papers were prospectively designed (22, 23) and four were retrospective [18-21]. Overall, the quality of the included literature is generally high and has some reference value.

[Downloaded from ijrr.com on 2026-11-24]

[DOI: 10.61186/ijrr.22.1.85]

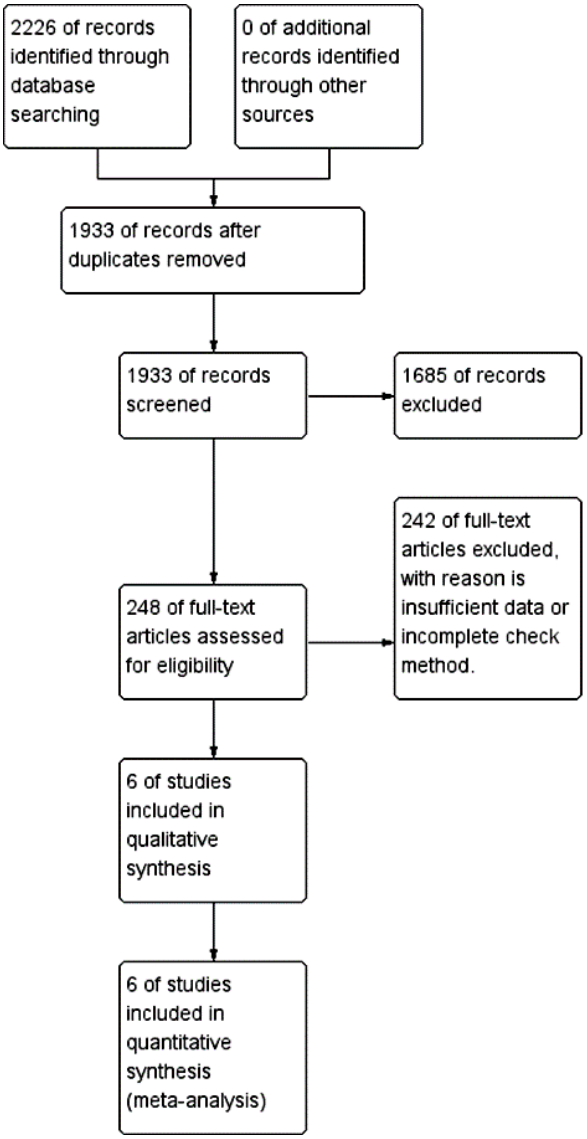

Figure 1. Flow chart of literature screening.

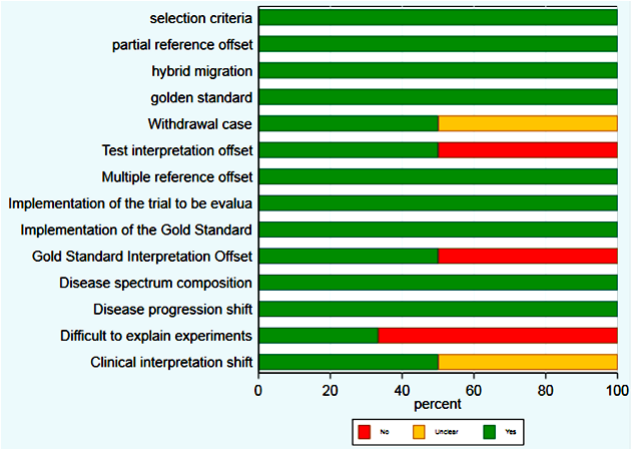

Figure 2. Risk of bias map for the included studies, the quality of the included literature is generally high and has some reference value.

Table 2. Instrument details.

author	MRI Model	MRI parameters	PETCT Model	PETCT parameters	Pathological assessment criteria
Giannini *et al.* [19]	GE 1.5T	ADC	Philips, PET-CT Gemini TF	SUV parameters	pCR
Aiba *et al.* [20]	1.5T/ 3.0T	MRI-TV	Siemens, Biography 16	SUV max	pCR
Huh *et al.* [21]	Siemens 3.0T	MRI TNM staging	GE, Discovery LS FDG-PETCT	SUVmax	pCR
Herrmann *et al.* [22]	GE 1.5T	MRI volume	Siemens, a hybrid TOF PETCT	SUV volume parameters	TRG
Uslu-Beşli *et al.* [23]	GE 1.5T	ADC	Siemens, a hybrid TOF PETCT	SUV max	TRG
Petrillo *et al.* [24]	Siemens 1.5T	SIS	GE, DST 600 PETCT	SUVmax	TRG/pCR

Note: Magnetic Resonance Imaging (MRI), Positron Emission Tomography Computed Tomography (PETCT), Television (TV), Tumor Node Metastasis (TNM), Apparent diffusion confficient (ADC), Signal intensities (SIS), Standardized uptake value (SUV), pathological complete remission (pCR), Tumor regression grade (TRG).

Table 1. Basic Characteristics of Literature.

Author	Years	Country	Types of Research	n	Male / Female	Age	Radiotherapy	Chemotherapy
Giannini [19]	2019	Italy	Retrospective	52	35/17	68(60-74)	not have	Standard CRT treatment with RectumSIB program
Aiba [20]	2014	Japan	Retrospective	40	32/8	56(28–76)	not have	XELOX (oxaliplatin plus cilostat), SOX (oxaliplatin plus S-1), or FOLFOX (oxaliplatin, formyltetrahydrofolate, and fluorouracil); 2-4 months
Huh [21]	2015	Korea	Retrospective	181	128/53	66(28-82)	180 cGy/day, 25 doses over 5 weeks; total dose 4,500 cGy	5-Fluorouracil (5-FU; 425 mg/m2/day), Calcium folinate (20 mg/m2/day)
Herrmann [22]	2011	Germany	Retrospective	28	20/8	61±10	Total dose 45.0 Gy	5-FU-based chemotherapy (250 mg/m2 body surface/day)
Uslu-Beşli [23]	2021	Turkey	Forward-looking	20	12/8	58(35-79)	1.8 Gy/day, 28 doses, total dose 50.4 Gy	Fluoropyrimidine; capecitabine 850 mg/m2 twice daily for 5 days
Petrillo [24]	2017	Italy	Forward-looking	75	50/25	62(44-77)	1.8Gy/day, 5 times per week, total dose 45Gy	Capecitabine 825 mg/m2 twice daily, 5 days a week for 5 weeks

[Downloaded from ijrr.com on 2026-11-24]

[DOI: 10.61186/ijrr.22.1.85]

Meta-analysis results

The final six original studies included had MRI sensitivities ranging from 0.38 to 0.93 and specificities ranging from 0.58 to 0.83, and the final combined sensitivity of MRI was 0.76 (95% CI, 0.58-0.88) and specificity was 0.74 (95% CI, 0.63-0.83). The sensitivity of PETCT ranged from 0.73 to 0.85 and the specificity from 0.64 to 0.82. The sensitivity and specificity of the final combined PETCT were 0.78 (95% CI, 0.71-0.84) and 0.71 (95% CI: 0.60-0.79), respectively. The forest map is shown in figure 6. The heterogeneity of diagnostic sensitivity and specificity was lower for MRI (I^2 =91.65%, and I^2 =83.83%) than for PETCT (I^2 =0% and I^2 =13.90%) (figures 3 and 4). Subsequently, the SROC curves of MRI and PETCT were plotted according to the results of each study, and it was seen that the AUC of MRI was 0.80, whereas the AUC of PETCT was 0.81, and both modalities had high AUCs, which indicated a high assessment accuracy (figures 5 and 6). Finally, the imaging images of a typical case are shown in figure 7, MRI T2WI axial image after RC nCRT show that the rectal mass is clearly regressed.

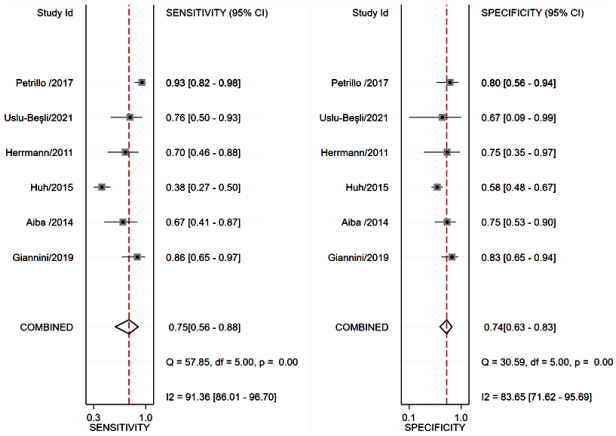

Figure 3. MRI forest plot of merge sensitivity and merge specificity for RC nCRT effect assessment, the combined MRI had a sensitivity of 0.76 and a specificity of 0.74.

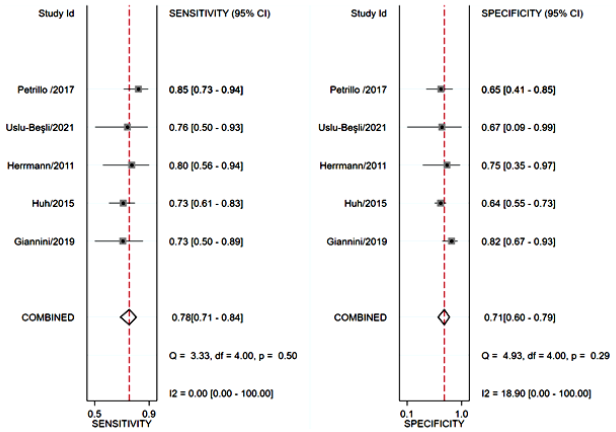

Figure 4. Forest plot of merge sensitivity and merge specificity of PETCT for RC nCRT effect assessment, the combined PETCT had a sensitivity of 0.78 and a specificity of 0.71.

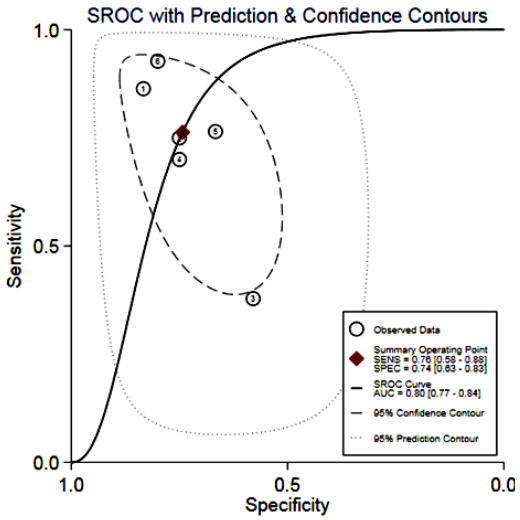

Figure 5. SROC curve of MRI on RC nCRT effect evaluation, with a sensitivity of 0.76, a specificity of 0.74, and an AUC of 0.80.

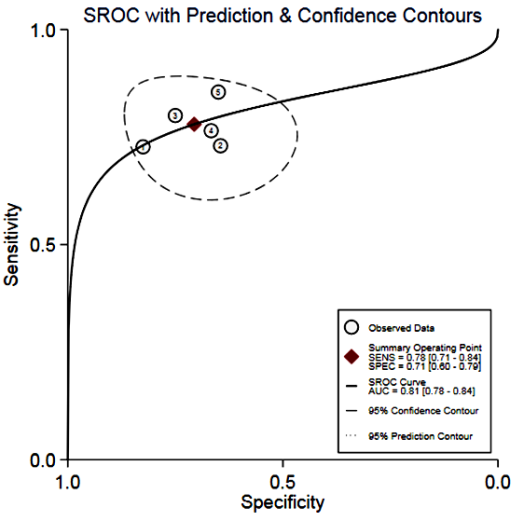

Figure 6. SROC curve of PETCT on RC nCRT effect evaluation, with a sensitivity of 0.78, a specificity of 0.71, and an AUC of 0.81.

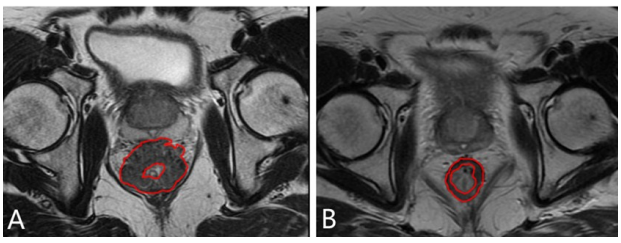

Figure 7. MRI images of a typical case. A: MRI T2WI axial image before RC nCRT; B: MRI T2WI axial image after RC nCRT: the rectal mass is clearly regressed. Areas of interest are shown in red.

Publication bias

The Deek's funnel plot for publication bias is shown in Figures 8 and 9. After Deek's test, the P values for MRI and PETCT were 0.21 and 0.27, respectively, which were both greater than 0.05, indicating that there was no publication bias in this study.

[Downloaded from ijrr.com on 2026-11-24]

[DOI: 10.61186/ijrr.22.1.85]

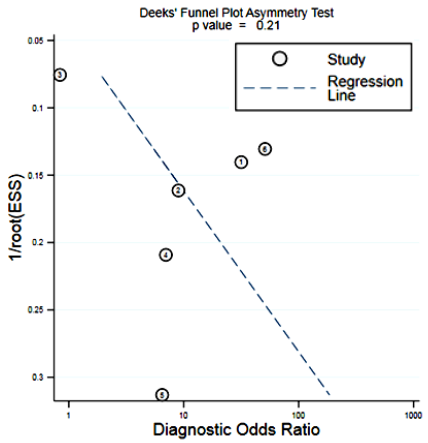

Figure 8. Deek's funnel plot for MRI assessment of the effect of neoadjuvant chemotherapy in rectal cancer, less bias.

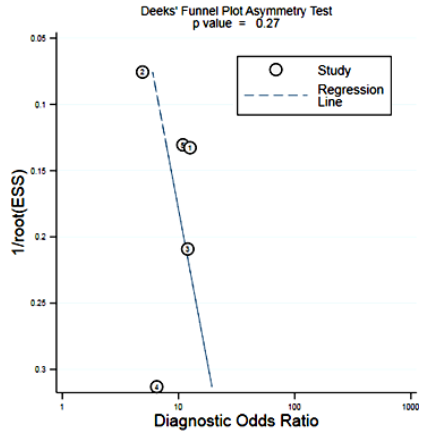

Figure 9. Deek's funnel plot for PETCT assessment of the effect of neoadjuvant chemotherapy in rectal cancer, less bias.

DISCUSSION

Non-surgical treatment (watch and wait strategy) for patients with cCR response was first proposed by Prof. Habr-Gama in 2004 [24]. Early prediction of outcomes after neoadjuvant therapy for RC can help clinicians provide personalized treatment, avoid overtreatment, and reduce recurrence and metastasis rates while preserving organ function.

CT and MRI are currently important examinations for RC nCRT effect assessment, but CT can only determine the tumor changes after nCRT by density and morphology. Conventional MRI can visualize tumor changes in multiple sequences, whereas functional MRI can further provide microscopic changes in tissue and quantitatively identify residual tumor and fibrosis [25]. MRI-based AI models can accurately predict treatment outcomes by reflecting the heterogeneity of many microscopic tissues, making MRI an important imaging tool for RC nCRT efficacy assessment [26].

PETCT determines tissue metabolic activity by high uptake of 18F-FDG in tumor tissue, which is usually highly correlated with tumor proliferation rate and malignant behavior, while providing local anatomical details with the help of CT imaging, a novel examination combining anatomical and functional imaging. It is currently used for preoperative staging by many institutions both nationally and internationally [27].

This study included 6 references, and finally concluded that the pooled sensitivity of MRI (78%) was slightly lower than that of PETCT (76%), the pooled specificity of PETCT (71%) was slightly lower than that of PETCT (74%), and the SROC of PETCT area under the curve was 0.81 for PETCT and 0.80 for MRI, suggesting that MRI and PETCT are similarly effective in predicting the effect of RC nCRT and that the two may play complementary roles in prediction. In previous studies, we can also see that both MRI and PETCT also have important clinical guidance for the clinical evaluation of tumors such as gastric cancer and esophageal cancer [28, 29, 30], which is similar to our viewpoint, indicating that both MRI and PETCT have important potential for application in malignant diseases.

The present study also has some limitations: (1) significant heterogeneity in the diagnostic sensitivity and specificity of MRI included in the study, different intervals between nCRT to MRI examinations, different follow-up times, and inconsistent scan device parameters, which may account for the high heterogeneity. However, further subgroup analysis was discarded due to the small sample size of each subgroup. (2) Fewer studies were included and more are needed for validation. (3) Unlike experimental studies, Meta-analysis is an observational study and quality control standards cannot be fully standardized.

CONCLUSION

MRI and PETCT are similar in predicting the effect of RC nCRT, and both can provide an objective basis for more accurate clinical assessment of pathological remission of RC after nCRT, thus providing a more reliable prognosis for the rehabilitation of RC patients.

***Ethical Approval*:** Not applicable.
***Consent to Publish*:** All authors gave final approval of the version to be published.
***Competing Interests*:** The authors report no conflict of interest.
***Author contributions*:** Panfeng Zhao and Yisheng Xu conceived and designed the project, and wrote the paper. Panfeng Zhao and Yisheng Xu generated the data. Chunmei Xie analyzed the data. Ming Zhan and Yile Qian modified the manuscript. All authors gave final approval of the version to be published, and agree to be accountable for all aspects of the work.
***Availability of data and materials*:** The data that support the findings of this study are available from

[Downloaded from ijrr.com on 2026-11-24]
[DOI: 10.61186/ijrr.22.1.85]

the corresponding author upon reasonable request.

***Funding*:** This study was supported by the Hangzhou Medical and Health Science and Technology Project (B20200234), Hangzhou Xiaoshan District Science and Technology Plan Guidance Project (2020318), Hangzhou Xiaoshan District Science and Technology Plan Guidance Project (2020324).

***Acknowledgements*:** Not applicable.

REFERENCES

1. Bray F, Ferlay J, Soerjomataram I, *et al.* (2020) Global cancer statistics 2018: GLOBORCN estimates of incidence and mortality worldwide for 36 cancers in 185 countries. *RC Cancer J Clin,* ***68****(6): 394-424*.
2. van Gijn W, Marijnen CA, Nagtegaal ID, *et al.* (2011) Preoperative radiotherapy combined with total mesorectal excision for resectable rectal cancer: 12-year follow-up of the multicentre, randomised controlled TME trial. *Lancet Oncol,* ***12:*** *575–82*.
3. Locally advanced rectal cancer: the past, present, and future. Semin Oncol (2020) Locally advanced rectal cancer: the past, present, and future. *Semin Oncol,* ***47:*** *85–92*.
4. Maas M, Nelemans PJ, Valentini V, *et al.* (2010) Long-term outcome in patients with a pathological complete response after chemoradiation for rectal cancer: a pooled analysis of individual patient data. *Lancet Oncol,* ***11****(9):* **835-44**.
5. Polanco PM, Mokdad AA, Zhu H, *et al.* (2018) Association of Adjuvant Chemotherapy With Overall Survival in Patients With Rectal Cancer and Pathologic Complete Response Following Neoadjuvant Chemotherapy and Resection. *JAMA Oncolm,* ***4****(7): 938-943*.
6. Fokas E, Schlenska-Lange A, Polat B, *et al.* German Rectal Cancer Study Group (2022) Chemoradiotherapy Plus Induction or Consolidation Chemotherapy as Total Neoadjuvant Therapy for Patients With Locally Advanced Rectal Cancer: Long-term Results of the CAO/ARO/AIO-12 Randomized Clinical Trial. *JAMA Oncol,* ***8****(1): e215445*.
7. Martin ST, Heneghan HM, Winter DC (2012) Systematic review and meta-analysis of outcomes following pathological complete response to neoadjuvant chemoradiotherapy for rectal cancer. *Br J Surg,* ***99****(7): 918-28*.
8. Smith JJ, Strombom P, Chow OS, *et al.* (2019) Assessment of a watch-and-wait strategy for rectal cancer in patients with a complete response after Neoadjuvant therapy. *JAMA Oncol,* ***5****(4): e185896*.
9. Dossa F, Chesney TR, Acuna SA, Baxter NN (2017) A watch-and-wait approach for locally advanced rectal cancer after a clinical complete response following neoadjuvant chemoradiation: a systematic review and meta-analysis. *Lancet Gastroenterol Hepatol,* ***2*** *(7): 501-513*.
10. van der Valk MJM, Hilling DE, Bastiaannet E, *et al.* IWWD Consortium (2018) Long-term outcomes of clinical complete responders after neoadjuvant treatment for rectal cancer in the International Watch & Wait Database (IWWD): an international multicentre registry study. *Lancet,* ***391****(10139): 2537-2545*.
11. Gollub MJ, Tong T, Weiser M, *et al.* (2017) Limited accuracy of DCE -MRI in identification of pathological complete responders after chemoradiotherapy treatment for rectal cancer. *Eur Radiol,* ***27****(4): 1605-1612*.
12. Beets-Tan RGH, Lambregts DMJ, Maas M, *et al.* (2018) Magnetic resonance imaging for clinical management of rectal cancer: Updated recommendations from the 2016 European Society of Gastrointestinal and Abdominal Radiology (ESGAR) consensus meeting. *Eur Radiol,* ***28****(4): 1465-1475*.
13. Kalisz KR, Enzerra MD, Paspulati RM (2019) MRI evaluation of the response of rectal cancer to neoadjuvant chemoradiation therapy. *Radiographics,* ***39****(2): 538-556*.
14. Uemura M, Ikeda M, Handa R, *et al.* (2021) The efficiency of 18F-FDG-PET/CT in the assessment of tumor response to preoperative chemoradiation therapy for locally recurrent rectal cancer. *BMC Cancer,* ***21****(1): 1132*.
15. López-López V, Abrisqueta Carrión J, *et al.* (2021) Assessing tumor response to neoadjuvant chemoradiation in rectal cancer with rectoscopy and 18F-FDG PET/CT: results from a prospective series. *Rev Esp Enferm Dig,* ***113****(5): 307-312*.
16. Chen SH, Miles K, Taylor SA, *et al.* (2021) FDG-PET/CT in colorectal cancer: potential for vascular-metabolic imaging to provide markers of prognosis. *Eur J Nucl Med Mol Imaging,* ***49****(1): 371-384*.
17. Whiting PF, Rutjes AW, Westwood ME, *et al.* QUADAS-2 Group (2011) QUADAS-2 Group. QUADAS-2: a revised tool for the quality assessment of diagnostic accuracy studies. *Ann Intern Med,* ***155****(8): 529-36*.
18. Giannini V, Mazzetti S, Bertotto I, *et al.* (2019) Predicting locally advanced rectal cancer response to neoadjuvant therapy with 18F-FDG PET and MRI radiomics features. *Eur J Nucl Med Mol Imaging,* ***46****(4): 878-888*.
19. Aiba T, Uehara K, Nihashi T, *et al.* (2014) MRI and FDG-PET for assessment of response to neoadjuvant chemotherapy in locally advanced rectal cancer. *Ann Surg Oncol,* ***21****(6): 1801-8*.
20. Huh JW, Kwon SY, Lee JH, Kim HR (2015) Comparison of restaging accuracy of repeat FDG-PET/CT with pelvic MRI after preoperative chemoradiation in patients with rectal cancer. *J Cancer Res Clin Oncol,* ***141****(2): 353-9*.
21. Herrmann K, Bundschuh RA, Rosenberg R, *et al.* (2011) Comparison of different SUV-based methods for response prediction to neoadjuvant radiochemotherapy in locally advanced rectal cancer by FDG-PET and MRI. *Mol Imaging Biol,* ***13****(5): 1011-9*.
22. Uslu-Beşli L, Mermut Ö, Yardimci AH, *et al.* (2021) Comparison of 18F-FDG PET/CT and DW-MRI in assessment of neoadjuvant radiochemotherapy response in locally advanced rectal cancer patients. *Rev Esp Med Nucl Imagen Mol (Engl Ed),* ***40****(1):* 19-29.
23. Petrillo A, Fusco R, Petrillo M, *et al.* (2017) Standardized index of shape (DCE-MRI) and standardized uptake value (PET/CT): Two quantitative approaches to discriminate chemo-radiotherapy locally advanced rectal cancer responders under a functional profile. *Oncotarget,* ***8****(5): 8143-8153*.
24. Habr-Gama A, São Julião GP, Vailati BB, *et al.* (2019) Organ preservation in cT2N0 rectal cancer after neoadjuvant chemoradiation therapy: The impact of radiation therapy dose-escalation and consolidation chemotherapy. *Ann Surg,* ***269****(1): 102-107*.
25. Wen L, Liu J, Hu P, *et al.* (2023) MRI-based radiomic models outperform radiologists in predicting pathological complete response to neoadjuvant chemoradiotherapy in locally advanced rectal cancer. *Acad Radiol,* ***S1076-6332(22)***00692-4.
26. Xiang Y, Li S, Wang H, *et al.* (2022) MRI-based radiomics to predict neoadjuvant chemoradiotherapy outcomes in locally advanced rectal cancer: A multicenter study. *Clin Transl Radiat Oncol,* ***38****: 175-182*.
27. Gülbahar Ateş S, Bilir Dilek G, Uçmak G (2023) Primary tumor heterogeneity on pretreatment 18F-FDG PET/CT to predict outcome in patients with rectal cancer who underwent surgery after neoadjuvant therapy. *Rev Esp Med Nucl Imagen Mol (Engl Ed),* ***S2253-8089(23)***00001-0.
28. Liu Y, Zheng D, Liu JJ, *et al.* (2019) Comparing PET/MRI with PET/CT for Pretreatment Staging of Gastric Cancer. *Gastroenterol Res Pract,* ***2019:*** *9564627*.
29. Eshaghi M (2020) The effect of pain management on pain reduction in women with breast cancer. *SJMSHM,* ***2****(2): 1-5*.

[Downloaded from ijrr.com on 2026-11-24]

[DOI: 10.61186/ijrr.22.1.85]