Volume 22, No 1 | International Journal of Radiation Research, January 2024

Application of two-dimensional color ultrasonography technology to evaluate the postoperative repair of massive rotator cuff tears after arthroscopic humeral insertion displacement treatment

S. Wu, Z. Yu*, W. Lin, W. Xu, Y. Luo, S. Guan

Department of Orthopedics, Zhangzhou Affiliated Hospital of Fujian Medical University, Zhangzhou 363000, Fujian Province, China

► ***Original article***

Corresponding author:
Zhenxing Yu, Ph.D.,
E-mail:
yzx830830830@163.com

Received: April 2023
Final revised: July 2023
Accepted: August 2023

Int. J. Radiat. Res., January 2024; 22(1): 125-130

DOI: 10.52547/ijrr.21.1.18

Keywords: *Color ultrasonography, arthroscopic surgery, massive rotator cuff tears.*

ABSTRACT

Background*:** To explore the value of two-dimensional color ultrasonography (US) in the evaluation of treatment effect of arthroscopic humeral insertion displacement for massive rotator cuff tears (MRCTs). ***Materials and Methods: From February 2021 to April 2022, 42 patients diagnosed as MRCTs by shoulder magnetic resonance imaging (MRI) were selected and separated into the control group (CG, n=21) and study group (SG, n=21). Patients in the SG received rotator cuff humeral insertion displacement and patients in the CG were treated with traditional suture bridge. The reliability of US imaging was examined and the clinical outcomes in two groups were compared. ***Results:*** The sensitivity and specificity of two-dimensional color ultrasonography reached 87.1% and 100% in detecting postoperative repair of MRCTs. Three months after surgery, compared with the CG, the university of California at Los Angeles shoulder rating scale (UCLA) scores in the SG were elevated (P<0.05), and the visual analogue scale (VAS) scores in the SG were declined (P<0.05). Degrees of external rotation, internal rotation, back extension and forward flexion of shoulder joint in both groups were increased after surgery, and those in the SG were higher relative to the CG (P<0.05). The retear rate of the SG was reduced compared with the CG (P<0.05). SG showed higher patient satisfaction rate compared with the CG (P<0.05). ***Conclusion:*** Two-dimensional color ultrasonography is a reliable approach to evaluate the repair of MRCT after arthroscopic rotator cuff internal displacement, which can reduce shoulder pain, improve patient life quality, and is valuable for promotion.

INTRODUCTION

In recent decades, the incidence of various acute and chronic injuries around the joint caused by sports injuries, traffic accident injuries and overwork injuries has elevated significantly, resulting in increasing patients with joint pain. Among them, the treatment of huge rotator cuff tears which causes shoulder joint pain is one of the challenging problems faced by orthopedic surgeons [1]. In recent years, the rapid development of sports medicine deepens our understanding of shoulder joint diseases [2]. The rotator cuff injury accounts for a large proportion of the previously considered "periarthritis of shoulder." At present, arthroscopic surgery has become the main treatment option [3]. However, for massive rotator cuff injuries with tear length >5 cm, it is difficult to repair because of severe tendon degeneration, large tear range, tendon retraction, extensive adhesion with surrounding tissues, and high incidence of re-tear [4]. Arthroscopic repair of massive rotator cuff tears (MRCTs) has undergone changes from single row, double row and suture bridge [5]. Previous studies have suggested that arthroscopic suture-bridge suture technique is a reasonable and effective treatment for massive rotator cuff tears [6]. In recent years, rotator cuff and humeral head insertion technique has been used to treat the massive rotator cuff. Five mm cartilage is removed from the humeral head articular surface edge, and contact surface between tendon and bone is increased [7]. At the same time, a single row of anchors is fixed, and the length of the massive rotator cuff is reduced, which can completely repair the rotator cuff and restore its globular structure [8]. In addition, it can reduce rotator cuff tension, reduce the probability of later rotator cuff tear, and improve the therapeutic effect [9]. However, literatures about this technique in the use of repairing MRCTs are rare.

The assessment of the rotator cuff via ultrasonography has been applied for more than two decades, while the results of US are not satisfactory at the initial stage. With the evolution of high-resolution ultrasound scanners, the quality of images in US has been significantly improved, which attracts increasing attention to the evaluation of US on the rotator cuff [10]. Compared with MRI, US is also reported to be reliable in the detection of full-

[Downloaded from ijrr.com on 2026-11-24]

[DOI: 10.61186/ijrr.22.1.125]

thickness and recurrent rotator cuff tears with high sensitivity and specificity [11]. Conventional two-dimensional (2D) sonography is a section imaging technology, and color Doppler ultrasound can provide real-time stereoscopic imaging on this basis.

In this study, we aimed to evaluate the effect of arthroscopic humeral insertion displacement in the treatment of massive rotator cuff tears based on two-dimensional color ultrasonography, which may provide novel clues for the management and evaluation of repair of MRCTs in clinical practice.

MATERIALS AND METHODS

General data

From February 2021 to April 2022, 42 patients with shoulder pain in our hospital diagnosed as massive rotator cuff tears by shoulder magnetic resonance imaging (MRI) examination received surgery. Inclusion criteria: (1) Severe shoulder pain that significantly affected work and daily life, or the upper limb abduction function was partially or completely lost; (2) shoulder MRI showed massive rotator cuff tear, and physical examination showed positive Neer sign, Hawkins sign, and Jobes sign. (3) Rotator cuff tear diameter >5 cm or rotator cuff tear containing 2 or more tendon tears. Exclusion criteria: (1) Partial rotator cuff tear or small rotator cuff tear. (2) Patients with a history of shoulder surgery and mental illness. (3) Rotator cuff injuries that cannot be repaired under the microscope. (4) Postoperative infection. (5) Shoulder osteoarthritis, rheumatoid arthritis. (6) Complicated with severe cervical disc protrusion. (7) Patients with deltoid atrophy or shoulder stiffness after stroke.

Totally 42 patients with massive rotator cuff tears were separated into both groups according to the random number table method. CG include 21 patients, with 10 males, and 11 females and. The mean age was 57.63±6.13 years (ranged from 45 to 76 years), and the disease duration ranged from 1 hour to 3 years. There were 6 cases with obvious trauma and 15 cases without obvious trauma. SG group included 9 males and 12 females and the average age of patients was 57.58±6.21 years (from 43 to 77 years), and the disease duration ranged from 1 hour to 5 years. There were 7 cases with obvious trauma and 14 cases without obvious trauma. There was no significant difference in preoperative general data between the two groups (P>0.05).

Surgical methods

Patients in the SG received rotator cuff humeral insertion displacement technique and patients in the CG accepted traditional suture bridge technique. The operation was performed by the same senior physician. The anatomical locations such as acromion, coracoid process, acromioclavicular joint, and scapular spine were marked before surgery.

General anesthesia combined with brachial plexus block anesthesia was performed. Patients were kept in healthy lateral decubitus position. The range of motion of the affected limb was checked, and manipulative reduction was performed for patients with limited mobility. A weight of 3 kg was loaded and traction was used to establish posterior, anterior, and lateral approaches to the shoulder joint to control blood pressure. Arthroscopy was performed via a posterior approach, with an anterior approach established and an anterolateral or posterolateral approach supplemented when exploring the subacromial space. The injury of the lower surface of the rotator cuff, the insertion of the rotator cuff, the long head tendon of the biceps brachii and the articular cartilage were investigated in the glenohumeral joint. Then, the subacromial space was entered, and the lateral or anterosuperior auxiliary approach was used to clear the subacromial capsule. After clear field of vision, the size, shape, retraction degree, acromial shape and impact degree of the rotator cuff tear were explored. A planer or basket forceps was used to clean and release the contractured tendon tissue, remove scar tissue and fatty degeneration tissue, and keep as much normal tendon tissue as possible. The tendon tension was probed while releasing. The tension and extensibility was explored via pull reduction of the torn rotator cuff.

In the SG, the bone bed was prepared at 5 mm of the humeral head articular cartilage surface (near the foot area). Then 2 to 3 internal anchor screws were placed at 45° anchor post Angle, and knotted and sutured through the rotator cuff tissue through mattress suture. An external Push-Lock anchor was used to fix the tail of the suture in the cortex lateral to the apex of the greater tuberosity of the humerus.

In the CG, the bone bed was prepared 3 mm lateral to the humeral head articular cartilage surface, and remaining operations were the same as those of the observation group. The normal saline in the joint was aspirated with a suction device before the incision was sutured in both groups, and no drainage tube was placed.

Postoperative treatment

Within 6 weeks, the affected shoulder was fixed with an external fixation brace, and the shoulder joint was maintained in a 30° abduction neutral position. During the protection period of 0-6 weeks, under the guidance of professional therapists, the patients performed isometric contraction of shoulder muscles, elbow and wrist flexion and extension exercises, and began to perform slow and strenuous open hand and fist movements at 800 to 1000 times a day, and conduct shrug exercises 30 to 40 times a day. Passive activities were conducted within tolerance, focusing

[Downloaded from ijrr.com on 2026-11-24]

[DOI: 10.61186/ijrr.22.1.125]

on forward flexion, abduction, and external rotation, and the passive range of motion of the shoulder was gradually increased, and the abduction of the affected limb was maintained below 90°. It was also possible to use the shoulder joint to perform circle movement and passive abduction when bending at 90°, once or twice a day for 10 min each time, and active abduction is prohibited. After 6 to 8 weeks, the full range of passive activities was gradually started. Under the condition of pain tolerance, the affected limb was passively lifted up and external rotation, and the passive lifting over the top or the rope were assisted, twice a day for 10 min each time. After 8 weeks, active abduction was started and shoulder joint muscle strength training was performed to gradually recover the function and muscle strength of the affected limb. Patients received reexamination 3 months after surgery, and two-dimensional color ultrasonography was performed to confirm postoperative repair.

Two-dimensional color ultrasonography

The 2D and color Doppler scanning was conducted to evaluate the postoperative repair three months after surgery using MyLab 50 US system (Esaote, Italy) with the frequency of 7.5-10-12 MHz. Patient arm was asked to maintain in internal rotation with minimal hyperextension to ensure comfort. The repair of rotator cuff was examined in coronal and sagittal axes, and the ultrasound beam depth was adjusted to adapt to differences in soft-tissue mass of each patient and ranged from 3 to 5 cm. The images were stored and transferred to BioPACS™ workstation (BIOPAC Systems Inc., US) for review. The US results were interpreted by 2 musculoskeletal radiologists (blinded) with 10 years of experience.

MRI detection

MRI was conducted and interpreted by 2 musculoskeletal radiologists blinded to the US results. The patient was maintained in supine position with shoulder in neutral position, the arm placed alongside, and the thumb pointing upwards. A Philips Achieva 3.0 T MRI scanner (Philips, the Netherlands) equipped with a shoulder array coil. The sequence included axial, coronal and sagittal. The parameters were set as follows: slice thickness: 4 mm, slice interval: 1 mm, the field of view: 220mm×220mm, the imaging matrix: 320×192-224, T2 weighted imaging (T2WI) and T1 weighted imaging (T1WI).

Observation index and clinical and US imaging evaluation

(1) Shoulder joint function: based on the University of California at Los Angeles shoulder rating scale (UCLA) [12], the assessment included anterior flexion strength, anterior flexion range of motion, shoulder function and other items. There are 35 points in total, and score positively reflects the function of shoulder joint.

(2) Pain evaluation: Visual analogue scale (VAS) was used for pain evaluation [13]. A walking scale of about 10 cm was used, with 0 ends representing no pain, 10 ends representing the most unbearable pain, and 1 cm representing 1 point. The score representing the degree of pain was determined by patients according to their subjective feelings.

(3) Degree of motion of shoulder joint: external rotation, internal rotation, back extension, and forward flexion of shoulder joint are measured by protractor.

(4) Retear rate was compared in both groups.

(5) The satisfaction rating scale was applied for the assessment of the patient satisfaction rate with the therapeutic effect during the follow-up at the end of 3 months after surgery.

(6) Two-dimensional color ultrasonography and MRI were performed to confirm postoperative repair, with MRI as the reference, and the diagnostic sensitivity and specificity of US for the detection of rotator cuff tears were determined. The intact repair was considered as the good continuity in band of tissue extending to the suture anchor.

Statistical analysis

SPSS 19.0 statistical software (SPSS Inc., Chicago, Illinois, USA) was applied for data analysis. t test was adopted for the analysis of measurement data and χ^2 test was adopted for counting data. $P<0.05$ indicated statistical significance.

RESULTS

Reliability of ultrasonography

As shown in table 1, the sensitivity and specificity of US was 87.1% and 100% respectively in the detection of postoperative repair of massive rotator cuff tears in all patients, with the MRI as the standard. The two-dimensional color ultrasonography result of a typical case with massive rotator cuff tears was shown in figure 1. The patient showed favorable postoperative repair (red arrow in figure 1C) following the rotator cuff humeral insertion displacement treatment. Consistently, the MRI images also indicated that the patient with massive rotator cuff tears showed incomplete structure in the perishoulder area before the surgery (figure 2A), and structural healing was observed three months after the surgery as shown in figure 2B.

Table 1. Sensitivity and specificity of US imaging for postoperative rotator cuff intact repair.

		MRI		Total (n, %)
		Positive	Negative	
US	Positive (n, %)	27 (87.1%)	0 (0.0%)	27 (64.3%)
	Negative (n, %)	4 (12.9%)	11 (100%)	15 (35.7%)
Total (n, %)		31 (100%)	11 (100%)	42 (100%)

MRI: magnetic resonance imaging; US: ultrasonography; n: number

[Downloaded from ijrr.com on 2026-11-24]

[DOI: 10.61186/ijrr.22.1.125]



Figure 1. Case example of a patient with rotator cuff tears **(A-B)** before and **(C)** after surgery under two-dimensional color ultrasonography. The injury site was marked with white rectangle, and red arrow indicated the injury was repaired after the surgery.



Figure 2. Representative MRI images of a patients with rotator cuff tear **(A)** before and **(B)** after the arthroscopic humeral insertion displacement treatment. The injury site was marked with red rectangle.

Retear rate in both groups based on ultrasonography

Three months after surgery, 12 cases in the CG showed rotator cuff retear (57.1%), while only 3 cases in the SG exhibited rotator cuff retear (14.3%). The results of ultrasonography showed that the retear rate of the SG was significantly reduced in comparison with the CG (P=0.0038, table 2).

Table 2. Retear rate in both groups.

Groups	n	Retear rate (n, %)
Control group	21	12 (57.1%)
Study group	21	3 (14.3%)
χ^2		8.4
P		0.0038

N: number.

UCLA scores in both groups

As displayed in figure 3, prior to surgery, no significant difference was discovered in UCLA scores between both groups (P>0.05). Three months following surgery, the UCLA scores were elevated in both groups, while those in the SG were significantly higher in comparison with the CG (P<0.05), suggesting that the rotator cuff humeral insertion displacement more effectively promoted the recovery of should joint function compared with the traditional suture bridge.

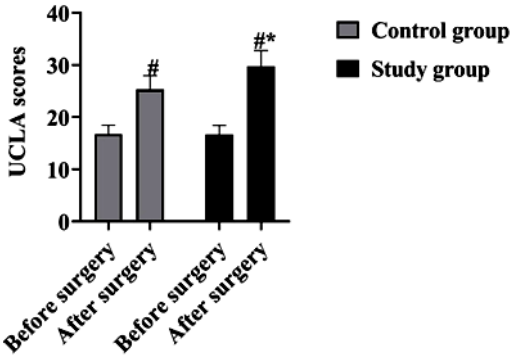

Figure 3. Shoulder joint function evaluated by UCLA scores in both groups before and after surgery. #P<0.05, compared with before surgery, *P<0.05, compared with the CG.

VAS scores in both groups

As displayed in figure 4, prior to surgery, no significant differences were discovered in VAS scores between both groups (P>0.05). After 3 months following surgery, the VAS scores in CG and SG were both reduced, and those in the SG were lower compared to the CG, which suggested that rotator cuff humeral insertion displacement showed better effects in alleviating pain relative to the traditional suture bridge (P<0.05).

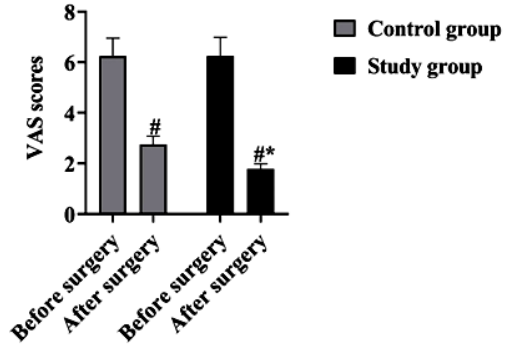

Figure 4. Evaluation of pain by VAS scores in both groups before and after surgery. #P<0.05, relative to before surgery, *P<0.05, relative to the CG.

Shoulder range of motion in both groups

As shown in figure 5, prior to surgery, we found no significant difference in external rotation, internal rotation, extension as well as flexion of shoulder between CG and SG (P>0.05). Three months after surgery, the degrees of external rotation, internal rotation, back extension, along with forward flexion of shoulder joint in both groups were increased compared with those before surgery (P<0.05), and those in the SG was higher than the CG, which indicated that rotator cuff humeral insertion displacement promoted the recovery of should joint motion in comparison with the traditional suture bridge (P<0.05).

[Downloaded from ijrr.com on 2026-11-24]

[DOI: 10.61186/ijrr.22.1.125]

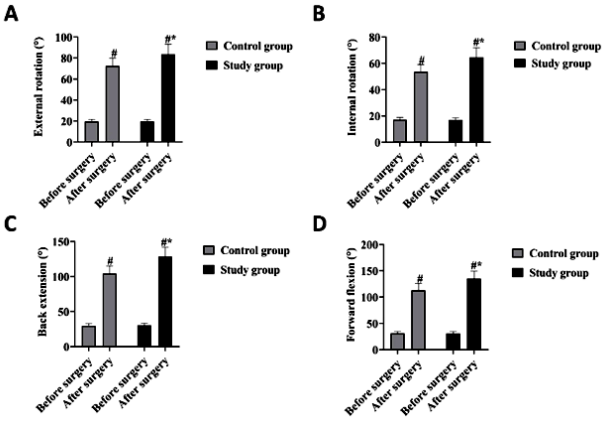

Figure 5. Shoulder joint motion degree of **(A)** external rotation, **(B)** internal rotation, **(C)** back extension and **(D)** forward flexion in both groups before and after surgery. #P<0.05, relative to before surgery, *P<0.05, relative to the CG.

Postoperative satisfaction of patients in both groups

Patient satisfaction rate of the surgery was evaluated three months after surgery. We found that 15 patients in the CG were satisfied or very satisfied with the traditional suture bridge treatment, and the satisfaction rate was 71.43%. For the SG, 20 patients were satisfied or very satisfied with the rotator cuff humeral insertion displacement treatment, and the satisfaction rate of patients in the SG reached 95.24%, which was significantly higher compared with the CG (χ^2= 4.55, P<0.05, table 3).

DISCUSSION

The rotator cuff consists of a complex of tendons that wrap around the humerus head. The cuff structure of these tendons plays an important role in maintaining the stability and the functions of abducting, flexion as well as extension of the shoulder joint [14]. Moreover, the tension of the rotator cuff produces compression stress on the glenohumeral articular surface and synchronously contracts the rotator cuff muscles during shoulder movement. The center of rotation of the glenoid in the glenohumeral joint can be maintained [15]. After a MRCT, the cable is damaged, and loses its pressure on the humerus head. During the movement of the shoulder joint, the head of the humerus shifts and the center of rotation of the glenoid shifts upward and becomes unstable, thus affecting the head movement of the upper limb [16]. If the huge rotator cuff tear is not repaired in time, with the progression of the disease, the humerus head will continue to move upward, the acromion appears acetabular situation, at the same time the rotator cuff muscle is severely atrophied, and the fat is aggravated, leading to an irreparable huge rotator cuff tear, which seriously affects the life quality in the later stage. The difficulty of surgical treatment is also increased with decreased efficacy, elevated cost and reduced patient satisfaction rate [17]. Rotator cuff tears should be treated early, and should be treated aggressively to prevent them from larger tears [18].

In recent years, arthroscopic shoulder technology has developed rapidly, with the strengths of less trauma, quick recovery, and reducing the patient's fear of surgery [19]. Therefore, arthroscopic repair is widely used for treating large rotator cuff tear [20]. The treatment principle for the massive rotator cuff is to restore the balance of the rotator cuff couple as much as possible, focus on rebuilding the front and back ends of the patient's cable, and restore the sleeve structure of the rotator cuff [21]. Traditional suture bridge technique can generally repair the transverse cable of the rotator cuff. However, due to incomplete release, the repaired rotator cuff tissue tension is high, and some patients suffer more severe pain in the early postoperative period than before surgery, and the possibility of later retear is also greater. Although patients can obtain a certain degree of satisfaction after surgery, it still affects the later function and efficacy [22].

For the diagnosis of rotator cuff muscles, ultrasonography is characterized by the advantages of low cost, tolerated and suitable for patients with claustrophobia compared with MRI, and can dynamically and globally evaluate the rotator cuff in real time [23]. Increasing studies have also revealed the accuracy and reliability of ultrasonography in the assessment of postoperative rotator cuff repairs [24, 25]. Gilat R, *et al.* have reported that the sensitivity and specificity of US imaging reached 80.8% and 100% for the diagnosis of rotator cuff retears after arthroscopic repair surgery [11]. Chen *et al.* indicate that 3D-US shows a diagnostic accuracy of 82.7% to evaluate rotator cuff tear patterns, which is higher than MRI, and is useful for preoperative evaluation and treatment option selection [26]. US is also regarded as a useful method for the evaluation of postoperative repair of rotator cuff along with MRI [27]. In this study, we found that the sensitivity and specificity of US reached 87.1% and 100% respectively in the detection of postoperative repair of MRCTs in all patients, with high reliability. The results were consistent with the previous findings (table 1). Moreover, the retear rate of the SG was decreased in comparison with the CG (table 2), which indicated the higher efficacy of arthroscopic humeral insertion displacement for the treatment of massive rotator cuff tears.

Furthermore, the outcomes displayed that three months after surgery, the UCLA scores in the SG were elevated compared to the CG (figure 3). The VAS scores in the SG were declined compared to the CG (figure 4). The degrees of external rotation, internal rotation, back extension, along with forward flexion of shoulder joint in both groups were increased compared with those before surgery, and those in the SG was greater than the CG (figure 5). All above data

[Downloaded from ijrr.com on 2026-11-24]

[DOI: 10.61186/ijrr.22.1.125]

suggested arthroscopic rotator cuff internal transfer technique was effective to treat patients with MRCTs, which could not only reconstruct the rotator cuff, restore the compression stress caused by the passive tension of the rotator cuff on the glenohumeral articular surface, but also acts as leverage to some extent after the repair of the torn rotator cuff, so that the shoulder joint could obtain better function and range of motion, and the shoulder pain of the patients was relieved [28]. By removing the bone cortex in the proximal footmark area of rotator cuff of the head of the humerus and its medial articular cartilage surface of about 5 mm, the area of the bone bed could be increased, and the contact surface of the tendon bone was increased, the length of the huge rotator cuff tear was shortened, the tension was reduced and the tendon bone healing rate was improved [29]. Therefore, rotator cuff humeral insertion fixation technique provided a new option for arthroscopic repair of MRCTs.

CONCLUSION

The two-dimensional color ultrasonography was an effective and reliable imaging method for the evaluating the treatment outcomes of MRCT repair after arthroscopic rotator cuff internal displacement, which effectively attenuated the shoulder pain, improved the shoulder joint function and life quality of patients, and was valuable for promotion.

ACKNOWLEDGMENT

Not applicable.

Funding: None.

***Conflicts of interests*:** The authors declare no conflicts of interest.

***Ethical consideration*:** This study was approved by the Ethics Committee of Zhangzhou Affiliated Hospital of Fujian Medical University (approval number: 2022LuB033; 2022).

***Author contribution*:** All authors were involved in the study design, data collection and analysis, drafting and revision of the manuscript. All author have read and approved the final version of the manuscript.

REFERENCES

1. Oh JH, Park MS, Rhee SM (2018) Treatment strategy for irreparable rotator cuff tears. *Clin Orthop Surg*, ***10****(2): 119-34.*
2. Piórek A and Adamiak Z (2010) Ultrasonography of the canine shoulder joint and its pathological changes. *Pol J Vet Sci*, ***13****(1): 193 -200.*
3. Fonseca Filho JM, Sella GDV, Souza LHL*, et al.* (2022) Evaluation of the clinical outcomes of the arthroscopic treatment of rotator cuff tears using the modified suture bridge technique. *Rev Bras Ortop (Sao Paulo)*, ***57****(6): 984-91.*
4. Berthold DP, Garvin P, Mancini MR*, et al.* (2022) Arthroscopic rotator cuff repair with biologically enhanced patch augmentation. *Oper Orthop Traumatol*, ***34****(1): 4-12.*
5. Di Benedetto P, Mancuso F, Tosolini L*, et al.* (2021) Treatment options for massive rotator cuff tears: a narrative review. *Acta Biomed*, ***92****(S3): e2021026.*
6. Wei S, Tang M, Li W*, et al.* (2022) Arthroscopic suture-bridge repair technique for an avulsion of the talar insertion of the anterior talofibular ligament. *J Foot Ankle Surg*, ***61****(4): 689-94.*
7. Do WS, Kim JH, Lim JR*, et al.* (2022) Pull-out strength of suture anchor and torque of buddy anchor for an osteoporotic humeral head in rotator cuff repair: Parallel versus divergent insertion. *Am J Sports Med*, ***50****(10): 2782-6.*
8. Euler SA, Hengg C, Kolp D*, et al.* (2014) Lack of fifth anchoring point and violation of the insertion of the rotator cuff during antegrade humeral nailing: pitfalls in straight antegrade humeral nailing. *Bone Joint J*, ***96-b****(2): 249-53.*
9. Suluova F, Kanatli U, Ozturk BY*, et al.* (2014) Humeral head cysts: association with rotator cuff tears and age. *Eur J Orthop Surg Traumatol*, ***24****(5): 733-9.*
10. Fotiadou AN, Vlychou M, Papadopoulos P*, et al.* (2008) Ultrasonography of symptomatic rotator cuff tears compared with MR imaging and surgery. *European Journal of Radiology*, ***68****(1): 174-9.*
11. Gilat R, Atoun E, Cohen O*, et al.* (2018) Recurrent rotator cuff tear: is ultrasound imaging reliable? *Journal of Shoulder and Elbow Surgery*, ***27****(7): 1263-7.*
12. Thamyongkit S, Wanitchanont T, Chulsomlee K*, et al.* (2022) The University of California-Los Angeles (UCLA) shoulder scale: translation, reliability and validation of a Thai version of UCLA shoulder scale in rotator cuff tear patients. *BMC Musculoskelet Disord*, ***23*** *(1): 65.*
13. Sung YT and Wu JS (2018) The visual analogue scale for rating, ranking and paired-comparison (VAS-RRP): A new technique for psychological measurement. *Behav Res Methods*, ***50****(4): 1694-715.*
14. Huegel J, Williams AA, Soslowsky LJ (2015) Rotator cuff biology and biomechanics: a review of normal and pathological conditions. *Curr Rheumatol Rep*, ***17****(1): 476.*
15. Greenspoon JA, Petri M, Warth RJ*, et al.* (2015) Massive rotator cuff tears: pathomechanics, current treatment options, and clinical outcomes. *J Shoulder Elbow Surg*, ***24****(9): 1493-505.*
16. Narvani AA, Imam MA, Godenèche A*, et al.* (2020) Degenerative rotator cuff tear, repair or not repair? A review of current evidence. *Ann R Coll Surg Engl*, ***102****(4): 248-55.*
17. Keener JD, Patterson BM, Orvets N*, et al.* (2019) Degenerative rotator cuff tears: refining surgical indications based on natural history data. *J Am Acad Orthop Surg*, ***27****(5): 156-65.*
18. Lewis J (2016) Rotator cuff related shoulder pain: Assessment, management and uncertainties. *Man Ther*, ***23****: 57-68.*
19. Cole BJ and Romeo AA (2001) Arthroscopic shoulder stabilization with suture anchors: technique, technology, and pitfalls. *Clin Orthop Relat Res*, *(390): 17-30.*
20. Liu T, Zhang MT, Zhou JP*, et al.* (2022) [Progress on arthroscopic surgery for massive rotator cuff tears]. *Zhongguo Gu Shang*, ***35*** *(12): 1177-82.*
21. Chianca V, Albano D, Messina C*, et al.* (2018) Rotator cuff calcific tendinopathy: from diagnosis to treatment. *Acta Biomed*, ***89****(1-s): 186-96.*
22. Yamakado K (2021) Two techniques for treating medium-sized supraspinatus tears: The medially based single-row technique and the suture bridge technique. *JBJS Essent Surg Tech*, ***11****(2).*
23. Wall LB, Teefey SA, Middleton WD*, et al.* (2012) Diagnostic performance and reliability of ultrasonography for fatty degeneration of the rotator cuff muscles. *The Journal of Bone and Joint Surgery American Volume*, ***94****(12): e83.*
24. Adler RS (2013) Postoperative rotator cuff. *Seminars in musculoskeletal radiology*, ***17****(1): 12-9.*
25. Gyftopoulos S, Cardoso MDS, Rodrigues TC*, et al.* (2022) Postoperative imaging of the rotator cuff: A systematic review and meta-analysis. *AJR American Journal of Roentgenology*, ***219****(5): 717-23.*
26. Chen X, Wang Y, Chen J*, et al.* (2023) Clinical value of three-dimensional ultrasonography in the morphologic evaluation of rotator cuff tear: a prospective study. *European Radiology*, ***33****(4): 2331-9.*
27. Lee SC, Williams D, Endo Y (2018) The repaired rotator cuff: MRI and ultrasound evaluation. *Current Reviews in Musculoskeletal Medicine*, ***11****(1): 92-101.*
28. Galasso O, Mantovani M, Muraccini M*, et al.* (2020) The latissimus dorsi tendon functions as an external rotator after arthroscopic-assisted transfer for massive irreparable posterosuperior rotator cuff tears. *Knee Surg Sports Traumatol Arthrosc*, ***28****(7): 2367-76.*
29. Cavalier M, Jullion S, Kany J*, et al.* (2018) Management of massive rotator cuff tears: Prospective study in 218 patients. *Orthop Traumatol Surg Res*, ***104****(8s): S193-s7.*

[Downloaded from ijrr.com on 2026-11-24]

[DOI: 10.61186/ijrr.22.1.125]