Volume 22, No 1 | International Journal of Radiation Research, January 2024

The application value of computed tomography perfusion imaging in diagnosing early cerebral infarction

B. Sun and Z. Wang*

Department of Neurosurgery, Qilu Hospital (Qingdao), Cheeloo College of Medicine, Shandong University, Qingdao, Shandong 266035, China

► ***Original article***

Corresponding author:
Zhigang Wang, Ph.D.,
E-mail:
wzhigang202212@163.com

Received: August 2023
Final revised: August 2023
Accepted: August 2023

Int. J. Radiat. Res., January 2024; 22(1): 139-143

DOI: 10.52547/ijrr.21.1.19

Keywords: *CT, perfusion imaging, cerebral infarction, detection accuracy, patient satisfaction.*

ABSTRACT

Background: To clarify the value of computed tomography (CT) perfusion (CTP) imaging in diagnosing early cerebral infarction (CI). ***Materials and Methods***: Totally 100 suspected early CI patients in our hospital from May 2019 to May 2022 were selected and divided into observation and control groups based on examination methods, with 50 patients per group. In control group, patients received plain scanning through 64 row multi-slice spiral CT. On this basis, patients in observation group received CTP in certain area. Comparison of detection rate between groups was conducted. The observation indicators of CI patients detected by CTP in observation group were recorded and analyzed, including the mean transit time (MTT) of the same blood volume, cerebral blood flow (CBF), cerebral blood volume (CBV), and time to peak (TTP). The satisfaction with examination in both groups was explored. ***Results:*** CTP presented higher detection accuracy than plain CT scanning ($P < 0.05$). TTP presented elevation and MTT, CBV and CBF presented depletion in CI position than those in other cerebral position ($P < 0.05$). TTP, MTT, CBV and CBF presented statistical significance between ischemic penumbra (IP) position and CI position ($P < 0.05$). The satisfaction degree was elevated in observation group relative to control group ($P < 0.05$). ***Conclusion:*** CTP in early CI has higher diagnostic value and accuracy and elevates patient satisfaction, helping reduce disability and mortality. Additionally, CTP has high maneuverability and flexibility, and can measure IP, reducing the degree of brain tissue damage in patients, and is worthy of clinical application.

INTRODUCTION

Cerebral infarction (CI), also known as ischemic stroke, is a relatively common type of cerebrovascular disease, accounting for approximately 70% of all acute cerebrovascular diseases, which is mostly diagnosed in middle-aged and elderly patients [1]. CI refers to the cerebral blood artery atherosclerosis or thrombosis caused by cerebral insufficiency, abnormal blood flow caused by blood flow interruption or blood flow loss caused by tissue necrosis [2, 3]. The clinical symptoms are usually hemiplegia, aphasia, dizziness, headache, coma, etc.; general awareness is clear, and severe condition can progress to cerebral hernia and brain death [4]. Risk factors such as family history, age, hypertension, diabetes, unhealthy lifestyle as well as atherosclerosis are associated with the increased occurrence of cerebral infarction [5]. As one of the leading causes of death and disability, acute ischemic stroke affects around 700 000 population annually [6]. The incidence of CI also shows an elevating and younger trend in recent years [7]. Currently, treatment of CI is still challenged in clinical medicine in spite of the deepening understanding the pathophysiology of stroke. The mechanical thrombectomy, reperfusion with recombinant tissue plasminogen activator (rtPA) such as alteplase are mainly used in the therapy of patients with CI [8, 9].

The earlier and prompt treatment is linked with the improved clinical outcomes [6]. Strengthening early screening and diagnosis of CI can provide reference and guidance for clinical practice (emergency thrombolytic therapy and prognosis judgment). Imaging is crucial to confirm the diagnosis and guide the treatment. Computed tomography (CT) is regarded as the primary imaging strategy for the detection of CI [10]. With the technical breakthrough, CT perfusion imaging (CTP) is a functional examination of brain tissue that characterizes the cerebral perfusion state and presents the circulation or microcirculation status [11]. By effectively judging the abnormal areas of brain, and conducting multi-indicator analysis on the identified areas, CTP is conducive to accurate diagnosis of CI [12]. Additionally, CTP benefits the differentiation between necrotic core and penumbra, and improves the possibility of treating patients with systemic thrombolysis or endovascular therapy outside the recommended therapeutic window [13]. Moreover, a meta-analysis study indicates that the role of CTP in the prognosis of cerebral ischaemia, suggesting that the ischaemic core volume and imaging-to-reperfusion time are independently associated with

[Downloaded from ijrr.com on 2026-11-24]

[DOI: 10.61186/ijrr.22.1.139]

functional independence and functional improvement [14].

In this study, CI patients treated in our hospital were diagnosed through CT and CTP respectively. We aimed to compare the accuracy of two different examination methods in clinic. The findings of our study may provide novel clues for the early and effective detection of CI patients.

MATERIALS AND METHODS

General data

A total of 100 suspected early CI patients admitted in our hospital from May 2019 to May 2022 were chosen and separated into observation and control groups based on the examination methods, including 50 patients per group. Inclusion criteria: 1) Normal psychology and spirit; 2) with clinical symptoms such as slurred speech, hemiplegia, unresponsiveness, etc.; 3) diagnosed as suspected CI patients; 4) obtained written informed consent from patients. Exclusion criteria: 1) With a history of CI; 2) mental disorders that affected cooperation and communication; 3) those with malignancies; 4) those who voluntarily withdrew from the research. The Ethics Committee of our hospital approved this research. Figure 1 showed the CT images of a CI patient before and after the treatment.

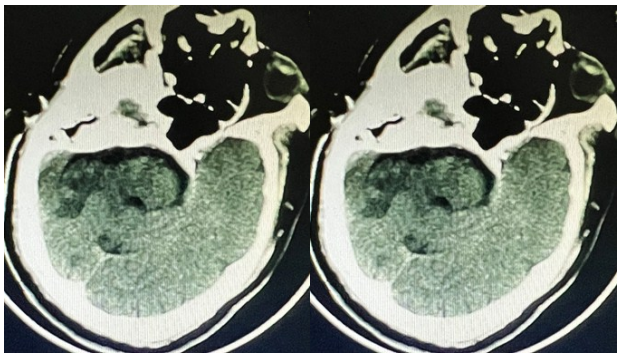

Figure 1. Representative CT imaging for a CI patient before (left panel) and after (right panel) treatment in our hospital. CT imaging showed low density infarcts in the right cerebellar hemisphere and right pontine before the treatment. After the treatment, CT imaging presented that the low-density infarcts were improved and returned to normal density after treatment.

Examination methods

In control group, patients received plain scanning through 64 row multi-slice spiral CT (GE Company, USA). The patients were maintained in a supine position and received conventional plain scanning to find the location of CI. The canthus ear line was the baseline, and the scanning was carried out to the top of skull. The instrument parameters were adjusted accordingly, with the ball tube voltage set as 80 kV, the current strictly controlled at 150 mA and relatively stable, both the layer thickness and spacing set as 7 mm, and the screw distance set as 1 mm.

On this basis, patients in observation group received CTP in certain area, and the clinician chose appropriate layer according to the needs of required diagnosis site. After strict disinfection of syringe, 40 ml of (Iopamidol 370, Bracco, Shanghai, China) and 20 ml of 0.9% sodium chloride injection (Harbin Sanlian Pharmaceutical, China) were respectively injected into the back of the patient right hand. After injection, CTP could be started. Except that it was continuous scanning, the scanning constant was basically the same as plain scanning. Parameters were adjusted as shown below. The voltage was set as 100 kV and kept stable, the current was set as 300 mA, the layer thickness was set as 7 mm, the screw pitch was set as 1.2 ram, the scanning speed was controlled at 1 layer/s, with interval of 1 s, the matrix was set as 512 × 512, and scanning range was set as 80 mm. The corresponding images and CT perfusion parameters were obtained and received processing through computer software. The final results were obtained after analysis and discussion by two experts.

Clinical observation indicators

(1) The detection rate in both groups received comparison. (2) The observation indicators of CI patients detected by CTP in observation group received recording and analysis, including the mean transit time (MTT) of the same blood volume, cerebral blood flow (CBF), cerebral blood volume (CBV), as well as time to peak (TTP). (3) Satisfaction with examination in both groups was investigated. Evaluation of this indicator was expressed by scores. The > 90 was very satisfied, 60-90 was satisfied, and < 60 was dissatisfied. The full score was 100. Satisfaction degree = (very satisfied + satisfied) cases / total cases × 100%.

Statistical analysis

SPSS statistical software (V. 20.0, SPSS Inc., Chicago, Illinois, USA) was used for statistical analysis. The measurement data were presented as the mean ± SD, and comparison between other cerebral position and CI position was conducted through t-test. The counting data was expressed as [n (%)]. The accuracy and satisfaction was compared through χ^2; Difference was statistically significant when P value was less than 0.05.

RESULTS

Comparison of general data between two groups

Totally 100 patients with suspected CI were enrolled in our study. Patients were divided into the observation and control groups based on the examination methods. The control group consisted of 24 males and 26 females; average age was 64.7 ± 3.2

[Downloaded from ijrr.com on 2026-11-24]

[DOI: 10.61186/ijrr.22.1.139]

years, ranging 54-70 years old; disease course was 1.6-3.0 h, with mean disease course of 2.10 ± 0.26 h; clinical manifestations: 16 cases of aphasia, 24 cases of hemiplegia and 10 cases of unconsciousness. The observation group consisted of 22 males and 28 females; average age was 64.1 ± 3.8 years, ranging 55 -71 years old; disease course was 1.6-2.8 h, with mean disease course of 2.13 ± 0.29 h; clinical manifestations: 17 cases of aphasia, 28 cases of hemiplegia and 5 cases of unconsciousness. The general data presented no statistical difference between both groups (P > 0.05) (Table 1).

Table 1. General data in two groups.

Groups	N	Gender		Age (year)	Disease course (h)	Clinical manifestations		
		Male	Female			Aphasia	Hemiplegia	Unconsciousness
Control group	50	24	26	64.7±3.2	2.10±0.26	16	24	10
Observation group	50	22	28	64.1±3.8	2.13±0.29	17	28	5
χ^2/t		0.161		0.697	1.897	2.005		
P		0.688		0.489	0.064	0.367		

N, number of cases.

Comparison of detection rate between two groups

In control group, 29 early CI patients were detected by plain CT scanning, with a detection rate of 58% (29/50), and these 29 patients were found to have a slightly low density of CI area and a locally seen and slightly shallow sulcus. In observation group, 41 early CI patients were detected by CTP, with a detection rate of 82% (41/50), and abnormal perfusion areas were observed in these 41 patients. The detection rate of CTP in observation group presented significant elevation relative to that of plain CT scanning in control group (χ^2= 6.857, P =0.009) (Table 2).

Table 2. Detection rate in two groups.

Groups	N	Detection rate [n (%)]
Control group	50	29 (58%)
Observation group	50	41 (82%)
χ^2/t		6.857
P		0.009

N, number of cases.

Comparison of observation indicators of 41 CI patients detected by CTP in observation group

In observation group, 41 patients were detected by CTP. Based on their CT images, we discovered that there were obvious abnormalities at CI position relative to other cerebral position. TTP presented significant elevation (P<0.001) and MTT, CBV and CBF presented significant reduction (P<0.001) in the CI position relative to those in other cerebral position (table 3). Moreover, TTP, MTT, CBV and CBF presented statistical difference between the ischemic penumbra (IP) position and the CI position (P < 0.001). The TTP was significantly increased (P < 0.001) while the MTT, CBV and CBF were decreased (P < 0.001) in the CI position in comparison with the IP position (table 4).

Table 3. CTP parameters in CI position and other cerebral position.

Groups	N	MTT (s)	CBF (ml / min.100 g)	CBV (ml / 100 g)	TTP (s)
CI position	41	3.5±1.0	15.1±5.1	0.7±0.3	26.8±6.5
Other cerebral position	41	6.1±0.7	30.5±10.1	2.6±0.3	15.2±5.9
χ^2/t		12.455	8.766	17.356	10.316
P		< 0.001	< 0.001	< 0.001	< 0.001

CTP, computed tomography perfusion; CI, cerebral infarction; MTT, mean transit time; N, number of cases; CBF, cerebral blood flow; CBV, cerebral blood volume; TTP, time to peak.

Table 4. CTP parameters in CI position and IP position

Groups	N	MTT (s)	CBF (ml/min·100 g)	CBV (ml/100 g)	TTP (s)
CI position	41	3.5±1.0	15.1±5.1	0.7±0.3	26.8±6.5
IP position	41	6.6±0.9	24.7±8.3	2.5±0.7	20.6±6.9
χ^2/t		14.565	6.243	16.995	6.794
P		< 0.001	< 0.001	< 0.001	< 0.001

CTP, computed tomography perfusion; CI, cerebral infarction; IP, ischemic penumbra; MTT, mean transit time; N, number of cases; CBF, cerebral blood flow; CBV, cerebral blood volume; TTP, time to peak.

Comparison of patient satisfaction rate between two groups

In observation group, 29 patients were very satisfied, 18 patients were satisfied, and only 3 patients were dissatisfied with the CTP imaging, and the satisfaction rate was 94% (47/50). Control group included 15 very satisfied patients, 13 satisfied patients and 16 dissatisfied patients with the plain CT scanning, and the satisfaction rate was 68% (34/50). The satisfaction degree in observation group was significantly higher relative to that in control group, with statistical significance (χ^2 = 10.981, P < 0.001) (table 5).

Table 5. Patient satisfaction rate in two groups.

Groups	N	Very satisfied	Satisfied	Dissatisfied	Satisfaction rate [n (%)]
Control group	50	15	19	16	34 (68%)
Observation group	50	29	18	3	47 (94%)
χ^2/t					10.981
P					< 0.001

DISCUSSION

Arterial obstruction and insufficient supply of cerebral vessels are common causes of CI. The onset of acute CI brings risks to the health and life of patients. For patients with CI, timely treatment is needed, otherwise it will lead to neurological impairment [15]. In the early stage (within 6 h) from the onset of CI, detection and confirmation of the disease can facilitate follow-up intravenous thrombolytic therapy, grasp the best time for thrombolytic therapy, reduce complications caused

[Downloaded from ijrr.com on 2026-11-24]

[DOI: 10.61186/ijrr.22.1.139]

by CI, and decrease the degree of brain tissue damage [16]. The diagnostic accuracy of early CI is closely associated with the improvement of prognosis in patients and even survival outcomes. Thus, it is urgent to develop effective means for the detection of CI.

The changes of electrolyte mainly occur during the time period before and after CI occurrence [17]. Thus, most early CI patients are difficult to find abnormalities in the early stage of CI by only conventional plain CT scanning. After 22 h of CI, plain CT scanning can diagnose the infarct position. Thus, the diagnosis of CI by plain CT scanning possesses great limitations, which may delay the therapy. Spiral CT perfusion (CTP) imaging technology has been widely applied to clinical practice in recent years [18]. CTP examination can perform multi-layer dynamic scanning and rapid same-layer scanning on selected layers to provide doctors with corresponding data for reference, thereby helping them understand the disease and carry out follow-up therapy. A previous study has reported that the sensitivity and specificity of CTP to diagnose acute ischaemic stroke is 82% and 96%, which is more sensitive compared with native CT scan detection and shows similar diagnosis accuracy to CT angiography [19]. The combination of CTP to non-contrast CT is revealed to elevate the detection accuracy of ischemia [20]. Compared with non-contrast CT and CT angiography, CTP also presents higher concordance for Alberta Stroke Program Early Computed Tomography Score, which is more sensitive to detect the early ischemic changes and predict the final infarction [21]. In this study, CTP presented higher detection accuracy relative to plain CT scanning, with statistical significance ($P = 0.009$) (Table 2), which was consistent with the previous findings. It suggests that conventional plain CT scanning has little change in CT value of acute CI within 6 h, which is difficult to identify, and the detection accuracy cannot meet clinical treatment needs, thus it is easy to miss diagnosis; detection accuracy of CTP is relatively higher, and the high detection accuracy in early stage provides patients with more timely treatment. Moreover, satisfaction degree in observation group presented significant elevation in comparison with control group ($P < 0.001$, Table 5). Based on the satisfaction survey, the CTP examination is more accurate and thus it is more accepted by patients.

CTP examination can be combined with CT plain scanning to elect a certain layer for specific analysis. The images and CT perfusion parameters can be obtained through computer software processing. Then MTT, CBF, CBV and TTP of infarcted area and other cerebral areas can be calculated, and perfusion images can be drawn. Parameters of perfusion can be generated from the tissue-time density curve reflecting the proportional signal intensity and concentration of contrast at indicated time points, and then applied to produce maps of CBV, CBF, and TTP. CBF is proportional to the amplitude of the curve while CBV is proportional to the area under the curve [22, 23]. The detection is conducted on a voxel-wise level and catches relatively small changes in the tissue signal, providing the evaluation for the microcirculation. It allows the distinction of focal ischemia below the resolution based on CT angiography particularly in non-large vessel occlusion cases [24-26]. When the ratio of CBV of CI position and other cerebral position is greater than 0.2, it suggests that there is a good therapeutic effect, and when it is less than 0.2, it suggests that the effect is not ideal. Additionally, IP can be measured to determine patients' infarct site, which can facilitate the later treatment. Herein, TTP presented elevation and MTT, CBV and CBF presented depletion in CI position relative to those in other cerebral position ($P < 0.001$, Table 3). TTP, MTT, CBV and CBF presented statistical significance between IP position and CI position ($P < 0.001$, Table 4). It suggests that in addition to the high accuracy of CTP examination, the provision of its corresponding images and parameters can also help determine the location of CI in clinical practice, so as to grasp the best time for thrombolysis and elevate the therapeutic efficacy.

In conclusion, CTP in early CI shows higher diagnostic value and accuracy and elevates patient satisfaction, helping reduce disability and mortality. Additionally, this examination method has high maneuverability and flexibility, and can measure ischemic penumbra, which benefits to the brain tissue damage reduction in CI patients, and is worthy of clinical application.

ACKNOWLEDGMENT

Not applicable.

***Funding*:** None.

***Conflicts of interests*:** The authors declare no conflicts of interest.

Ethical consideration: This study was approved by the Ethics Committee of Qilu Hospital (Qingdao), Cheeloo College of Medicine, Shandong University (approval number: 2018-R-064; 2018).

Author contribution: Bin Sun and Zhigang Wang designed the study. Bin Sun collected and analyzed the data. Bin Sun wrote the draft and Zhigang Wang revised the manuscript. Both two authors have read and approved the final version of the manuscript.

REFERENCES

1. Schrader I, Wilk D, Jansen O, *et al.* (2013) Whole-brain perfusion CT using a toggling table-technique to predict final infarct volume in acute ischemic stroke. *RoFo: Fortschritte auf dem Gebiete der Rontgenstrahlen und der Nuklearmedizin,* ***185****(10): 975-82*.

[Downloaded from ijrr.com on 2026-11-24]

[DOI: 10.61186/ijrr.22.1.139]

2. Tan XL, Xue YQ, Ma T, *et al.* (2015) Partial eNOS deficiency causes spontaneous thrombotic cerebral infarction, amyloid angiopathy and cognitive impairment. *Molecular Neurodegeneration,* ***10****: 24*.
3. Zeng Q, Lin K, Yao M, *et al.* (2015) Significant correlation between cystatin C, cerebral infarction, and potential biomarker for increased risk of stroke. Current neurovascular research, **12**(1): 40-6.
4. Abbasian S, Kargar Moghaddam M, Nazari B (2022) The effect of high-intensity treadmill training on motor function in patients with a stroke. *SJMSHM,* ***4*** *(1): 1-3*.
5. Ke J and Jing M (2016) Analysis of treatment effect of urinary kallidinogenase combined with edaravone on massive cerebral infarction. *Biomedical Reports,* ***5****(2): 155-8*.
6. Walter K (2022) What Is Acute Ischemic Stroke? *Jama,* ***327****(9): 885*.
7. Béjot Y, Duloquin G, Thomas Q, et al. (2021) Temporal Trends in the Incidence of Ischemic Stroke in Young Adults: Dijon Stroke Registry. *Neuroepidemiology,* ***55****(3): 239-44*.
8. Paul S and Candelario-Jalil E (2021) Emerging neuroprotective strategies for the treatment of ischemic stroke: An overview of clinical and preclinical studies. *Experimental Neurology,* ***335****: 113518*.
9. Herpich F and Rincon F (2020) Management of acute ischemic stroke. *Critical Care Medicine,* ***48****(11): 1654-63*.
10. Ospel JM, Holodinsky JK, Goyal M (2020) Management of acute ischemic stroke due to large-vessel occlusion: JACC Focus Seminar. *Journal of the American College of Cardiology,* ***75****(15): 1832-43*.
11. Joundi RA and Menon BK (2021) Thrombus composition, imaging, and outcome prediction in acute ischemic stroke. *Neurology,* ***97****(20 -2): S68-s78*.
12. Schrader I, Wilk D, Jansen O, *et al.* (2013) Whole-brain perfusion CT using a toggling table technique to predict final infarct volume in acute ischemic stroke. *RoFo: Fortschritte auf dem Gebiete der Rontgenstrahlen und der Nuklearmedizin,* ***184****(10): 975-82*.
13. Václavík D, Volný O, Cimflová P, *et al.* (2022) The importance of CT perfusion for diagnosis and treatment of ischemic stroke in anterior circulation. *Journal of Integrative Neuroscience,* ***21****(3): 92*.
14. Campbell BCV, Majoie C, Albers GW, *et al.* (2019) Penumbral imaging and functional outcome in patients with anterior circulation ischaemic stroke treated with endovascular thrombectomy versus medical therapy: a meta-analysis of individual patient-level data. *The Lancet Neurology,* ***18****(1): 46-55*.
15. Hurford R, Sekhar A, Hughes TAT, *et al.* (2020) Diagnosis and management of acute ischaemic stroke. *Practical Neurology,* ***20****(4): 304 -16*.
16. Malinova V, Dolatowski K, Schramm P, *et al.* (2016) Early whole-brain CT perfusion for detection of patients at risk for delayed cerebral ischemia after subarachnoid hemorrhage. *Journal of Neurosurgery,* ***125****(1): 128-36*.
17. Martha SR, Fraser JF, Pennypacker KR (2019) Acid-Base and Electrolyte Changes Drive Early Pathology in Ischemic Stroke. *Neuromolecular Medicine,* ***21****(4): 540-5*.
18. Bektas H, Wu TC, Kasam M, *et al.* (2010) Increased blood-brain barrier permeability on perfusion CT might predict malignant middle cerebral artery infarction. *Stroke,* ***41****(11): 2539-44*.
19. Shen J, Li X, Li Y, *et al.* (2017) Comparative accuracy of CT perfusion in diagnosing acute ischemic stroke: A systematic review of 27 trials. *PloS one,* ***12****(5): e0176622*.
20. Lin K, Do KG, Ong P, *et al.* (2009) Perfusion CT improves diagnostic accuracy for hyperacute ischemic stroke in the 3-hour window: study of 100 patients with diffusion MRI confirmation. (Basel, Switzerland) *Cerebrovascular Diseases,* ***28****(1): 72-9*.
21. Chu Y, Ma G, Xu XQ, *et al.* (2022) Total and regional ASPECT score for non-contrast CT, CT angiography, and CT perfusion: inter-rater agreement and its association with the final infarction in acute ischemic stroke patients. (Stockholm, Sweden: 1987) *Acta Radiological,* ***63****(8): 1093-101*.
22. Saini M and Butcher K (2009) Advanced imaging in acute stroke management-Part I: Computed tomographic. *Neurology India,* ***57*** *(5): 541-9*.
23. Butcher K and Emery D (2010) Acute stroke imaging. Part II: The ischemic penumbra. *The Canadian Journal of Neurological Sciences,* ***37****(1): 17-27*.
24. van der Hoeven EJ, Dankbaar JW, Algra A, *et al.* (2015) Additional diagnostic value of computed tomography perfusion for detection of acute ischemic stroke in the posterior circulation. *Stroke,* ***46****(4): 1113-5*.
25. Das T, Settecase F, Boulos M, *et al.* (2015) Multimodal CT provides improved performance for lacunar infarct detection. *AJNR American Journal of Neuroradiology,* ***36****(6): 1069-75*.
26. Rudilosso S, Urra X, San Román L, *et al.* (2015) Perfusion Deficits and Mismatch in Patients with Acute Lacunar Infarcts Studied with Whole-Brain CT Perfusion. *AJNR American journal of neuroradiology,* ***36****(8): 1407-12*.

[Downloaded from ijrr.com on 2026-11-24]

[DOI: 10.61186/ijrr.22.1.139]

[DOI: 10.61186/ijrr.22.1.139] [Downloaded from ijrr.com on 2026-11-24]