Volume 22, No 1 | International Journal of Radiation Research, January 2024

Protective efficacy of luteolin against γ-rays induced early pneumonitis in rats

S.S. Tawfik[1], A.A. El Kady[1*], R.M. Ebrahim[1], W.A. El khouly[2]

[1]Health Radiation Research Department, National Centre for Radiation Research and Technology (NCRRT), P. O. Box 29, Nasr City, Cairo, Egypt. Egyptian Atomic Energy Authority, Nasr City, Cairo, Egypt
[2]Radiation Protection Department, Nuclear and Radiation Safety Research Center (NRSRC), P. O. Box: 7551, Nasr City, Cairo, Egypt. Egyptian Atomic Energy Authority, Nasr City, Cairo, Egypt

► ***Original article***

Corresponding author:
Ahmed Amer El kady, Ph.D.,
E-mail: *elkadyah13@gmail.com*

Received: March 2023
Final revised: July 2023
Accepted: August 2023

Int. J. Radiat. Res., January 2024; 22(1): 193-198

DOI: 10.52547/ijrr.21.27

Keywords: *Luteolin, radio protector, radiation pneumonitis, γ-rays, rats.*

ABSTRACT

Background: Radiotherapy treats over 70% of thoracic tumours; however, the technique frequently causes radiation-pneumonitis. Luteolin exhibits anti-inflammatory properties and inhibits chemotaxis release. The radio protective effects of luteolin on γ-rays-induced pneumonitis in rats were evaluated. ***Materials and Methods:*** Thirty-two rats were distributed into four groups. Rats were exposed to 8.5Gy-γ-rays then, treated with or without luteolin for 20-days. Oxidative-stress, antioxidant, anti-inflammatory markers levels, collagen content, and histopathological structures were evaluated in lung tissue. ***Results:*** Increased reactive oxygen species (ROS) production and oxidative stress after irradiation were down-regulated by luteolin treatment, demonstrating luteolin's antioxidant and anti-inflammatory properties. Luteolin attenuated lung histopathological changes which represented by desquamation of bronchiolar epithelia with pre-bronchiolar leukocytic infiltrations, proliferation of pneumocytes type II, emphysema and collapse induced by γ-rays. ***Conclusion:*** The current study found, for the first time, that luteolin has a protective effect on whole body γ-rays-induced early lung injury in rat model.

INTRODUCTION

Lung tissues are relatively sensitive to radiation [1]. Radiation-induced pathological acute lung damages are refractory side effects in lung cancer radiotherapy; however, they could result in morbidity and mortality with severe side effects [2].

Consequently, radiation-induced lung injury is classified as an early-phase pneumonitis or late-phase fibrosis [3], and numerous studies have indicated that inflammation plays a crucial role in the development of fibrosis. Therefore, the pathology of acute pneumonitis is closely associated with fibrosis [4]. Early pneumonitis is characterized by the appearance of intra-alveolar oedema, and the infiltration of inflammatory cells [5]. The cytokine indicators, such as tumour necrosis factor-alpha (TNF -α) and interleukin-6 (IL-6) are stimulated by the infiltrated inflammatory cells [6]. Currently, luteolin inhibits the signal transducer and activator of transcription-3 which acts as an oncogenic transcription-factor in practically 50% of human lung cancers [7, 8]. Luteolin and luteolin glycosides bioactive composites can lessen tumor cell production via numerous mechanisms, such as inhibiting cell cycle and exciting apoptosis via stimulating initiator and assassin caspase [9]. Also, luteolin as a cardio-protective factor improves cardiac toxicity induced by doxorubicin [10].

Furthermore, luteolin as a nutraceutical factor that markedly alleviates and protects against the damaging and ill effects of ionizing-radiation on laboratory animals [11]. Likewise, it inhibits UVB-induced photo aging [12]. Moreover, centipede grass extract that has been reported to contain luteolin that may be an effective agent in the control of oxidative stress-related diseases and in radioprotection [13]. Therefore, the search for regulatory molecules alter the inflammatory response may be a new therapeutic strategy for radiation-induced lung injury [14]. Luteolin, a flavone found in many plants, significantly inhibits superoxide anion generation, the ROS production and the increase in chemotaxis release. It can be a favourable anticancer agent against human colorectal carcinoma and cervical cancer cells [15, 16]. Moreover, it ameliorates neutrophil infiltration as well as the thickness of paw oedema and ROS production in acute inflammatory arthritis [17]. This study is the first to focus on the role and mechanism of luteolin in radiation-induced pneumonitis and lung dysfunction in a rat model.

MATERIALS AND METHODS

Animals

Thirty-two adult male Swiss albino rats, aged 10–11 weeks (245-270g) were obtained from the

[Downloaded from ijrr.com on 2026-11-24]

[DOI: 10.61186/ijrr.22.1.193]

Egyptian organization for biological product and vaccines Giza, Egypt. Animals received a typical diet and water *ad-libitum* and were kept under regular environments of humidity, temperature (20-24°C), and 12-hours light-dark regimen. Animals were deprived of food, but not water, overnight before experiments. All experiments were performed in accordance with the ethics committee of NCRRT, protocol: 7A/20.

Radiation processing

It was performed by using gamma cell-40 (cesium -137) located at NCRRT, Cairo, Egypt. Animals were irradiated with a single dose level of 8.5Gy γ-rays, delivered at a dose rate of 0.38Gy/ min at the time of experimentation. An irradiation regime (8.5Gy), an acute shot-dose to induce distinctive radiobiological toxicity and acute lung radiation syndromes was carried out [18]. Animals were not anesthetized before irradiation.

Chemicals

Luteolin, ≥98%, powder obtained from Sigma-Aldrich, St. Louis, USA was used in this study. All other chemicals and solvents used were of the highest purity grade available.

Experimental design and animal grouping

Rats were randomly distributed into four groups, each consisting of 8 rats. The control group: animals received normal saline (N/S); 2 ml/ kg body weight as a vehicle daily for 20 successive days, intraperitoneal (ip). Luteolin group: animals received luteolin (10 mg/ kg body weight, ip) according to Ruan *et al.* [19]. For the same time, Ruan and his colleagues found that dosage of 10 mg gave results that of 20 mg so, the authors chose the dose of 10mg for their trial. The γ-rays group: animals received N/S with the same dose and time; then whole-body irradiation (8.5Gy γ-rays) was carried out according to Saini *et al.* [20]. This dose is enough to induce early pneumonitis and lung toxicity. The γ-rays & luteolin group: Luteolin with the same dose and time was given post to irradiation. The animals were decapitated 72 hours after the end of the experiment following an overnight fast.

Biochemical analysis

Blood and lung-sections were harvested from the rat groups under normal laboratory conditions. The collagen content in lung tissues was calculated following the hydroxyproline assay, using colorimetric kits (Abcam, UK), according to the manufacturer's instructions. The absorbance was read at 560nm. Serum TNF-α and IL-6 was performed by ELISA procedure (BioSource International, Camarillo, CA, USA) according to the manufacturer's directions. Each sample assay was repeated three times. The absorbance was read at 450nm with a microplate reader (Thermo Scientific Multiskan MK3, USA). Estimation of malondialdehyde (MDA) level, and the relative antioxidant enzyme activity of superoxide dismutase (SOD) and glutathione peroxidase (GPx) in the lung homogenates was measured using commercial kits (Zellbio GmbH, Germany) according to the manufacturer's instructions. The absorbance was read at 420nm, 535nm and 412nm, respectively.

Histopathological analysis

The lung tissues were fixed in 10% neutral formalin solution. After 72 hours, tissues were dehydrated through a series of graded alcohol, embedded in paraffin, and cut into 5-micron sections and stained with haematoxylin and eosin (H & E) according to Bancroft *et al.* [21] and examined microscopically (Olympus, Japan).

Statistical analysis

Data were evaluated by means of one-way analysis of variance (ANOVA) followed by LSD post hoc test. The results were expressed as mean± standard deviation. Differences were considered significant at $p \leq 0.05$ [22].

RESULTS

As presented in table 1, animal group treated with luteolin only showed non-significant deviations in all calculated biochemical indices when compared to the corresponding values of the control group.

Table 1. The level of MDA and hydroxyproline contents in lung tissue of different animal groups.

Groups	Control	Luteolin	γ-rays	γ-rays & Luteolin
hydroxyproline (µg/ mg tissue)	21.12± 2.32	20.46± 2.19	22.14± 2.12	22.02± 2.1 7
MDA (nmol/ mg tissue)	2.38± 0.29	2.28± 0.18	3.81± 0.39[a,b]	2.71± 0.22[c]

[a]Significant difference from control group. [b]Significant difference from luteolin group. [c]Significant difference from γ-rays group.

There was a significant rise in MDA content in the γ-rays group as compared to control and luteolin groups. Treatment with luteolin at a dose of 10 mg/ kg ip, revealed a significant drop in MDA level, when compared to the γ-rays group at a dose of 8.5 Gy γ-rays. Also MDA level showed non-significant changes as compared to control and luteolin groups. Moreover, no significant differences were found in hydroxyproline content (the direct measure of the amount of collagen present in lung tissues) in between the four animal experiment groups (P<0.05), table 1.

Gamma-rays challenge significantly increased TNF -α and IL-6 levels in the irradiated rat group compared with the control and luteolin groups (table. 2). The luteolin & γ-rays group showed significantly reduced TNF-α and IL-6 levels compared with the irradiated rat group, but there were significant increases as compared to control and luteolin groups

[Downloaded from ijrr.com on 2026-11-24]

[DOI: 10.61186/ijrr.22.1.193]

(table 2).

Table 2. The inflammatory marker levels of TNF-α and IL-6 in serum of different animal groups.

Groups	Control	Luteolin	γ-rays	γ-rays & Luteolin
TNF-α (pg/ mL)	52.34± 5.61	53.16± 5.18	128.16± 11.54[a,b]	83.23±7.56[a,b,c]
IL-6 (pg/ mL)	27.94± 2.66	25.92± 2.73	83.22± 8.17[a,b]	39.51±3.82[a,b,c]

[a]Significant difference from control group. [b]Significant difference from luteolin group. [c]Significant difference from γ-rays group.

The data show a marked decrease in lung SOD and GPx activities in the γ-rays group. This change was significantly reversed in γ-rays & Luteolin group, when compared to the corresponding γ-rays group, table 3. There were significant decreases in SOD activity as compared to control and luteolin groups but GPx activities showed non-significant changes as compared to control and luteolin groups, table 3.

Table 3. The anti-oxidative stress marker activity of SOD and GPx in lung tissue of different animal groups.

Groups	Control	Luteolin	γ-rays	γ-rays & Luteolin
SOD (U/ g tissue)	521.15± 54.17	539.62± 55.11	305.61± 32.13[a,b]	455.24± 44.23[a,b,c]
GPx (nmol/ g tissue)	25.15± 2.74	25.31± 2.52	14.21± 1.61[a,b]	22.61± 2.22[c]

[a]Significant difference from control group. [b]Significant difference from luteolin group. [c]Significant difference from γ-rays group.

The data show a marked decrease in lung SOD and GPx activity. This change was significantly reversed in rats treated with the luteolin, when compared to the corresponding irradiated group values, table 3.

Histopathological findings

The alveoli of the control rat are lined by simple squamous epithelium. Nearby alveoli have shared inter-alveolar septa. At the open ends of the alveoli are narrow bands of smooth muscle, which extend from the muscle layer of the respiratory bronchiole (figure 1). Alveoli of the luteolin group showed the same features as controls (figure 2). In γ-rays group, the lung showed congested inter-alveolar septa blood vessels, which may be advanced to hemorrhage, in other case, emphysema may be connected with compression atelectasis of some alveoli, which decrease in size with thickness of inter-alveolar septa. Desquamation of bronchiolar epithelial cells in its lumen is shown with mild pre-bronchial leukocytic infiltrations (figures 3. A, B, and C). On the other hand, pulmonary tissues of the luteolin & γ-rays group revealed in some cases the histological structure of the lung to have a comparatively well conserved architecture with few degenerative alterations, in other cases, lung tissue showed slightly thicker inter-alveolar septa with pre-bronchiolar rise leukocytic infiltration and proliferative pneumocytes type Π (figures 4. A and B).

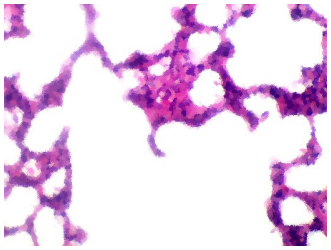

Figure 1. Lung of control rat showing normal structure (H & E ×400).

Figure 2. Lung of Luteolin rat showing normal structure (H & E ×400).

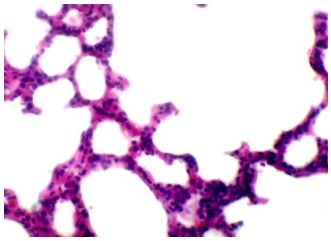

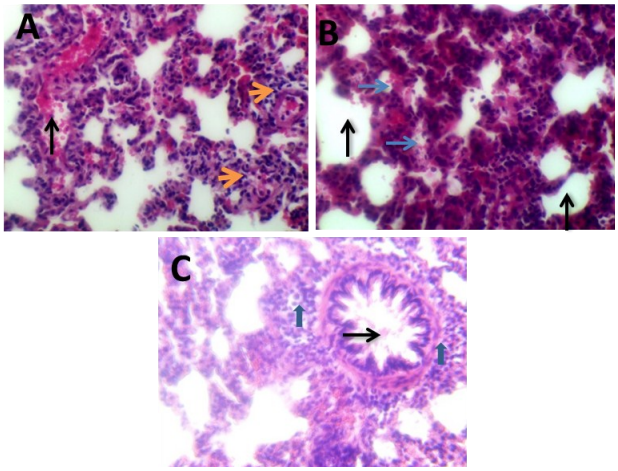

Figure 3. A) Lung of γ-rays group showing hemorrhage (↑) and proliferation of pneumocytes type II (➔). B) Lung of γ-rays group showing emphysema (↑) and collapse (➔) of some alveoli with thickness of inter-alveolar septa. C) Lung of γ-rays group showing desquamation of bronchiolar epithelia (→) with pre bronchiolar leukocytic infiltrations (↑) and slightly proliferation of pneumocytes type II. (H & E ×400).

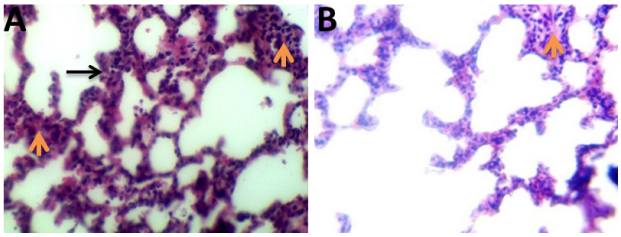

Figure 4. A) Lung of luteolin & γ-rays group showing slightly thickness of inter-alveolar septa (→) and proliferation of pneumocytes type II (↑). **B)** Lung of luteolin & γ-rays group showing normal alveoli with slightly proliferation of pneumocytes type II (↑). (H & E ×400).

DISCUSSION

The exact pathophysiology of radiation-induced lung injury is not completely understood, but the

[Downloaded from ijrr.com on 2026-11-24]

[DOI: 10.61186/ijrr.22.1.193]

data suggest that inflammation has a crucial role in the initiation and establishment of acute radiation-induced lung injury [23]. Acute lung injury is characterized by uncontrolled hyper-inflammatory responses in the lung airspaces and lung parenchyma and involves alveolar capillary membrane damage, increased vascular permeability, neutrophils enrolment, pulmonary oedema, and respiratory failure [24-28].

In the current study, the radiation pneumonitis pathological changes were recorded 3weeks post γ-rays-exposure. The mice exhibited acute radiation pneumonitis after 2weeks post-irradiation [23]. Inflammatory cell employment is an important initial step in acute lung injury, leading to the pulmonary capillary damage and an increase in alveolar epithelial permeability [29]. Gamma-rays trigger the release of inflammatory cytokines, resulting in loss of microvascular and epithelial integrity and increased interstitial and alveolar oedema [30,31]. The lungs in the irradiated rat group showed significant pathological changes, including pulmonary congestion, interstitial oedema, alveolar wall thickening, and inflammatory cell infiltration. The extent of these changes decreased after luteolin treatment in the γ-rays & luteolin group. These results suggest that luteolin can improve pathological lung changes and attenuate pulmonary oedema and vascular leakage, indicating that luteolin has protective and therapeutic effects on γ-rays-induced acute lung injury.

Hydroxyproline content, the major constituent of collagen [32], was also measured in the lungs of the rat groups. No significant difference was recorded in hydroxyproline content at the 3-week time point in the γ-rays-irradiated group in comparison to the controls. Also, hydroxyproline content was similar to the controls in both of luteolin only and γ-rays & luteolin groups. Simply put, the early-phase pneumonitis was recorded at the 3-week time point in the current study. Hydroxyproline was found to be remarkably increased at late-phase fibrosis only in radiation-induced lung injury [33].

The MDA; an indicator of oxidative stress and lipid peroxidation is an important indicator of oxidative damage [34]. In the present study, γ-rays-exposure increased the levels of MDA, which established oxidative stress due to radiation-induced pneumonitis. However, its level in the γ-rays & luteolin group significantly decreased in lung tissue (P<0.05). Inhibition of oxidative stress has been previously shown to ameliorate radiation-induced lung injury [35]. A recent study indicates that luteolin. Improves hypoxia induced pulmonary hypertension [36], and has a protective role against the methotrexate-induced hepatorenal toxicity in rats [37]. Also, luteolin significantly reverses the oxidative stress parameters that resulted in cobalt-induced cardiomyopathy and renal toxicity in rats, leading to the suppression of histopathological lesions observed in the renal and cardiac tissues [38]. Moreover, luteolin decreases the level of MDA in rat model of sodium fluoride initiated gastro-enterohepatic damage in rats [39]. These findings were confirmed by the results of the present study.

Cytokines are minor solvable proteins with a widespread array of biological action that are released by active immune cells and act as a link between inherent immunity, infection, inflammation and cancer cells [40]. Irradiation induced escalation of TNF-α and IL-6 levels in rat [41]. The current study demonstrated γ-rays mediated enhancement of TNF-α and IL-6 levels in the irradiated animal group. However, this increase in serum TNF-α and IL-6 levels was significantly blocked by luteolin treatment when compared to the corresponding irradiated rats' group. The inflammatory mediator, produced in the irradiated acute lung injury, can increase the inflammatory responses and results in pathological injuries in the lung [23]. TNF-α and IL-6 are characteristic early cytokines associated with the inflammatory process of acute lung injury [42]. The results suggest that luteolin could attenuate the inflammatory reaction in γ-rays-induced acute lung injury.

Oxidative stress is a major driving mechanism of lung tissue damage after radiation [43]. Therefore, we evaluated the anti-oxidative stress markers; SOD and GPx in lung tissue of irradiated rats. The current data revealed a lessening in the activity of SOD and GPx in γ-rays group compared with the controls. Ahmadvand *et al.* [44] found that the activity of SOD and GPx in radiation groups decreased when compared to controls. Luteolin treatment for irradiated rats improved the activity of SOD and GPx compared to the irradiated group. Akinrinde *et al.* [39] recorded that luteolin has anti-inflammatory and anti-oxidative-stress properties. Also, they established that luteolin treatment prevented the increase of SOD and GPx in cognition insufficiency following chronic cerebral hypo-perfusion in rats. Besides, Zhou *et al.* [45] confirmed the chemo preventive and the histopathological perspective of luteolin against lung cancer.

CONCLUSION

In this rat model of γ-rays-induced acute lung injury, luteolin administration post irradiation improved lung histopathological changes, reduced lung lipid peroxidation, and decreased vascular leakage and inflammatory cytokine release. It regulates antioxidant system by inhibiting radiation-induced oxidative and inflammatory stress, which has helped in minimizing radiation-provoked pneumonitis.

[Downloaded from ijrr.com on 2026-11-24]

[DOI: 10.61186/ijrr.22.1.193]

ACKNOWLEDGEMENTS

We express our gratitude to our colleagues, the Health Radiation Research Department for providing laboratory conveniences, and members of the National Center for Radiation Research and Technology (NCRRT), Egyptian Atomic Energy Authority for providing the necessary irradiation facilities. Also, the authors thank Ramy Tawfik who helped with the practical work. This work was done in the NCRRT, Egypt.

***Funding*:** Not applicable.

***Competing Interests*:**

***Conflict of interest statement*:** The authors declare that they have no conflicts of interest. The authors alone are accountable for the content and script of the article.

***Authors Contributions*:** All authors conceived, designed the study and analyzed the data. R.E. and W. E-K performed the biochemical studies. A.E-K. and performed the pathological studies. All authors prepared the manuscript.

***Ethical Approval*:** All experiments were performed in accordance with the Research Ethics Committee (REC, NCRRT) Number: 7A/20.

***Availability of data and materials*:** The datasets used and/or analyzed during the current study are available from the corresponding author on reasonable request.

REFERENCES

1. Wang L, Liu C, Lu W, *et al.* (2023) ROS-sensitive Crocin-loaded chitosan microspheres for lung targeting and attenuation of radiation-induced lung injury. *Carbohydr Polym, **307**:120628.*
2. Ma F, Zhu X, Niu Y, *et al.* (2023) FGFR inhibitors combined with nab-paclitaxel - A promising strategy to treat non-small cell lung cancer and overcome resistance. *Front Oncol, **13**:1088444.*
3. Cogno N, Bauer R, Durante M (2022) An agent-based model of radiation-induced lung fibrosis. *Int J Mol Sci, **23**(22): 13920.*
4. Shi LL, Yang JH, Yao HF (2023) Multiple regression analysis of risk factors related to radiation pneumonitis. *World J Clin Cases, **11**(5):1040-1048.*
5. Zeng Z, Xu L, Xie XY, *et al.* (2020) Pulmonary pathology of early-phase COVID-19 pneumonia in a patient with a benign lung lesion. *Histopathology, **77**(5): 823-831.*
6. Zhang Y, Chen M, Wang Y, *et al.* (2023) Effect of SIRT1 regulating Nrf2/HO-1 signaling pathway on sepsis-induced acute lung injury. *Zhonghua Wei Zhong Bing Ji Jiu Yi Xue, **35**(3): 244-249.*
7. Aryappalli P, Shabbiri K, Masad RJ, *et al.* (2019) Inhibition of Tyrosine-phosphorylated STAT3 in human breast and lung cancer cells by Manuka honey is mediated by selective antagonism of the IL-6 receptor. *Int J Mol Sci, **20**(18): 4340.*
8. Azab KS, El Fatih NM, El Tawill G, El Bakary NM (2020) Pro-apoptotic and anti-neoplastic impact of luteolin on solid Ehrlich carcinoma.bearing exposed to gamma radiation. *J Cancer Res Ther, **16**(6):1506-1516.*
9. Esmeeta A, Adhikary S, Dharshnaa V, *et al.* (2022) Plant-derived bioactive compounds in colon cancer treatment: An updated review. *Biomed Pharmacother **153**: 113384.*
10. Syahputra RA, Harahap U, Dalimunthe A, *et al.* (2022) The role of flavonoids as a cardioprotective strategy against doxorubicin-induced cardiotoxicity: A review. *Molecules, **27**(4):1320.*
11. Raghu SV, Rao S, Kini V, Kudva AK, *et al.* (2023) Fruits and their phytochemicals in mitigating the ill effects of ionizing radiation: review on the existing scientific evidence and way forward. *Food Funct, **14**(3):1290-1319.*
12. Mu J, Ma H, Chen H, *et al.* (2021) Luteolin Prevents UVB-induced skin photoaging damage by modulating SIRT3/ROS/MAPK signaling: An *in-vitro* and *in-vivo* studies. *Front Pharmacol, **12**: 728261.*
13. Kang SH, Bak DH, Lee SS, Bai HW, *et al.* (2021) Radioprotective effects of centipedegrass extract on NIH-3T3 fibroblasts via antioxidative activity. *Exp Ther Med, **21**(5): 419.*
14. Kumar P and Patel D (2021) Ocimum Sanctum: An All-Round Treatment for Cancer? *Altern Ther Health Med, **31**: AT6685.* PMID: 34331753.
15. Chen YH, Wu JX, Yang SF, Hsiao YH (2023) Synergistic combination of luteolin and asiatic acid on cervical cancer in vitro and in vivo. *Cancers (Basel), **15**(2): 548.*
16. Erdoğan MK, Ağca CA, Aşkın H (2022) Quercetin and luteolin improve the anticancer effects of 5-fluorouracil in human colorectal adenocarcinoma in vitro model: A mechanistic insight. *Nutr Cancer, **74**(2): 660-676.*
17. Yang SC, Chen PJ, Chang SH, *et al.* (2018) Luteolin attenuates neutrophilic oxidative stress and inflammatory arthritis by inhibiting Raf1 activity. *Biochem Pharmacol, **154**: 384-396.*
18. Gasperetti T, Miller T, Gao F, *et al.* (2021) Polypharmacy to mitigate acute and delayed radiation syndromes. *Front Pharmacol, **12**: 634477.*
19. Ruan JS, Liu YP, Zhang L, *et al.* (2012) Luteolin reduces the invasive potential of malignant melanoma cells by targeting β3 integrin and the epithelial-mesenchymal transition. *Acta Pharmacol Sin, **33**(10): 1325-31.*
20. Saini R, Verma S, Singh A, Gupta M (2013) Role of active principles of Podophyllum hexandrum in amelioration of radiation mediated lung injuries by reactive oxygen/nitrogen species reduction. *CellBio, **2**(3):105–16.* 21. Bancroft D, Stevens A and Turmer R (1996) Theory and practice of histological technique, 4th ed., Churchill Living Stone, Edinburgh, London, Melbourne, p. 47-67.
22. Snedecor GW, Cochran WG (1994) "Statistical Methods", 8th ed., Calcutta, India: Oxford & IBH Publishing Co, p. 503-513.
23. Arora A, Bhuria V, Singh S, *et al.* (2022) Amifostine analog, DRDE-30, alleviates radiation induced lung damage by attenuating inflammation and fibrosis. *Life Sci, **298**: 120518.*
24. Brazee PL and Sznajder JI (2020) Targeting the linear ubiquitin assembly complex to modulate the host response and improve influenza A virus induced lung injury. *Arch Bronconeumol (Engl Ed), **56**(9):586-591.*
25. Carteaux G, Parfait M, Combet M, *et al.* (2021) Patient-self inflicted lung injury: A practical review. *J Clin Med, **10**(12): 2738.*
26. Liu X, Zhang J, Xie W (2022) The role of ferroptosis in acute lung injury. *Mol Cell Biochem, **477**(5): 1453-1461.*
27. Piper A, Song Y, Eves ND, Maher TM (2014) Year in review 2013: Acute lung injury, interstitial lung diseases, sleep and physiology. *Respirology, **19**(3):428-37.*
28. Wessels I, Pupke JT, von Trotha K, *et al.* (2020) Zinc supplementation ameliorates lung injury by reducing neutrophil recruitment and activity. *Thorax, **75**(3): 253-261.*
29. Tian C, Zhang P, Yang J, *et al.* (2019) The protective effect of the flavonoid fraction of Abutilon theophrasti Medic. leaves on LPS-induced acute lung injury in via the NF-κB and MAPK signalling pathways. *Biomed Pharmacother, **109**:1024-1031.*
30. Ortiz G, Garay M, Mendoza D, Cardinal-Fernández P (2019) Impact and safety of open lung biopsy in patients with acute respiratory distress syndrome (ARDS). *Med Intensiva (Engl Ed), **43**(3): 139-146.*
31. Zhen S, Qiang R, Lu J, *et al.* (2022) TGF-β1-based CRISPR/Cas9 Gene Therapy Attenuates Radiation-induced Lung Injury. *Curr Gene Ther, **22**(1):59-65.*
32. Cao S, Xiao Y, Huang R, *et al.* (2022) Dietary supplementation with hydroxyproline enhances growth performance, collagen synthesis and muscle quality of Carassius auratus triploid. *Front Physiol, **13**: 913800.*
33. Wang J, Zhou F, Li Z, *et al.* (2018) Pharmacological targeting of BET proteins attenuates radiation-induced lung fibrosis. *Sci Rep, **8**(1): 998.*
34. Yesildag K, Gur C, Ileriturk M, Kandemir FM (2022) Evaluation of oxidative stress, inflammation, apoptosis, oxidative DNA damage and metalloproteinases in the lungs of rats treated with cadmium and carvacrol. *Mol Biol Rep, 49(2):1201-1211.* doi: 10.1007/s11033-021-06948-z.
35. Keskinidou C, Vassiliou AG, Dimopoulou I, *et al.* (2022) Mechanistic understanding of lung inflammation: Recent advances and emerging techniques. *J Inflamm Res, **15**: 3501-3546.*
36. Ji L, Su S, Xin M, *et al.* (2022) Luteolin ameliorates hypoxia-induced pulmonary hypertension via regulating HIF-2α-Arg-NO axis and

[Downloaded from ijrr.com on 2026-11-24]

[DOI: 10.61186/ijrr.22.1.193]

PI3K-AKT-eNOS-NO signaling pathway. *Phytomedicine,* ***104****: 154329.*

37. Dar AA, Fehaid A, Alkhatani S, *et al.* (2021) The protective role of luteolin against the methotrexate-induced hepato-renal toxicity via its antioxidative, anti-inflammatory, and anti-apoptotic effects in rats. *Hum Exp Toxicol,* ***40****(7):1194-1207.*
38. Oyagbemi AA, Akinrinde AS, Adebiyi OE, *et al.* (2020) Luteolin supplementation ameliorates cobalt-induced oxidative stress and inflammation by suppressing NF-κB/Kim-1 signaling in the heart and kidney of rats. *Environ Toxicol Pharmacol,* ***80****:103488.*
39. Akinrinde AS, Soetan KO, Tijani MO (2022) Exacerbation of diclofenac-induced gastroenterohepatic damage by concomitant exposure to sodium fluoride in rats: protective role of luteolin. *Drug Chem Toxicol,* ***45****(3): 999-1011.*
40. Wang M, Zhai X, Li J, *et al.* (2021) The Role of cytokines in predicting the response and adverse events related to immune checkpoint inhibitors. *Front Immunol,* ***12****:670391.*
41. Zhou YS, Cui Y, Zheng JX, *et al.* (2022) Luteolin relieves lung cancer -induced bone pain by inhibiting NLRP3 inflammasomes and glial activation in the spinal dorsal horn in. *Phytomedicine,* ***96****:153910.*
42. Durkin A, Vu HY, Lee H (2020) The VR23 antitumor compound also shows strong anti-inflammatory effects in a human rheumatoid arthritis cell model and acute lung inflammation in . *J Immunol,* ***204****(4):788-795.*
43. Abo-Zaid OA, Moawed FS, Hassan HA, Moustafa EM (2022) Bisphenol-A/Radiation mediated inflammatory response activates EGFR/KRAS/ERK1/2 signaling pathway leads to lung carcinogenesis incidence. *Int J Immunopathol Pharmacol,* ***36****: 3946320221092918.*
44. Ahmadvand MH, Nikzad S, Changizi V, *et al.* (2023) Evaluation of the Mitigation Effect of Spirulina against lung injury induced by radiation in rats. *Curr Radiopharm,* ***16****(1): 71-77.*
45. Zhou J, Wu P, Sun H, *et al.* (2022) Lung tissue extracellular matrix-derived hydrogels protect against radiation-induced lung injury by suppressing epithelial-mesenchymal transition. *J Cell Physiol,* ***235*** *(3): 2377-2388.*

[Downloaded from ijrr.com on 2026-11-24]

[DOI: 10.61186/ijrr.22.1.193]