

Secondary sequencing assisted diagnosis of pulmonary infection caused by *Aspergillus oryzae* in children with acute lymphoblastic leukemia: a case report

Z. Wang[#], Q. Liu[#], D. Wang, N. Zhang, H. Jiang, H. Li^{*}, J. Shao^{*}

Shanghai Children's Hospital, School of medicine, Shanghai Jiao Tong University, Shanghai 200040, China

► Case report

*Corresponding author:

Jingbo Shao & Hong Li, Ph.D.,

E-mail:

Shaojingbo2024@163.com,

Lihong131313@163.com

Received: September 2023

Final revised: October 2023

Accepted: November 2023

Int. J. Radiat. Res., January 2024;
22(1): 229-233

DOI: 10.52547/ijrr.21.33

Keywords: *Aspergillus oryzae*, pediatrics, precursor cell lymphoblastic leukemia, invasive pulmonary aspergillosis, ct imaging.

[#]Zhen Wang and Qing Liu contributed equally.

CORE TIPS

An 8-year-old male patient with ALL developed severe pneumonia during chemotherapy. The infection was found to be caused by *Aspergillus oryzae*, which was identified using the second-generation sequencing of alveolar lavage fluid. The patient received antifungal treatment with caspofungin and voriconazole, which showed a good therapeutic effect. However, the patient experienced massive hemoptysis. After the successful rescue, the patient received pulmonary lobectomy and purulent moss stripping and finally recovered.

INTRODUCTION

Due to the application of immunosuppressants and intensive therapy, the incidence of pulmonary Aspergillosis has increased. Invasive pulmonary Aspergillosis (IPA), if not treated promptly, has a high mortality rate ^(1,2). The most common pathogen of pulmonary Aspergillosis is *Aspergillus fumigatus*, followed by *Aspergillus flavus* ⁽²⁾. However, pulmonary Aspergillosis caused by *Aspergillus oryzae*,

ABSTRACT

Background: Pulmonary *Aspergillus* has a high incidence and mortality rate, but is difficult to be diagnosed. It is mainly caused by *Aspergillus fumigatus*. Pulmonary *Aspergillus* caused by *Aspergillus oryzae* is rare. This case reports an 8-year-old male patient with acute lymphoblastic leukemia (ALL) who was found to have pulmonary *Aspergillus oryzae* infection by NGS of alveolar lavage fluid. **Case Summary:** The patient had ALL and received induction remission chemotherapy. During chemotherapy, the patient developed severe agranulocytosis and severe pneumonia. The treatment was performed accordingly. The second-generation sequencing of alveolar lavage fluid identified the pathogen as *Aspergillus oryzae*. After combined antifungal treatment with caspofungin and voriconazole, pneumonia was absorbed and improved. One week later, spontaneous fluid pneumothorax accompanied by massive hemoptysis occurred, and the patient received rescue therapy, which was successful. Finally, the patient recovered after pulmonary lobectomy and purulent moss stripping. **Conclusion:** Early diagnosis and treatment of pulmonary Aspergillosis are very important. *Aspergillus oryzae* infection has only rarely been reported in humans. Second-generation sequencing of alveolar lavage fluid is an accurate and effective detection method to assist diagnosis of microorganism infection. Combination of caspofungin and voriconazole is an effective method to treat severe *Aspergillus* pneumonia.

which is used for industrial fermentation, is rarely reported. Herein, we reported an 8-year-old male patient with ALL who was diagnosed with pulmonary *Aspergillus oryzae* infection by second-generation sequencing of alveolar lavage fluid.

CASE PRESENTATION

Chief complaint

An 8-year-old male patient presented with the chief complaints of "fever and cough for 2 days, and skin congestion for half a day".

History of present illness

On July 31, 2020, the patient was admitted to the hospital due to fever and cough for 2 days and skin congestion for half a day. According to the Chinese Children's Cancer Group Study-ALL 2020 (CCCG-ALL-2020) protocol and based on the results of peripheral blood routine, bone marrow Morphology, Immunology, Cytogenetics, Molecular biology and other examinations (Flow cytometry cantO2: Biosciences, America; RT-PCR and FISH detection kit: Shanghai Yuanqi Biotechnology Company), the patient was diagnosed as ALL (Ph+, MR). Then, the

induction remission chemotherapy and dasatinib targeted therapy were started. On day 19 of treatment, bone marrow smear showed remission, with a minimal residual disease of 0.62%.

On August 26, the patient had recurrent fever, but no cough. Blood routine showed severe agranulocytosis and high C-Reactive Protein. The chest CT (GE Prospeed, America) showed exudation (figures 1 A1 and A2). The patient was given empirical anti-bacterial treatment and fluconazole antifungal treatment. The fever of the patient did not improve. On August 28, the chest CT showed that exudation was worse than before (figures 1 B1 and B2). The patient was given voriconazole antifungal treatment. On August 31, the body temperature was still high and there was respiratory failure.

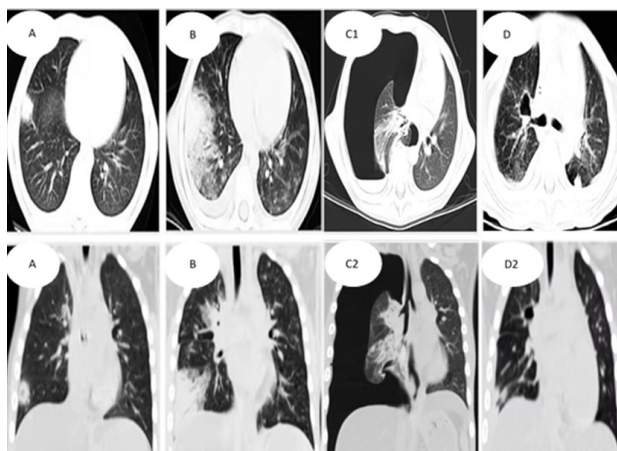


Figure 1. Pulmonary imaging. Chest CT showed exudation (A1 and A2); Chest CT showed that it was worse than before (B1 and B2); Chest CT showed massive pneumothorax with atelectasis and exudation on the right side (C1 and C2); Chest CT showed that the pneumothorax disappeared and the pleural effusion was absorbed (D1 and D2).

After 3 days of combined anti-infection treatment with voriconazole and caspofungin, the body temperature and lung characters improved, and there was obvious pneumonia absorption. On September 2, under bronchoscope (BF TYPE tE60f, Japan), yellow and white secretions were observed in the dorsal segment of the lower lobe of the left lung, the middle lobe of the right lung, and the anterior, posterior and outer basal segments of the lower lobe (figures 2A and 2B). The results of improved bronchoscopy and alveolar lavage fluid examination showed *Aspergillus oryzae* infection. On September 10, the patient developed sudden chest pain with decreased oxygen saturation, and the chest CT revealed massive pneumothorax with lung compression (figures 1C1 and C2). Oxygen inhalation was given, and 600 ml of air was aspirated by thoracentesis. Then, massive hemoptysis occurred, with dark red blood clots and a blood volume of about 160 ml (figure 2C).

There was also shortness of breath. The blood oxygen saturation was 75% and the blood pressure

was 56/25 mmHg. Emergency endotracheal intubation, ventilator-assisted ventilation, closed thoracic drainage, and red blood cell infusion were performed to restore the vital signs of the patient. After voriconazole antifungal treatment, the pneumonia was absorbed and improved. The tracheal intubation was removed one week later. On September 23, the thoracic drainage tube was attempted to be clamped but failed, with a large amount of gas accumulating in the thoracic cavity again. On September 29, pulmonary lobectomy and purulent moss stripping were performed.

During the operation, the lungs were re-dilated. Postoperative pulmonary histopathology showed congestion in the alveolar cavity, tissue cell aggregation, local fibrous hyperplasia and consolidation, and local granulation tissue formation as well as emphysema, alveolar expansion, rupture of pulmonary septum, and alveolar fusion (figure 3). Fungal fluorescent staining was negative. One week after the operation, the chest CT showed that the pneumonia was absorbed and improved, and no gas accumulation and effusion were found (figures 1 D1 and D2).

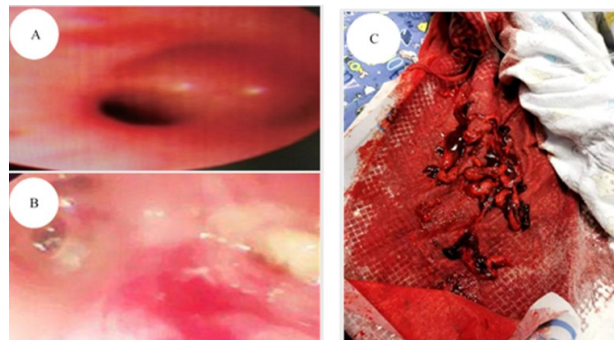


Figure 2. Under bronchoscope, yellow and white secretions were observed in the dorsal segment of the lower lobe of the left lung, the middle lobe of the right lung, and the anterior, posterior and outer basal segments of the lower lobe (A and B). Massive dark red blood clots were observed after hemoptysis on September 10 (C).

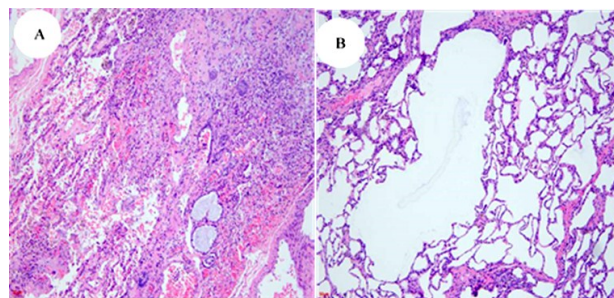


Figure 3. Postoperative pulmonary histopathology. A: There was congestion in the alveolar cavity, tissue cell aggregation, local fibrous hyperplasia and consolidation, and local granulation tissue formation. B: Emphysema, alveolar expansion, rupture of pulmonary septum, and alveolar fusion were also observed. Fungal fluorescent staining was negative.

History of past illness

The patient had no history of past illness.

Personal and family history

The living place of the patient was clean and tidy. The history of contact with animals, industrial food, and fungi for fermentation was denied. There was no history of infectious disease in the family of the patient.

Physical examination

When the patient was diagnosed with pneumonia, his body temperature was 39 degrees Celsius, the respiration rate was 30 times/min, the pulse rate was 105 times/min, and the blood pressure was 96/50 mmHg. There were a few rales in the lungs.

When pneumothorax and hemoptysis occurred, his body temperature was 36.5 degrees Celsius, the respiration rate was 35-40 times/min, the pulse rate was 105-125 times/min, the oxygen saturation was 89%, and the blood pressure was 90/45 mmHg. The respiratory sound in the right lung disappeared, and there were a few rales in the left lung. After hemoptysis, the blood pressure was 56/25 mmHg.

Laboratory examinations

When the patient was diagnosed with pneumonia, the white blood cell count was $0.5 \times 10^9/L$ (reference range: $4.0-10.0 \times 10^9/L$), the hemoglobin was 74 g/L (110-160 g/L), the neutrophil percentage was 39.2% (50%-70%), the lymphocyte percentage was 60.8% (30%-40%), and the hypersensitive C-reactive protein was 136 mg/L (<5 mg/L). The serum (1-3)-beta-D-glucan (G) and galactomannan (GM) tests were negative.

After bronchoscopy, the procalcitonin was 1.94 ng/ml (<0.1). The serum G test was negative. The GM test result of the alveolar lavage fluid was 0.9 (<0.65), while the serum GM test result was 0.75 (<0.65). The fungal cultures or smears of sputum and alveolar lavage fluid were negative. *Aspergillus oryzae* was detected by second-generation sequencing of alveolar lavage fluid.

When there were pneumothorax and hemoptysis, the white blood cell count was $6.9 \times 10^9/L$, the hemoglobin was 80 g/L, the neutrophil percentage was 71.2%, the lymphocyte percentage was 16.8%, the hypersensitive C-reactive protein was 63 mg/L, and the serum GM test result was 0.61. The pathogen in the fresh blood clots after hemoptysis was identified as *Aspergillus oryzae* by second-generation sequencing. No abnormality was found in coagulation function, liver and kidney function, electrolyte, etc.

On August 26, Chest CT showed exudation (figures 1 A1 and A2). On August 28, the chest CT showed that it was worse than before (figures 1 B1 and B2). On September 2, the bronchoscopy was given (figures 2A and 2B). On September 10, the chest CT revealed massive pneumothorax with lung compression (figures 1C1 and C2). Then, massive hemoptysis occurred, with dark red blood clots and a blood volume of about 160 ml (figure 2C). One week after

the operation, the chest CT showed that the pneumonia was absorbed and improved, and no gas accumulation and effusion were found (figures 1 D1 and D2).

Imaging examinations

Final Diagnosis

Based on the above findings, the diagnoses of IPA, tension pneumothorax, haemoptysis, and pulmonary *Aspergillus oryzae* infection were made.

Treatment

According to the Chinese guidelines for the diagnosis and treatment of invasive fungal disease in patients with hematological disorders and cancers, empirical fluconazole (12 mg/kg qd) antifungal treatment was given for 2 days, followed by intravenous treatment of voriconazole (8 mg/kg q12h) for 3 days. The pulmonary symptoms and vital signs worsened and respiratory failure occurred. Then, combined treatment with voriconazole (8 mg/kg q12h) and caspofungin (First dose: 70mg/m², after: 50mg/m²) was given intravenously for 5 days. The pulmonary infection was quickly and effectively controlled. After that, according to the results of alveolar lavage fluid examinations, the treatment was switched to maintenance treatment with intravenous voriconazole. The pneumonia was absorbed and improved.

After successful rescue treatment of pneumothorax and hemoptysis, Voriconazole antifungal treatment continues for 3 months (8 mg/kg q12h, intravenous continuous oral administration). The tracheal intubation was removed one week later. On September 23 (2 weeks later), an attempt was made to clamp the thoracic drainage tube but failed. A large amount of gas accumulated in the thoracic cavity again. Cardiothoracic surgery with right empyema fibreboard stripping was performed. During the operation, it was found that there was a cavity with a diameter of 2 cm in the lower lobe of the right lung, with air leakage. The lower lobe of the right lung was repaired. Lung tissue samples obtained during surgery were fixed with 4% neutral formaldehyde, routine Dehydration, paraffin embedding, and 3mm section were performed for HE staining and immunohistochemical labeling, fungal fluorescence staining respectively. Postoperative pathology showed that the inflammatory changes in the lung tissue were accompanied by bleeding and the development of emphysema (figure 3). Fungal fluorescent staining was negative (All chemical reagents were purchased from GeneTech (Shanghai) Company Limited). After the operation, the lung was dilated again. The thoracic drainage tube was removed one week later, and no pneumothorax occurred again. CT examination showed that the pneumonia was obviously absorbed (figures 1 D1 and

D2).

Outcome and follow-up

Three months after the operation, a chest CT reexamination on January 3, 2021 showed that pneumonia was obviously absorbed.

DISCUSSION

In recent years, with the increase of chemotherapy intensity and the application of small-molecule targeted drugs in hematological malignancies, the incidence of IPA in children has been increasing rapidly. The clinical symptoms of IPA are not specific, and the diagnosis is difficult. Therefore, most children with IPA are not diagnosed and treated promptly, and the mortality is as high as 62%-100%^(1,2).

In this report, the case was an ALL patient with severe neutropenia after induction chemotherapy, and the neutropenia lasted for more than 10 days. It is reported that after the application of high-dose glucocorticoid and other high-risk factors for invasive fungal disease (IFD)⁽³⁻⁶⁾, there was agranulocytosis accompanied by fever. When chest CT showed exudation, blood G and GM tests were negative. Antifungal treatments with fluconazole and voriconazole were given successively. Pneumonia was aggravated and respiratory failure occurred. The lung signs obviously improved after combined voriconazole and carbophenazine, and anti-bacterial treatments. During this period, bronchoscopic alveolar lavage was performed. The GM test result of alveolar lavage fluid was 0.9 (< 0.65), and the serum GM test result was 0.75 (< 0.65). *Aspergillus oryzae* was detected by second-generation sequencing of alveolar lavage fluid. According to the "Revision and update of the consensus definitions of invasive fungal disease from the European Organization For Research and Treatment of Cancer and Mycoses Study Group Education and Research Consortium"⁽⁶⁾ issued by the Infectious Diseases Society of America in 2020, this case in the present report was clinically diagnosed as IPA.

It is reported that the pathogens of IPA are mostly *Aspergillus fumigatus*, followed by *Aspergillus flavus* and *Aspergillus niger*⁽⁷⁾. Pulmonary infection of *Aspergillus oryzae* is rare. *Aspergillus flavus* is one of the most important pathogens of invasive and non-invasive Aspergillosis, especially in tropical and subtropical regions of the world, including Iran. *Aspergillus oryzae* is closely related to *Aspergillus flavus*, and it is known for its economic importance in traditional fermentation industry. There are few studies on the infections caused by *Aspergillus oryzae*^(8,9) and most studies have focused on allergic aspergillosis caused by *Aspergillus oryzae* in Japan⁽¹⁰⁻¹⁵⁾.

According to the diagnostic criteria and treatment principles of invasive mycosis in patients with hematological diseases/malignant tumors (the sixth revision)⁽¹⁶⁾, for high-risk cases with single drug treatment failure, early antifungal treatment with the combination of two drugs can significantly improve the efficacy^(8,17).

Massive hemoptysis refers to the expectoration of 100 to 1000 mL of blood within 24 hours. Massive hemoptysis usually occurs during the period of bone marrow recovery, which is a life-threatening complication of IPA^(18,19). In this report, the patient received combined antifungal treatment for nearly 3 weeks; however, the cavities of the lungs were not repaired. Finally, the right empyema fiberboard stripping and lobectomy were performed, which was therapeutic for this patient. Surgical treatment can remove the residual lesions, prevent fungal recurrence during further immunosuppressive treatment, and prevent the recurrence of hemoptysis. For patients without improvement after antifungal treatment, especially those with cavity lesions, early surgical intervention is recommended to effectively improve the prognosis⁽²⁰⁾.

ACKNOWLEDGMENT

The authors would like to thank Top Edit (www.topeditsci.com) for its linguistic assistance during the preparation of this manuscript.

Conflict of Interests: The authors declared no conflict of interest.

Ethical statement: This study was approved by the Ethics Committee of Children' Hospital of Shanghai/ Shanghai Children's Hospital, Shanghai Jiao Tong University (Approval No:2022R013-E02).

Funding: The role of TGFβ1-PI3K/AKT-GLI signaling axis in epithelial-mesenchymal transformation in neuroblastoma, Project No. 2020YGZM05; An observational study of low-dose decitabine after hematopoietic stem cell transplantation in children with high-risk AML. Project No. 2021R123.

Authors' contributions: Zhen Wang, Hong Li and Jingbo Shao designed the study and performed the experiments, Qing Liu and Dan Wang collected the data, Na Zhang and Hui Jiang analyzed the data, Zhen Wang, Hong Li and Jingbo Shao prepared the manuscript. All authors read and approved the final manuscript.

Consent for publication: The written consent for publication of clinical details and radiologic images was obtained from the guardian for patient who under 17 years old.

REFERENCES

1. Ledoux MP, Guffroy B, Nivoix Y, et al. (2020) Invasive pulmonary aspergillosis. *Seminars in Respiratory and Critical Care Medicine*, **41**(1): 80-98.

2. Yeoh DK, McMullan BJ, Clark JE (2023) The challenge of diagnosing invasive pulmonary aspergillosis in children: A review of existing and emerging tools. *Mycopathologia*, **188**(5): 731-743.
3. Sun Y, Huang H, Chen J, et al. (2015) Invasive fungal infection in patients receiving chemotherapy for hematological malignancy: a multicenter, prospective, observational study in China. *Tumour Biol*, **36**(2): 757-767.
4. Sun Y, Meng F, Han M, et al. (2015) Epidemiology, management, and outcome of invasive fungal disease in patients undergoing hematopoietic stem cell transplantation in China: a multicenter prospective observational study. *Biology of Blood and Marrow Transplantation*, **21**(6): 1117-1126.
5. Ghez D, Calleja A, Protin C, et al. (2018) Early-onset invasive aspergillosis and other fungal infections in patients treated with ibrutinib. *Blood*, **131**(17): 1955-1959.
6. Wang L, Wang Y, Hu J, et al. (2019) Clinical risk score for invasive fungal diseases in patients with hematological malignancies undergoing chemotherapy: China Assessment of Antifungal Therapy in Hematological Diseases (CAESAR) study. *Frontiers of Medicine*, **13**(3): 365-377.
7. Wang Y, Zhang L, Zhou L, et al. (2022) Epidemiology, Drug Susceptibility, and Clinical Risk Factors in Patients With Invasive Aspergillosis. *Frontiers in Public Health*, **10**: 835092.
8. Donnelly JP, Chen SC, Kauffman CA et al. (2020) Revision and update of the consensus definitions of invasive fungal disease from the European organization for research and treatment of cancer and the mycoses study group education and research consortium. *Clinical Infectious Diseases*, **71**(6): 1367-1376.
9. Payne GA, Nierman WC, Wortman JR et al. (2006) Whole genome comparison of *Aspergillus flavus* and *A. oryzae*. *Medical Mycology*, **44**(Supplement_1): S9-S11.
10. Nargesi S, Abastabar M, Valadan R et al. (2021) Differentiation of *Aspergillus flavus* from *Aspergillus oryzae* Targeting the cyp51A Gene. *Pathogens*, **10**(10):
11. Schwetz I, Horina J, Buzina W, et al. (2007) *Aspergillus oryzae* peritonitis in CAPD: case report and review of the literature. *American Journal of Kidney Diseases*, **49**(5): 701-704.
12. Mazza A, Luciani N, Luciani M, et al. (2017) Fungal endocarditis due to *aspergillus oryzae*: The first case reported in the literature. *J Heart Valve Dis*, **26**(2): 205-207.
13. Stenson S, Brookner A, Rosenthal S (1982) Bilateral endogenous necrotizing scleritis due to *Aspergillus oryzae*. *Ann Ophthalmol*, **14**(1): 67-72.
14. Byard RW, Bonin RA, Haq AU (1986) Invasion of paranasal sinuses by *Aspergillus oryzae*. *Mycopathologia*, **96**(1): 41-43.
15. Akiyama K, Takizawa H, Suzuki M, et al. (1987) Allergic bronchopulmonary aspergillosis due to *Aspergillus oryzae*. *Chest*, **91**(2): 285-286.
16. Kino T, Chihara J, Mitsuyasu K, et al. (1982) [A case of allergic bronchopulmonary aspergillosis caused by *Aspergillus oryzae* which is used for brewing bean paste (miso) and soy sauce (shoyu) (author's transl)]. *Nihon Kyobu Shikkan Gakkai Zasshi*, **20**(4): 467-475.
17. The Chinese guidelines for the diagnosis and treatment of invasive fungal disease in patients with hematological disorders and cancers (the 6th revision) (2020). *Zhonghua Nei Ke Za Zhi*, **59**(10): 754-763.
18. Gurlek GD, Fettah A, Kirbas I, et al. (2015) Successful Off-Label Use of Recombinant Factor VIIa and coil embolization in an adolescent with massive hemoptysis due to invasive pulmonary aspergillosis. *Turkish Journal of Hematology*, **32**(1): 73-76.
19. Piracha S, Mahmood A, Qayyum N, Ganaie MB (2018) Massive haemoptysis secondary to mycotic pulmonary artery aneurysm in subacute invasive aspergillosis. *Bmj Case Reports*, **2018**: bcr2017223088.
20. AlShanafey S, AlMoosa N, Hussain B, AlHindi H (2019) Surgical management of pulmonary aspergillosis in pediatric population. *Journal of Pediatric Surgery*, **54**(9): 1938-1940.

