

The value of magnetic resonance diffusion weighted imaging sequence and T2 mapping imaging technology in evaluating knee joint defects

C.Z. Huang[#], C.K. Lin^{*#}, Q.M. Fu, J.H. Huang, N.L. Jia, Y. Chen^{*}

Department of Radiological, The second Affiliated Hospital of Hainan Medical University, Hainan, China

► Original article

*Corresponding author:

Yan Chen, Changkun Lin, Ph.D.,

E-mail: chenyl86a@163.com;

724897505@qq.com

Received: November 2023

Final revised: January 2024

Accepted: February 2024

Int. J. Radiat. Res., April 2024;
22(2): 271-275

DOI: 10.61186/ijrr.22.2.271

Keywords: Knee osteoarthritis (KOA), magnetic resonance imaging (MRI), diffusion-weighted imaging (DWI), T2 mapping, cartilage degeneration.

#these authors contributed equally to this work.

ABSTRACT

Background: Diagnosing knee osteoarthritis (KOA) often relies on limited routine methods. This study investigates the efficacy of T2 mapping and Apparent Diffusion Coefficient (ADC) values in MRI for enhanced assessment of cartilage damage in KOA, focusing on their correlation with pain severity. **Materials and Methods:** A total of 52 KOA patients (74 knee joints) and 50 healthy individuals (100 knee joints) were assessed from May 2022 to June 2023. Both groups underwent MRI with Diffusion Weighted Imaging (DWI) sequence and T2 mapping to analyze ADC and T2 mapping values across femoral condyle, tibial plateau, and patellar joint surfaces, and their correlation with pain levels. **Results:** The KOA group showed significantly higher ADC and T2 mapping values in all examined areas compared to the control group ($P < 0.05$). These values were also higher in advanced stages of cartilage degeneration and correlated positively with increased pain scores ($P < 0.05$). **Conclusion:** MRI utilizing DWI and T2 mapping provides a quantitative reflection of knee joint cartilage degeneration in KOA. These methods show a positive correlation with pain severity, suggesting their potential for more accurate KOA diagnostics and assessment.

INTRODUCTION

Knee osteoarthritis (KOA) is a common clinical joint pathology characterized primarily by degeneration of joint cartilage and osteophyte formation ⁽¹⁾. When severe, this condition can cause joint mobility impairments, significantly impacting patients' quality of life ⁽²⁻³⁾. Prompt diagnosis and treatment of joint cartilage damage are crucial for improving the prognosis of patients with KOA. Clinically, X-ray examination is commonly used for detection, but it has the disadvantage of radiation exposure ⁽⁴⁾. Magnetic resonance imaging (MRI) is an effective, non-invasive, and radiation-free method for directly visualizing joint cartilage damage. However, traditional MRI imaging struggles to quantitatively assess the degree of knee joint cartilage degeneration and is less sensitive in detecting biochemical changes ⁽⁵⁾. Therefore, identifying accurate and highly sensitive diagnostic methods for knee joint cartilage degeneration is of great importance. Imaging sequences such as T2 relaxation time mapping (T2* mapping), diffusion tensor imaging, and diffusion weighted imaging (DWI) can detect morphological changes in the early stages of cartilage damage,

holding significant clinical value, and T2 mapping technology has been initially used for quantitative assessment of changes in biochemical components within cartilage ⁽⁶⁻⁷⁾. Current research, both domestic and international, mainly focuses on technologies like T2* mapping and DWI, obtaining quantitative parameters such as T2* mapping and Apparent Diffusion Coefficient (ADC) values to assist in the clinical diagnosis of KOA cartilage degeneration. However, studies on the combined analysis of ADC and T2* mapping in assessing KOA knee joint cartilage damage are limited ⁽⁶⁻⁷⁾. In light of this, our study measures and analyzes the T2* mapping and ADC values in the knee joint cartilage of both healthy individuals and KOA patients, exploring their quantitative diagnostic value in KOA knee joint cartilage damage.

MATERIALS AND METHODS

Baseline information

From May 2022 to June 2023, 52 KOA patients with 74 knee joints were enrolled in the KOA group, while 50 healthy individuals with 100 knee joints

were enrolled as controls in normal group. This study has been approved by The Ethics Committee of The second Affiliated Hospital of Hainan Medical University (Approval number: 202205031), and all participants and their families have signed informed consent. The clinical characteristics of the KOA group and normal group were compared and shown in table 1. Inclusion criteria were as follows: (1) KOA diagnosis that met the standards ⁽⁸⁾; (2) no history of lower limb trauma or surgery; (3) age > 30 years; (4) informed consent from the subjects. Exclusion criteria were as follows: (1) presence of gout, rheumatoid arthritis, or other rheumatic diseases; (2) history of intra-articular treatment in the past 2 months.

Table 1. Comparison of baseline information between KOA group and control group.

Group	N	Gender		Age (years)	BMI (kg/m ²)
		Female	Male		
KOA group	52	33 (63.46)	19 (36.54)	57.85±8.22	21.54±1.32
Control group	50	34 (68.00)	16 (32.00)	58.10±9.31	21.80±1.51
t/c ²		0.233		-0.144	-0.927
P		0.629		0.886	0.356

Examination methods

The imaging equipment used for the examination was the Siemens Skyra 3.0T (Siemens Healthineers, Erlangen, Germany) superconducting Magnetic Resonance (MR) scanner. Standard T1-weighted imaging (T1WI) and T2-weighted imaging (T2WI) scans were performed. T2 mapping was performed with the following parameters: Repetition Time (TR)=1000 ms, Echo Time(TE)=9.9 ms, slice thickness=4mm, gap=0.8mm, Number of Excitations (NEX)=1. The acquired images were transferred to the GE ADW 4.4 workstation(GE HealthCare, USA) for analysis, and the Map software was used to process the T2* mapping pseudo-color images. The T2 mapping values of the knee joint cartilage were measured, and three measurements were taken and averaged.

For the DWI sequence examination, DWI images with a b value of 800 were selected on the Siemens Syngo View workstation. Three regions of interest were defined on the lateral condyle of the femur, medial plateau of the tibia, and articular surface of the patella to obtain three ADC values. The average value was taken as the final result.

The Visual Analog Scale (VAS) was used to assess the patient's pain intensity, with a total score of 10. A higher score indicates more severe pain ⁽⁹⁾.

Image analysis

The film readings were performed by two associate chief physicians. If there were inconsistent results, they would discuss and reach a consensus. The severity of knee joint cartilage degeneration was assessed according to the Recht MRI grading criteria. The grading criteria are as follows: Grade 0: Smooth

cartilage surface with diffuse thinning; Grade I: Smooth cartilage surface with gradual loss of layered structure and low signal intensity; Grade II: Cartilage defect with a depth less than 1/2 and irregular contour; Grade III: Markedly irregular cartilage contour with a defect depth greater than half; Grade IV: Signal changes in the cartilage bone and full-thickness cartilage defect ⁽¹⁰⁾.

Statistical analysis

The Statistic Package for Social Science (SPSS) 22.0 software (IBM, Armonk, NY, USA) was used, and the measurement data were expressed as mean ± standard deviation. The t-test was used to analyze the differences between two groups, and the variance test was used to analyze the differences among multiple groups. The count data were expressed as n (%) and analyzed using the chi-squared test to determine differences between groups. The correlation between ADC values, T2 mapping values, and pain scores was analyzed using Pearson correlation analysis. Statistical significance was set at P < 0.05.

RESULTS

Comparison of ADC values and T2-mapping values between KOA group and normal group.

As shown in table 2, the comparison between the KOA group and the control group revealed significant differences in ADC and T2-mapping values across various knee joint regions. In the KOA group (n=74), ADC values were elevated in the lateral femoral condyle (1.23±0.34 vs. 0.98±0.20), tibial lateral platform (1.28±0.30 vs. 0.96±0.22), and facies articularis patellae (1.20±0.28 vs. 1.01±0.25), indicating altered diffusion characteristics. Additionally, T2-mapping values were significantly higher in the KOA group compared to the control group in the lateral femoral condyle (44.45±5.54 vs. 36.68±4.18), tibial lateral platform (45.50±6.18 vs. 35.17±5.20), and facies articularis patellae (43.84±5.72 vs. 35.01±5.14). Statistical analysis (t-tests) demonstrated highly significant differences (p < 0.001) for all comparisons, emphasizing the distinct imaging parameters between the KOA and normal groups.

Table 2. Comparison of apparent diffusion coefficient (ADC) values and T2-mapping values between Knee Osteoarthritis (KOA) group and normal group.

Group	Number of knee joints	ADC value (10 ⁻³ mm ² /s)			T2-mapping value (ms)		
		Lateral femoral condyle	Tibial lateral platform	Facies articularis patellae	Lateral femoral condyle	Tibial lateral platform	Facies articularis patellae
KOA group	74	1.23±0.34	1.28±0.30	1.20±0.28	44.45±5.54	45.50±6.18	43.84±5.72
Control group	100	0.98±0.20	0.96±0.22	1.01±0.25	36.68±4.18	35.17±5.20	35.01±5.14
t		6.072	8.120	4.709	10.547	11.951	10.676
P		0.000	0.000	0.000	0.000	0.000	0.000

Comparison of ADC values and T2-mapping values among KOA patients with different severity levels.

As shown in table 3, the comparison of ADC and T2-mapping values among KOA patients with different severity levels (III and IIIIV) revealed notable distinctions. In patients with mild to moderate severity (III, n=45), ADC values were significantly lower in the lateral femoral condyle (1.18 ± 0.22 vs. 1.30 ± 0.21), tibial lateral platform (1.21 ± 0.24 vs. 1.39 ± 0.27), and facies articularis patellae (1.15 ± 0.23 vs. 1.28 ± 0.21) compared to those with severe KOA (IIIIV, n=29). Correspondingly, T2-mapping values were markedly decreased in the mild to moderate group compared to the severe group in the lateral femoral condyle (42.26 ± 5.10 vs. 47.85 ± 5.19), tibial lateral platform (43.54 ± 6.82 vs. 48.54 ± 6.60), and facies articularis patellae (41.17 ± 5.80 vs. 47.98 ± 6.00). The statistical analyses (t-tests) demonstrated significant differences ($p < 0.05$) for all comparisons, indicating that ADC and T2-mapping values vary with different severity levels in KOA patients.

Table 3. Comparison of apparent diffusion coefficient (ADC) values and T2-mapping values among Knee Osteoarthritis (KOA) patients with different severity levels.

Order of severity	Number of knee joints	ADC value ($10^{-3} \text{ mm}^2/\text{s}$)			T2-mapping value (ms)		
		Lateral femoral condyle	Tibial lateral platform	Facies articularis patellae	Lateral femoral condyle	Tibial lateral platform	Facies articularis patellae
I~II	45	1.18 ± 0.22	1.21 ± 0.24	1.15 ± 0.23	42.26 ± 5.10	43.54 ± 6.82	41.17 ± 5.80
III~IV	29	1.30 ± 0.21	1.39 ± 0.27	1.28 ± 0.21	47.85 ± 5.19	48.54 ± 6.60	47.98 ± 6.00
t		-2.331	-2.999	-2.454	-4.571	-3.117	-4.865
P		0.023	0.004	0.017	0.000	0.003	0.000

Comparison of ADC values and T2-mapping values among KOA patients with different levels of pain

The comparison of ADC and T2-mapping values among KOA patients with different levels of pain demonstrated significant variations based on the severity of pain. In patients with mild pain scores of 13 (n=24), ADC values were lower in the lateral femoral condyle (1.13 ± 0.17), tibial lateral platform (1.19 ± 0.12), and facies articularis patellae (1.12 ± 0.11), along with decreased T2-mapping values (40.82 ± 4.82 , 39.82 ± 5.03 , and 39.12 ± 4.88 , respectively). As the pain severity increased to scores of 46 (n=30) and 7~10 (n=20), ADC and T2-mapping values exhibited a progressive elevation. Notably, statistical analysis (ANOVA) revealed significant differences ($p < 0.001$) among pain severity groups for all measured parameters, indicating a correlation between pain severity and alterations in imaging metrics in KOA patients. Detailed information was presented in table 4.

Correlation between ADC values, T2-mapping values, and pain levels.

The table presents the correlation analysis between ADC values, T2-mapping values, and pain

levels in KOA patients. Positive and statistically significant correlations were observed between pain scores and ADC values in the lateral femoral condyle ($r=0.445$, $p<0.001$), tibial lateral platform ($r=0.482$, $p<0.001$), and facies articularis patellae ($r=0.501$, $p<0.001$). Similarly, significant positive correlations were found between pain levels and T2-mapping values in the lateral femoral condyle ($r=0.463$, $p<0.001$), tibial lateral platform ($r=0.442$, $p<0.001$), and facies articularis patellae ($r=0.515$, $p<0.001$). These findings suggest a consistent association between the severity of pain and both diffusion and T2 relaxation characteristics in various knee joint regions among KOA patients, as shown in table 5.

Table 4. Comparison of apparent diffusion coefficient (ADC) values and T2-mapping values among Knee Osteoarthritis (KOA) patients with different levels of pain.

severity of pain	Number of knee joints	ADC value ($10^{-3} \text{ mm}^2/\text{s}$)			T2-mapping value (ms)		
		Lateral femoral condyle	Tibial lateral platform	Facies articularis patellae	Lateral femoral condyle	Tibial lateral platform	Facies articularis patellae
1~3 score	24	1.13 ± 0.17	1.19 ± 0.12	1.12 ± 0.11	40.82 ± 4.82	39.82 ± 5.03	39.12 ± 4.88
4~6 score	30	$1.25 \pm 0.14a$	$1.29 \pm 0.11a$	$1.23 \pm 0.10a$	$44.42 \pm 5.10a$	$43.42 \pm 5.11a$	$43.08 \pm 4.82a$
7~10 score	20	$1.32 \pm 0.15ab$	$1.37 \pm 0.12ab$	$1.30 \pm 0.12ab$	$48.85 \pm 4.98ab$	$48.18 \pm 4.92ab$	$50.64 \pm 4.90ab$
F		8.850	13.348	14.585	14.191	15.059	15.059
P		0.000	0.000	0.000	0.000	0.000	0.000

a: Comparison of group a with groups 1-3 showed a significance level of $P<0.05$; b: comparison of group b with groups 4-6 also showed a significance level of $P<0.05$.

Table 5. Correlation between apparent diffusion coefficient (ADC) value, T2-mapping value, and pain levels.

Indicator	Pain score	
	r	P
ADC value of lateral femoral condyle	0.445	0.000
ADC value of tibial lateral platform	0.482	0.000
ADC value of facies articularis patellae	0.501	0.000
T2-mapping value of lateral femoral condyle	0.463	0.000
T2-mapping value of tibial lateral platform	0.442	0.000
T2-mapping value of facies articularis patellae	0.515	0.000

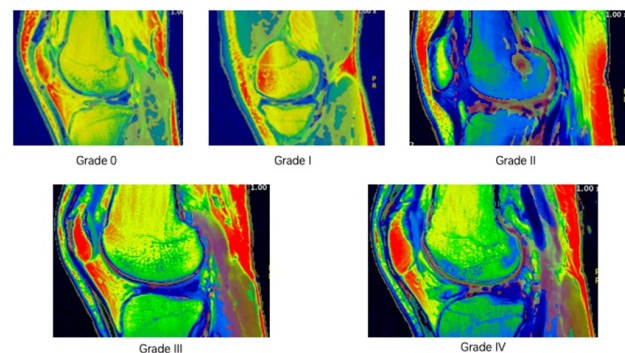


Figure 1. MRI grading criteria for the severity of cartilage degeneration of the knee joint.

DISCUSSION

At present, arthroscopic examination is a common method for diagnosing KOA, capable of evaluating the degree of knee joint cartilage degeneration. However,

it is an invasive procedure with high costs, making it unsuitable for widespread use ⁽¹¹⁾. MRI offers the advantages of being non-invasive and simple to operate, playing a crucial role in the assessment of KOA lesions. This study aims to explore the value of MRI's DWI sequence and T2* mapping imaging technology in assessing cartilage degeneration in KOA knee joints and their correlation with the severity of pain.

The ADC values obtained from the DWI sequence reflect the extent of molecular diffusion and are one of the main quantitative measures in MRI ⁽¹²⁾. Studies have shown ⁽¹³⁾ that ADC values play a significant role in assessing joint cartilage lesions and are sensitive and stable quantitative indicators. Our study reveals that the ADC values of the femoral condyle, tibial plateau, and patellar joint surface in the KOA group are significantly higher compared to the normal group. Previous research ⁽¹⁴⁾ has found that the diffusivity of joint cartilage is related to its water content, and DWI can examine this relationship. In the KOA group, the rapid outflow of water from the cartilage under load and the loss of proteoglycans create a large expansion space, increasing the water content. Combined with our study results, the decrease in collagen and proteoglycan content within the joint cartilage of KOA patients, and the increase in water content, lead to elevated ADC values, consistent with previous findings.

Our study indicates that the ADC values for the femoral condyle, tibial plateau, and patellar joint surface in grade III-IV knee joint cartilage degeneration are significantly higher than those in grades I-II, and these ADC values positively correlate with pain scores. As degeneration progresses, the internal water content of the cartilage increases, decreasing resistance and facilitating faster diffusion of water molecules, further elevating the ADC values ⁽¹⁵⁾. Research suggests ⁽¹⁶⁾ that the degree of pain in patients correlates with the extent of local damage in KOA. The DWI technique allows macroscopic observation of water molecule movement, and measuring ADC values can transform qualitative analysis of joint pain into a quantitative analysis. Understanding the correlation between ADC values in KOA knee joint cartilage degeneration and morphological and pain gradings, as well as their patterns of change, can provide an imaging basis for the clinical diagnosis and treatment of KOA.

T2* mapping is a method with advantages such as short imaging time and high resolution, reflecting changes in collagen cartilage, and plays a significant role in examining joint cartilage lesions ⁽¹⁷⁾. Our study shows that T2* mapping values in the KOA group are significantly higher than those in the normal group. T2* mapping values are influenced by collagen content and water molecule content. Previous studies have used this technique for diagnosing intervertebral disc degeneration, where the

technique typically uses red and blue colors to represent the abundance or scarcity of water, enabling the acquisition of information about the content of water, proteins, and collagen substances, and can also describe the arrangement of collagen fibers and changes in the fibrous ring, thereby reflecting the degree of cartilage degeneration ⁽¹⁸⁾. Combined with our results, in the early stages of KOA, a decrease in joint cartilage collagen in patients necessitates the absorption of more water, reducing anisotropy and causing an increase in T2* mapping values. Our study shows that T2* mapping values for the femoral condyle, tibial plateau, and patellar joint surface in grade III-IV knee joint cartilage degeneration are significantly higher than those in grades I-II. Previous studies have found ⁽¹⁹⁾ that T2* mapping values, as a means of diagnosing patellar cartilage damage, correlate positively with the degree of cartilage damage, similar to our findings. Combined with our study results, in KOA knee joint cartilage degeneration, the higher the disease grading, the higher the T2 values in T2* mapping sequence imaging. T2* mapping imaging can detect changes in cartilage tissue composition and differentiate between different disease severity levels. The more severe the knee joint cartilage degeneration, the higher the water content in the cartilage, and the more significant the increase in T2* mapping values. T2* mapping sequence imaging can provide a basis for the clinical diagnosis, treatment, and grading assessment of KOA and is worthy of clinical application. However, T2* mapping sequence imaging measurements are influenced by background uniformity and chemical shifts, necessitating further exploration.

The results of this study showed that the ADC values of the femoral condyle, tibial plateau, and patellofemoral joint surface of the knee joint were significantly higher in patients with higher pain scores compared to those with lower pain scores. This suggests that quantitative ADC parameters obtained from magnetic resonance diffusion-weighted imaging (DWI) can indirectly reflect the level of pain in patients. These findings are consistent with previous research. Pearson correlation analysis in this study showed a positive correlation between the T2-mapping values of the femoral condyle, tibial plateau, and patellofemoral joint surface and the pain scores, indicating that T2 mapping values are of significant importance in the quantitative analysis of knee joint cartilage degeneration.

DWI is commonly used for the diagnosis of central nervous system diseases and its application in musculoskeletal disorders has been increasing in recent years ⁽²⁰⁾. Magnetic resonance T2 mapping imaging can quantitatively evaluate the compositional changes in articular cartilage tissue and has good sensitivity. This study combined the use of these two techniques to investigate their value in assessing KOA

cartilage degeneration and their correlation with pain levels, which has important clinical significance.

In conclusion, magnetic resonance DWI and T2 mapping effectively quantify knee cartilage degeneration in KOA, showing elevated ADC and T2 values, particularly in advanced stages and with increased pain severity. These non-invasive techniques offer valuable diagnostic insights, demonstrating their potential as crucial tools for assessing KOA severity and guiding treatment decisions.

Ethical compliance: This study was approved by the ethics committee of the second Affiliated Hospital of Hainan Medical University. Signed written informed consent were obtained from the patients and/or guardians.

Conflict of interest: The authors have no potential conflicts of interest to report relevant to this article.

Author contributions: CH and CL designed the study and performed the experiments, QF and JH collected the data, CH and NJ analyzed the data, YC prepared the manuscript. All authors read and approved the final manuscript.

Funding: This study did not receive any funding in any form.

REFERENCES

1. Tan H, Kang W, Fan Q, et al. (2023) Intravoxel incoherent motion diffusion-weighted MR imaging findings of infrapatellar fat pad signal abnormalities: Comparison between symptomatic and asymptomatic knee osteoarthritis. *Academic Radiology*, **30**(7): 1374-1383.
2. Barendregt AM, Mazzoli V, van Gulik EC, et al. (2020) Juvenile idiopathic arthritis: Diffusion-weighted MRI in the assessment of arthritis in the knee. *Radiology*, **295**(2): 373-380.
3. Banjar M, Horiuchi S, Gedeon DN, Yoshioka H (2022) Review of quantitative knee articular cartilage MR imaging. *Magnetic Resonance in Medical Sciences*, **21**(1): 29-40.
4. Luo P, Hu W, Xu R, et al. (2023) Enabling early detection of knee osteoarthritis using diffusion-relaxation correlation spectrum imaging. *Clinical Radiology*, **78**(9): e681-e687.
5. Ikuta F, Takahashi K, Hashimoto S, et al. (2020) Effect of physical therapy on early knee osteoarthritis with medial meniscal posterior or tear assessed by MRI T2 mapping and 3D-to-2D registration technique: A prospective intervention study. *Modern Rheumatology*, **30**(4): 738-747.
6. Leichtenberg CS, van Tol FR, Gademan M, et al. (2021) Are pain, functional limitations and quality of life associated with objectively measured physical activity in patients with end-stage osteoarthritis of the hip or knee? *Knee*, **29**: 78-85.
7. Schutz U, Martensen T and Kleiner S, et al. (2022) T2*-mapping of knee cartilage in response to mechanical loading in alpine skiing: A feasibility study. *Diagnostics*, **12**(6): 1391.
8. Verschueren J, Eijgenraam SM, Klein S, et al. (2021) T(2) mapping of healthy knee cartilage: multicenter multivendor reproducibility. *Quantitative Imaging in Medicine and Surgery*, **11**(4): 1247-1255.
9. Tsai PH, Wong CC, Chan WP (2022) Radial T2* mapping reveals early meniscal abnormalities in patients with knee osteoarthritis. *European Radiology*, **32**(8): 5642-5649.
10. Viren T, Saarakkala S, Kaleva E, et al. (2009) Minimally invasive ultrasound method for intra-articular diagnostics of cartilage degeneration. *Ultrasound in Medicine and Biology*, **35**(9): 1546-1554.
11. Yang Z, Xie C, Ou S, et al. (2022) Cutoff points of T1 rho/T2 mapping relaxation times distinguishing early-stage and advanced osteoarthritis. *Archives of Medical Science*, **18**(4): 1004-1015.
12. Luo P, Hu W, Jiang L, et al. (2022) Evaluation of articular cartilage in knee osteoarthritis using hybrid multidimensional MRI. *Clinical Radiology*, **77**(7): e518-e525.
13. Murakami K, Arai Y, Ikoma K, et al. (2018) Total resection of any segment of the lateral meniscus may cause early cartilage degeneration: Evaluation by magnetic resonance imaging using T2 mapping. *Medicine*, **97**(23): e11011.
14. Bachmann GF, Basad E, Rauber K, et al. (1999) Degenerative joint disease on MRI and physical activity: a clinical study of the knee joint in 320 patients. *European Radiology*, **9**(1): 145-152.
15. Chan WP, Lang P, Stevens MP, et al. (1991) Osteoarthritis of the knee: comparison of radiography, CT, and MR imaging to assess extent and severity. *American Journal of Roentgenology*, **157**(4): 799-806.
16. Nishioka H, Hirose J, Okamoto N, et al. (2015) Evaluation of the relationship between T1rho and T2 values and patella cartilage degeneration in patients of the same age group. *European Journal of Radiology*, **84**(3): 463-468.
17. Lindner D, Chechik Y, Beer Y, et al. (2022) T2 Mapping Values in Postmeniscectomy Knee Articular Cartilage after Running: Early Signs of Osteoarthritis? *Journal of Knee Surgery*, **35**(7): 739-749.
18. Shi L, Wang K, Yu J, et al. (2021) Relationship between magnetic resonance T2-mapping and matrix metalloproteinase 1, 3 in knee osteoarthritis. *Indian Journal of Orthopaedics*, **55**(4): 974-982.
19. Roth C, Hirsch FW, Sorge I, et al. (2023) Preclinical cartilage changes of the knee joint in adolescent competitive volleyball players: A prospective T2 mapping study. *Rofo-Fortschritte Auf Dem Gebiet Der Rontgenstrahlen Und Der Bildgebenden Verfahren*, **195**(10): 913-923.
20. Mittal S, Pradhan G, Singh S, Batra R (2019) T1 and T2 mapping of articular cartilage and menisci in early osteoarthritis of the knee using 3-Tesla magnetic resonance imaging. *Polish Journal of Radiology*, **84**: e549-e564.

