

# Efficacy of radiotherapy for hepatocellular carcinoma with portal vein and/or inferior vena cava tumor thrombosis

Q. Tian<sup>1</sup>, L. Li<sup>1</sup>, F. Zhang<sup>2</sup>, X. Wu<sup>1\*</sup>

<sup>1</sup>Department of Radiation Oncology, Shandong Provincial Third Hospital, Jinan Shandong 250031, P.R. China.

<sup>2</sup>Department of Gastroenterology, Shandong Second Provincial General Hospital, Jinan Shandong, 250000, P.R. China

## ABSTRACT

### ► Original article

#### \*Corresponding author:

Xia Wu, Ph.D.,

E-mail: wywx7606@163.com

Received: December 2023

Final revised: October 2023

Accepted: January 2024

Int. J. Radiat. Res., April 2024;  
22(2): 379-385

DOI: 10.61186/ijrr.22.2.379

**Keywords:** Hepatocellular carcinoma, Portal vein tumor thrombosis, Inferior vena cava, Three-dimensional conformal radiotherapy, Clinical efficacy.

**Background:** The To investigate the feasibility, efficacy, and toxicity of three-dimensional conformal radiotherapy (3D-CRT) for treatment of patients with advanced hepatocellular carcinoma (HCC) complicated by portal vein tumor thrombosis (PVTT) and/or inferior vena cava tumor thrombosis (IVCTT). **Materials and Methods:** 53 HCC patients with PVTT/IVCTT undergoing 3D-CRT during the period from September 2008 to January 2014 were analyzed. The Kaplan-Meier method was used to analyze between-group differences in patient baseline information. Univariate and multivariate cox regression analyses were used to identify factors affecting survival in patients with HCC. **Results:** Computed tomography (CT) scan or MRI (Magnetic Resonance Imaging) of the upper abdomen one month post-radiotherapy showed an overall response rate (CR + PR) of 56.6% (30/53). Univariate analysis revealed that treatment regimen (P = 0.008), alpha fetoprotein (AFP) level (P = 0.012), response to radiotherapy, metastasis to celiac lymph nodes and site of tumor thrombosis were strongly associated with the prognosis of HCC patients with PVTT (P = 0.000). The median survival time was 9 months (95% CI: 7.43-10.57 months) in 23 (43.4%) PVTT patients, and 24 months (95% CI: 20.04-27.96 months) in 30 (56.6%) IVCTT patients. Multivariate Cox regression analysis revealed that metastasis to celiac lymph nodes (P = 0.004) and response to radiotherapy (P = 0.001) were independent factors affecting patients' survival. **Conclusion:** 3D-CRT has high efficacy for treating HCC patients with PVTT, and metastasis to celiac lymph nodes and response to radiotherapy are primary factors affecting HCC patients' survival.

## INTRODUCTION

Primary liver cancer encompasses three pathological types: hepatocellular carcinoma (HCC), cholangiocarcinoma, and hepatocellular-cholangiocellular carcinoma, with hepatocellular carcinoma accounting for 75% to 85% (1,2). According to epidemiological statistics, primary liver cancer has emerged as the sixth most prevalent malignancy globally and ranks as the third leading cause of cancer-related mortality, surpassed only by lung cancer and colorectal cancer (3). Currently, in China, primary liver cancer holds the fourth position among common malignancies, with the second-highest mortality rate, posing a severe threat to the lives and health of the population (4). Primary liver cancer is a malignancy with high incidence in China, and approximately 70%–80% of patients are diagnosed at a middle or late stage. Defining the complications of primary liver cancer and adopting appropriate treatments have become one of the urgent problems in clinical medicine.

Portal vein tumour thrombosis (PVTT) is a major complication in patients with hepatocellular carcinoma and can be considered as a special type of

hepatocellular carcinoma metastasis (5). Inferior vena cava tumour thrombosis (IVCTT) is classified into four grades: inferior vena cava tumour thrombosis below the first hepatic hilar is grade I, above the first hepatic hilar to the second hepatic hilar is grade II, from the second hepatic hilar to the level of the diaphragm is grade III, and above the diaphragm is grade IV (6). As common complications in patients with advanced HCC, PVTT and IVCTT are the main causes of death from hepatocellular carcinoma (7). Although the survival of liver cancer patients with PVTT/IVCTT remains poor, and median survival time is estimated to be approximately 3 months if untreated (8,9).

Primary liver cancer with PVTT and IVCTT is a complex condition that requires a comprehensive treatment plan based on the patient's specific situation, including the size and location of the tumour, the patient's overall health status and the extent of PVTT or IVCTT (10). The following are some of the common treatment options: surgery, liver transplantation, transcatheter intervention, radiotherapy, targeted therapy, and immunotherapy (11). Acknowledgments are extended to the reviewers for their invaluable

insights on my manuscript. Notably, three-dimensional conformal radiotherapy (3D-CRT), intensity-modulated radiotherapy (IMRT), and stereotactic body radiotherapy (SBRT) have emerged as pivotal modalities for managing primary liver cancer complicated by portal vein tumor thrombosis (PVTT) or inferior vena cava tumor thrombosis (IVCTT), yielding commendable efficacy<sup>(12, 13)</sup>. In addition, 3D-CRT is reported to be of great significance for local tumor control rate and survival rate in liver cancer patients with PVTT or IVCTT<sup>(12, 14-18)</sup>. This study retrospectively analyzes the survival outcomes of liver cancer patients with PVTT undergoing 3D-CRT, categorized by tumor thrombosis classification. The aim is to assess radiotherapy efficacy, identify factors influencing prognosis, and offer insights into treating liver cancer with PVTT.

## MATERIALS AND METHODS

### Ethics statement

This study was approved by the ethics review committee of Jinan Military General Hospital. Signed informed consent was obtained from all participants with a detailed description of the potential benefits from the study. This study was a retrospective study, and the patient has signed an informed consent form at the time of treatment, so it is exempt from ethical approval.

### Subjects

A total of 53 patients with advanced liver cancer complicated by PVTT and IVCTT undergoing 3D-CRT in our department were retrospectively analyzed, and all subjects had a definite diagnosis of liver cancer according to the guidelines for the diagnosis and treatment of primary liver cancer (2011 version)<sup>(19)</sup>. Inclusion criteria involved (1) patients at age of 30 to 80 years; (2) patients with diagnosis of liver cancer with PVTT and/or IVCTT using pathologic or imaging examinations, which is unresectable or identified unresectable by doctors; (3) patients with Child-Pugh class A or B; (4) patients with no previous history of radiotherapy; and (5) patients with Eastern Cooperative Oncology Group (ECOG) performance status score of 2 or less. PVTT or IVCTT was diagnosed using contrast-enhanced computed tomography (CT Philips 16-slice CT, made in the Netherlands) or magnetic resonance imaging (MRI 1.5T magnetic resonance, made in the USA). Patients' clinical characteristics are described in table 1. The subjects had a median age of 59 years (range, 38 to 80 years), and 48 cases (90.5%) had hepatitis B. There were 24 cases (45.3%) with tumor thrombosis in the main trunk of portal vein, and 29 cases (54.7%) with tumor thrombosis in the branches of portal vein and/or inferior vena cava. There were 19 cases undergoing transcatheter arterial

chemoembolization (TACE) with 600–800 mg tegafur, 50–80 mg cisplatin, 40 mg epirubicin or 30 mg pirarubicin at least one month before radiotherapy, and 7 cases received TACE three times or more, while 33 cases received radiotherapy alone.

**Table 1.** Clinical characteristics of 53 patients with liver cancer complicated by portal vein tumor thrombosis.

Characteristic	No. of patients	Percentage (%)
Sex	Male	36
	Female	17
Age (years)	Median	59
	Range	38-83
Treatment	3D-CRT	33
	TACE+3D-CRT	20
ECOG performance status	0–1	13
	2	40
Intrahepatic tumor type	Solitary	23
	Multiple	20
Abdominal lymph node metastasis	Yes	10
	No	43
AFP elevation	Yes	39
	No	14
Site of tumor thrombosis	Portal vein trunk	23
	Inferior vena cava or portal vein branch	30
Time of TACE	< 3	46
	≥ 3	7
No. of cases with various types of cancer embolus	Type I	23
	Type II	30
AFP	< 400	28
	≥ 400	25
Diameter (cm)	< 10	42
	≥ 10	11
Radiation dose (Gy)	< 45	29
	≥ 45	24
Abdominal LNM	Yes	31
	No	22

3D-CRT, three-dimensional conformal radiotherapy; ECOG: Eastern Cooperative Oncology Group; AFP: alpha fetoprotein; TACE: transcatheter arterial chemoembolization; LNM: lymph node metastasis.

### 3D-CRT

Patients were placed in a supine position, and all subjects had their two hands lifted at forehead. The position was fixed using a thermoplastic positioning device. Under quiet breathing, continuous CT scans were performed from the site 3 to 5 cm inferior to the top of diaphragm to the site 3 to 5 cm below the lower margin of liver with a 5-mm thin-slice spiral CT scanner, and CT image sets were loaded into the Pinnacle radiation treatment planning system (PPhilips Medical Systems; Andover, MA, USA). At the same time, the images of the patient's MR examination were fused to CT. The radiotherapy equipment is Elekta Synergy @VMAT. The gross tumor volume (GTV) was estimated by well-experienced radiologists. The clinical target volume (CTV) expanded 0.5 to 1.0 cm on GTV, while planning target volume (PTV) expanded 0.8 to 1.5 cm if the diameter of primary lesions was less than 12 cm and 0.5 cm if the size of primary lesions was 12 cm or greater. The treatment planning program was

evaluated and optimized using a dose-volume histogram (DVH). The median prescription dose was 42 Gy (range, 36 to 60 Gy), so as to allow 90% isodose curve covering PTV, and the radiation dose delivered to normal liver tissues, duodenum, stomach, pancreas, kidney and spinal cord was controlled within the normal tolerance range: the median dose to normal liver tissues was 18 Gy or less; the highest dose to stomach and small intestine was 30 Gy or less; the median dose to bilateral kidney was 18 Gy or less; and the highest dose to spinal cord was less than 35 Gy. 3D-CRT was given at a total dose of 36 to 60 Gy delivered in 2 Gy per fraction, 5 fractions per week. Radiotherapy placement and radiotherapy plan implementation: 1 treatment per day, 5 fractions per week, and 1 time per week of Radiotherapy plan validation, Through the planning of the post-line simulation positioning machine under the position, compared with the plan center level, the treatment is started after the correct error.

#### Assessment of radiotherapy-related toxicity

Acute and chronic adverse reactions one week, one and three months post-radiotherapy were evaluated according to the Common Terminology Criteria for Adverse Events version 4.0 (CTCAE 4). A telephone follow-up was performed in patients who did not return to hospital for reexamination to evaluate adverse reaction.

#### Follow-up and statistical analysis

Follow-up after radiotherapy was until 1 August 2014, with an overall follow-up rate of 100%. Overall survival (OS) was calculated from the start of radiotherapy to the date of death or last follow-up. All 53 subjects completed the radiotherapy schedule and had their routine blood tests, liver and kidney functions, electrolyte tests, alpha-fetoprotein (AFP) and carcinoembryonic antigen (CEA) blood tests, abdominal CT or MRI reviewed at 1 and 3 months after radiotherapy. Tumour changes were evaluated using the Response Evaluation Criteria in Solid Tumours (RECIST) proposed by the World Health Organisation (WHO) <sup>(20)</sup>, which included complete response (CR), partial response (PR), stable disease (SD) and disease progression (PD), where CR + PR was defined as response. The efficacy of the tumour thrombus was assessed using the following criteria: CR was defined as complete disappearance of the PVT; PR was defined as a reduction of at least 30% in the longest diameter of the thrombus; PD was defined as an increase of at least 20% in the longest diameter of the PVT; and SD was defined as neither sufficient shrinkage to meet the criterion for PR nor sufficient increase to meet the criterion for PD.

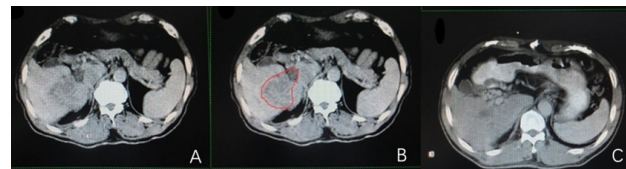Reviews were performed every 1 to 3 months, and those who did not return for review were followed up by telephone. Overall survival at death or last follow-up was estimated using the Kaplan-Meier method. Univariate analyses of gender, age,

alpha-fetoprotein level, tumour size, tumour thrombus site, treatment regimen, radiotherapy dose and abdominal lymph node metastasis were performed using the log-rank test, followed by multivariate Cox regression analyses to determine factors affecting patient survival. All statistical analyses were performed using SPSS version 16.0 statistical software (SPSS Inc.; Chicago, IL, USA).

## RESULTS

#### Short-term efficacy

Upper abdominal CT or MRI review one month after radiotherapy showed 3 primary lesions CR, 27 PR, 10 SD, and 13 PD, with a response (CR + PR) rate of 56.6% (30/53); 2 tumour thrombi CR, 28 PR, 11 SD, and 9 PD, with a response (CR + PR) rate of 56.6% (30/53). Figure 1 shows the case of a patient with PVT CR.



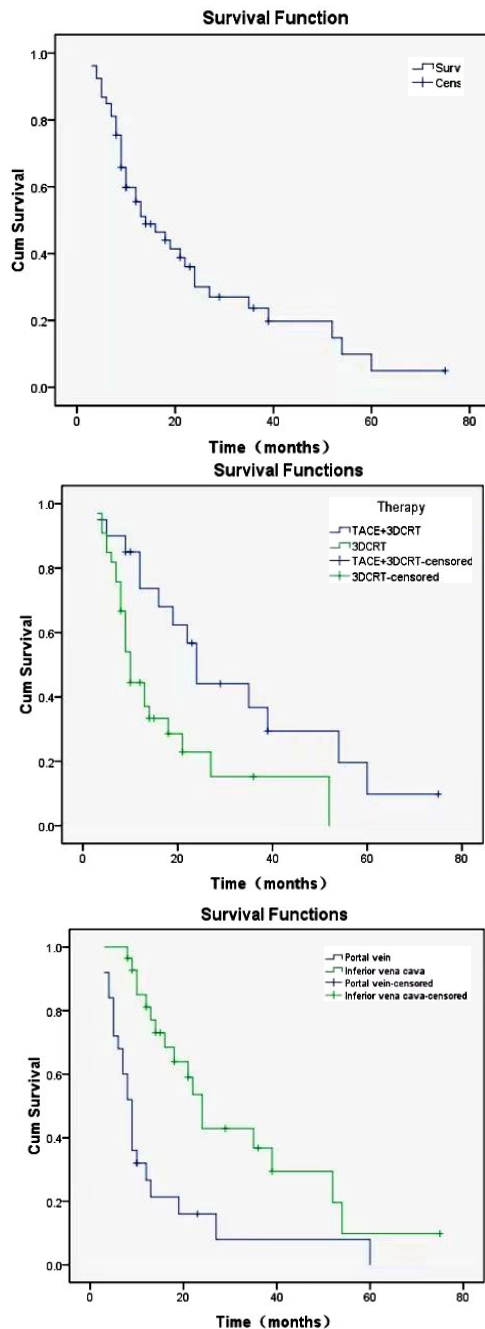
**Figure 1.** CT scanning of a HCC patient with PVT. A, pre-radiotherapy CT image; B, A planning scheme for radiotherapy; C, Re-examination with CT scan 2 months post-radiotherapy.

#### Survival and prognosis

Eight patients survived and 45 patients died until August 2014. The overall median survival time was 14 months (95% CI: 14 ± 3.69 months) (figure. 2A), and the median survival time was 10 (95% CI: 10 ± 0.79 months) and 24 months (95% CI: 24 ± 1.903 months) in patients undergoing 3D-CRT and 3D-CRT + TACE, respectively. The 1-year, 2-year and 3-year survival rates were 55.5%, 30% and 23.7%, respectively (figure. 2B). There were 23 cases (43.4%) with tumor thrombosis in the main trunk of portal vein, with a median survival time of 9 months (95% CI: 7.43–10.57 months), and 30 cases (56.6%) with tumor thrombosis in the branches of portal vein and inferior vena cava, with a median survival time of 24 months (95% CI: 20.04–27.96 months) (figure 2C).

Univariate analysis of factors that affected the prognosis of HCC patients with PVT showed statistical significances of treatment regimen, AFP level, response to radiotherapy, metastasis to celiac lymph nodes and site of tumor thrombosis (table 2). The median survival time was 10 and 24 months in patients undergoing 3D-CRT and transcatheter arterial chemoembolization (TACE) + 3D-CRT, respectively, and there was significant difference observed ( $P = 0.008$ ). The median survival time was 9 and 35 months in patients with and without metastasis to celiac lymph nodes ( $P = 0$ ), and the median survival time was 9 and 24 months in

patients with tumor thrombosis in the main trunk of portal vein and collaterals of portal vein, respectively ( $P = 0$ ). Univariate analysis revealed that treatment regimen, AFP level, response to radiotherapy, metastasis to celiac lymph nodes and site of tumor thrombosis were strongly associated with the prognosis of HCC patients with PVTT. The median survival time was 27 and 8 months in patients with CR + PR and PD + SD, respectively ( $P = 0$ ). Patient's age, gender, Child-Pugh classification, and radiotherapy dose had no significant effect on the survival of HCC patients with PVTT.



**Figure 2.** Survival curve for patients. (A, Overall survival curve for 53 HCC patients with PVTT/IVCTT; B, Overall survival curves according to the site of tumor thrombosis Patients with PVTT in branches had longer survival than those with PVTT in main trunk or IVCTT ( $P = 0.0001$ ). C Survival curves for the patients undergoing TACE + 3D CRT and 3D CRT.)

**Table 2.** Univariate analysis of factors affecting the survival of patients with liver cancer complicated by portal vein tumor thrombosis.

Factor		No. of cases	Median survival (month; 95% CI)	P value
Sex	Male	36	13±2.588 (7.928-18.072)	0.789
	Female	17	21±6.992 (7.297-34.703)	
Age (years)	< 60	28	12±2.575 (6.953-17.047)	0.415
	≥ 60	25	16±3.192 (9.744-22.256)	
Treatment	3DCRT	33	10±0.790 (8.452-11.548)	0.008
	TACE+3DCRT	20	24±1.903 (20.270-27.730)	
AFP	< 400	28	24±6.747 (10.776-37.224)	0.012
	≥ 400	25	10±3.069 (3.985-16.015)	
Child-Pugh classification	A	41	16±4.654 (6.879-25.121)	0.844
	B	4	14±0	
Diameter (cm)	< 10	42	12±2.988 (6.143-17.857)	0.562
	≥ 10	10	22±5.454 (11.311-32.689)	
Site of tumor thrombosis	Portal vein branch	25	9±8 (7.432-10.568)	0.000
	Inferior vena cava	28	24±2.021 (20.039-27.961)	
Abdominal LNM	Yes	31	9±0.525 (7.971-10.029)	0.000
	No	22	35±8.033 (19.255-50.745)	
Radiation dose (Gy)	< 45	29	13±3.726 (5.697-20.303)	0.110
	≥ 45	24	19±5.368 (6.518-31.482)	
Response to RT	CR + PR	30	27±6.632 (14-40)	0.000
	SD + PD	23	8±0.792 (6.447-9.553)	
ECOG	1	14	13±14.261 (0-40.951)	0.684
	2	31	14±3.645 (6.856-21.144)	
	3	6	21±8.638 (4.069-37.931)	

AFP: alpha fetoprotein; LNM: lymph node metastasis; ECOG: Eastern Cooperative Oncology Group; RT: Radiotherapy.

Those factors with significant differences were involved in Cox regression model, including treatment regimen, AFP level, metastasis to celiac lymph nodes, site of tumor thrombosis and response to radiotherapy. Multivariate analysis revealed that metastasis to celiac lymph nodes ( $P = 0.004$ ) and response to radiotherapy ( $P = 0.001$ ) were independent factors affecting patients' survival. It is estimated that the risk of death in patients with metastasis to celiac lymph nodes was 6.381 times more than in patients without metastasis to celiac lymph nodes, and the risk of death in patients with SD + PD post-radiotherapy is 18.35 times more than in patients with CR + PR (table 3).

**Table 3.** Stepwise multivariate analysis of factors affecting the survival of patients with liver cancer complicated by portal vein tumor thrombosis.

Factor	P value	Exp(β) RR	Median survival (month; 95% CI)
Therapy	0.052	2.633	0.992-6.989
AFP	0.059	2.295	0.970-5.429
Site of tumor thrombosis	0.141	0.554	0.252-1.217
Abdominal LNM	0.004	6.381	1.836-22.181
Response to radiotherapy	0.001	18.350	3.565-94.458

β, regression coefficient; RR, relative risk; 95% CI: 95% confidential interval; AFP: alpha fetoprotein; LNM: lymph node metastasis.



### Adverse reactions

Grade 3–5 severe adverse reactions were observed in patients one month post-radiotherapy (table 4). There were 46 patients (86.8%) with grade 1–2 nausea and vomiting, the most common adverse reaction seen post-radiotherapy, 25 cases (47.2%) with abnormal liver function, 20 cases with grade 1–3 elevated bilirubin levels, 11 cases (20.8%) with grade 1 anemia, 28 cases (52.8%) with grade 1–2 reduced leukocyte count, and 27 cases (50.9%) with grade 1–2 reduced platelet count.

**Table 4.** Acute toxicity present in 53 patients with liver cancer complicated by portal vein tumor thrombosis.

CTC toxicity	No. of patients	Percentage (%)
Grade of nausea/vomiting	0	7
	1	38
	2	8
	3-5	0
Liver enzymes, grade	0	28
	1	20
	2	5
	3-5	0
Grade of bilirubin	0	23
	1	16
	2	3
	3	1
Anemia	0	42
	1	11
	2-5	0
Leukocytes	0	25
	1	20
	2	8
	3-5	0
Platelets	0	26
	1	18
	2	9
	3-5	0

CTC, common toxicity criteria.

## DISCUSSION

Primary liver cancer frequently invades intrahepatic vessels, and inferior vena cava, especially the portal vein trunk and/or branches. As a major factor affecting the poor prognosis of patients with hepatocellular carcinoma, PVTT usually leads to intrahepatic metastasis and postoperative recurrence (21). To date, there is no standard treatment for patients with PVTT hepatocellular carcinoma. Surgical treatment is effective for hepatocellular carcinoma patients with tumour thrombosis in the primary branch of the portal vein, but satisfactory progress has not been made in the treatment of hepatocellular carcinoma patients with tumor thrombosis in the main trunk of the portal vein (22, 23). During the past 10 years, radiotherapy has shown promising for treatment of advanced liver cancer with PVTT and/or IVCTT. However, there is little knowledge on the efficacy of radiotherapy for liver cancer with PVTT/IVCTT till now. The current study

was therefore designed to evaluate the efficacy and toxicity of radiotherapy for treatment of liver cancer with PVTT/IVCTT.

Radiotherapy has been widely used for treatment of primary liver cancer and liver metastasis, and satisfactory efficacy is found (24, 25). The effectiveness of radiotherapy for liver cancer with PVTT/IVCTT has been proved, and 3D-CRT has shown effective for treatment of liver cancer and vascular invasion. Systemic chemotherapy was employed for treatment of primary liver cancer with PVTT metastasis; however, the optimal therapy resulted in a median survival time of 9.4 months (26). Studies have shown that the overall response rate to 3D-CRT therapy in patients with hepatocellular carcinoma and vascular invasion ranged from 25.2% to 62.3%, and the 1-year overall survival rate of patients ranged from 25.0% to 57.6%, with a median survival time of 3.8-13.9 months (27, 28). There were also studies with smaller sample sizes that have evaluated the efficacy of radiotherapy in liver cancer with PVTT/IVCTT. In a study aiming to evaluate the long-term clinical outcomes of TACE and 3D-CRT in 412 HCC patients with PVTT, 3D-CRT at a median radiation dose of 40 Gy (range, 21–60 Gy) delivered in 2- to 5-Gy fractions resulted in a 39.6% response rate of PVTT, median patient survival of 10.6 months, and a 1-year survival rate of 42.5% (15). Huang and colleagues (27) reported a 25.2% treatment response rate of the 326 HCC patients with PVTT following 3D-CRT. The best survival outcome was reported by Rim *et al.* (17), who reported 6.7% CR rate and 55.6% PR rate in 45 HCC patients with PVTT, respectively. In 9 HCC patients targeting PVTT treated with stereotactic body radiation therapy (SBRT) using the Cyberknife at a dose of 30–39 Gy in 3 fractions for consecutive days for 70%–85% of the planned target volume, one case (11.1%) had CR, and 3 cases (33.3%) had PR (29). In addition, hypofractionated radiotherapy with helical tomotherapy resulted in CR in 5 (14.3%) unresectable HCC patients with PVTT, PR in 10 cases (28.6%), and SD in 18 cases (51.4%) (30). The overall response rate (CR + PR) to radiotherapy in patients in our study was 56.6%. In line with the convergence of findings from previous studies, we accordingly tentatively concluded that 3D-CRT was efficacious in treating patients with PVTT HCC.

In the current study, the patients had overall survival time of 14 months, which was comparable to that (10.7 to 19.9 months) reported in previous studies (17, 18, 26, 27), and the median survival time was 10 and 24 months in subjects receiving radiotherapy alone (33 cases) and TACE + radiotherapy (20 cases), respectively, indicating that the efficacy of TACE + radiotherapy is superior to radiotherapy alone. In addition, 23 cases (43.4%) had tumor thrombosis involved in the main trunk of the portal vein, with a median survival time of 9 months (95% CI: 7.43-10.57 months), and 30 cases (56.6%) had tumor

thrombosis of the inferior vena cava and its branches, with a median survival time of 24 months (95% CI: 20.04–27.96 months). The results of other studies supported our findings to some extent <sup>(31, 32)</sup>. They also reported that TACE followed by radiotherapy was superior to radiotherapy alone <sup>(33, 34)</sup>.

Multivariate analysis revealed that metastasis to celiac lymph nodes and response to radiotherapy were independent factors affecting patients' prognosis. It is reported that locally advanced HCC patients with a tumor diameter of < 100 mm have a relatively good prognosis <sup>(28)</sup>. In the current study, both univariate and multivariate analyses revealed that the liver cancer patients receiving multiple times of TACE in the absence of obvious tumor thrombosis had relatively good prognosis. With the progress of interventional technique and development of embolic agent and chemotherapeutics, the range of indications for TACE has been steadily expanded. However, the compensatory increase in blood supply to cancer lesions by portal vein and the establishment of collateral circulation following hepatic artery embolism cause continuous proliferation of residual cancer cells after TACE, resulting in recurrence of PVTT <sup>(35)</sup>. The involvement of tumor thrombosis in the main trunk of portal vein is defined as a contraindication for TACE, when combined radiotherapy is required. The value of comprehensive therapy for advanced liver cancer with PVTT has been demonstrated <sup>(28)</sup>. Locally advanced HCC patients with Child-Pugh class A and PVTT that were given 3D-CRT in combination with hepatic arterial infusion of 5-fluorouracil had a median survival time of 13.1 months and a 3-year overall survival rate of 24.1%, and the responders after localized chemoradiation therapy demonstrated significantly better survival ( $P = 0.033$ ) than nonresponders (median survival time: 19.9 months vs. 11.4 months) <sup>(28)</sup>. Our findings also demonstrate the superiority in the efficacy of comprehensive therapy to radiotherapy alone for liver cancer; however, radiotherapy had superiority in the presence of tumor thrombosis in portal vein and its branches. McIntosh and colleagues <sup>(36)</sup> reported that one out of 20 unresectable HCC patients undergoing intensity-modulated radiation therapy (IMRT) developed melena and secondary gastrointestinal ulcer and bleeding. In the present study, most patients undergoing radiotherapy developed adverse reactions including nausea and vomiting; however, no gastrointestinal or duodenal ulcer was observed.

In summary, our clinical experiences demonstrate that active comprehensive therapy should be required for patients with primary liver cancer, and 3D-CRT has high efficacy for treatment of liver cancer with tumor thrombosis involved in portal vein or its branches, which causes shrink or disappearance of tumor thrombosis, extends survival and has a high tolerance.

## CONCLUSION

3D-CRT is effective in treating patients with PVTT HCC, and abdominal lymph node metastasis and response to radiotherapy are the main factors affecting the survival of HCC patients. Our next step is to explore individualized treatment strategies based on patients' clinical characteristics and molecular biomarkers. The research direction may focus on predicting patients' response to 3D-CRT and developing more effective treatment plans based on the molecular characteristics of lymph node metastasis.

## ACKNOWLEDGMENT

*We thank the project that funded this study and all the authors.*

**Funding:** Shandong Province Medical and Health Science and Technology Development Plan Project: 202003031535.

**Conflicts of interests:** All authors have approved this manuscript and no actual or potential conflicts of interest exist.

**Ethical consideration:** Informed consent was obtained from all individual participants included in the study.

**Author contribution:** Conception, design, and administrative support by X.W. and Q.T.; Provision of study materials or patients, Q.T. and L.L.; Collection and assembly of data, Q.T. and F. Z.; Data analysis and interpretation done by Q.T., L.L. Manuscript is written by the all authors. And the final approval of manuscript is done by the all authors.

## REFERENCES

1. Li G, Zhao Y, Li K, *et al.* (2023) Effectiveness and safety of the PD-1 inhibitor Lenvatinib plus radiotherapy in patients with HCC with main PVTT: Real-world data from a tertiary center. *J Hepatocell Carcinoma*, **10**: 2037-2048.
2. Nomura T, Tani J, Deguchi A, *et al.* (2019) Efficacy of combined modality therapy with sorafenib following hepatic arterial injection chemotherapy and three-dimensional conformal radiotherapy for advanced hepatocellular carcinoma with major vascular invasion. *Mol Clin Oncol*, **11**(5): 447-454.
3. Shi X, Liu J, Wang G (2023) A peroxidase-like magneto-gold nanozyme AuNC@Fe(3)O(4) with photothermal effect for induced cell apoptosis of hepatocellular carcinoma cells *in-vitro*. *Front Bioeng Biotechnol*, **11**: 1168750.
4. Tian Z, Zhao J, Wang Y (2022) The prognostic value of TPM1-4 in hepatocellular carcinoma. *Cancer Med*, **11**(2): 433-446.
5. Wang K, Liu Z, Hong P, *et al.* (2022) T.H.R.O.B.V.S. Score - A Comprehensive Model to Predict the Surgical Complexity of Renal Cell Carcinoma With Tumor Thrombus. *Front Oncol*, **12**: 900550.
6. Xi M, Zhang L, Zhao L, *et al.* (2013) Effectiveness of stereotactic body radiotherapy for hepatocellular carcinoma with portal vein and/or inferior vena cava tumor thrombosis. *PLoS One*, **8**(5): e63864.
7. Yildirim, OM, Bingolbali A, Bozkurt A, *et al.* (2023). Monte Carlo calculations of critical organ doses in radioembolization therapy of primary liver tumors via 90Y microspheres. *Int J Radiat Res*, **21**(3): 353-360.
8. Nakazawa T, Adachi S, Kitano M, *et al.* (2007) Potential prognostic benefits of radiotherapy as an initial treatment for patients with unresectable advanced hepatocellular carcinoma with invasion to

- intrahepatic large vessels. *Oncology*, **73**: 90–97.
9. Llovet JM, Bustamante J, Castells A, et al. (1999) Natural history of untreated nonsurgical hepatocellular carcinoma: rationale for the design and evaluation of therapeutic trials. *Hepatology*, **29**: 62–67.
  10. Zhang JJ, Wang ZX, Niu JX, et al. (2021). Successful totally laparoscopic right trihepatectomy following conversion therapy for hepatocellular carcinoma: A case report. *World J Clin Cases*, **9**(22), 6469–6477.
  11. Zhou J, Sun H, Wang Z, et al. (2023). Guidelines for the Diagnosis and Treatment of Primary Liver Cancer (2022 Edition). *Liver Cancer*, **12**(5): 405–444.
  12. Zeng ZC, Fan J, Tang ZY, et al. (2005) A comparison of treatment combinations with and without radiotherapy for hepatocellular carcinoma with portal vein and / or inferior vena cava tumor thrombus. *Int J Radiat Oncol Biol Phys*, **61**: 432–43.
  13. Zhu XD, Liang SX, Wang AY, et al. (2005) Hypofractionated three dimensional conformal radiotherapy for primary liver cancer with portal vein tumor thrombosis. *Chin J Radial Oncol* **14**: 476–8.
  14. Kim JY, Chung SM, Choi BO, Kay CS (2011) Hepatocellular carcinoma with portal vein tumor thrombosis: improved treatment outcomes with external beam radiation therapy. *Hepatol Res*, **41**: 813–24.
  15. Yoon SM, Lim YS, Won HJ, et al. (2012) Radiotherapy plus transarterial chemoembolization for hepatocellular carcinoma invading the portal vein: long-term patient outcomes. *Int J Radiat Oncol Biol Phys*, **82**: 2004–11.
  16. Koo JE, Kim JH, Lim YS, et al. (2010) Combination of transarterial chemoembolization and three-dimensional conformal radiotherapy for hepatocellular carcinoma with inferior vena cava tumor thrombus. *Int J Radiat Oncol Biol Phys*, **78**: 180–87.
  17. Rim CH, Yang DS, Park YJ, et al. (2012) Effectiveness of high-dose three-dimensional conformal radiotherapy in hepatocellular carcinoma with portal vein thrombosis. *Jpn J Clin Oncol*, **42**: 721–9.
  18. Toya R, Murakami R, Baba Y, et al. (2007) Conformal radiation therapy for portal vein tumor thrombosis of hepatocellular carcinoma. *Radiother Oncol*, **84**: 266–71.
  19. Ministry of health, People's Republic of China (2011) Guidelines for diagnosis and treatment of primary liver cancer. *Chin Clin Oncol*, **16**: 929–46.
  20. Llovet JM, Di Bisceglie AM, Bruix J, et al. (2008) Design and endpoints of clinical trials in hepatocellular carcinoma. *J Natl Cancer Inst*, **100**: 698–711.
  21. Addario L, Tritto G, Cavaglià E, et al. (2011) Preserved liver function, portal thrombosis and absence of oesophageal varices are risk factors for metastasis of hepatocellular carcinoma. *Dig Liver Dis*, **43**: 319–24.
  22. Tazawa J, Maeda M, Sakai Y, et al. (2001) Radiation therapy in combination with transcatheter arterial chemoembolization for hepatocellular carcinoma with extensive portal vein involvement. *J Gastroenterol Hepatol*, **16**: 660–5.
  23. Toya R, Murakami R, Baba Y, et al. (2007) Conformal radiation therapy for portal vein tumor thrombosis of hepatocellular carcinoma. *Radiother Oncol*, **84**: 266–71.
  24. Tse RV, Hawkins M, Lockwood G, et al. (2008) Phase I study of individualized stereotactic body radiotherapy for hepatocellular carcinoma and intrahepatic cholangiocarcinoma. *J Clin Oncol*, **26**: 657–64.
  25. Lee MT, Kim JJ, Dinniwell R, et al. (2009) Phase I study of individualized stereotactic body radiotherapy of liver metastases. *J Clin Oncol*, **27**: 1585–91.
  26. Ando E, Yamashita F, Tanaka M, Tanikawa K (1997) A novel chemotherapy for advanced hepatocellular carcinoma with tumor thrombosis of the main trunk of the portal vein. *Cancer*, **79**: 1890–6.
  27. Huang YJ, Hsu HC, Wang CY, et al. (2009) The treatment responses in cases of radiation therapy to portal vein thrombosis in advanced hepatocellular carcinoma. *Int J Radiat Oncol Biol Phys*, **73**: 1155–63.
  28. Han KH, Seong J, Kim JK, et al. (2008) Pilot clinical trial of localized concurrent chemoradiation therapy for locally advanced hepatocellular carcinoma with portal vein thrombosis. *Cancer*, **113**: 995–1003.
  29. Choi BO, Choi IB, Jang HS, et al. (2008) Stereotactic body radiation therapy with or without transarterial chemoembolization for patients with primary hepatocellular carcinoma: preliminary analysis. *BMC Cancer*, **8**: 351.
  30. Kim JY, Yoo EJ, Jang JW, et al. (2013) Hypofractionated radiotherapy using helical tomotherapy for advanced hepatocellular carcinoma with portal vein tumor thrombosis. *Radiation Oncology*, **8**: 15.
  31. Cheng AL, Kang YK, Chen Z, et al. (2009) Efficacy and safety of sorafenib in patients in the Asia-Pacific region with advanced hepatocellular carcinoma: a phase III randomised, double-blind, placebo-controlled trial. *Lancet Oncol*, **10**: 25–34.
  32. Llovet JM, Ricci S, Mazzaferro V, et al. (2008) Sorafenib in advanced hepatocellular carcinoma. *N Engl J Med*, **359**: 378–90.
  33. Choi BO, Choi IB, Jang HS, et al. (2008) Stereotactic body radiation therapy with or without transarterial chemoembolization for patients with primary hepatocellular carcinoma: preliminary analysis. *BMC Cancer*, **8**: 351.
  34. Nakagawa K, Yamashita H, Shiraishi K, et al. (2005) Radiation therapy for portal venous invasion by hepatocellular carcinoma. *World J Gastroenterol*, **11**: 7237–41.
  35. Park HC, Seong J, Han KH, et al. (2002) Dose-response relationship in local radiotherapy for hepatocellular carcinoma. *Int J Radiat Oncol Biol Phys*, **54**: 150–55.
  36. McIntosh A, Hagspiel KD, Al-Osaimi AM, et al. (2009) Accelerated treatment using intensity modulated radiation therapy plus concurrent capecitabine for unresectable hepatocellular carcinoma. *Cancer*, **115**: 5117–25.

