

# Clinical application of three-dimensional pelvic floor ultrasound in patients with pelvic organ prolapse and the application value of levator hiatus and levator ani indicators

Z. Wang\*, Y. Chen, A. Huang

Taizhou People's Hospital, Department of Gynecology and Obstetrics, Taizhou, Jiangsu, 225300, China

## ► Original article

## ABSTRACT

### \*Corresponding author:

Zhongqin Wang, Ph.D.,

### E-mail:

15261006315@163.com

Received: August 2023

Final revised: October 2023

Accepted: November 2023

Int. J. Radiat. Res., April 2024;  
22(2): 473-479

DOI: 10.61186/ijrr.22.2.473

**Background:** Pelvic organ prolapse is a common gynecological condition affecting many women and impairing quality of life. Imaging modalities like 3D ultrasound can provide a valuable anatomical and morphological evaluation of pelvic floor support defects contributing to prolapse. **Materials and Methods:** This study evaluated the clinical utility of 3D transperineal pelvic floor ultrasound for assessing pelvic organ prolapse in women. Prolapse was quantified using the Pelvic Organ Prolapse Quantification (POP-Q) system based on ultrasound imaging. Additional ultrasound parameters measured were the levator hiatus area, levator ani muscle thickness, and hiatal balloon volume on Valsalva. **Results:** 3D ultrasound enabled comprehensive visualization and staging of pelvic organ prolapse. Significant stepwise differences were found between mild, moderate, and severe prolapse groups in the levator hiatus area, levator ani thickness, and balloon volume. Ultrasound measurements showed excellent reproducibility. **Conclusion:** 3D pelvic floor ultrasound allows accurate diagnosis and staging of pelvic organ prolapse severity. Quantified ultrasound indicators of levator injury and pelvic floor laxity correlate with prolapse grade. Our findings demonstrate that 3D ultrasound is a valuable imaging modality for comprehensive pelvic organ prolapse assessment in clinical practice.

**Keywords:** Pelvic organ prolapse, three-dimensional pelvic floor ultrasound, pelvic organ prolapse quantification, levator.

## INTRODUCTION

Pelvic organ prolapse (POP) is when one or more organs (such as the bladder, uterus, rectum, or small intestine) descend into the vagina due to weak or damaged pelvic floor response muscles and tissues. This occurs when the supporting structures that normally hold the body in place stretch or weaken, losing their anatomical functions and functions <sup>(1, 2)</sup>.

Many factors can cause pelvic organ prolapse to develop, including pregnancy and childbirth, hormonal changes associated with menopause, constipation, chronic cough, obesity, weight regain, and genetic predisposition. At the same time, these conditions can cause more stress on the pelvic floor and weaken its support system <sup>(3, 4)</sup>.

The symptoms of pelvic prolapse can be different depending on the body involved and the severity of the condition. Common symptoms include pain or heaviness in the pelvic area <sup>(5)</sup>, feeling or seeing a lump or protrusion in the genital area, urinary incontinence or difficulty urinating, problems with bowel movements, discomfort or pain during sexual intercourse <sup>(6)</sup>, and back pain. Pelvic organ prolapse can be classified into different types based on the specific organs involved:

A cystocele is characterized by the descent of the bladder into the vaginal canal, leading to the

formation of a bulge or protrusion. The condition may give rise to urinary manifestations such as increased frequency of urination, a sense of urgency, or difficulties with fully emptying the bladder <sup>(7)</sup>. Rectocele refers to a medical condition characterized by the bulging of the rectum into the vaginal canal. The condition may give rise to challenges in bowel motions, such as constipation or the necessity for manual assistance in evacuation <sup>(8)</sup>. Uterine prolapse is characterized by the downward displacement of the uterus into the vaginal canal. The condition can elicit a perception of weightiness or compression in the pelvic region, as well as impairments in urine and bowel functionality. Furthermore, enterocele is a medical condition characterized by the protrusion of the small bowel into the vaginal canal. The consumption of this substance has the potential to induce physical discomfort, a sensation of satiety, and challenges in the process of defecation <sup>(9)</sup>.

Pelvic organ prolapse is usually diagnosed through a combination of history, physical examination, and possibly other diagnostic testing, such as a pelvic floor ultrasound or Pelvic Organ Prolapse Quantitative (POP-Q) test <sup>(10)</sup>.

The treatment of pelvic prolapse is dependent upon various aspects, including the severity of symptoms, the level of interference with everyday activities, and the individual's personal preferences.

Medical care for certain conditions can involve various interventions such as pelvic floor exercises, modifications to one's lifestyle, utilization of a pessary (a supportive device), and administration of hormone therapy. In instances of heightened severity or unsuccessful implementation of conservative approaches, surgical treatments, such as those addressing pelvic prolapse and organ prolapse, should prompt individuals to seek consultation with a medical professional who possesses expertise in pelvic floor issues. This may include specialists such as urogynecologists or urologists, who may provide comprehensive examination and treatment. Correct diagnosis and stage of COC are important for good management and treatment decisions. Although clinical examination remains the primary tool in the evaluation of POP, advances in medicine have opened new possibilities to improve the accuracy and understanding of pelvic floor anatomy <sup>(11)</sup>.

One such example is 3D pelvic floor ultrasound, which has become an important tool in the evaluation of POP. Unlike traditional 2D ultrasound, 3D ultrasound provides multiple images and volumes of information, allowing three-dimensional reconstruction of the abdomen <sup>(12)</sup>. This technology provides a comprehensive view of the structure and strength of the abdominal cavity, enables objective measurement of prolapse weight, identifies defects of the levator, measures size, and enables measurement of physical descent during various procedures <sup>(13)</sup>.

3D ultrasound can improve our understanding of the support system of the stomach and complement clinical studies. It offers a noninvasive, noninvasive option that can be easily performed in an outpatient setting. 3D ultrasound also has the advantage of being performed well by patients, making it suitable for repeat or follow-up examinations <sup>(14)</sup>.

Our study aims to evaluate the potential of 3D ultrasound in diagnosis and stage based on these sources. Additionally, we investigated whether ultrasound findings of levator muscle injury and pelvic floor laxity were associated with prolapse severity. By investigating the relationship between ultrasound results and the clinical setting, we hope to contribute to the growing body of evidence supporting 3D ultrasound as an accurate and therapeutic tool.

The results of this study will have important implications for urogynecology. Improving the accuracy of POP diagnosis and operation with 3D ultrasound can help improve personalized treatment plans, improve surgical outcomes <sup>(15)</sup>, and increase patient satisfaction. Finally, our study aims to introduce 3D pelvic floor ultrasound as an important contribution to clinical assessment and facilitate the development of management strategies for women affected by sexual intercourse. 3D pelvic floor ultrasound has many advantages in theory. One of the key advantages of 3D ultrasound is its ability to

provide objective measurements of prolapse severity. By accurately visualizing the position and descent of pelvic organs, clinicians can quantify the extent of prolapse using standardized measurements. This objective assessment can aid in treatment decision-making, monitoring disease progression, and evaluating the effectiveness of interventions <sup>(16)</sup>. Levator ani muscle injury commonly contributes to pelvic organ prolapse. 3D ultrasound makes it possible to evaluate the integrity of the levator muscles and identify any defects or abnormalities. This information can help guide treatment strategies, such as targeted pelvic floor exercises or surgical repairs, to address specific muscle weaknesses <sup>(17)</sup>. Also, 3D ultrasound allows dynamic imaging. This means that pelvic floor movements and changes may be seen during various procedures. For example, the patient may be asked to perform the Valsalva maneuver or other activities that simulate changes in the abdominal cavity. These dynamic measurements give a good idea of the function of the abdominal support system and can help identify factors contributing to sagging <sup>(12)</sup>. One other advantage is that the visual nature of 3D ultrasound makes it an effective tool for patient counselling and education. Clinicians can improve patient understanding of their condition by visualizing the pelvic floor structures and demonstrating the anatomical changes associated with pelvic organ prolapse. This visual feedback can empower patients to actively participate in their treatment decisions and engage in preventive measures.

At last, 3D ultrasound can be used for longitudinal monitoring of pelvic organ prolapse. By comparing serial ultrasound examinations, clinicians can track changes in prolapse severity, evaluate the effectiveness of interventions over time, and identify potential recurrence or progression of the condition. This capability contributes to a comprehensive and personalized approach to patient care <sup>(18)</sup>.

Although 3D pelvic floor ultrasound is promising in the evaluation of pelvic organ prolapse, it should be remembered that it is intended to supplement the diagnosis, not replace it. Integrating 3D ultrasound findings with the patient's history, symptoms, and physical examination can help provide a more comprehensive assessment of abdominal health <sup>(19)</sup>.

With the advancement of science and technology, the use of technology, measurement and analysis technology has become more advanced. Greater accessibility of 3D ultrasound could lead to its widespread use in medicine. Exploration of the possibilities of 3D ultrasound has helped to increase the medical level of abdominal level and the consequences of pelvic organ prolapse <sup>(20)</sup>.

Indications for pelvic floor ultrasound in the evaluation and treatment of pelvic floor disease, including pelvic organ prolapse. Some important features of the application are discussed below.

Ultrasound indicators such as levator defects, hiatal dimensions, and organ descent can aid in diagnosing and staging pelvic organ prolapse. These objective measurements provide valuable information about the severity and extent of the condition, helping clinicians accurately classify and categorize prolapse cases <sup>(21)</sup>. Pelvic floor ultrasound indicators are crucial in treatment planning for pelvic organ prolapse. Clinicians can tailor treatment strategies to address specific anatomical or functional abnormalities by assessing levator injuries and pelvic floor laxity. This personalized approach allows for more targeted therapies, such as pelvic floor exercises, pessaries, or surgical interventions, improving treatment outcomes <sup>(22)</sup>. Ultrasound indicators provide a means to monitor the progression of pelvic organ prolapse over time. Serial ultrasound examinations can track changes in prolapse severity, evaluate the effectiveness of conservative or surgical interventions, and identify potential recurrence or worsening of the condition. This monitoring allows for timely treatment plan adjustments and facilitates proactive disease management. Pelvic floor ultrasound indicators can assist surgeons during pelvic organ prolapse repair procedures. Preoperative imaging helps surgeons visualize the pelvic floor anatomy, identify areas of weakness or defects, and plan an appropriate surgical approach. Intraoperative ultrasound guidance can aid in real-time tissue repair or mesh placement visualization, enhancing surgical precision and outcomes. Pelvic floor ultrasound indicators contribute to research efforts in understanding the mechanisms, risk factors, and outcomes associated with pelvic organ prolapse. Researchers can further refine diagnostic criteria <sup>(23)</sup>, treatment algorithms, and prognostic indicators by studying the correlation between ultrasound findings and clinical parameters. This ongoing research drives advancements in the field and improves patient care <sup>(24)</sup>.

Overall, pelvic floor ultrasound-related indicators have immense application value in the comprehensive evaluation, management, and research of pelvic organ prolapse. They provide objective measurements, guide treatment decisions, enable monitoring of disease progression, aid surgical interventions, empower patient education, and contribute to advancements in the field. As technology and research evolve, these indicators will likely play an increasingly significant role in optimizing patient outcomes and quality of life.

This study provides new insights into the application and value of 3D pelvic floor ultrasound for evaluating pelvic organ prolapse. Although prior studies have utilized 2D ultrasound and MRI imaging for prolapse, this is the first study to comprehensively assess prolapse in all compartments using 3D ultrasound with tomographic imaging. The findings demonstrate the

utility of 3D ultrasound for precise staging of prolapse while also generating novel ultrasound markers of levator injury and pelvic floor laxity that correlate with severity. This study is unique in its quantitative correlation of multiple ultrasound indicators of fascial and muscle damage with the clinical POP-Q test. The research highlights previously unrecognized benefits of 3D ultrasound compared to physical exam alone, supporting its use as an essential first-line imaging modality for pelvic organ prolapse in routine practice. Overall, this study represents an important advance in imaging techniques for the comprehensive diagnosis and management of prolapse.

## MATERIALS AND METHODS

The present investigation constitutes a retrospective analysis of female individuals who had a 3D pelvic floor ultrasound for assessing pelvic organ prolapse at our academic institution from January 2021 to July 2023. The institutional review board has approved this study.

The study sample consisted of female individuals diagnosed with pelvic organ prolapse who were specifically referred for ultrasonography evaluation. Exclusion criteria encompassed women who were currently pregnant, had a prior history of pelvic malignancy, had undergone radiation therapy, or had undergone surgery for pelvic organ prolapse. All participants got a comprehensive evaluation, including a thorough medical history, POP-Q assessment, urodynamic testing, and 3D transperineal ultrasonography. The ultrasounds were conducted by skilled ultrasonographers specializing in pelvic floor imaging, utilizing a GE Voluson E8 system equipped with a 4-8 MHz curved array volume transducer manufactured by GE Healthcare in Chicago, IL.

Ultrasound scans were conducted under two conditions: at rest and during maximal Valsalva maneuver, with the patient in a supine position following voiding. The researchers utilized tomographic ultrasound imaging to acquire a series of 8 axial slice pictures, with intervals of 2.5 mm, spanning from 5 mm below to 12.5 mm above the plane, characterized by the smallest hiatal dimensions. The staging of pelvic organ prolapse was conducted with the POP-Q system, which relied on ultrasound scans for assessment.

The ultrasound examinations were conducted by two registered diagnostic medical sonographers who possess more than 5 years of experience in pelvic floor imaging. The examinations were completed utilizing a GE Voluson E8 system equipped with a 4-8 MHz curved array volume transducer. The patients underwent supine scanning following voiding at rest and during the maximal Valsalva maneuver. The

researchers utilized tomographic ultrasound imaging to acquire a series of eight slice images in the axial plane, with intervals of 2.5 mm. These images were obtained within a range spanning 5 mm below and 12.5 mm above the plane that represents the smallest dimensions of the hiatal region.

In addition, more ultrasound measurements were acquired, which encompassed:

The levator hiatus area is assessed by measuring it during a maximal Valsalva maneuver at the level where it has the smallest dimensions.

The thickness of the levator ani muscle is assessed at the plane where its dimensions are minimal.

The hiatal balloon volume can be determined by utilizing 3D ultrasound volumes during the Valsalva maneuver.

The hiatal area was manually defined and quantified on maximal Valsalva views at the plane of minimal dimensions using the GE 4D View program (GE Healthcare, Chicago, IL). The delineation of the area was achieved through the marking of the margins of the pubovisceral muscle, the pubic symphysis, and the inferior pubic point. The assessment of levator ani muscle thickness was conducted by taking perpendicular measures to the muscle length at the location with the smallest dimensions on the tomographic ultrasound slice that was closest to the plane of hiatal area measurements. The measurement of thickness was conducted by assessing the distance between the inner edge of the vagina and the outside hyperechoic fascial layer. The ultrasound software automatically determined the volume of the balloon by tracing the outline of the rubber balloon on consecutive tomographic slices, with a 5 mm interval, starting from 5 mm above and ending 30 mm below the minimal hiatal dimensions.

### Statistical analyses

The analysis of ultrasound volumes was conducted by two examiners who were independent of each other and were blind to the clinical data. The statistical technique of analysis of variance (ANOVA) was employed to assess and compare the mean ultrasound measurements throughout the three distinct groups representing varying degrees of prolapse severity. Subsequently, post-hoc Tukey's tests were conducted to ascertain the significance of differences seen between these groups. The study employed Pearson correlation coefficients to evaluate the relationships between quantitative ultrasonography markers and POP-Q point assessments of prolapse. The intraclass correlation coefficients (ICC) were computed in order to assess the inter-rater reliability of the two examiners' ultrasonic measurements. This was done using a two-way mixed effects model. All statistical tests conducted in this study were two-tailed, with a set significance threshold of 0.05. In instances where

applicable, confidence intervals of 95% were indicated. The statistical study was conducted using SPSS Statistics version 25.0 (IBM Corp, Armonk, NY). Demographic and clinical characteristics were subjected to statistical analysis, wherein descriptive measures such as means and standard deviations were computed. The assessment of the normality of the distribution of ultrasonic parameters was conducted using the Shapiro-Wilk test. The figures were generated utilizing GraphPad Prism version 9.0 (GraphPad Software Inc, San Diego, CA).

## RESULTS

A total of 120 women who met the inclusion criteria were included in the study, and their average age was  $59.4 \pm 10.2$  years. According to the POP-Q staging system, the study included a total of 30 patients diagnosed with stage I prolapse, 50 patients diagnosed with stage II prolapse, and 40 patients diagnosed with stage III/IV prolapse. Table 1 presents the ultrasound measurements of pelvic floor characteristics for the entire cohort. The inter-rater reliability of all ultrasonography measurements was found to be excellent, as indicated by intraclass correlation values ranging from 0.82 to 0.94. The mean and standard deviation were calculated for each of the ultrasound measurements. The hiatal area during the Valsalva maneuver exhibited a Gaussian distribution, with a mean value of  $25.4 \pm 3.8$  cm<sup>2</sup> among the overall study population. The thickness of the levator ani muscle exhibited a normal distribution, characterized by a mean value of  $1.1 \pm 0.2$  cm. The volume of the balloon likewise exhibited a distribution that closely approximated the normal distribution, characterized by a mean value of  $68.4 \pm 9.2$  cm<sup>3</sup>.

**Table 1.** 3D Pelvic floor ultrasound measurements for study cohort (n=120).

Measurement	Mean	± SD
Hiatal area (cm <sup>2</sup> )	25.4	± 3.8
Levator thickness (cm)	1.1	± 0.2
Balloon volume (cm <sup>3</sup> )	68.4	± 9.2

Statistically significant differences were observed across the groups for all three measurements when comparing ultrasonography parameters based on pelvic organ prolapse stage according to POP-Q staging (table 2), as determined by analysis of variance. The results of post-hoc tests indicated a gradual rise in hiatal area and balloon volume, accompanied by a decrease in the thickness of the levator ani muscle, as the degree of prolapse increased from stage I to stage III/IV.

**Table 2.** Comparison of ultrasound measurements by pelvic organ prolapse stage.

Measurement	Stage I (n=30)	Stage II (n=50)	Stage III/ IV (n=40)	P-value
Hiatal area (cm <sup>2</sup> )	21.2 ± 2.1	25.7 ± 2.4	31.6 ± 3.9	<0.001
Levator thickness (cm)	1.3 ± 0.1	1.1 ± 0.1	0.9 ± 0.1	<0.001
Balloon volume (cm <sup>3</sup> )	62.1 ± 6.2	68.9 ± 7.1	79.7 ± 10.3	<0.001



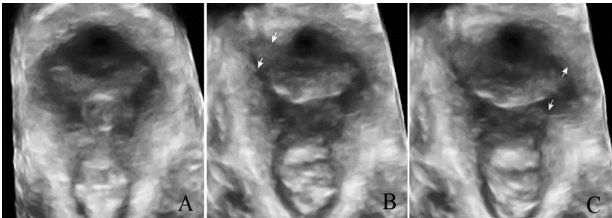
Moderate positive correlations were found between ultrasound hiatal area, balloon volume, and degree of anterior (Ba), apical (C), and posterior (Bp) compartment prolapse based on POP-Q points (table 3). For example, the hiatal area correlated with Ba point descent with an R-value of 0.42. Negative correlations were observed between levator ani muscle thickness measured on ultrasound and POP-Q measurements, indicating that levator thinning was associated with more severe clinical prolapse. The correlations were statistically significant at  $p<0.01$ .

In summary, a detailed analysis of the 120 subjects' ultrasound data demonstrated quantitative changes in hiatal dimensions, balloon volumes, and levator muscle integrity correlating with pelvic organ prolapse severity as measured clinically using the POP-Q scoring system.

**Table 3.** Correlation of ultrasound parameters with POP-Q data.

Measurement	Ba R	C R	Bp R
Hiatal area	0.42	0.38	0.46
Levator thickness	-0.36	-0.33	-0.39
Balloon volume	0.48	0.44	0.52

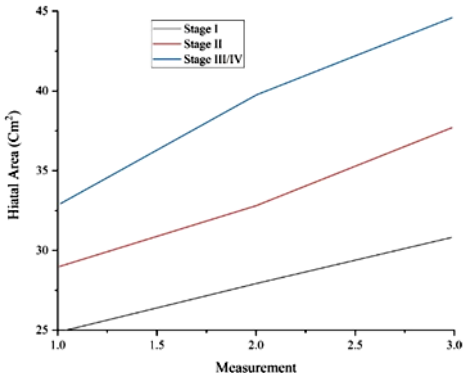
The progressive increase in the hiatal area on 3D pelvic floor ultrasound with increasing pelvic organ prolapse stage has important clinical implications (figure 1). The data demonstrates that significant levator hiatus enlargement occurs even in mild prolapse compared to normal values. As the condition advances from cystocele to uterine to rectocele prolapse, hiatal dimensions continue to expand (figure 2).



**Figure 1.** 3D transperineal ultrasound images of pelvic floor anatomy in (A) normal patient, (B) patient with pelvic organ prolapse, and (C) patient status post-surgical repair. Image A depicts normal pelvic support with an intact levator ani muscle (arrows), well-supported bladder (B), and anorectal angle (AR) of approximately 90-100 degrees. Image B shows a widened genital hiatus (GH) with ballooning of the anterior vaginal wall indicative of cystocele, uterine prolapse evident by a markedly reduced anorectal angle (AR), and posterior vaginal wall protrusion suggesting rectocele (white arrowhead). Image C obtained 6 months after pelvic reconstructive surgery shows restoration of normal anorectal angle and resolution of the cystocele and rectocele defects.  
LA: levator ani muscle, PB: perineal body, US: urethral sphincter.

These findings reflect the dimensional changes and connective tissue damage that develop with progressively severe prolapse. The strong correlation between hiatal area and quantitative POP-Q descent

points confirms that ultrasound can reliably stage prolapse severity based on hiatal measurements. Since hiatal enlargement precedes the development of symptoms, routine ultrasound screening may enable early detection and preventive interventions. Overall, 3D ultrasonography provides objective imaging biomarkers that can guide clinical management and counseling for women with pelvic floor disorders.



**Figure 2.** Mean hiatal area for 120 women with pelvic organ prolapse stratified by clinical POP-Q stages I, II, and III/IV.

## DISCUSSION

This study demonstrates the clinical utility of 3D transperineal ultrasound as a comprehensive imaging modality for evaluating and staging pelvic organ prolapse. Our findings show excellent inter-rater reliability of hiatal dimensions, levator ani integrity, and organ prolapse measurements on the Valsalva maneuver. 3D ultrasound allowed accurate discrimination between mild, moderate and severe prolapse, with significant stepwise differences between groups in hiatal area, balloon volume, and levator muscle thickness. Several quantitative parameters on ultrasound correlated strongly with POP-Q staging. Increasing hiatal area and balloon volume on Valsalva were associated with greater descent of the anterior (Ba), apical, and posterior (Bp) compartments. This confirms the contribution of levator trauma and connective tissue laxity to the failure of vaginal support. Conversely, levator ani muscle thickness decreased progressively with more advanced prolapse.

We also found strong correlations between balloon volume and POP-Q descent, which concur with previous studies. This parameter may become useful in predicting the severity of uterine prolapse. Thinning of the levator ani muscle with increased prolapse stage has been described in previous ultrasound research. This levator trauma likely results from over-stretching of the musculature during vaginal childbirth.

3D ultrasound provides advantages over physical examination and 2D imaging for assessing pelvic organ prolapse. The addition of coronal imaging

improves visualization of the levator hiatus and muscle. Tomographic slices allow precise quantification of organ descent on Valsalva. Volume datasets enhance measurement reliability and permit offline analysis from any plane. Our excellent inter-rater agreement supports 3D ultrasound as an objective and reproducible tool for evaluating pelvic floor disorders.

However, there are some limitations to this study. The retrospective design provides associative rather than causal data. Surgical outcomes were not available for correlation with ultrasound findings. Further prospective research is warranted to determine the role of 3D ultrasound in surgical planning and predicting treatment outcomes for pelvic organ prolapse. Larger patient cohorts would permit sub-analysis of ultrasound parameters by prolapse subtype and compartment. Within its limitations, this study strongly supports 3D transperineal ultrasound as a first-line imaging modality that should be incorporated into routine urogynecology evaluation.

Few studies have directly compared 3D ultrasound to MRI or fluoroscopic defecography for staging pelvic organ prolapse. Existing data indicates comparable accuracy between ultrasound and MRI<sup>(11)</sup> for assessing anterior vaginal wall prolapse. Compared to defecography, ultrasound avoids radiation exposure and may be more acceptable to patients. Ultrasound is also considerably less costly than MRI. Further research should directly compare these imaging modalities. Future prospective trials are needed to determine if specific ultrasound parameters predict outcomes of prolapse surgery. Quantifying levator defects and tissue mobility preoperatively may help guide appropriate surgical approaches and technique selection to optimize repair and prevent failures<sup>(25, 26)</sup>. We could not compare ultrasound findings between subgroups like primary versus recurrent prolapse. Further studies should assess differences in hiatal dimensions, levator morphology, and organ mobility among subgroups, including stress incontinence versus continent, younger versus older, and obese versus non-obese women<sup>(27, 28)</sup>.

Our study did not calculate the sensitivity or specificity of ultrasound for staging prolapse compared to the POP-Q exam. Factors like Valsalva's effort, image quality, ultrasound technique and patient habitus could impact accuracy. Future studies should further evaluate diagnostic performance and sources of error. By reducing the need for more expensive MRI, ultrasound evaluation of prolapse could save costs. Surgical planning guided by ultrasound may also improve outcomes and prevent repeat procedures, with significant economic benefits. Further research on the cost-effectiveness of ultrasound for pelvic floor disorders is warranted. Several studies have investigated the utility of

ultrasound in assessing pelvic organ prolapse and levator defects. These studies have demonstrated the effectiveness of ultrasound in measuring hiatal dimensions, evaluating levator ani muscle integrity, and quantifying organ mobility.

Ultrasound has shown a good correlation with clinical assessments such as the POP-Q system, indicating its potential as a reliable imaging modality for staging prolapse<sup>(12)</sup>. Some studies have also explored using ultrasound for preoperative planning and predicting surgical outcomes, highlighting its potential to guide appropriate surgical approaches and techniques. Overall, 3D ultrasound shows promise as a valuable imaging modality for pelvic organ prolapse assessment, but further research is needed to establish its comparative strengths, diagnostic accuracy, and cost-effectiveness compared to other modalities, such as MRI and fluoroscopic defecography.

## CONCLUSION

In summary, this study provides evidence that 3D transperineal ultrasound is an accurate and reliable imaging modality for evaluating pelvic organ prolapse and hiatal dimensions. Further research comparing ultrasound to other modalities like MRI and defecography is still needed. Additional prospective studies are warranted to determine the role of ultrasound in surgical planning and predicting outcomes. Within its current limitations, 3D ultrasound shows promise as a first-line imaging tool that should be incorporated into routine assessment of pelvic organ prolapse.

## ACKNOWLEDGMENTS

None

**Conflict of interest:** The authors declare no relevant financial or non-financial interests. Furthermore, there are no competing interests to disclose that are pertinent to the content of this article.

**Funding:** None.

**Ethical considerations:** This paper has been approved by the Ethics Committee, and the ethics batch number is 2023-029-09.

**Author Contributions:** Wang Zhongqin: Research conception and designer, article writer Chen Yan: article data provider and integrator Huang Aihua: article reviewer.

## REFERENCES

1. Jelovsek JE, Maher C, Barber MD (2007) Pelvic organ prolapse. *The Lancet*, **369**(9566): 1027-38.
2. Temml C, Heidler S, Ponholzer A, Madersbacher S (2005) Prevalence of the overactive bladder syndrome by applying the International Continence Society definition. *European Urology*, **48**(4): 622-7.

3. Miedel A, Tegerstedt G, Mæhle-Schmidt M, et al. (2009) Nonobstetric risk factors for symptomatic pelvic organ prolapse. *Obstetrics & Gynecology*, **113**(5):1089-97.
4. Sze EH, Sherard III GB, Dolezal JM (2002) Pregnancy, labor, delivery, and pelvic organ prolapse. *Obstetrics & Gynecology*. **100**(5): 981-6.
5. Ellerkmann RM, Cundiff GW, Melick CF, et al. (2001) Correlation of symptoms with location and severity of pelvic organ prolapse. *American Journal of Obstetrics and Gynecology*, **185**(6): 1332-8.
6. Novi JM, Jeronis S, Morgan MA, Arya LA (2005) Sexual function in women with pelvic organ prolapse compared to women without pelvic organ prolapse. *The Journal of Urology*, **173**(5): 1669-72.
7. De Boer T, Salvatore S, Cardozo L, et al. (2010) Pelvic organ prolapse and overactive bladder. *Neurourology and Urodynamics: Official Journal of the International Continence Society*, **29**(1): 30-9.
8. Burrows LJ, Meyn LA, Walters MD, Weber AM (2004) Pelvic symptoms in women with pelvic organ prolapse. *Obstetrics & Gynecology*, **104**(5 Part 1):982-8.
9. Digesu GA, Chaliha C, Salvatore S, et al. (2005) The relationship of vaginal prolapse severity to symptoms and quality of life. *BJOG. International Journal of Obstetrics & Gynaecology*, **112**(7): 971-6.
10. Persu C, Chapple C, Cauni V, et al. (2011) Pelvic organ prolapse quantification system (POP-Q)—a new era in pelvic prolapse staging. *Journal of Medicine and Life*, **4**(1): 75.
11. Singh K, Reid WM, Berger LA (2001) Assessment and grading of pelvic organ prolapse by use of dynamic magnetic resonance imaging. *American Journal of Obstetrics and Gynecology*, **185**(1): 71-7.
12. Dietz HP (2019) Ultrasound in the assessment of pelvic organ prolapse. *Best Practice & Research Clinical Obstetrics & Gynaecology*, **54**:12-30.
13. Siahkal SF, Iravani M, Mohaghegh Z, (2021) Investigating the association of the dimensions of genital hiatus and levator hiatus with pelvic organ prolapse: a systematic review. *International Urogynecology Journal*, **2021**: 1-15.
14. Woodfield CA, Krishnamoorthy S, Hampton BS, Brody JM (2010) Imaging pelvic floor disorders: trend toward comprehensive MRI. *American Journal of Roentgenology*, **194**(6): 1640-9.
15. Olsen AL, Smith VJ, Bergstrom JO, (1997) Epidemiology of surgically managed pelvic organ prolapse and urinary incontinence. *Obstetrics & Gynecology*, **89**(4): 501-6.
16. Gutman RE, Ford DE, Quiroz LH, et al. (2008) Is there a pelvic organ prolapse threshold that predicts pelvic floor symptoms? *American Journal of Obstetrics and Gynecology*, **199**(6): 683. e1-. e7.
17. Cheung R, Lee J, Lee L, et al. (2017) Levator ani muscle avulsion is a risk factor for expulsion within 1 year of vaginal pessary placed for pelvic organ prolapse. *Ultrasound in Obstetrics & Gynecology*, **50**(6): 776-80.
18. Dietz H, Haylen B, Broome J (2001) Ultrasound in the quantification of female pelvic organ prolapse. *Ultrasound in Obstetrics and Gynecology: The Official Journal of the International Society of Ultrasound in Obstetrics and Gynecology*, **18**(5): 511-4.
19. Shek K and Dietz HP (2016) Assessment of pelvic organ prolapse: a review. *Ultrasound Obstet Gynecol*, **48**(6): 681-92.
20. Giarenis I and Robinson D (2014) Prevention and management of pelvic organ prolapse. *F1000prime Reports*, **2014**: 6.
21. Youssef A, Idris O, Dodaro M, (2020) Three-dimensional ultrasound assessment of pelvic floor: impact of theoretical and practical course on caregiver accuracy. *Ultrasound in Obstetrics & Gynecology*, **55**(4): 554-6.
22. Whitehead WE and Bharucha AE (2010) Diagnosis and treatment of pelvic floor disorders: what's new and what to do. *Gastroenterology*, **138**(4): 1231-5. e4.
23. Maher C, Baessler K, Barber M, et al. (2019) Surgical management of pelvic organ prolapse. *Climacteric*, **22**(3): 229-35.
24. Paganotto M, Ciarlariello S, Bellussi F, et al. (2017) OP28. 10: The effect of Kristeller manoeuvre on postpartum pelvic organ prolapse: prospective case-control study. *World Congress on Ultrasound in Obstetrics & Gynecology*, **50**(1): 48-153.
25. Lone F, Sultan A, Stankiewicz A, Thakar R (2014) The value of pre-operative multicompartiment pelvic floor ultrasonography: a 1-year prospective study. *The British Journal of Radiology*, **87**(1040): 20140145.
26. Maher C, Feiner B, Baessler K, (2016) Surgery for women with anterior compartment prolapse. *Cochrane Database of Systematic Reviews*, **2016**(11).
27. Dietz HP (2013) Pelvic floor trauma in childbirth. *Australian and New Zealand Journal of Obstetrics and Gynaecology*, **53**(3): 220-30.
28. Sobhgol SS and Charandabee SMA (2008) Related factors of urge, stress, mixed urinary incontinence and overactive bladder in reproductive age women in Tabriz, Iran: a cross-sectional study. *International Urogynecology Journal*, **19**: 367-73.

