

The role of imaging techniques in the diagnosis and treatment of neonatal pneumothorax: A comparative analysis of ultrasound and chest X-ray

H. Leng*, Y. Zhang, L. Zhang, Y. Liu

Department of Neonatology, Chongzhou People's Hospital, 611230, Chengdu, Sichuan, China

► Review article

*Corresponding author:

Hui Leng, Ph.D.,

E-mail: Lenghuicz@163.com

Received: September 2023

Final revised: November 2023

Accepted: December 2023

Int. J. Radiat. Res., April 2024;
22(2): 495-500

DOI: 10.61186/ijrr.22.2.495

Keywords: Neonatal pneumothorax, ultrasonography, mass chest X-ray, radiation.

ABSTRACT

While neonatal pneumothorax (NP) is uncommon, it presents a serious condition requiring immediate and precise diagnosis and treatment. To achieve this, dependence on imaging techniques is crucial for detecting gas accumulation within the infant's thoracic cavity. Traditionally, diagnosing NP relies heavily on Chest X-ray (CXR) examinations, involving ionizing radiation exposure, a persisting concern. Conversely, lung ultrasonography (LUS) has gained widespread recognition due to its convenience, expediency, and radiation-free attributes. The debate over whether LUS can completely replace traditional CXR remains contentious. Our objective is to conduct a thorough analysis of the efficacy of LUS and CXR examinations in diagnosing NP, with the intention of offering additional references for clinicians to optimize medical care for infants, minimizing radiation exposure and ensuring comprehensive protection of their health and safety.

INTRODUCTION

Neonatal pneumothorax (NP) is characterized by the accumulation of gas in the chest cavity after birth, resulting in lung compression and triggering respiratory distress in newborns. It represents one of the more prevalent critical illnesses in neonates admitted to the intensive care unit ⁽¹⁾. Pneumothorax is categorized into two types: primary and secondary. Primary pneumothorax results from congenital lung tissue abnormalities, while secondary pneumothorax is typically associated with other diseases or conditions (e.g., prematurity, neonatal induced pneumonia, mechanical ventilation, etc.) ⁽²⁾. Common clinical signs of NP include shortness of breath, dyspnea, diminished cries, pallor or cyanosis, and emotional distress. A sudden increase in the respiratory rate aids in reliably identifying early signs of impending NP ⁽³⁾. While NP is relatively rare, its incidence may vary regionally and among specific populations. Mortality typically depends on the severity of the condition and the efficacy of early diagnosis and treatment. A retrospective survey of 71,237 neonates in Canada revealed that the incidence of pneumothorax (PTX) in the neonatal population was 4.00% in early preterm, 2.60% in mid- to late-term preterm, and 6.70% in full-term neonates ⁽⁴⁾. Another survey from the United States of

America demonstrated that among 13,811 neonates, the prevalence of PTX was 2.50% in infants with a birth weight of <2500 g and 2.50% in infants with a birth weight of ≥2500 g ⁽⁵⁾. Proper treatment of NP typically results in no significant long-term sequelae. However, in some cases, especially if the pneumothorax is severe or progresses rapidly, it may be accompanied by hypoxia, hypercapnia, and sudden deterioration of cardiorespiratory fitness ⁽⁶⁾, necessitating long-term monitoring and management. Rapid and accurate diagnosis facilitates early intervention in NP development, minimizing the likelihood of sequelae.

Ultrasonography offers radiation-free, real-time, high-resolution images for assessing gas accumulation in the thoracic cavity ⁽⁷⁾. LUS primarily employed to observe peripheral lung lesions and pleural manifestations. In cases of pneumothorax, air is present between the chest wall and the visceral pleura, which is shallow and easily visualized using ultrasound. This method is particularly advantageous in neonates due to their thin chest wall and small lung volume ⁽⁸⁾. This feature aids neonates in reducing the risk of respiratory distress, respiratory muscle fatigue, and other complications. The accuracy of ultrasound features in detecting NP is now widely validated ⁽⁹⁾. Ultrasound imaging can typically be performed through the chest wall

without invasive procedures. Typically, physicians require some training and experience to perform ultrasound for pneumothorax detection. Additionally, ultrasonography is a real-time examination method that enables immediate observation of results by the physician. This makes ultrasonography a powerful tool in NP management due to its research advances, accuracy, and ease of use.

The standard diagnostic method for detecting pneumothorax is computed tomography (CT), but CXR is often used as a first-line diagnostic test⁽¹⁰⁾. CXR technology, also known as chest fluoroscopy, is a medical imaging method focused on creating images of chest structures through X-ray radiation to diagnose diseases and injuries⁽¹¹⁾. X-rays penetrate the patient's chest, and their absorption by different tissues results in the creation of an image on a photographic negative or digital detector. Consequently, CXRs have been widely employed to detect diseases such as lung infections, pneumothorax, and chest trauma⁽¹²⁾. Despite its non-invasive nature, CXR technology may lack the precision of other imaging techniques (e.g., CT scan or MRI) in certain cases. Additionally, CXRs emit ionizing radiation, posing a potential risk of cellular damage. Clinical staff routinely take measures to minimize patients' radiation exposure, especially for pregnant women and newborns. Therefore, this study explores whether ultrasonography can serve as a safer, faster, and more accurate screening method to mitigate the risks of ionizing radiation and provide health protection for newborns. This study conducted searches in the PubMed database, Web of Science database, and Google Scholar to investigate whether ultrasonography could serve as a safer, faster, and more accurate method to mitigate the risk of ionizing radiation for the health of newborns. The keywords "Pneumothorax," "neonatal," "imaging," "ultrasound," and "X-ray" were employed for a comprehensive full-text search. A substantial body of literature was reviewed to assess the potential of ultrasonography as a safer, faster, and more accurate screening method to minimize the hazards of ionizing radiation and provide health protection for newborns. To the best of our knowledge, this study represents the first attempt to explore the safety and efficacy of ultrasonography and CXR in managing neonatal pneumonia.

Ultrasound in neonatal pneumothorax

Technical principles and application scenarios

In ultrasound diagnosis, physicians employ ultrasound probes to transmit high-frequency sound waves to various body parts of newborns, subsequently detecting the reflections of these waves in tissues to assess the health status of the newborn. Ultrasound proves effective in revealing abnormal pockets or sacs of gas when a pneumothorax leads to air accumulation in the chest cavity⁽¹³⁾. At this stage,

the physician can utilize the ultrasound image to determine the location, size, and severity of the pneumothorax. With technological advancements, an increasing number of hospitals and healthcare facilities are integrating portable and handheld ultrasound equipment, facilitating ultrasound examinations in neonatal wards or infant care units and enhancing diagnostic accessibility⁽¹⁴⁾.

The assessment of pneumothorax progression through ultrasonography is currently considered a safe, straightforward, and radiation-free method for visualizing the status of peripheral lung lesions and pleural manifestations, proving to be a valuable diagnostic tool employed by specialists⁽¹⁵⁾. Various lung conditions, including respiratory distress syndrome, neonatal transient dyspnea, pneumonia, atelectasis, and pneumothorax, can be readily diagnosed using LUS^(16, 17). Key LUS indicators of neonatal pneumothorax encompass the disappearance of lung glides, B-lines, pleural and A-lines, and/or lung points. Furthermore, the vanishing of the pleural line hiatus (PHI) is a rare ultrasound sign on LUS, and selecting the precordial region as the puncture site is considered safe for treating neonatal pneumothorax in cases where PHI disappears. The high resolution of ultrasound enables physicians to observe real-time ultrasound images, providing better guidance for therapeutic procedures like thoracentesis, thereby minimizing unnecessary trauma⁽¹⁸⁾. However, the inability of ultrasound waves to pass through air creates reflection artifacts, preventing LUS from serving as a complete substitute for chest X-rays or CT/MRI scans⁽¹⁹⁾. Consequently, if the neonate's clinical symptoms are not effectively alleviated with medication or if the clinical manifestations do not align with ultrasound results, it is advisable to conduct a chest X-ray or CT/MRI scan to avoid misdiagnosis and mistreatment.

Operational precautions

When utilizing ultrasound for NP diagnosis, practitioners must adhere to specific principles and precautions to ensure accurate diagnosis and neonatal safety. Following the determination of the ultrasound scan position, the physician should select an appropriate linear high-frequency probe, examining various directions, including longitudinal and transverse, to gather comprehensive information. Real-time monitoring to identify optimal dynamic changes allows for capturing images, providing essential clinical references for treatment. Given the challenges posed by uncooperative newborns, additional personnel may be enlisted to assist in securing the infant's position during the examination, minimizing the risk of accidental injury from the instrument. In instances where the neonate cries, the physician should elucidate the procedure and results, furnish clear information to the parents or guardians to alleviate anxiety, and seek their

assistance in calming the neonate.

If PTX puncture therapy is warranted based on LUS, strict aseptic techniques are observed to ensure procedural safety. In general, the intercostal space exhibiting B-shaped pleural and A lines, the space where lung sliding disappears on real-time LUS, and the site of the M-shaped stratospheric sign are considered safe puncture sites. Continuous monitoring of neonates post-puncture is imperative to prevent potential serious complications arising from pneumothorax.

Future development

With technological advancements, 5G-based remote ultrasound consultation offers some patients the opportunity to access medical treatment locally, reducing the time and transport costs associated with traveling to and from larger hospitals, thereby alleviating the economic burden on patients. Nevertheless, the clarity of dynamic ultrasound images directly influences the judgment of remote expert consultations. Enhancing the resolution of dynamic ultrasound images in remote settings can aid experts in clearly discerning details of pneumothorax, such as the size and position of the air sac, thereby effectively improving the compliance rate of remote ultrasound diagnoses.

Expanding on traditional ultrasound diagnostic technology, the incorporation of 3D ultrasound imaging, along with computer-aided diagnosis and deep learning technology, and integrated multimodal imaging, promises a more comprehensive assessment of pneumothorax. This approach facilitates automatic pneumothorax detection, reducing subjective operator interventions and enhancing result accuracy. Moreover, utilizing ultrasound technology for real-time monitoring of pneumothorax changes and guiding minimally invasive puncture techniques to minimize patient discomfort and risk represents a promising avenue for future technological advancements.

Throughout the entire ultrasound diagnostic process, the operator's proficiency, training, emergency thinking, critical care expertise, and other knowledge reserves are pivotal factors influencing the development of ultrasound technology. There is a pressing need to integrate ultrasound with emergency and critical care theoretical systems to facilitate its more effective application in clinical settings.

Application of CXR in neonatal pneumothorax

Technical principles and application scenarios

The technical process underlying CXR for diagnosing NP encompasses the transmission, capture, and generation of X-ray images⁽²⁰⁾. X-rays, being high-energy electromagnetic radiation, are absorbed to varying degrees by substances of different densities in body tissues. Accumulated air in

pneumothorax exhibits low X-ray absorption, appearing as a darker area distinguishable from the brighter surrounding tissues⁽²¹⁾. The transmitted X-rays are captured by a digital X-ray detector and converted into a digital image. Clinical digital image recognition features of pneumothorax include reduced lung volume and the presence of a dark area in the thoracic cavity. However, specific X-ray manifestations closely correlate with the amount of free gas, lung freedom, and body position^(22, 23).

As X-rays involve radiation, physicians should carefully balance medical necessity against the risk of radiation exposure. For neonates with respiratory and cardiovascular symptoms resembling pneumothorax, X-rays can aid physicians in ruling out other underlying diseases, ensuring accurate diagnosis⁽²²⁾. Additionally, in neonates requiring surgical intervention for pneumothorax, CXRs can be used preoperatively to assess the extent and location of the pneumothorax, aiding the surgical team in planning the operation and evaluating postoperative outcomes. Despite their utility, CXR instruments lack portability, hindering real-time monitoring of neonatal pneumothorax. In cases of tension pneumothorax, waiting for an X-ray may not be feasible⁽²⁴⁾. Furthermore, X-ray equipment and examinations are generally less costly compared to some advanced ultrasound equipment (CT/MRI). LUS and CXR images of a NP patient were selected for display (figure 1)⁽²⁵⁾.

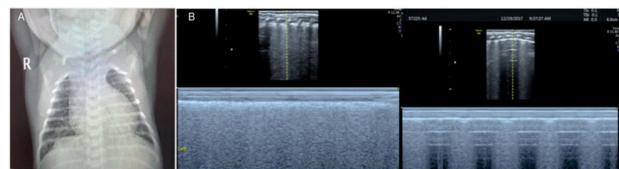


Figure 1. The chest X-ray (CXR) exhibits an increase in pulmonary markings with a blurred pattern, and a distinct "spinning top-shaped" shadow is clearly visible. Signs of pneumothorax (A) are detected. Lung ultrasonography (LUS, M-mode): The left lung reveals the presence of "comet tail artifacts," while the right lung exhibits the typical "lung point" sign, confirming the presence of right-sided pneumothorax (B).

Operational note

When neonatal pneumothorax occurs, gas tends to accumulate in the anterior part of the chest cavity, on the diaphragm, and in the inner part of the lung field. Due to the unique chest structure of neonates, coupled with immature development and lower cooperation ability, they are more susceptible to radiation, making it challenging to obtain high-quality imaging. To achieve such images, a standardized approach to camera operation is crucial, accompanied by an effective radiation protection strategy to mitigate the impact of radiation exposure on the neonate.

In general, it is advisable to position the neonate in the supine anterior-posterior position, with both

upper limb joints internally rotated, pulling the scapulae to the sides, straightening both lower limbs, and immobilizing both upper and lower limbs using sandbags of appropriate weight. Projections are made without filters, and the focal spot distance is typically set at 70 cm. The tube current was fixed at 50 mA, the tube voltage ranged between 45 and 55 kV, and the exposure time was established at 0.10 s. Aligning the centerline at three transverse fingers below the sternoclavicular joint, it was further tilted 10~15° toward the foot's side to minimize overlap between the lung field and the diaphragm (25). To prevent the neonate's crying and restlessness from affecting image quality, it's crucial to grasp respiratory amplitude and crying patterns effectively. The exposure button should be pressed after observing the neonate's chest elevation during the brief period of crying and breath change. Additionally, attention should be paid to tilting the ray towards the foot at a certain angle, elongating the lung field to reduce the obscuring range of the transverse septum. For critically ill neonates in special conditions where turning is not feasible, a lateral horizontal position may be adopted, placing the IP plate on the affected side. The centerline is ingested vertically in the horizontal direction on the other side, with careful observation of respiratory dynamics and capturing the relative instantaneous exposure during inhalation.

Reducing radiation damage

Neonates face an elevated risk of potential adverse effects from CXRs due to their small size and proximity to radiosensitive tissues and organs. When employing CXRs for neonatal pneumothorax diagnosis, physicians should prioritize the use of the lowest necessary X-ray radiation dose and meticulously document it (26). Adhering to the principles of small irradiation fields and employing thick filters can enhance radiograph quality while minimizing the radiation dose to the child (27). A judicious and scientifically determined irradiation field of view can mitigate unnecessary limb irradiation and obviate the need for filters. Regular maintenance of mechanical equipment, such as IP boards, is essential to promptly eliminate potential artifacts. Focused inspections of the optical system, mechanical system, and information conversion system, coupled with optimization of image quality through computer image processing, can prevent unnecessary harm from secondary radiation on neonates. When feasible, the addition of appropriate thickness of radiation filters, judicious adjustment of irradiation dose, strict adherence to operating procedures, and the use of shields to protect sensitive areas such as the genitals and thyroid gland of newborns collectively contribute to minimizing the impact of radiation on neonates and obtaining high-quality imaging images.

Safety, sensitivity and limitations of LUS and CXR in NP diagnosis

Some studies indicate that LUS exhibits higher sensitivity compared to conventional CXRs in diagnosing pneumothorax (6, 28-31). This heightened sensitivity may be attributed to X-rays' susceptibility to lung and tissue overlap, leading to a substantial discrepancy between values assessed on chest orthopantomograms and actual values, posing a risk of clinical misinformation. This risk is particularly pronounced in critically ill patients with respiratory compromise requiring mechanical ventilation.

A scarcity of literature exists on the value of ultrasound and CXR in NP. Cizmeci *et al.* (32) observed that the sensitivity of a positive CXR sign was below 50% in neonatal patients in the supine position, with a leakage rate as high as 41% (29). Alrajab *et al.* (33) conducted a comprehensive search on MEDLINE, EMBASE, and the Cochrane Library, comparing English articles on ultrasound and chest radiography's accuracy and validity for pneumothorax diagnosis. Their analysis of current literature concluded that LUS is more accurate than CXR for pneumothorax detection. Results from a trial by Lichtenstein *et al.* (34, 35) supported the superiority of ultrasound over CXR in pneumothorax diagnosis, albeit without complete differentiation between adults and neonates. Chen *et al.* (36) assessed 3405 neonates in an intensive care unit, determining that LUS, with its advantages of radiation-free exposure and non-invasive monitoring of treatment progress, is clinically valuable for diagnosing lung disease in preterm infants compared to CXR. A study in Guinea suggested that in resource-limited settings, chest radiography is more effective than CXR in critically ill NP patients. In such cases, CXR may not be necessary, but LUS proves helpful (37). A Chinese study provided more conclusive results, asserting that LUS could entirely replace CXR based on three years of clinical practice (38). This could benefit from the dynamic imaging feature of LUS. Unaffected by respiratory movements, the ultrasound probe can effortlessly detect even the smallest lung areas.

Additional studies indicate that LUS aligns with the sensitivity of conventional CXR. Luigi *et al.* (39) conducted LUS, CTR, and CXR on 23 patients with NP, demonstrating that the accuracy of LUS in diagnosing NP was at least as good as that of CXR, while CTR's accuracy was lower. However, CXR possesses certain diagnostic weaknesses, such as higher effective dose to infants (40). Moreover, the infant's position and the radiation beam's orientation may hinder the detection of pathological lesions in specific lung regions, like posterior dorsal, parasternal, or paravertebral lung segments. Therefore, considering comparable accuracy, we recommend opting for the LUS approach for NP diagnosis and guided treatment to minimize neonatal radiation exposure. A literature review on the use of CXR for NP diagnosis, treatment,

or grading revealed no precise mention of precautions related to newborn radiation protection. Standardized practices and radiation dose control should be implemented in the diagnosis and treatment of NP.

CONCLUSIONS

Both LUS and CXR possess distinct advantages and disadvantages. They should be employed as complementary diagnostic methods to furnish accurate, timely, and reliable information. We advocate for clinicians to acquire an in-depth understanding of the strengths of each method to mitigate radiation exposure in newborns.

ACKNOWLEDGMENTS

The authors express their gratitude to all individuals involved in the review process.

Conflicts of Interest: The authors affirm that they have no conflicts of interest to disclose.

Ethical Consideration: Ethical considerations were not applicable in the context of this study.

Authors' contributions: Each author made an equal and substantial contribution to the research surveys, literature review, and manuscript composition.

Financial support: It is pertinent to note that this study did not receive any financial support.

REFERENCES

- Al Matary A, Munshi HH, Abozaid S, et al. (2017) Characteristics of Neonatal Pneumothorax in Saudi Arabia: Three Years' Experience. *Oman Med J*, **32**(2): 135-139.
- Alleva DG, Kaser SB, Beller DI (1998) Intrinsic defects in macrophage IL-12 production associated with immune dysfunction in the MRL/++ and New Zealand Black/White F1 lupus-prone mice and the Leishmania major-susceptible BALB/c strain. *J Immunol*, **161**(12), 6878-6884.
- Alrajab S, Youssef AM, Akkus NI, et al. (2013) Pleural ultrasonography versus chest radiography for the diagnosis of pneumothorax: review of the literature and meta-analysis. *Crit Care*, **17**(5): R208.
- Alrajhi K, Woo MY, Vaillancourt C (2012) Test characteristics of ultrasonography for the detection of pneumothorax: a systematic review and meta-analysis. *Chest*, **141**(3): 703-708.
- Aly H, Massaro A, Acun C, et al. (2014) Pneumothorax in the newborn: clinical presentation, risk factors and outcomes. *J Matern Fetal Neonatal Med*, **27**(4): 402-406.
- Gregorio-Hernández R, Pérez-Pérez A, Alonso-Ojembarrera A, et al. (2022) Neonatal pneumothoraces with atypical location: the role of lung ultrasound. *European journal of pediatrics*, **181**(4): 1751-1756.
- Bhalla D, Naranje P, Jana M, et al. (2022) Pediatric lung ultrasonography: current perspectives. *Pediatric Radiology*, **52**(10): 2038-2050.
- Wang J, Wei H, Chen H, et al. (2022) Application of ultrasonography in neonatal lung disease: An updated review. *Frontiers in Pediatrics*, **10**: 1020437.
- Perri A, Tana M, Riccardi R, et al. (2020) Neonatal lung ultrasonography score after surfactant in preterm infants: A prospective observational study. *Pediatric Pulmonology*, **55**(1): 116-121.
- Tulay CM, Yaldiz S, et al. (2018) Oblique chest X-ray: An alternative way to detect pneumothorax. *Annals of thoracic and cardiovascular surgery: official journal of the Association of Thoracic and Cardiovascular Surgeons of Asia*, **24**(3): 127-130.
- Swenson J, Bloch R, et al. (2023) Male adolescent with syncope and abnormal chest X-ray. *Annals of Emergency Medicine*, **81**(2): e13-e14.
- Gassert FT, Urban T, Frank M, et al. (2023) X-ray dark-field chest imaging: qualitative and quantitative results in healthy humans. *Radiology*, **306**(2): e229037.
- Du X, Wang J, Zhou Q, et al. (2018). Advanced physical techniques for gene delivery based on membrane perforation. *Drug Delivery*, **25**(1): 1516-1525.
- Burton SO, Donovan JK, Jones SL, et al. (2022) Can non-physician providers use ultrasound to aid in establishing peripheral IV access in patients who are difficult to cannulate? A scoping review. *Prehospital and Disaster Medicine*, **37**(4): 535-546.
- Ramos Hernández C, Núñez Delgado M, Botana Rial M, et al. (2021) Validity of lung ultrasound to rule out iatrogenic pneumothorax performed by pulmonologists without experience in this procedure. *Revista Clinica Espanola*, **221**(5): 258-263.
- Chichra A, Makaryus M, Chaudhri P, et al. (2016) Ultrasound for the Pulmonary Consultant. *Clinical medicine insights. Circulatory, Respiratory and Pulmonary Medicine*, **10**: 1-9.
- Smargiassi A, Inchingolo R, Chiappetta M, et al. (2019) Agreement between chest ultrasonography and chest X-ray in patients who have undergone thoracic surgery: preliminary results. *Multidisciplinary Respiratory Medicine*, **14**: 9.
- Alleva DG, Kaser SB, et al. (1998) Intrinsic defects in macrophage IL-12 production associated with immune dysfunction in the MRL/++ and New Zealand Black/White F1 lupus-prone mice and the Leishmania major-susceptible BALB/c strain. *Journal of Immunology (Baltimore, Md: 1950)*, **161**(12): 6878-6884.
- Baum S (2012) Current readings in nuclear medicine. *Clinical Nuclear Medicine*, **37**(9): 922-930.
- Piérard GE and Piérard-Franchimont C (1993) Effect of a topical erythromycin-zinc formulation on sebum delivery. Evaluation by combined photometric-multi-step samplings with Sebutape. *Clinical and experimental dermatology*, **18**(5): 410-413.
- MMA opposes Medicare cuts (1995) *Minnesota Medicine*, **78**(3): 38.
- Huang J, Zhang H, Li T, et al. (2015) Assessment of human sinus cavity air volume using tunable diode laser spectroscopy, with application to sinusitis diagnostics. *Journal of Biophotonics*, **8**(11-12): 985-992.
- Balshine S and Blomqvist D (1999) Parental behaviour in Kentish plovers: who cares? *Trends in Ecology & Evolution*, **14**(8): 293-294.
- Shajin T and Reang P (2020) Vein finder - A cost-effective tool to screen pneumothorax in neonatal intensive care unit. *The Indian Journal of Medical Research*, **152**(1): S25.
- Liu J, Lovrenski J, Ye Hlaing A, et al. (2021) Neonatal lung diseases: lung ultrasound or chest X-ray. *The journal of maternal-fetal & neonatal medicine : the official journal of the European Association of Perinatal Medicine, the Federation of Asia and Oceania Perinatal Societies, the International Society of Perinatal Obstetricians*, **34**(7):1177-1182.
- Szymońska I, Wentrys Ł, Jagła M, et al. (2019) Lung ultrasound reduces the number of chest X-rays in newborns with pneumothorax. *Developmental Period Medicine*, **23**(3): 172-177.
- Barriga F, Ramirez, P, Wietstruck A, et al. (2012) Hematopoietic stem cell transplantation: clinical use and perspectives. *Biological Research*, **45**(3): 307-316.
- Shostak E, Brylka D, Krepp J, et al. (2013) Bedside sonography for detection of postprocedure pneumothorax. *Journal of ultrasound in medicine: official journal of the American Institute of Ultrasound in Medicine*, **32**(6), 1003-1009.
- Alrajhi K, Woo MY, et al. (2012) Test characteristics of ultrasonography for the detection of pneumothorax: a systematic review and meta-analysis. *Chest*, **141**(3), 703-708.
- Liu X, Si S, Guo Y, et al. (2022) Limitations of Bedside Lung Ultrasound in Neonatal Lung Diseases [J]. *Front Pediatr*, **10**: 855958.
- Sandig J, Bührer C, Czernik C (2021) Lungensultraschall in der Neonatologie zur Diagnostik eines Pneumothorax (Teil 2): Eine Praxisanleitung [Lung Ultrasound in Neonatology to diagnose a Pneumothorax (part two): A Guideline]. *Zeitschrift für Geburtshilfe und Neonatologie*, **225**(2): 105-110.
- Cizmec MN, Akin K, Kanburuglu MK, et al. (2013) The utility of special radiological signs on routinely obtained supine anteroposterior chest radiographs for the early recognition of neonatal pneumothorax. *Neonatology*, **104**(4): 305-311.
- Alrajab S, Youssef AM, Akkus NI, et al. (2013) Pleural ultrasonogra-

- phy versus chest radiography for the diagnosis of pneumothorax: review of the literature and meta-analysis. *Critical care (London, England)*, **17**(5): R208.
34. Lichtenstein DA and Menu Y (1995) A bedside ultrasound sign ruling out pneumothorax in the critically ill. Lung sliding. *Chest*, **108**(5): 1345–1348.
 35. Lichtenstein D, Mezière G, Biderman P, et al. (1999) The comet-tail artifact: an ultrasound sign ruling out pneumothorax. *Intensive Care Medicine*, **25**(4): 383–388.
 36. Chen SW, Fu W, Liu J, et al. (2017) Routine application of lung ultrasonography in the neonatal intensive care unit. *Medicine*, **96**(2): e5826.
 37. Alves MBN, Conté N, Sory Diallo I, Roth-Kleiner M (2021) Clinical presentation and improvised management of neonatal pneumothorax in the setting of a low-resource country: Conakry, Guinea. *BMJ case reports*, **14**(3): e235801.
 38. Gao YQ, Qiu RX, Liu, J, et al. (2022) Lung ultrasound completely replaced chest X-ray for diagnosing neonatal lung diseases: a 3-year clinical practice report from a neonatal intensive care unit in China. *The journal of maternal-fetal & neonatal medicine: the official journal of the European association of perinatal medicine, the federation of Asia and Oceania perinatal societies, the International Society of Perinatal Obstetricians*, **35**(18): 3565–3572.
 39. Ozturk E, Tanidir IC, Yildiz O, et al. (2017) The efficacy of thoracic ultrasonography in postoperative newborn patients after cardiac surgery. *Brazilian Journal of Cardiovascular Surgery*, **32**(4): 283–287.
 40. Paydar R, Takavar A, Kardan MR, Babakhani A, Deevband Mr, Saber S (2012) Patient effective dose evaluation for chest X-ray examination in three digital radiography centers. *Int J Radiat Res*, **10**(3-4): 139-143.