

Reducing contrast media extravasation during dynamic CT scanning by combined dexamethasone acetate cream and massage

X.L. Xu, R.L. Xie, J.C. Chen, Y.S. Ye*

Department of Radiology, Guangdong Provincial Hospital of Chinese Medicine, Guangdong, China

ABSTRACT

► Short Report

***Corresponding author:**

Yongsong Ye, MM.,

E-mail:

ye7yong7song@163.com

Received: January 2024

Final revised: January 2024

Accepted: February 2024

Int. J. Radiat. Res., April 2024;
22(2): 509-513

DOI: 10.61186/ijrr.22.2.509

Keywords: Compound dexamethasone acetate cream, massage, iodine contrast extravasation.

Background: To investigate the clinical efficacy of compound dexamethasone acetate cream coordinated with massage in the treatment of iodine contrast extravasation.

Materials and Methods: There were sixty patients who were selected in total with iodine contrast extravasation transferred to our hospital from June 2020 to June 2021. With the adaption of the random number method, patients were split into observation group and control group, with 30 cases in each. Compound dexamethasone acetate cream coordinated with massage was applied to the observation group. Meanwhile, simple compound dexamethasone acetate cream was applied to the other group. The clinical efficacy, swelling and pain degree and complication rate of the two groups were compared. **Results:** The clinical effective rate of the former group (93.33%) was considerably higher than that of the latter (86.67%), the discrepancy was quite essential in statistics ($P < 0.05$). Apart from that, the limb swelling value, redness and swelling resolution time and pain resolution time in the former group were considerably less than those in the latter one, which was with statistical essential ($P < 0.05$). Besides, the incidence of complications in observation group (3.33%) was also considerably lower than that in control group (13.33%), and the two sets of data indicate the statistically significant difference ($P < 0.05$) as well. **Conclusion:** Compound dexamethasone acetate cream combined with massage for the treatment of iodine contrast extravasation has definite clinical efficacy and high safety, which is able to considerably ameliorate the clinical symptoms of patients, which is worthy of widespread clinical application.

INTRODUCTION

Tumor imaging stands as a cornerstone in modern healthcare, profoundly influencing cancer detection and management. Crucially, it enables early detection, enhancing treatment efficacy and expanding therapeutic options. Advanced modalities, including MRI, CT, PET, and ultrasound, provide non-invasive insights into tumor characteristics, guiding clinicians in distinguishing between benign and malignant lesions. The precision afforded by tumor imaging facilitates personalized treatment plans, optimizing interventions and minimizing adverse effects. CT dynamic enhancement scanning and angiography imaging methods are widely used in clinical diagnosis and treatment, which have the advantage of non-invasive and convenience. The operation process requires the injection of contrast agent, and the iodine contrast agent is injected through a high pressure syringe, taking advantage of the difference in the absorption density of the contrast agent in normal and diseased tissues, so as to make accurate qualitative positioning of the lesion^(1,2). However, the high-pressure syringe is easy to cause extravasation during the intravenous injection of iodine contrast

agent, which not only affects the image quality, but also causes damage to the subjects. Extravasation of contrast agents into vascular peripheral tissues can change the osmolarity of the tissue space, making water molecules entering the cells and causing tissue swelling⁽³⁾, which, in severe cases, can cause necrosis, phlebitis, osteocompartment syndrome, limb dysfunction and so on⁽⁴⁾. Therefore, giving timely and effective intervention during iodine contrast extravasation can help to reduce the pain level in patients and avoid medical risks. Compound dexamethasone acetate cream is one of the commonly used glucocorticoid drugs for iodine contrast agent extravasation, which has the effect of reducing and preventing tissue inflammatory response and inhibiting inflammatory cells^(5,6). Massage can push away the extravasated iodine contrast agent, thus playing a rapid relief of tissue swelling and pain symptoms⁽⁷⁾. However, most of the current clinical studies on extravasation of iodine contrast agents aim at local drug cold compress, nursing and other aspects^(8,9), few studies on compound dexamethasone acetate cream and massage. In conclusion, this study focuses on the clinical efficacy of compound dexamethasone acetate

cream and massage in the treatment of iodine contrast extravasation, a topic that has received limited attention in current literature. Our research uniquely investigates the combined approach of using compound dexamethasone acetate cream and massage. The novelty lies in the exploration of a comprehensive treatment strategy addressing both the inflammatory response and the mechanical removal of extravasated iodine contrast agent. By studying 60 patients over a one-year period, this research aims to contribute valuable insights into an underexplored aspect of iodine contrast extravasation management. The findings are anticipated to offer a theoretical foundation for enhancing clinical symptom management in patients experiencing iodine contrast extravasation, potentially paving the way for more effective and holistic interventions in the future.

MATERIALS AND METHODS

General information

There were sixty patients with iodine contrast extravasation were selected and transferred to our hospital from June 2020 to June 2021, 33 males and 27 females; aged from 24 to 64 years, mean age was 47.85 ± 5.31 years; scanning site: 21 head, 23 abdomen and 16 pelvis. They were randomly split into two different groups which were the observation group and the control group, with 30 cases in each. The former group was treated with compound dexamethasone acetate cream coordinated with massage, while the other one was treated with simple compound dexamethasone acetate cream. Fully informed of the content of the study, all the patients and their families signed an informed consent form. This study was approved by the Ethics Committee of Guangdong Provincial Hospital of Chinese Medicine (202006GD-LL)

Inclusion criteria and exclusion criteria

Inclusion criteria: (1) all patients have no contraindications to CT angiography, such as pregnancy and iodine allergy; (2) all meet CT enhanced scanning, angiography, and iodine contrast extravasation; (3) good compliance; (4) no history of allergy to therapeutic drugs.

Exclusion criteria: (1) skin infection; (2) systemic infectious diseases; (3) serious lesions or functional abnormalities in systemic vital organs; (4) phlebitis caused by other drugs; (5) peripheral vascular diseases; (6) mental illness or consciousness disorders.

Treatment Method

A method of simple compound dexamethasone acetate cream was applied to the control group, specifically including, mix 10 mg compound

dexamethasone acetate cream (Guangdong Taenkang Pharmaceutical Factory Co., LTD., H44024369, specification 20 g: 15 mg / branch) with 20 mL isotonic saline, fully soak 5 cm × 7 cm sterile gauze, and extract the gauze at the local extravasation of the patient, continuous external application, change once in two hours for continuous treatment for two weeks. All patients were examined with a third-generation dual-source DECT scanner (SOMATOM Force; Siemens Healthineers). DECT images were analyzed using commercially available software (syngo. via, version VB40A; Siemens Healthineers). The contrast agent used was Ioversol Injection (Jiangsu Hengrui Pharmaceuticals Co., Ltd., approval number: H20113430)

The observation group was treated with compound dexamethasone acetate cream combined with massage, specifically including, patients take the sitting position or supine position, place the affected side limb flat on the table surface, disinfection the needle eye outlet and cover with sterile application, apply Euler gel to the extravasation swelling, the nursing staff holds the affected side limb with his left hand, right-hand grip proximal to the extravasation site, push swelling fluid vigorously to the proximocardial end, make the subcutaneous swelling effusion push, wrinkled skin on the swelling, the epidermis turns red, patients experience pain during massage, the epidermis color returned to normal after the massage, stop when massage to the subcutaneous swelling effusion spread, for about 1-3 minutes, the number of massage is 1-2 times according to the degree of effusion dispersion. Then, compound dexamethasone acetate cream was applied in the same low temperature as the control group.

Observational indicators

(1) Comparison of clinical efficacy of the two groups: evaluation of clinical efficacy according to the *Clinical disease diagnosis basis and the cure and improvement standard* ⁽¹⁰⁾; 1) obvious effect: edema, pain and blood stasis disappear after 24 hours after treatment; 2) effective: edema, pain and blood stasis are reduced, and the scope is significantly narrowed after 48 hours after treatment; 3) Ineffectiveness: clinical symptoms are not significantly relieved or even aggravated after 48 hours. Clinical efficiency = (obvious effect+ effective) / total cases×100%.

(2) Comparison of swelling and pain degree between the two groups: observation and record of the patient swelling and pain regression time, and compare the limb swelling value of the two groups before and after treatment. Soft ruler was used to measure the perimeter diameter of the extravasation limb and the healthy side limb, and the limb swelling value = the perimeter of the affected limb - the perimeter of the healthy side.

(3) Comparison of complications in the two

groups: local tissue necrosis, vascular and nerve injury, and venous thrombosis in the two groups were observed and recorded.

Statistical analysis

The data were analyzed by Statistic Package for Social Science (SPSS) 22.0 statistical software (IBM, Armonk, NY, USA). The measurement data with normal distribution is indicated as mean \pm standard deviation ($\bar{x} \pm s$), t-test is used for group comparison; count data as cases (n) or percentage (%), and χ^2 test is aimed for data comparison. There was significant difference when $P < 0.05$.

RESULTS

General Information

The age, sex, Body Mass Index, (BMI) and scanning site of the two groups were not statistically significant ($P > 0.05$), which were comparable. See table 1.

Table 1. Comparison of general data between the two groups.

| Group | Control Group (n = 30) | Observation group (n = 30) | t/ χ^2 | P |
|--------------------------|---------------------------|-------------------------------|-------------|-------|
| age (year) | 47.84 \pm 4.26 | 47.87 \pm 4.42 | 1.252 | 0.162 |
| sex | male | 16 | 1.207 | 0.328 |
| | female | 14 | | |
| BMI (kg/m ²) | 20.84 \pm 2.36 | 20.34 \pm 2.64 | 0.874 | 0.312 |
| Scanning site | head | 11 | 0.873 | 0.687 |
| | abdomen | 11 | | |
| | pelvic cavity | 8 | | |

Comparison of the clinical efficacy between the two groups

The therapeutic effect is shown in figure 1. The clinical response rate (93.33%) was considerably higher than that of the control group (86.67%), and the difference was statistically significant ($P < 0.05$). See table 2 and figure 2.

Table 1. Comparison of general data between the two groups.

| Efficacy | Control group (n=30) | Observation group (n=30) | χ^2 | P |
|------------------------|-------------------------|-----------------------------|----------|-------|
| Obvious effect | 18 | 22 | - | - |
| effective | 8 | 6 | - | - |
| ineffective | 4 | 2 | - | - |
| Clinical effectiveness | 26 (86.67%) | 28 (93.33%) | 10.953 | 0.000 |

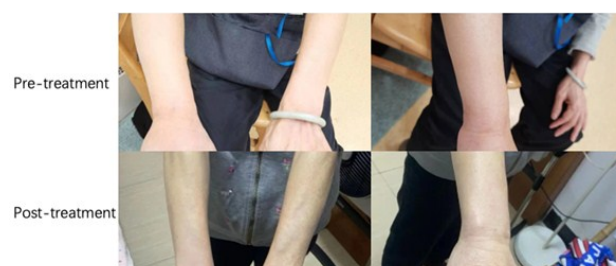

Figure 1. Comparison Pre-treatment and Post-treatment.

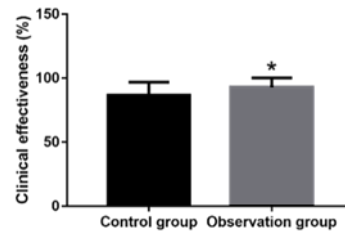


Figure 2. Comparison of clinical efficacy between the two groups.

Comparison of swelling and pain degree between the two groups

The limb swelling value, red swelling regression time and pain regression time were considerably less than those of the control group, and the difference was considered to be statistically significant ($P < 0.05$). See table 3 and figure 3.

Table 3. Comparison of the degree of swelling and pain between the two groups.

| | Control group (n=30) | Observation group (n=30) | t | P |
|-------------------------------------|-------------------------|-----------------------------|--------|-------|
| limb swelling value (cm) | 1.12 \pm 0.13 | 0.23 \pm 0.12 | 9.263 | 0.001 |
| red swelling regression time (h) | 33.61 \pm 4.15 | 26.37 \pm 2.73 | 10.215 | 0.000 |
| pain regression time (h) | 35.08 \pm 3.25 | 27.84 \pm 3.39 | 10.864 | 0.000 |

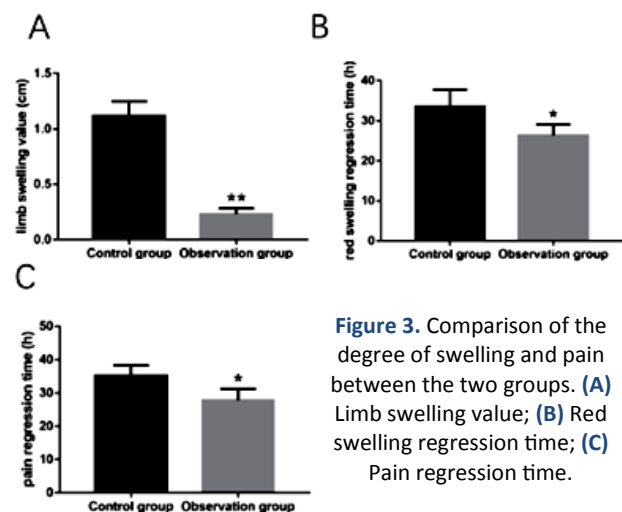


Figure 3. Comparison of the degree of swelling and pain between the two groups. (A) Limb swelling value; (B) Red swelling regression time; (C) Pain regression time.

Comparison of the occurrence of complications between the two groups

The complication rate (3.33%) was significantly lower than the control group (13.33%), and the difference was statistically significant ($P < 0.05$). See table 4 and figure 4.

Table 4. Comparison of complications between the two groups.

| | Control group (n=30) | Observation group (n=30) | χ^2 | P |
|---------------------------------------|-------------------------|-----------------------------|----------|-------|
| Local tissue necrosis | 1 | 0 | | |
| Vascular nerve injury | 0 | 0 | | |
| venous thrombus | 3 | 1 | | |
| The incidence of complications (%) | 4 (13.33%) | 1 (3.33%) | 10.895 | 0.000 |

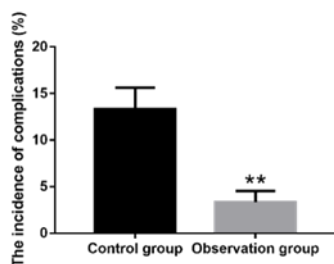


Figure 4. Comparison of complications between the two groups.

DISCUSSION

Iodine contrast agent extravasation refers to the infiltration of iodine contrast agent into the subcutaneous vascular space ⁽¹¹⁾ due to high pressure trocar sliding or blood vessel rupture caused by the contrast agent after injection. A large number of extravasated iodine contrast will directly compress the surrounding tissues, plus the anatomical specificity of the injection site (often selected upper limb vessels), the contrast will enter the muscle interval and deep fascia, causing arterioles closure, muscle blood supply, muscle and tissue ischemia, leading to osteocompartment syndrome ^(12,13). In addition, contrast extravasation can also cause chemical damage of tissue cells, its high osmotic pressure makes cell fluid through transmembrane movement into the tissue space, because cell water loss, tissue edema ⁽¹⁴⁾, and iodine contrast ion contrast agent can also directly destroy cell membrane ion pump, affect the normal cell metabolism, further aggravate cytotoxicity and tissue edema ⁽¹⁵⁾. Therefore, effective treatment is given during the extravasation of iodine contrast agent, thus avoiding or reducing the risk of serious complications.

Compound dexamethasone acetate cream is a kind of glucocorticoid commonly used in clinical practice, which can be applied for allergic and autoimmune inflammatory diseases, such as localized pruritus, neurodermatitis, neurodermatitis, contact dermatitis, seborrheic dermatitis, chronic eczema and other treatments, and has anti-inflammatory, anti-virus, anti-allergy and other effects ⁽¹⁶⁾. Massage plays the vital role in accelerating blood circulation and removing blood stasis, functioning as the key to keep the swelling down and relieve the pain. The results of Chen ⁽¹⁷⁾ study showed that the extravasation with Lidocaine and dexamethasone could promote the disappearance of redness, relieve pain and have ideal nursing effect. Moreover, the limb swelling value and pain score of lidocaine and dexamethasone were lower than that of the routine group; the resolution time of redness was shorter than that in the conventional group. Chun and other studies ⁽¹⁸⁾ showed that the extravasation of patients with iodine contrast agent using massage method is faster and better than magnesium sulfate wet application effect, and the operation is simple, which

is worth promoting clinically, and the time of swelling and pain in the massage group were earlier than those in the external application one. It was indicated by the study that the clinical response rate (93.33%) was much higher than the control group (86.67%), the limb swelling, swelling and pain regression time were much less than the control group, indicating that the clinical effect of compound dexamethasone acetate cream and massage for iodine extravasation is able to effectively ameliorate the clinical symptoms such as limb swelling, tissue swelling and pain, consistent with the above study conclusion. Analysis of the reason is that compound dexamethasone acetate cream local wet compress can prevent lysosomal and inflammatory, sensitization, painful substance release, has anti-inflammatory, immunosuppression effect, and has a repair effect on local vascular endothelium, by increasing vascular tension, reduce capillary permeability, to reduce fluid exudation, reduce tissue local congestion, eventually play the role of tissue repair, regression edema; massage technique, by pushing away the extravasation iodine contrast agent, can quickly relieve the swelling and pain of the extravasation site, playing the role of accelerating blood circulation, removing blood stasis, keeping swelling down and relieving pain. In addition, the use of skin surface pressure and friction heat generated in massage can help restore the skin vascular elasticity, improve local lymphatic circulation and vascular permeability, and also help to increase the drug absorption area, promote the tissue space accumulation of iodine contrast agent to be absorbed by the tissue, accelerate its metabolism, reduce edema. The combination of the two can play a synergistic role and further improve the treatment effect.

Iodine contrast agent has a large viscosity and a fast flow rate, which is easy to lead to various adverse reactions, no effective treatment intervention after extravasation can cause vascular damage and perivascular basal tissue hyperplasia, thus leading to blood vessel thickening, hardening, vascular lumen narrowing and blockage, causing venous thrombosis, local tissue necrosis and other complications. Hui *et al.* ⁽¹⁹⁾ found that Yunnan combined with dexamethasone external application for the medical treatment of contrast agent is the effective improvement of the symptoms in skin swelling and pain of the extravasation site, combining nursing intervention has positive significance to shorten hospitalization and reduce the occurrence of phlebitis, with high safety. She and other ⁽²⁰⁾ research found that the use of massage can effectively improve the symptoms of iodine contrast extravasation, significantly reduce the pain of patients, as convenient and effective treatment means, and help to promote the recovery of body tissue, reduce patients' heart and physical damage, and reduce the risk of complications. What could be shown by the

study is that the complication rate (3.33%) of the observation group was significantly lower than that of the control group (13.33%), indicating the obvious clinical effect and high safety of compound dexamethasone acetate cream and massage for iodine contrast extravasation, which helped to cut down the risk of complications, refining the prognosis of patients. This study is consistent with the conclusions mentioned above. The reason is that compound dexamethasone acetate cream can increase vascular tone and reduce capillary permeability; massage can restore skin blood vessels and improve local lymphatic circulation and vascular permeability. The combination of the two can further improve vascular blockage and inflammation, thus reducing the risk of vascular complications.

In conclusion, the clinical effect of compound dexamethasone acetate cream and massage for iodine contrast extravasation is remarkable, which can effectively alleviate the clinical symptoms such as limb swelling and pain, decreasing the risk of vascular related complications, with high safety and high clinical promotion value.

Conflict of Interests: The authors declared no conflict of interest.

Funding: This study did not receive any funding in any form.

REFERENCES

1. Lai LY, Tan P, Jiang Y, et al. (2022) Dual-layer spectral detector CT for contrast agent concentration, dose and injection rate reduction: Utility in imaging of the superior mesenteric artery. *European Journal of Radiology*, **150**: 110246.
2. Shigematsu S, Oda S, Sakabe D, et al. (2022) Practical Preventive Strategies for Extravasation of Contrast Media During CT: What the Radiology Team Should Do. *Academic Radiology*, **29**(10): 1555-1559.
3. Hammerschlag J, Hershkovitz Y, Ashkenazi I, et al. (2022) Angiography in patients with pelvic fractures and contrast extravasation on CT following high-energy trauma. *European Journal of Trauma and Emergency Surgery*, **48**(3): 1939-1944.
4. Yamagishi T, Kashiura M, Shindo Y, et al. (2021) Effectiveness of endoscopic hemostasis in preventing diverticular bleeding with extravasation detected by contrast-enhanced computed tomography: A single-center retrospective cohort study. *Medicine*, **100**(8): e24736.
5. Huang Z, Hu F, Liu H, Wang M (2022) A retrospective study to compare the effects of methylprednisolone and dexamethasone in 35 patients with anaphylactic shock due to iodinated contrast media during cardiac catheterization. *Medical Science Monitor*, **28**: e934703.
6. Hoang VT, Hoang TH, Trinh CT, Hoang NT (2023) Contrast agent extravasation in external jugular vein. *American Journal of Emergency Medicine*, **69**: 203-204.
7. Morita S, Koizumi J, Sakurai K, et al. (2009) A typical extravasation of contrast medium in massive extrapleural haematoma due to cardiac massage without rib fracture. *Emergency Medicine Journal*, **26**(10): 710.
8. Liu R, Hua S, Wei C, et al. (2023) T1 mapping for differentiating of haemorrhagic transformation from extravasation of iodine contrast agents: A phantom study. *Jcpssp-Journal of the College of Physicians and Surgeons Pakistan*, **33**(7): 742-747.
9. Cooley MB, Wulfstange WJ, Wegierak D, et al. (2023) Real-time imaging of nanobubble ultrasound contrast agent flow, extravasation, and diffusion through an extracellular matrix using a microfluidic model. *Lab On a Chip*, **23**(15): 3453-3466.
10. Hammerschlag J, Hershkovitz Y, Ashkenazi I, et al. (2022) Angiography in patients with pelvic fractures and contrast extravasation on CT following high-energy trauma. *European J Trauma and Emergency Surgery*, **48**(3): 1939-1944.
11. Sonis JD, Gottumukkala RV, Glover MT, et al. (2018) Implications of iodinated contrast media extravasation in the emergency department. *American Journal of Emergency Medicine*, **36**(2): 294-296.
12. Papatheodorou N, Keskinis A, Georgoulas P, et al. (2022) Hand compartment syndrome due to extravasation of contrast medium. A technical error. A report of a case and review of the literature. *J Surgical Case Reports*, **2022**(3): rjac054.
13. Taydas O, Ogul H, Ozcan H, Kantarci M (2018) Gadolinium-Based Contrast Agent Extravasation Mimicking Subarachnoid Hemorrhage After Electroconvulsive Therapy. *World Neurosurgery*, **114**: 130-133.
14. Kamupira SR, Tarr JD and Kuruvilla M (2022) Contrast study in umbilical venous line extravasation. *Archives of Disease in Childhood-Fetal and Neonatal Edition*, **107**(2): 120.
15. Xu T, Wang Y, Yuan J, et al. (2021) Contrast extravasation and outcome of endovascular therapy in acute ischaemic stroke: a systematic review and meta-analysis. *Bmj Open*, **11**(7): e044917.
16. Notani N, Miyazaki M, Kanezaki S, et al. (2021) The fibrinogen levels on admission is a predictive marker of the contrast extravasation on enhanced computed tomography in sacral fracture. *Medicine*, **100**(10): e25056.
17. Al-Jabbari E, Shroff N, Khan H, et al. (2022) Peritoneal vaginal fistula and contrast extravasation during MRI. *Radiol Case Rep*, **17**(10): 3731-3734.
18. Gupta IJ, Ghosh A, Yadav J, et al. (2023) External beam radiotherapy interdigitated with high dose rate (HDR) intracavitary brachytherapy versus external beam radiotherapy followed by sequential HDR Intracavitary Brachytherapy for Locally Advanced Carcinoma Cervix-Randomized Control Study. *Asian Pac J Cancer Prev*, **24**(10): 3441-3445.
19. Liu W, Wang P, Zhu H, et al. (2023) Contrast media extravasation injury: a prospective observational cohort study. *European J Medical Research*, **28**(1): 458.
20. Diop B, Soh GT, Nde A, et al. (2022) Hand compartment syndrome secondary to contrast media extravasation: A case report. *Int J Surgery Case Reports*, **98**: 107595.

