

Diagnostic value of head and neck computed tomography angiography in combination with color Doppler ultrasonography in carotid artery stenosis in ischemic stroke patients

H. Liu¹, Z. Zhao¹, H. Xu¹, W. Chen¹, Q. Lu², X. Chen^{1*}

¹Department of Radiology, The Affiliated Huai'an Hospital of Xuzhou Medical University, Huai'an 223001, Jiangsu, China

²Department Ultrasound Medicine, The Affiliated Huai'an Hospital of Xuzhou Medical University, Huai'an 223001, Jiangsu, China

ABSTRACT

► Original article

*Corresponding author:

Xiaoyu Chen, Ph.D.,

E-mail: lhy59202023@163.com

Received: December 2023

Final revised: January 2024

Accepted: February 2024

Int. J. Radiat. Res., October 2024;
22(4): 869-873

DOI: 10.61186/ijrr.22.4.869

Keywords: ischemic stroke, computed tomography angiography, color Doppler ultrasonography, carotid artery stenosis.

Background: To investigate the diagnostic value of head and neck computed tomography angiography (CTA) in combination with color Doppler ultrasonography (CDUS) in carotid artery stenosis in ischemic stroke (IS) patients. **Materials and Methods:** DSA examination was performed on all patients, and they were separated into mild group, moderate group, as well as severe group (n=30) according to the degree of vascular stenosis. Head and neck CTA and CDUS were used to examine the plaque length, thickness, and quantity of each group. The total plaque area, carotid intima-media thickness (IMT), common carotid artery index (CCA), internal carotid artery index (ICA) as well as vertebral artery index (VA) were compared. **Results:** A total of 110 narrow blood vessels were detected by CTA combined with ultrasound, and had a higher accuracy rate. The total plaque area, length, thickness and number of plaques, the values of CCA, ICA and VA, and IMT in the moderate together with severe groups presented higher relative to the mild group, and those in severe group presented elevated relative to the moderate group ($P < 0.05$). The sensitivity, specificity and accuracy of the combined detection of head and neck CTA and CDUS in the diagnosis of vascular stenosis in IS patients were higher relative to the single detection ($P < 0.05$). **Conclusion:** Head and neck CT angiography in combination with CDUS has a high application value in detecting carotid artery stenosis in IS patients, and provides an important reference value for the formulation of the next treatment plan and the assessment of patient prognosis.

INTRODUCTION

Ischemic stroke (IS) is a cerebrovascular disease that endemic in people ≥ 40 years of age in China and usually ischemic from the lumen ⁽¹⁾. Proximal cerebral artery blockage can lead to local severe ischemia, resulting in cell energy metabolism failure, and cell necrosis can occur within a few minutes ⁽²⁾. Meanwhile, the infarct center can be surrounded by the surrounding ischemic area, forming a penumbra, and neuron apoptosis can occur within a few hours ⁽³⁾. Since IS possesses a high risk of disability and death, early diagnosis as well as appropriate treatment are of great significance for patients to obtain a good prognosis ⁽⁴⁾. The therapeutic methods of IS are drug thrombolysis or mechanical thrombolysis ⁽⁵⁾. The accurate identification of the infarct site and the degree of arterial stenosis (AS) by imaging technology are the important conditions of IS treatment ⁽⁶⁾.

Digital subtraction angiography (DSA) has been

considered to be the gold standard for judging AS for a long time, which can rotate cerebral arteries in three dimensional ways and clearly display the shape and position of intra-arterial plaque, thus providing a high reliability in the diagnosis of AS ⁽⁷⁾. However, DSA is a traumatic examination method, which can cause trauma to patients during the examination and the examination operation is difficult, and contrast agent is required during the examination, which is difficult for most patients to accept, so its clinical application is limited ⁽⁸⁾. In recent years, non-invasive imaging techniques containing head and neck computed tomography angiography (CTA) as well as transcranial color Doppler ultrasonography (CDUS) have been used in the diagnosis of AIS ^(9,10). Head and neck CTA can clearly present the structure of carotid artery and cerebral artery, which can help doctors make judgment on AS ⁽¹¹⁾. Transcranial CDUS can reflect the level of AS and cerebral blood flow and has the advantages of simple operation and strong repeatability ⁽¹²⁾.

Therefore, our study planned to explore the diagnostic value of head and neck CTA in combination with CDUS in carotid AS in patients with IS. Head and neck CT angiography combined with CDUS can improve the specificity and accuracy of diagnosis for IS patients, reduce the economic pressure on patients and society, and provide important reference value for the formulation of next treatment plans and the evaluation of patient prognosis.

MATERIALS AND METHODS

General data

Ninety patients with IS admitted to our hospital from January 2021 to December 2022 were selected. DSA examination was performed on all patients, and they were separated into mild group (30 cases), moderate group (30 cases) as well as severe group (30 cases) according to the degree of vascular stenosis (table 1). Mild group: 16 males and 14 females, ranging in age from 40 to 73 years, with an average age of (62.32 ± 6.18) years. Moderate group: 15 males and 15 females, ranging in age from 41 to 75 years, with an average age of (62.38 ± 5.98) years. Severe group: 17 males and 13 females, ranging in age from 41 to 74 years, with an average age of (62.48 ± 6.23) years. No significant difference was observed in baseline data among the three groups ($P > 0.05$) and there was comparability among the groups. All patients signed informed consent forms.

Inclusion criteria: 1) The diagnostic criteria for IS in the Chinese Guidelines for the Diagnosis and Treatment of Acute Ischemic Stroke: 2) First onset: 3) There was no contraindication of relevant contrast agents. Exclusion criteria: 1) Combined with hypertension or other cerebrovascular diseases: 2) Combined with atrial fibrillation: 3) Combined with autoimmune disease: 4) Complicated with abnormal liver and kidney function; 5) Consciousness disorder in patients with mental illness.

Table 1. The demographic information of IS patients.

	IS patients (n=90)		
Group	mild (n=30)	moderate (n=30)	severe (n=30)
Sex (n)			
male	16	15	17
female	14	15	13
Age (range)	62.32±6.18	62.38±5.98	62.48±6.23

Methods

DSA examination

DSA was examined by Artis-zee angiography machine (Siemens, Germany). The patient was placed in supine position and disinfected with routine iodophor under local anesthesia. The right femoral artery was punctured by modified Seldinger technique⁽¹³⁾, the 5F artery sheath was inserted, and

2 ml of contrast agent was injected. After no abnormality was observed, 3 500 U heparin was injected into the arterial sheath before operation, and total cerebrovascular angiography was performed. A 5F pigtail catheter super-smooth guide wire was used to gently enter the aortic arch, and aortic arch and superior aortic arch vessels were observed by contrast iohexol angiography. The right carotid artery system, the right vertebral artery system, the left vertebral artery system, and the left carotid artery system were compared by a single curved catheter guided by the super-slippy guide wire. After imaging, the single curved catheter was removed. The patient was checked for clarity of speech, normal limb movement, stable blood pressure, and returned to the ward. The image was digitized and subtracted to obtain the final image.

CTA examination

Head and neck CTA scan was performed with 320-slice CT (Toshiba Aquilion One, Japan), first with plain scan followed by enhanced head and neck CTA scan. First, plain scan was performed for the patient, followed by enhanced CTA scan for the head and neck, extending from the patient's ascending aorta to the cranial roof. Iopproxamine (non-ionic contrast agent) with a concentration of 370 mg I/ mL was injected into the patient's anterior cubital vein at a flow rate of 4.00 mL /s. A total of 80 mL was injected, and the patient was injected with 0.9% sodium chloride solution 30 mL at the same flow rate for tube flushing. CTA enhancement scan: Sure Start contrast tracer was used to scan patients. Ascending aorta was used as the ROI trigger point, and the trigger threshold was set at 200 HU. The tube voltage and tube current were set to 120 kVp and 250 mA respectively, the layer thickness was 3 mm and the layer spacing was 3 mm. After the scan, the data was uploaded to the workstation for volume display, multi-plane reconstruction, maximum brightness projection, etc., and the stenosis rate was calculated.

Transcranial CDUS

The DWIQL Doppler ultrasound instrument produced by Epiq7c (Philips, Netherlands) was selected. The patient was placed in a supine reclining position with full exposure to the neck. The thickness of carotid intima-media and the presence of plaque were observed. For those with plaque, the location and nature of plaque were observed and recorded.

Evaluation criteria for carotid AS

According to the relevant NASCET standards, the narrowest location diameter/distal normal artery diameter $\times 100\%$ was taken as the degree of stenosis, and the stenosis rate $< 50\%$ was considered as mild stenosis. The stenosis rate of 50% to 69% was moderate stenosis. The stenosis rate of 70% ~ 99% was severe stenosis. The stenosis rate was 100%

carotid artery occlusion.

Observation indicators

The plaque length, plaque thickness and plaque quantity of each group were observed and the total plaque area, carotid intima-media thickness (IMT), common carotid artery index (CCA), internal carotid artery index (ICA) along with vertebral artery index (VA) were compared. The imaging features of carotid plaque color Doppler flow imaging (CDFI) and head and neck CTA were observed to assess the efficacy of carotid plaque CDFI combined with head and neck CTA in the diagnosis of carotid artery stenosis in IS patients.

Statistical analysis

The computation of statistics was carried out using SPSS 22.0 software, and the data were analyzed normally first, and all the data were in accordance with normal distribution and exhibited as ($x \pm s$) and ANOVA and LSD-t test were adopted for comparison. The count data was presented as n (%) and χ^2 test was performed for comparison. Statistics were deemed meaningful if $P < 0.05$.

RESULTS

Detection of carotid artery stenosis

In this study, carotid plaque CDFI, head and neck CTA, combination examination, and DSA were used to detect the number and degree of narrow blood vessels in patients. In 90 patients, DSA showed 115 narrow blood vessels, ultrasound showed 91 narrow blood vessels and CTA showed 101 narrow blood vessels. A total of 110 narrow blood vessels were detected by CTA combined with ultrasound, as shown in table 2.

Table 2. Detection of carotid artery stenosis.

Detection method	Narrow blood vessels	Degree of coronary artery stenosis $\geq 70\%$	Degree of coronary artery stenosis $< 70\%$
Carotid plaque CDFI	91	51	40
Head and neck CTA	101	60	41
Combination examination	110	66	44
DSA	115	69	46

CDFI: Color Doppler flow imaging; CTA: Computed tomography angiography; DSA: Digital subtraction angiography.

Comparison of total plaque area and IMT among 3 groups

We divided patients into mild, moderate and severe groups according to the degree of vascular stenosis and then compared the total plaque area and IMT of the three groups. Figure 1 displayed that the total plaque area and IMT in the moderate together with severe groups presented higher relative to the mild group, and those in severe group presented

elevated when comparing to the moderate group ($P < 0.05$).

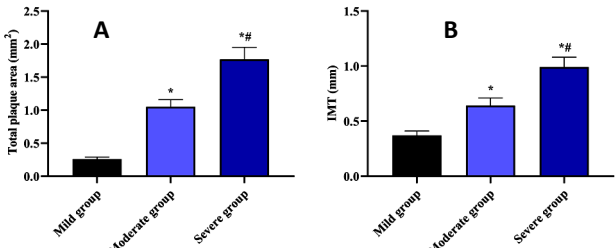


Figure 1. Comparison of total plaque area and IMT among 3 groups. **A)** Comparison of total plaque area among mild, moderate, and severe groups. **B)** Comparison of IMT among 3 groups. * $P < 0.05$, compared with mild group. # $P < 0.05$, compared with moderate group.

Comparison of length, thickness as well as numbers of plaques among 3 groups

We compared the length, thickness as well as numbers of plaques of the three groups. Figure 2 revealed that the length, thickness and number of plaques in the moderate together with severe groups presented higher relative to the mild group, and those in the severe group presented elevated when comparing to the moderate group ($P < 0.05$).

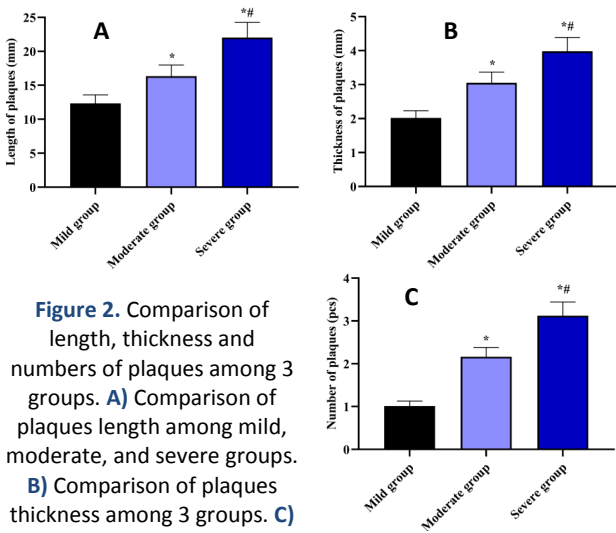


Figure 2. Comparison of length, thickness and numbers of plaques among 3 groups. **A)** Comparison of plaques length among mild, moderate, and severe groups. **B)** Comparison of plaques thickness among 3 groups. **C)** Comparison of plaques numbers among 3 groups. * $P < 0.05$, compared with mild group. # $P < 0.05$, compared with moderate group.

Comparison of CCA, ICA as well as VA among 3 groups

We compared the CCA, ICA as well as VA of the three groups. Figure 3 revealed that CCA, ICA and VA in the moderate together with severe groups presented higher relative to the mild group and those in the severe group presented elevated when comparing to the moderate group ($P < 0.05$).

Diagnostic efficacy of CDUS, head and neck CTA and their combined detection for vascular stenosis in IS

Accuracy of using carotid plaque CDFI, head and neck CTA and combination examination to detect

vascular stenosis in IS patients. The sensitivity, specificity and accuracy of the combined detection of head and neck CTA and CDUS in the diagnosis of vascular stenosis in IS patients were higher relative to the single detection ($P < 0.05$) (table 3).

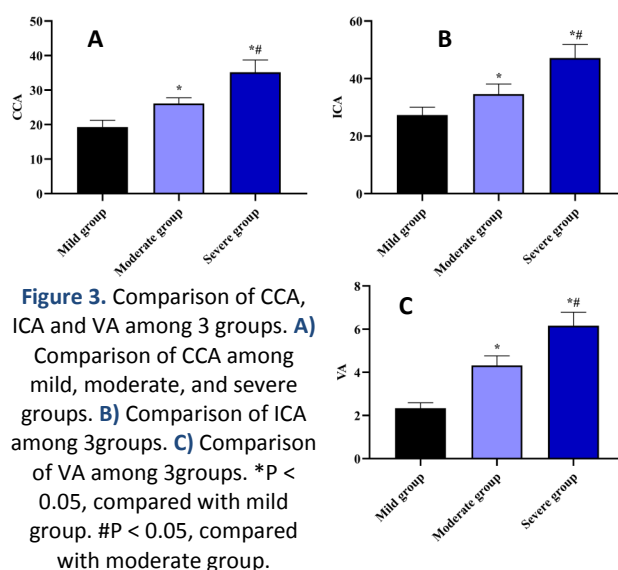


Figure 3. Comparison of CCA, ICA and VA among 3 groups. **A)** Comparison of CCA among mild, moderate, and severe groups. **B)** Comparison of ICA among 3 groups. **C)** Comparison of VA among 3 groups. * $P < 0.05$, compared with mild group. # $P < 0.05$, compared with moderate group.

Table 3. Diagnostic efficacy of CDUS, head and neck CTA and their combined detection for vascular stenosis in IS.

Detection method	Sensitivity	Specificity	Accuracy
Carotid plaque CDFI	73.91% (51/69)	86.96% (40/46)	79.13% (91/115)
Head and neck CTA	86.96% (60/69)	91.30% (42/46)	87.83% (101/115)
Combination examination	95.65% (66/69)	97.83% (45/46)	95.65% (110/115)

IS: Ischemic stroke, CDFI: Color Doppler flow imaging, CTA: Computed tomography angiography.

DISCUSSION

Lack of blood supply to the brain belongs to the main characteristic of IS patients ⁽¹⁴⁾. Studies have shown that lack of blood supply to the brain is related to the lesions of blood supply arteries ⁽¹⁵⁾. As an important extracranial blood supply artery, if the occurrence of IS is accompanied by carotid artery stenosis or carotid artery occlusion, with the deepening of carotid artery stenosis, the blood supply to the brain will become more insufficient, thus aggravating the patient's condition and symptoms ⁽¹⁶⁾. It can be seen that carotid artery stenosis in IS patients may be both the cause and the accomplice, which will seriously affect the life health and prognosis of patients ⁽¹⁷⁾. Therefore, it is of great significance to determine the AS degree of IS patients through imaging techniques for their early diagnosis and treatment.

DSA can clearly present the degree of AS and distortion with contrast media, which is a reliable technique for the diagnosis of AIS ⁽¹⁸⁾. However, it is an invasive operation and may cause complications of nerve defects, so this examination method should

not be the first choice ⁽¹⁹⁾. Therefore, non-invasive and effective examination methods should be explored to diagnose AIS. In recent years, head and neck imaging methods such as CTA and transcranial CDUS have been used in clinic because of their advantages of non-invasive, convenient operation and low cost ^(20,21). CTA is a contrast agent injected into the elbow. By observing the flow of CTA, the blood flow filling degree in the blood vessel and the difference between the blood vessel walls can be determined ⁽²²⁾. At the same time, aided by three-dimensional reconstruction technology, the inner wall of the lumen can be three-dimensionally presented and it is helpful to understand the size and nature of the plaques, so AS to determine the degree of AS in IS patients ⁽²³⁾. Transcranial CDUS is an imaging method to determine the condition of blood vessels by detecting hemodynamic changes ⁽²⁴⁾. It can evaluate whether there is plaque in the wall of the tube and its status by combining the internal diameter of the artery and the condition of blood flow filling and then help physicians to judge the degree of AS in patients ⁽²⁵⁾. Therefore, in this study, head and neck CT angiography combined with CDUS was used to detect arterial stenosis in 90 patients with IS to improve the accuracy of the examination.

We first divided the patients into mild, moderate and severe groups. It could be seen from the results of this paper that ultrasound showed 91 narrow blood vessels and CTA showed 101 narrow blood vessels. A total of 110 narrow blood vessels were detected by CTA combined with ultrasound and was closer to the results of DSA and had a higher accuracy rate. Consistently, M Anzidei *et al.* have discovered that CTA is the most accurate technique for evaluating carotid stenoses, with a greater accuracy than CDUS ⁽²⁶⁾. Both CTA and DSA are processed by computer after angiography, and the obtained vascular imaging information is clear and comprehensive, which can better reflect vascular stenosis, obstruction and other lesions ⁽²⁷⁾. Therefore, the diagnostic effect of CTA is similar to that of DSA. Studies have shown that Transcranial CDUS uses two-dimensional ultrasound images to reflect blood flow rate, vascular inner diameter, intima thickness and whether there is plaque in the blood vessels and then indirectly determines AS conditions, so it is not as direct and accurate as CTA ⁽²⁸⁾. In our study, the sensitivity, specificity and accuracy of the combined detection of head and neck CTA and CDUS in the diagnosis of vascular stenosis in IS patients were higher relative to the single detection. Therefore, we indicated that the detection of CTA combined with CDUS can accurately reflect whether there is plaque in the blood vessels, the location of plaque and various indicators.

CONCLUSION

In summary, head and neck CT angiography in

combination with CDUS has a high application value in detecting carotid artery stenosis in IS patients and provides an important reference value for the formulation of the next treatment plan and the assessment of patient prognosis.

ACKNOWLEDGMENT

Not applicable.

Conflicts of interest: The authors declare that they have no conflicts of interest.

Funding: This work was not supported by any funds.

Ethical approval: The present study adhered to ethical norms set forth by the institutional and/or national research committee, the Helsinki Declaration and its subsequent revisions, or equivalent standards of care in all procedures involving human subjects. The Affiliated Huai'an Hospital of Xuzhou Medical University granted approval for all subjects (LL-H22010).

Author contribution: X.C. conceived and designed the experiments. H.L. and Z.Z. contributed significantly to the experiments and arranging data. H.X., W.C., and Q.L. performed data analyses. H.L. wrote the draft manuscript. X.C. revised the manuscript. All authors read and approved the final manuscript.

REFERENCES

1. Feske SK (2021) Ischemic Stroke. *Am J Med*, **134**(12): 1457-1464.
2. Herpich F and F Rincon (2020) Management of Acute Ischemic Stroke. *Crit Care Med*, **48**(11): 1654-1663.
3. Walter K (2022) What Is Acute Ischemic Stroke? *Jama*, **327**(9): 885.
4. Jolugbo P and RAS Ariëns (2021) Thrombus Composition and Efficacy of Thrombolysis and Thrombectomy in Acute Ischemic Stroke. *Stroke*, **52**(3): 1131-1142.
5. Mendelson SJ and S Prabhakaran (2021) Diagnosis and Management of Transient Ischemic Attack and Acute Ischemic Stroke: A Review. *Jama*, **325**(11): 1088-1098.
6. Van Dam-Nolen DHK, MTB Truijman, AG van der Kolk, MI Liem, F Schreuder, E Boersma, et al. (2022) Carotid Plaque Characteristics Predict Recurrent Ischemic Stroke and TIA: The PARISK (Plaque At Risk) Study. *JACC Cardiovasc Imaging*, **15**(10): 1715-1726.
7. Zhang J, L Wang, Y Chen, S Wang and L Cui (2022) Non-invasive Detection of Diffuse Intracranial Vertebrobasilar Artery Stenosis: A Prospective Comparison with Digital Subtraction Angiography. *Ultrasound Med Biol*, **48**(3): 554-564.
8. Ozpar R, Y Dinc, OF Nas, MF Inecikli, M Parlak and B Hakyemez (2023) Arterial transit artifacts observed on arterial spin labeling perfusion imaging of carotid artery stenosis patients: What are counterparts on symptomatology, dynamic susceptibility contrast perfusion, and digital subtraction angiography? *J Neuroradiol*, **50**(4): 407-414.
9. Wang D, Z Li, X Zheng, H Cong, T Zhang, Z Wang, et al. (2020) Head and neck CT angiography to assess the internal carotid artery stealing pathway. *BMC Neurol*, **20**(1): 334.
10. Liu S, ZL Huang, YR Sun, L Liu, H Qi and LY Wei (2023) Application value of transcranial contrast-enhanced ultrasonography in evaluating middle cerebral artery stenosis. *Eur Rev Med Pharmacol Sci*, **27**(1): 224-232.
11. Yang Y, X Huan, D Guo, X Wang, S Niu and K Li (2023) Performance of deep learning-based autodetection of arterial stenosis on head and neck CT angiography: an independent external validation study. *Radiol Med*, **128**(9): 1103-1115.
12. Kocur D, P Paździora, J Baron and A Rudnik (2020) Role of transcranial Doppler ultrasonography in assessing stenosis after flow diversion. *Clin Neurol Neurosurg*, **198**: 106219.
13. Krause U, T Kroencke, E Spielhauer, M Taupitz, W Kenn, B Hamm, et al. (2005) Contrast-enhanced magnetic resonance angiography of the lower extremities: standard-dose vs. high-dose gadodiamide injection. *J Magn Reson Imaging*, **21**(4): 449-454.
14. Silva GS and RG Nogueira (2020) Endovascular Treatment of Acute Ischemic Stroke. *Continuum (Minneapolis)*, **26**(2): 310-331.
15. Rabinstein AA (2020) Update on Treatment of Acute Ischemic Stroke. *Continuum (Minneapolis)*, **26**(2): 268-286.
16. Renú A, M Millán, L San Román, J Blasco, J Martí-Fàbregas, M Terceño, et al. (2022) Effect of Intra-arterial Alteplase vs Placebo Following Successful Thrombectomy on Functional Outcomes in Patients With Large Vessel Occlusion Acute Ischemic Stroke: The CHOICE Randomized Clinical Trial. *Jama*, **327**(9): 826-835.
17. Heck D and A Jost (2021) Carotid stenosis, stroke, and carotid artery revascularization. *Prog Cardiovasc Dis*, **65**: 49-54.
18. Mittmann BJ, M Braun, F Runck, B Schmitz, TN Tran, A Yamlahi, et al. (2022) Deep learning-based classification of DSA image sequences of patients with acute ischemic stroke. *Int J Comput Assist Radiol Surg*, **17**(9): 1633-1641.
19. Lee SJ, B Liu, N Rane, P Mitchell, R Dowling and B Yan (2021) Correlation between CT angiography and digital subtraction angiography in acute ischemic strokes. *Clin Neurol Neurosurg*, **200**: 106399.
20. Salehi L, J Jaskolka, M Ossip, P Phalpher, R Valani and M Mercuri (2022) Utilization of CT angiography of the head and neck in the era of endovascular therapy for acute ischemic stroke: a retrospective study. *Emerg Radiol*, **29**(2): 291-298.
21. Siniscalchi A, G Malferrari, P Lochner and S Sanguigni (2021) Transcranial Doppler Ultrasonography in Pre-hospital Management of Stroke: Can it make a Difference? *Curr Med Imaging*, **17**(7): 850-853.
22. Kilburg C, J Scott McNally, A de Havenon, P Taussky, MY Kalani and MS Park (2017) Advanced imaging in acute ischemic stroke. *Neurosurg Focus*, **42**(4): E10.
23. Wannamaker R, B Buck and K Butcher (2019) Multimodal CT in Acute Stroke. *Curr Neurol Neurosci Rep*, **19**(9): 63.
24. Saqqur M, K Khan, C Derksen, A Alexandrov and A Shuaib (2018) Transcranial Doppler and Transcranial Color Duplex in Defining Collateral Cerebral Blood Flow. *J Neuroimaging*, **28**(5): 455-476.
25. Brisson RT, R Santos, L Stefano, CMA Barreira, JFL Arruda, FA Dias, et al. (2021) Association between Tomographic Characteristics of the Temporal Bone and Transtemporal Window Quality on Transcranial Color Doppler Ultrasound in Patients with Stroke or Transient Ischemic Attack. *Ultrasound Med Biol*, **47**(3): 511-516.
26. Anzidei M, A Napoli, F Zaccagna, P Di Paolo, L Saba, B Cavallo Marincola, et al. (2012) Diagnostic accuracy of colour Doppler ultrasonography, CT angiography and blood-pool-enhanced MR angiography in assessing carotid stenosis: a comparative study with DSA in 170 patients. *Radiol Med*, **117**(1): 54-71.
27. Tian B, Y Jiang, Q Kang, B Xu, R Liu, Q Liu, et al. (2018) Comparative study of 4D CTA and DSA for vascular assessment in moyamoya disease. *Clin Imaging*, **48**: 74-78.
28. Bajus A, L Streit, T Kubek, A Novák, J Vaniček, O Šedivý, et al. (2023) Color Doppler ultrasound versus CT angiography for DIEP flap planning: A randomized controlled trial. *J Plast Reconstr Aesthet Surg*, **86**: 48-57.

