

Study on the application of multislice spiral CT in the diagnosis and evaluation of radiotherapy efficacy for esophageal cancer

W. Huang^{1#}, L. Wang^{2#}, H. Ye^{3*}

¹11st Ward of Tumor Center, Navy Anqing Hospital, Anqing, China

²Department of Imaging, Affiliated Haimen Hospital of Xinglin College, Nantong University, Nantong, China

³Department of Radiology, Wenzhou TCM Hospital of Zhejiang Chinese Medical University, Wenzhou, China

ABSTRACT

► Original article

*Corresponding author:

Hongda Ye, BM,

E-mail:

wzzyyfsk2020@163.com

Received: May 2024

Final revised: June 2024

Accepted: July 2024

Int. J. Radiat. Res., January 2025;
23(1): 121-125

DOI: 10.61186/ijrr.23.1.121

Keywords: Multislice spiral CT; Esophageal cancer; Diagnosis; Radiotherapy.

Background: To analyze the application value of multislice spiral CT in the diagnosis of esophageal cancer and the evaluation of radiotherapy efficacy. **Materials and Methods:** A total of 90 esophageal cancer patients treated in our hospital from October 2022 to December 2023 were selected and underwent multislice spiral CT examination. Surgical pathology diagnosis results were used as the gold standard for this study. The diagnostic accuracy of multislice spiral CT for T and N staging of esophageal cancer patients was statistically analyzed. CT perfusion parameters [permeability surface (PS), mean transit time (MTT), blood volume (BV), blood flow (BF)] were compared between the complete remission (CR) group and the non-CR group after radiotherapy. ROC analysis was used to evaluate the predictive efficiency of CT perfusion parameters for CR. **Results:** The diagnostic accuracy of multislice spiral CT for T1, T2, T3, and T4 staging in esophageal cancer patients was 78.57%, 83.33%, 87.50%, and 95.00%, respectively. The diagnostic accuracy for N0 and N1 staging was 91.89% and 92.45%, respectively. The CR group had lower BV, BF, MTT, and PS compared to the non-CR group ($P < 0.05$). Combined detection of BV, BF, MTT, and PS had a higher sensitivity (95.12%) for predicting CR than single detection methods (66.52%, 76.86%, 72.39%, 77.63%) ($P < 0.05$), with no significant difference in specificity between combined (80.26%) and single detections (78.46%, 81.24%, 82.71%, 80.89%) ($P > 0.05$). **Conclusion:** Multislice spiral CT can accurately diagnose T and N staging in esophageal cancer patients. Combined detection of CT perfusion parameters BV, BF, MTT, and PS can improve the sensitivity of predicting CR, providing important reference value.

INTRODUCTION

Esophageal cancer is a clinically common malignant tumor. Risk factors include human papillomavirus infection, family genetics, excessive intake of nitrites, smoking, and drinking. Typical symptoms are progressive dysphagia, accompanied by hoarseness, dyspnea, and in severe cases, esophageal perforation, hematemesis, and melena, posing a threat to the patient's life ^(1, 2). Surveys show that esophageal cancer ranks fourth in the mortality rate of malignant tumors in China ^(3, 4). Due to the atypical clinical symptoms in the early stages of esophageal cancer, it is easily confused with chronic pharyngitis, leading to a late diagnosis and missing the best surgical treatment opportunity ^(5, 6). Therefore, radiotherapy has become one of the important clinical treatments for esophageal cancer. Techniques such as intensity-modulated radiotherapy (IMRT) and three-dimensional conformal radiotherapy (3D-CRT) have achieved certain success in treating esophageal cancer. Early evaluation of radiotherapy efficacy helps guide

clinical individualized treatment plans, improving patient prognosis. TNM staging is the main basis for clinically assessing the severity and prognosis of malignant tumors ⁽⁷⁾. Thus, early and accurate clinical staging and efficacy evaluation of esophageal cancer patients are crucial. Multislice spiral CT is a commonly used diagnostic technique for esophageal cancer and other esophageal lesions. It can clearly display the tumor's location, has strong repeatability, is low-cost, easy to operate, and non-invasive ^(8, 9). Previously, multislice spiral CT has mostly been used in disease diagnosis, with few reports on its evaluation of radiotherapy efficacy ⁽¹⁰⁾. This study aims to explore the application value of multislice spiral CT in the diagnosis and evaluation of radiotherapy efficacy for esophageal cancer by examining 90 esophageal cancer patients treated in our hospital from November 2021 to December 2023, providing more reference for clinical staging and predicting radiotherapy efficacy in esophageal cancer, thereby better guiding clinical diagnosis and treatment of esophageal cancer. The novelty of this study lies in its focus on the practical application of

multislice spiral CT for early and precise evaluation of radiotherapy outcomes, a relatively unexplored area that holds significant potential for enhancing personalized treatment strategies and improving patient prognosis in esophageal cancer. This research could pave the way for more widespread use of this imaging technique in routine clinical practice, offering a new perspective on integrating advanced diagnostic tools with therapeutic monitoring.

MATERIALS AND METHODS

General information

A total of 90 esophageal cancer patients treated in our hospital from October 2022 to December 2023 were selected, including 55 males and 35 females, aged 45-85 years, with an average age of (65.75±3.85) years (table 1). The study was approved by the hospital ethics committee. (1) Inclusion criteria: ① All met the "Expert Consensus on Early Screening and Endoscopic Diagnosis and Treatment of Esophageal Cancer" diagnostic criteria for "esophageal cancer"; ② Age >18 years, gender not limited; ③ No major organ dysfunction such as kidney or liver; ④ Mentally normal, able to cooperate with doctors to complete this study; ⑤ Expected survival >6 months. (2) Exclusion criteria: ① Women who are breastfeeding, planning to conceive, or pregnant; ② Poor CT imaging quality, local artifact interference; ③ Concurrent participation in other studies; ④ Combined with hyperthyroidism or other diseases; ⑤ Combined with other malignant tumors; ⑥ History of drug dependence, drug abuse, or alcohol addiction; ⑦ Allergic to contrast agents used in this study. Barium swallow imaging and CT images before and after radiotherapy in esophageal cancer patients are shown in figure 1.

Table 1. Demographic information on patients with esophageal cancer.

Demographic Information	Value
Total Patients	90
Gender	
Male	55
Female	35
Age Range (years)	45-85
Average Age (years)	65.75 ± 3.85
Tumor Stage (T)	
T1	14
T2	24
T3	32
T4	20
Lymph Node Status (N)	
N0	37
N1	53

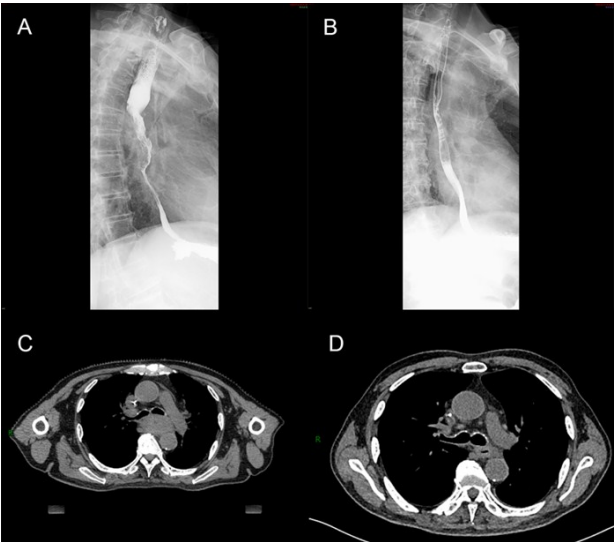


Figure 1. Barium swallow imaging and CT images of esophageal cancer patients before and after radiotherapy. (A) Barium swallow imaging before radiotherapy in esophageal cancer patients; (B) Barium swallow imaging after radiotherapy in esophageal cancer patients; (C) CT image before radiotherapy in esophageal cancer patients; (D) CT image after radiotherapy in esophageal cancer patients.

Methods

Multislice spiral CT examination: GE 128-slice 256-layer CT (GE Healthcare, USA) was used, with a slice thickness of 5 mm, tube current of 150 mAs, tube voltage of 150 kV, reconstruction layer thickness of 0.625 mm, pitch of 1.25, using standard reconstruction method and large scan field. Patients were instructed to take a supine position, breathe calmly, and undergo chest plain scan to determine the lesion location and maximum plane. The lesion location was used as the center for 8-layer enhanced scanning. A high-pressure injector (Ulrich Medical, Germany) was used to inject 50 mL of iodixanol (320 mg/mL, Visipaque, GE Healthcare, Ireland) via the elbow vein at a rate of 4 mL/s. Scanning of 8 layers was performed 5 seconds after injection, with a 1-second interval. The obtained images were then transferred to the workstation, the region of interest (ROI) was selected, and CT perfusion parameters [permeability surface (PS), mean transit time (MTT), blood volume (BV), blood flow (BF)] were calculated. The final recorded value was the average of three consecutive measurements. All multislice spiral CT examinations were diagnosed by the same two experienced physicians with more than 5 years of experience using a double-blind method. Any disagreements were discussed to determine the final diagnosis. Radiotherapy was performed using an Elekta Synergy linear accelerator (Elekta, Sweden). The treatment planning system (TPS) utilized was Monaco (Elekta, Sweden), which employs advanced algorithms for intensity-modulated radiotherapy (IMRT) and three-dimensional conformal radiotherapy (3D-CRT) planning. The total dose

administered to the primary tumor site ranged from 60 to 66 Gy, delivered in daily fractions of 2 Gy over 30 to 33 sessions. For patients with involved lymph nodes, an additional dose of 45 to 50 Gy was given, depending on the size and location of the nodes, delivered in daily fractions of 1.8 to 2 Gy over 25 to 28 sessions. The radiotherapy plan was reviewed and approved by a multidisciplinary team, ensuring that the prescribed dose covered the entire tumor volume while sparing adjacent normal tissues to the greatest extent possible. During the treatment course, patients were monitored for any acute side effects, and dose adjustments were made as necessary based on their response and tolerance. Barium swallow imaging was performed to assess the esophageal anatomy and function in esophageal cancer patients before and after radiotherapy. The procedure was conducted using a digital radiography unit (Siemens Luminos Agile Max, Siemens Healthineers, Germany). Patients were instructed to fast for at least 6 hours prior to the examination to ensure an empty stomach. They were positioned upright on the radiography table. Patients were given a barium sulfate suspension (E-Z-HD, Bracco Diagnostics, USA) to drink. The standard concentration was used to provide optimal coating of the esophageal mucosa. Sequential radiographs were taken as the patient swallowed the barium suspension.

Observation indicators

CT perfusion parameters were compared between the complete remission (CR) group and the non-CR group after radiotherapy. The evaluation criteria for radiotherapy efficacy in esophageal cancer were as follows: CR: disappearance of lesions for 4 weeks. Partial Remission (PR): lesions reduced by $\geq 50\%$ compared to pre-treatment, for 4 weeks. No Change (NC): lesions reduced by $< 50\%$ or increased by $< 25\%$ compared to pre-treatment. Progression (PD): lesions increased by $\geq 25\%$ compared to pre-treatment.

Statistical analysis

Data processing was performed using Statistic Package for Social Science (SPSS) 26.0 software (IBM, Armonk, NY, USA). The t-test was used for quantitative data in the form of " $\bar{x} \pm s$ ", and the χ^2 test was used for categorical data in the form of "[n/%]". ROC analysis was used to evaluate the predictive efficiency of CT perfusion parameters for CR, with $P < 0.05$ indicating a significant difference.

RESULTS

Efficiency of multislice spiral CT for T and N staging

The diagnostic accuracy of multislice spiral CT for T staging in esophageal cancer patients was as follows: T1: 78.57%; T2: 83.33%; T3: 87.50%; T4: 95.00%. For N staging, the diagnostic accuracy was:

N0: 91.89%; N1: 92.45%. These results demonstrate the high accuracy of multislice spiral CT, particularly in advanced stages (T3 and T4). Detailed results are presented in tables 2 and 3.

Table 2. Diagnostic efficiency of multislice spiral CT for t staging in esophageal cancer patients.

Multislice Spiral CT Staging	Gold Standard Staging			
	T1	T2	T3	T4
T ₁	11	1	2	0
T ₂	2	20	2	0
T ₃	1	3	28	1
T ₄	0	0	0	19
Total	14	24	32	20

Table 3. Diagnostic efficiency of multislice spiral CT for N staging in esophageal cancer patients.

Multislice Spiral CT Staging	Gold Standard Staging	
	N0	N1
N0	34	49
N1	3	4
Total	37	53

Comparison of CT perfusion parameters between CR and non-CR groups

After radiotherapy, 38 patients achieved CR, and 52 non-CR. The CR group had significantly lower BV, BF, MTT, and PS values compared to the non-CR group ($P < 0.05$). See table 4 for details.

Table 4. Comparison of CT perfusion parameters between CR and non-CR groups ($\pm s$).

Group	Cases (n)	BV (mL/100g)	BF [mL/(min·100g)]	MTT (s)	PS [mL/(min·100g)]
CR	38	5.09 \pm 1.62	27.52 \pm 3.66	8.16 \pm 1.05	26.31 \pm 4.55
Non-CR	52	9.29 \pm 1.94	40.55 \pm 9.84	10.29 \pm 1.64	34.82 \pm 6.08
t	--	10.859	7.770	7.018	7.265
P	--	0.000	0.000	0.000	0.000

Predictive efficiency of CT perfusion parameters for CR

The area under the curve (AUC) for the combined detection of these parameters was 0.912 (95% CI: 0.847-0.937), indicating high predictive accuracy. The sensitivity and specificity of the combined detection method were: Sensitivity: 95.12%, significantly higher than individual detection methods (BV: 66.52%, BF: 76.86%, MTT: 72.39%, PS: 77.63%) ($P < 0.05$). Specificity: 80.26%, not significantly different from individual detection methods (BV: 78.46%, BF: 81.24%, MTT: 82.71%, PS: 80.89%) ($P > 0.05$). These findings suggest that combining multiple CT perfusion parameters enhances the sensitivity of predicting complete response to radiotherapy without compromising specificity. Detailed results are presented in table 5.

Table 5. Predictive efficiency of CT perfusion parameters for CR.

Indicator	AUC	95% CI	Optimal Cutoff Value	Sensitivity	Specificity
BV	0.682	0.582-0.708	5.27	66.52	78.46
BF	0.746	0.626-0.819	28.13	76.86	81.24
MTT	0.713	0.618-0.801	8.64	72.39	82.71
PS	0.752	0.626-0.847	28.19	77.63	80.89
Combined	0.912	0.847-0.937	-	95.12	80.26

DISCUSSION

According to surveys, the 5-year survival rate for esophageal cancer patients is less than 25%, and 21% of cancer deaths in China are due to esophageal cancer^(11, 12). Currently, various clinical treatment options are available for esophageal cancer, but since most patients are diagnosed at an advanced stage, radiotherapy has become one of the primary treatment methods⁽¹³⁻¹⁵⁾. Early diagnosis and treatment are key to improving patient prognosis, and accurate staging of esophageal cancer is crucial for formulating clinical treatment plans.

X-ray barium swallow can show esophageal mucosal damage, filling defects, and esophageal dilation, but it only observes local lesions and does not meet the clinical diagnosis and treatment needs^(16, 17). In contrast, multislice spiral CT, with its high spatial resolution, fast scanning speed, short scanning time, and comprehensive information collection, can clearly display the size, shape, and relationship of the lesion with surrounding tissues through three-dimensional reconstruction technology. This significantly improves the accuracy of disease diagnosis^(18, 19). The current study shows that the diagnostic accuracy of multislice spiral CT for T1, T2, T3, and T4 staging in esophageal cancer patients is 78.57%, 83.33%, 87.50%, and 95.00%, respectively. The diagnostic accuracy for N0 and N1 staging is 91.89% and 92.45%, respectively. These findings indicate that multislice spiral CT can enhance the diagnostic accuracy of clinical staging of esophageal cancer, assisting clinicians in making comprehensive assessments of the patient's condition.

Other studies have also demonstrated the utility of advanced imaging techniques in improving diagnostic accuracy and treatment planning for esophageal cancer. Multislice CT could accurately stage esophageal cancer and predict response to radiotherapy, aligning with our findings⁽²⁰⁾.

Multislice spiral CT perfusion parameters can reflect the blood flow perfusion characteristics of the lesion site, providing clinicians with hemodynamic information related to the lesion⁽²¹⁾. Generally, the higher the malignancy of the tumor, the higher the permeability of the new blood vessels, and consequently, the higher the BV, BF, MTT, and PS⁽²²⁻²⁴⁾. This study shows that the CR group had significantly lower BV, BF, MTT, and PS compared to the non-CR group, indicating that as the condition of esophageal cancer patients improves after radiotherapy, these perfusion parameters decrease significantly. This decrease is likely due to the effects of radiotherapy in killing cancer cells, blocking the blood supply between the lesions and surrounding tissues, reducing the number of microvessels in tumor cells, decreasing blood flow perfusion and tumor microvessel density, and inducing tumor cell

necrosis.

A study by Zhu *et al.* demonstrated similar findings, showing that effective chemotherapy in esophageal cancer patients led to a significant reduction in BV, consistent with our results⁽²⁵⁾. The sensitivity of combined detection of BV, BF, MTT, and PS in predicting CR (95.12%) was higher than that of single detection methods. The specificity of combined detection (80.26%) was not significantly different from that of single detection. This suggests that the combined detection of BV, BF, MTT, and PS has higher sensitivity in predicting complete remission in esophageal cancer patients undergoing radiotherapy, compensating for the shortcomings of single detection methods. It has important reference value in the clinical efficacy and prognosis evaluation of esophageal cancer. The lack of significant difference in specificity between combined and single detection methods may be related to the small sample size of this study, which could lead to biased results. Future studies with larger sample sizes are needed to validate these findings and further explore the potential of multislice spiral CT in various clinical settings.

CONCLUSION

In summary, multislice spiral CT can improve the diagnostic accuracy of clinical staging of esophageal cancer. Combined detection of multislice spiral CT perfusion parameters (BV, BF, MTT, and PS) can also improve the sensitivity of predicting CR after radiotherapy, providing valuable reference for evaluating the patient's condition and prognosis. This method is worth reference and promotion in clinical practice.

ACKNOWLEDGMENT

None.

Conflict of interests: The authors declare that they have no conflict of interests.

Funding: This study did not receive any funding in any form.

Ethical consideration: This study was approved by the ethics committee of Navy Anqing Hospital (Approval no. AQ457216). Signed written informed consents were obtained from the patients and/or guardians.

Authors' contributions: W.H., L.W. and H.Y. designed the study and performed the experiments, W.H. and L.W. collected the data, H.Y. analyzed the data, W.H., L.W. and H.Y. prepared the manuscript. All authors read and approved the final manuscript.

REFERENCES

1. Sohda M, Kuwano H, Saeki H, *et al.* (2021) Nationwide survey of

- neuroendocrine carcinoma of the esophagus: a multicenter study conducted among institutions accredited by the Japan Esophageal Society. *Journal of Gastroenterology*, **56**(4): 350-359.
2. Takakusagi Y, Yoshida D, Kusano Y, et al. (2021) Dosimetric comparison between carbon-ion radiotherapy and photon radiotherapy for stage I esophageal cancer. *In Vivo*, **35**(1): 447-452.
 3. Li XJ, Li CR, Ye YC, Zhang YS, Zong XQ, Feng CL (2024) A Dosimetric comparative study of carbon-ion radiotherapy versus x-ray volumetric modulated arc therapy for stage III non-small-cell lung cancer. *Nigerian Journal of Clinical Practice*, **27**(2): 236-243.
 4. Light E and Bridge P (2024) Clinical indications for carbon-ion radiotherapy in the UK: A critical review. *Radiography (Lond)*, **30**(2): 425-430.
 5. Martin JT (2021) Consolidation therapy in esophageal cancer. *Surgical Clinics of North America*, **101**(3): 483-488.
 6. Li J, Jia Y, Cheng Y, Wang J (2020) Chemoradiotherapy vs radiotherapy for nonoperative early stage esophageal cancer: A seer data analysis. *Cancer Medicine*, **9**(14): 5025-5034.
 7. Byun HK, Kim C, Seong J (2023) Carbon ion radiotherapy in the treatment of hepatocellular carcinoma. *Clin Mol Hepatol*, **29**(4): 945-957.
 8. Song S, Jiang H, Li H, Fu W, Yin Y, Liu L (2022) Application of contrast-enhanced ultrasound combined with multislice spiral CT in the diagnosis of gastric cancer. *Minerva Gastroenterology*, **68**(3): 356-358.
 9. Wang J, Tang L, Lin L, Li Y, Li J, Ma W (2022) Imaging characteristics of esophageal cancer in multi-slice spiral CT and barium meal radiography and their early diagnostic value. *Journal of Gastrointestinal Oncology*, **13**(1): 49-55.
 10. Hao J, Liu W, Zhao C, Xia T (2021) The diagnostic significance of 64 -slice spiral CT combined with serological CA19-9, Bcl-2, CYFRA21-1 detection in thoracic esophageal carcinoma. *Transl Cancer Res*, **10**(12): 5383-5389.
 11. Zhou XC, Chen QL, Huang CQ, Liao HL, Ren CY, He QS (2019) The clinical application value of multi-slice spiral CT enhanced scans combined with multiplanar reformations images in preoperative T staging of rectal cancer. *Medicine*, **98**(28): e16374.
 12. Ippolito D, Drago SG, Franzesi CT, Fior D, Sironi S (2016) Rectal cancer staging: Multidetector-row computed tomography diagnostic accuracy in assessment of mesorectal fascia invasion. *World Journal of Gastroenterology*, **22**(20): 4891-4900.
 13. Chen D, Xue Y, Mao Y, Chen Y (2021) Comment on "Prognostic impact of postoperative lymph node metastases after neoadjuvant chemoradiotherapy for locally advanced squamous cell carcinoma of esophagus". *Annals of Surgery*, **274**(6): e767-e768.
 14. Balasubramanian S, Chittawadagi B, Misra S, Ramakrishnan P, Chinnusamy P (2022) Propensity matched analysis of short term oncological and perioperative outcomes following robotic and thoracalaparoscopic esophagectomy for carcinoma esophagus-the first Indian experience. *Journal of Robotic Surgery*, **16**(1): 97-105.
 15. Leng X, Yang H, Fu J, Han Y (2021) Response to comment on "Prognostic impact of postoperative lymph node metastases after neoadjuvant chemoradiotherapy for locally advanced squamous cell carcinoma of esophagus". *Annals of Surgery*, **274**(6): e768-e769.
 16. Castoro C, Scarpa M, Cagol M, et al. (2011) Nodal metastasis from locally advanced esophageal cancer: how neoadjuvant therapy modifies their frequency and distribution. *Annals of Surgical Oncology*, **18**(13): 3743-3754.
 17. Barbour AP, Jones M, Gonen M, et al. (2008) Refining esophageal cancer staging after neoadjuvant therapy: importance of treatment response. *Annals of Surgical Oncology*, **15**(10): 2894-2902.
 18. Jiang H, Liu L, Song S, Zhuang T, Liu Y, Li H (2023) Comparative study of 3.0T magnetic resonance imaging and multislice spiral CT in the diagnosis of gastric cancer. *Minerva Medica*, **114**(4): 547-550.
 19. Yin JJ, Hu X, Hu S, Sheng GH (2023) Efficacy of multi-slice spiral computed tomography in evaluating gastric cancer recurrence after endoscopic submucosal dissection. *World Journal of Gastrointestinal Oncology*, **15**(9): 1636-1643.
 20. Yin JJ, Hu X, Hu S, Sheng GH (2023) Efficacy of multi-slice spiral computed tomography in evaluating gastric cancer recurrence after endoscopic submucosal dissection. *World J Gastrointest Oncol*, **15**(9): 1636-1643.
 21. Choi KS, Kim SH, Kim SG, Han JK (2016) Early gastric cancers: Is CT surveillance necessary after curative endoscopic submucosal resection for cancers that meet the expanded criteria? *Radiology*, **281**(2): 444-453.
 22. Suzuki H, Oda I, Abe S, et al. (2016) High rate of 5-year survival among patients with early gastric cancer undergoing curative endoscopic submucosal dissection. *Gastric Cancer*, **19**(1): 198-205.
 23. Shim CN and Lee SK (2014) Endoscopic submucosal dissection for undifferentiated-type early gastric cancer: do we have enough data to support this? *World Journal of Gastroenterology*, **20**(14): 3938-3949.
 24. Shiotsuki K, Takizawa K, Ono H (2022) Indications of endoscopic submucosal dissection for undifferentiated early gastric cancer: current status and future perspectives for further expansion. *Digestion*, **103**(1): 76-82.
 25. Zhu Y, Yao W, Xu BC, et al. (2021) Predicting response to immunotherapy plus chemotherapy in patients with esophageal squamous cell carcinoma using non-invasive Radiomic biomarkers. *BMC Cancer*, **21**(1): 1167.

